

# The Full Continuum of Robotic Breast Surgery: Robotic-assisted Mastectomy, Robotic DIEP Flap, and Robotic Supermicrosurgery

Neil Tanna, MD, MBA\*†  
 Gainosuke Sugiyama, MD, MS\*†  
 Mark L. Smith, MD\*†  
 Susana Benitez Sanchez, MD†  
 Raquel A. Minasian, MD†  
 Emma Robinson, BS\*  
 Julia Silverman, BS†  
 John W. Shuck, MD†  
 Jesse Selber, MD, MPH, MHCM†

**Summary:** In recent years, robotic surgery has rapidly expanded to improve surgical outcomes in a variety of surgical subspecialties. Although plastic surgery has taken longer to integrate robotic surgery into practice, the advantages of robotic-assisted surgery, including improved visualization and resolution, minimally invasive approaches, and the ability to surpass human precision and scale, have driven its more recent adoption into plastic surgery. Currently, procedures performed with robotic assistance that are considered part of the continuum of surgical treatment of breast cancer include robotic-assisted nipple-sparing mastectomy, reconstruction with the robotic latissimus dorsi flap or the deep inferior epigastric artery perforator flap, and robotic microsurgery for the flap anastomosis and/or the surgical treatment of lymphedema. The authors provide an overview of robotic surgery and how it has been integrated into the field of plastic surgery, as well as a review of the most common procedures within the field where robotic assistance can be incorporated: nipple-sparing mastectomy, robotic latissimus flap, robotic deep inferior epigastric artery perforator flap breast reconstruction, and microvascular anastomoses. (*Plast Reconstr Surg Glob Open* 2023; 11:e5491; doi: 10.1097/GOX.0000000000005491; Published online 20 December 2023.)

## INTRODUCTION

Since its conception in the late 20th century, robotic surgery has advanced toward the forefront of surgical innovation.<sup>1</sup> An extension of laparoscopic surgery that greatly decreases the invasiveness and morbidity of surgery, robotic surgery is quickly expanding in its use. With benefits to both the surgeon and the patient, robotic surgery has become popular in a variety of surgical specialties, including head and neck surgery; gynecological surgery; urological surgery; neurosurgery; and, more recently, plastic surgery.<sup>2</sup>

The first robotic system adapted for use in surgery was the programmable universal machine for assembly 200 (PUMA 200), which consisted of a single arm and primarily worked using fixed anatomical landmarks, such as

in transurethral resection of the prostate and computed tomography-guided brain tumor biopsies.<sup>2</sup> Advancements in the surgical robotic systems eventually led to the development of the da Vinci system; developed for forward areas in battle and near space, this technology was developed by DARPA and then licensed to Intuitive Surgical. The improved precision and visualization and enhanced minimally invasive capabilities allowed the DaVinci to dominate robotic surgery and enabled surgeons to perform dynamic operations robotically. Using the da Vinci system, the surgeon sits at a console and remotely controls the robotic system positioned at the bedside. Robotic-assisted surgery helps surgeons work in capacities that surpass human limitations by reducing tremor and fatigue, as well as providing up to 7 degrees of freedom, ergonomic positioning, 3D-magnified vision, and improved resolution.<sup>2,3</sup>

From the \*Department of Surgery, The Donald and Barbara Zucker School of Medicine at Hofstra/Northwell, Hempstead, N.Y.; †Department of Surgery, Northwell Health, Great Neck, N.Y.; and ‡Department of Surgery, Corewell Health, Grand Rapids, Mich.

Received for publication August 19, 2023; accepted October 24, 2023.

Copyright © 2023 The Authors. Published by Wolters Kluwer Health, Inc. on behalf of The American Society of Plastic Surgeons. This is an open-access article distributed under the terms of the [Creative Commons Attribution-Non Commercial-No Derivatives License 4.0 \(CCBY-NC-ND\)](https://creativecommons.org/licenses/by-nc-nd/4.0/), where it is permissible to download and share the work provided it is properly cited. The work cannot be changed in any way or used commercially without permission from the journal.

DOI: 10.1097/GOX.0000000000005491

## ROBOTICS IN PLASTIC SURGERY: OVERVIEW

Over the last two decades, robotic surgery has become widely adopted as routine in many surgical

Disclosure statements are at the end of this article, following the correspondence information.

Related Digital Media are available in the full-text version of the article on [www.PRSGlobalOpen.com](http://www.PRSGlobalOpen.com).

fields. One specialty in which robotic surgery has progressed more rapidly is head and neck surgery.<sup>4,5</sup> The field of plastic surgery, however, has taken more time to integrate robotic-assisted surgery into routine procedures.<sup>6–8</sup> Robotic-assisted surgery has gained popularity in oncologic and reconstructive breast surgery, with the development of robotic-assisted procedures such as nipple-sparing mastectomy (NSM), latissimus dorsi muscle flap harvest, deep inferior epigastric perforator (DIEP) flap breast reconstruction, and microsurgery with arterial and venous anastomosis being done with robotic assistance routinely.<sup>2</sup> With the advancements in the field of robotic plastic surgery, it will soon be possible for patients to undergo an extirpative breast surgery with immediate reconstruction utilizing robotic assistance. The authors believe that the technology exists for a patient to receive a robotic mastectomy with robotic DIEP flap harvest and robotic-assisted microsurgical anastomosis and prophylactic lymphovenous bypass when appropriate.

## ROBOTIC MASTECTOMY

In NSM, the primary goal is to remove the breast tissue completely while preserving blood flow to the nipple-areolar complex (NAC) and breast skin envelope. In the process of removing breast tissue, the main blood supply to the nipple is cut off, leaving the breast skin as the remaining source of blood flow to the nipple. In a traditional NSM, access to the breast is made through an incision on the actual breast, such as an inframammary fold incision. These incisions further devascularize the blood supply to the NAC and skin envelope. Furthermore, challenges of a traditional NSM through inframammary incision can include awkward positioning and difficulty visualizing and dissecting the more remote upper pole regions of the breast.<sup>9</sup> The robotic nipple-sparing mastectomy (R-NSM) is a technological development in the NSM procedure that offers a minimally invasive approach with the potential to limit some of the challenges faced in a traditional procedure. In the most recent iteration of the R-NSM, a single incision is made away from the breast, in the anterior axillary line at the level of the NAC, and the breast is insufflated, uniformly retracting the superficial tissue along the plane of dissection, creating a consistent line of sight and working distance.<sup>9</sup> By keeping the incision away from the breast, the blood supply to the breast soft tissue envelope is preserved (Fig. 1). Although aesthetics are not the primary incentive for the aforementioned approach, there is an additional visual benefit for the patient of having the scar away from the breast, along the lateral chest wall (bra line). The R-NSM approach improves visualization and accessibility for dissection across all regions of the breast, while simultaneously resulting in a low rate of skin and nipple necrosis and a high rate of patient satisfaction.<sup>9,10</sup>

Antonio Toesca performed the first R-NSM in 2015, and the technique has since been adopted by other surgeons in Europe and Asia.<sup>9</sup> In 2017, Toesca et al described the outcomes of the first robotic nipple-sparing mastectomies with immediate robotic breast reconstruction. The

## Takeaways

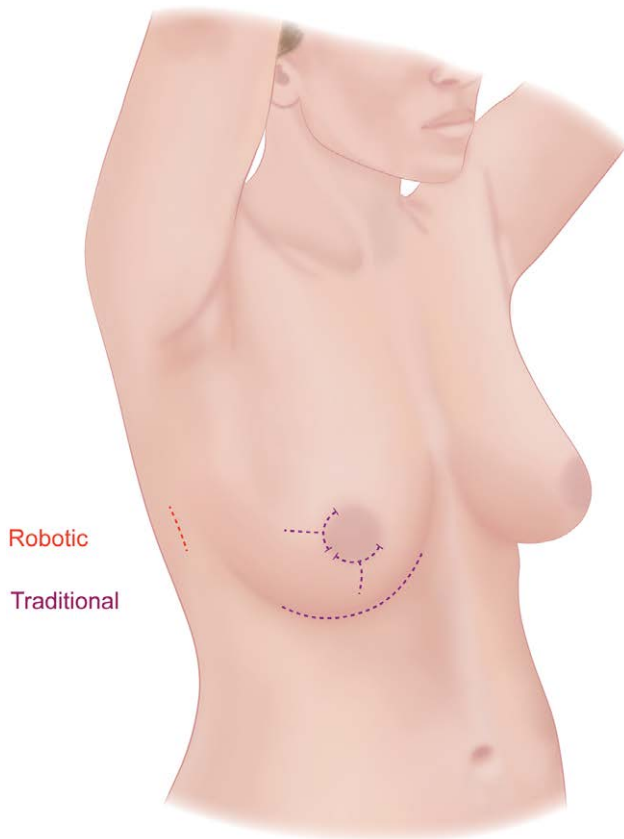
**Question:** What is robotic breast surgery? What is the contemporary state of robotic-assisted mastectomy, flap harvest, and microsurgery?

**Findings:** Currently, procedures performed with robotic assistance that are considered part of the continuum of surgical treatment of breast cancer include robotic-assisted nipple-sparing mastectomy, reconstruction with the robotic latissimus dorsi flap or the deep inferior epigastric artery perforator (DIEP) flap, and robotic microsurgery for the flap anastomosis and/or the surgical treatment of lymphedema.

**Meaning:** Robotic nipple-sparing mastectomy, robotic latissimus flap, robotic DIEP flap breast reconstruction, and robotic-assisted microvascular anastomoses are becoming prevalent practices in plastic surgery.

low complication rates, rapid learning curve, and low conversion rate to open surgery reported in this study has encouraged increasing numbers of surgeons to adopt robotic breast surgery into their practices.<sup>11</sup> In a case control study in Seoul, Lee et al found significantly lower rates of postoperative nipple necrosis and high-grade postoperative complications, such as infection, bleeding and wound dehiscence, in patients undergoing R-NSMs compared with those undergoing traditional NSMs.<sup>10</sup> In a systematic review by Filipe et al, 49 studies including a total of 13,886 cases were reviewed to analyze differences in complication rates between NSM and R-NSM, examining outcomes such as implant loss, hematoma, necrosis, infection, and seroma.<sup>12</sup> This meta-analysis found no statistically significant difference in complication rates between the two groups, indicating that the R-NSM is a reasonable and safe option for patients requiring a prophylactic or therapeutic mastectomy.<sup>12</sup>

The most notable limitations of the R-NSM are the challenges in learning the technique, as well as patient breast size and shape-related indications.<sup>11,13</sup> It is important to acknowledge that R-NSM is not the most suitable technique for all patients. As summarized by an expert panel from the International Endoscopic and Robotic Breast Surgery Symposium in 2019, the indications for a R-NSM include early breast cancer and tumor smaller than 5 cm with no skin, chest wall, or NAC involvement.<sup>14</sup> In addition, some contraindications for the R-NSM include breast cancer invasion of the pectoralis muscle or NAC and large or ptotic breasts. Given the need for mastectomy skin flap reduction in large or ptotic breasts, R-NSM is not advocated in these patients. Studies examining the feasibility and outcomes of R-NSMs thus far have primarily enrolled patients with small to medium-sized breasts without ptosis, and have found benefits in this population.<sup>10,11</sup> There is limited literature describing the technique in different sized breasts. Additionally, the learning curve of the technique has been examined and been shown to be relatively rapid, with significant decrease in time of procedure appearing around the 22nd procedure performed.<sup>13</sup> Despite these limitations, the potential



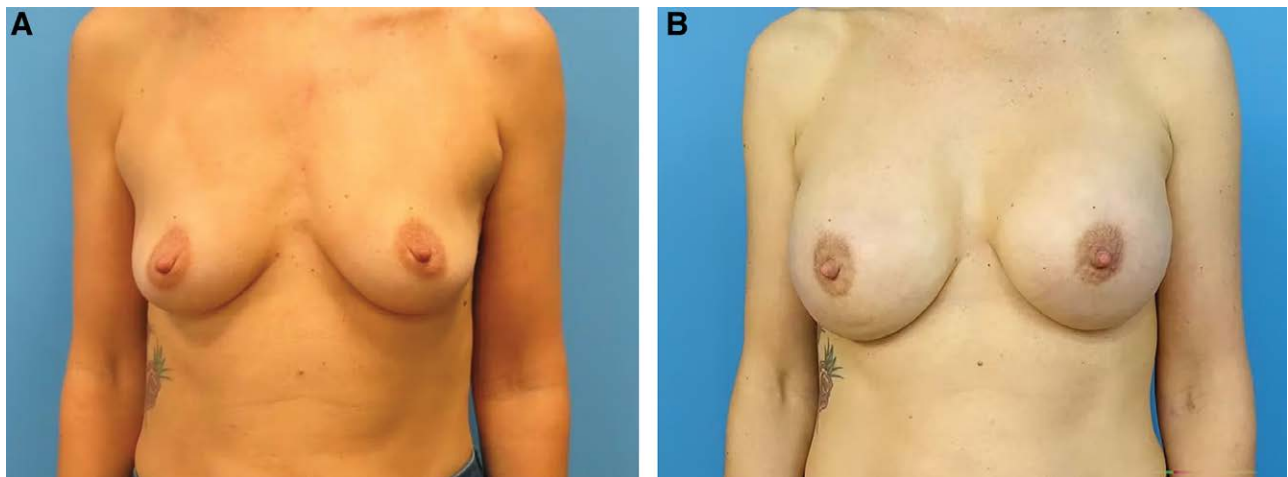
**Robotic vs Traditional Incisions with Nipple-sparing Mastectomy**

**Fig. 1.** In R-NSM, a single incision is made away from the breast, in the anterior axillary line at the level of the NAC. Traditional NSM procedures involve incision(s) on the actual breast. By keeping the incision away from the breast, the blood supply to the breast soft tissue envelope is preserved.

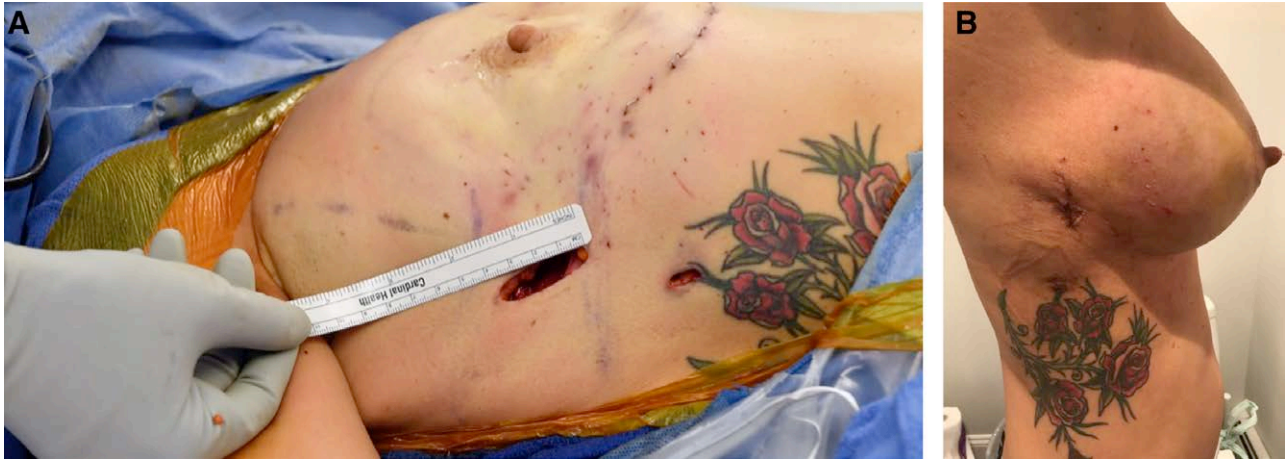benefits provided by the R-NSM technique, including increased visibility and ease of dissection, decreased complication rates, and improved aesthetic outcomes, offer reasonable motivation to continue to develop and practice this procedure (Fig. 2).<sup>14,15</sup> At present, there is an ongoing multicenter investigational device exemption trial sponsored by Intuitive Surgical in collaboration with the Food and Drug Administration. The goal of the trial is to achieve a Food & Drug Administration–approved indication for the Da Vinci robot for R-NSM. Endpoints include 30-day complications, conversion to open technique, adverse events related to the device, and reconstructive complications. Two of the authors (N.T. and J.C.S.) are involved in the trial. An additional IDE trial is being initiated to examine the suitability of the SP system for R-NSM, with the logic that a 3-cm incision is being used anyway for specimen extraction and the setup may facilitate a smoother axillary lymph node sampling and elimination of an additional port site.

**Operative Technique**

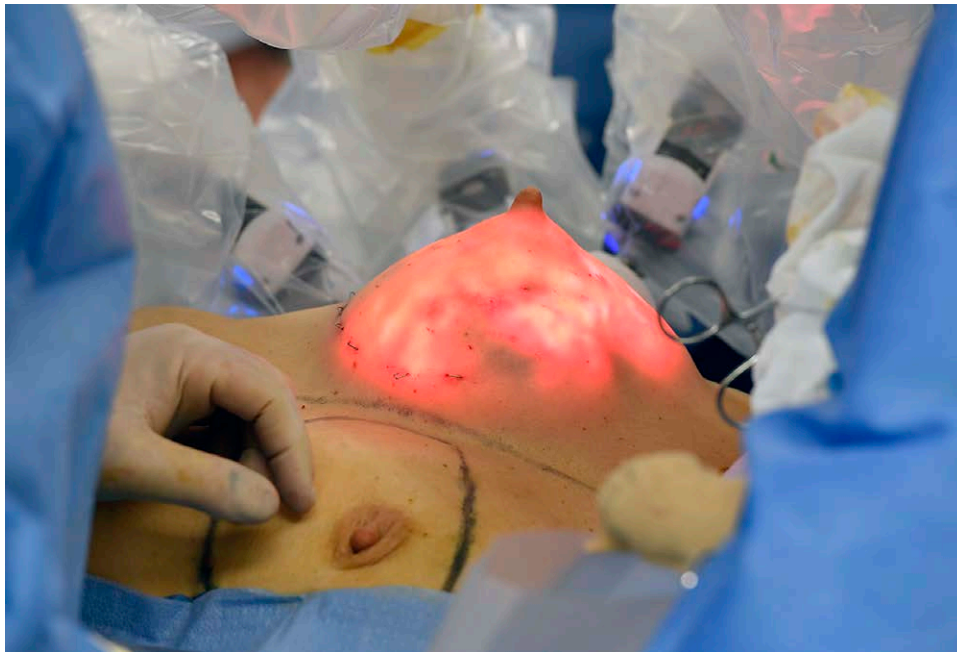When starting the R-NSM, the patient is placed supine on the operating room table with arms out in neutral position. A 3-cm vertical incision is made between the anterior axillary line and the midaxillary line with the lower end of the incision at the level of the nipple (Fig. 3). The first portion of the dissection is performed open through this incision down through the dermis into the subcutaneous tissue. A flap is raised anteriorly to the lateral edge of the breast. A normal mastectomy flap is then created using electrocautery along the entire borders of the breast to the mid-nipple line as well as along the anterior surface of the breast to the level of the nipple. Laterally, the dissection is carried down to the chest wall, and the retroglandular space is dissected off the pectoralis major muscle. The anterior and posterior dissections are then connected with electrocautery to the level of the nipple line.



**Fig. 2.** R-NSM avoids an incision on the visible breast. A patient is shown before (A) and three years after R-NSM (B) with immediate DTI prepectoral implant reconstruction.



**Fig. 3.** R-NSM is performed through a small incision along the lateral chest wall. A small incision is made off the breast to perform the R-NSM and reconstruction (A). The same patient is shown 2 weeks after R-NSM and immediate DTI prepectoral implant reconstruction (B).

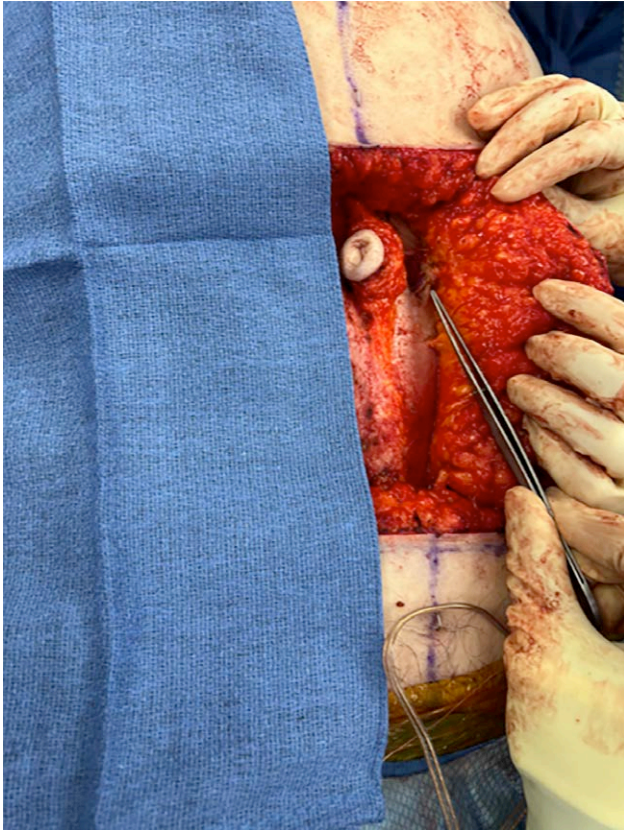


**Fig. 4.** With insufflation of the breast, the R-NSM is completed by dissecting medially under the nipple-areolar complex to the level of the sternum, then superiorly and inferiorly along the borders of the breast.

Before starting the robotic part of the procedure, the arm is placed over the patient's head and secured to an ether screen bar. A variety of fixation techniques and devices have been used for this purpose. The arm is released every 45 minutes to avoid any injuries to the shoulder. Next, an 8-mm robotic trocar is placed through a stab incision at the anterior axillary line at the level of the inframammary fold under direct visualization. A wound protector and GelPOINT mini device are placed through the 3-cm incision with insertion of two additional robotic trocars, as well as the AirSeal trocar, into this site. The robot is then docked on the ipsilateral side

of the mastectomy. With the use of monopolar scissors and fenestrated bipolar forceps, the mastectomy is completed by dissecting medially under the NAC to the level of the sternum, then superiorly and inferiorly along the borders of the breast (Fig. 4). Once the robotic dissection is completed, the robot is undocked, and the specimen is removed via the GelPOINT device.

In the current trial, robotic NSM is paired with an implant based breast reconstruction, either direct-to-implant (DTI) or tissue expander. Although a deflated tissue expander can be more straightforward to insert through the small incision, an implant (DTI) can be more

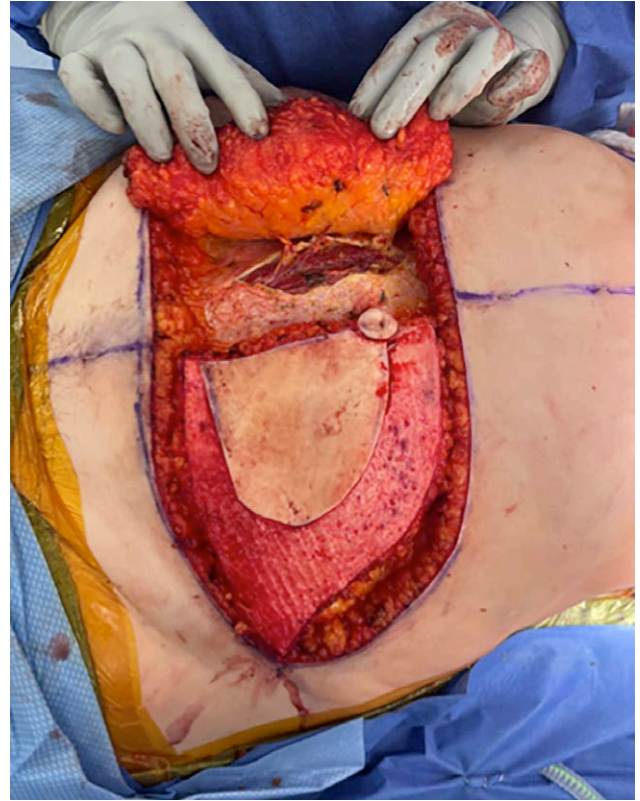

**Fig. 5.** Based on magnetic resonance angiogram, the perforator of interest is identified with minimal fascial opening.

challenging. The latter often requires an implant insertion funnell. Similarly, securing acellular dermal matrix at the reconstruction site can be challenging. This can be facilitated with robotic-assisted suturing.

### ROBOTIC DIEP

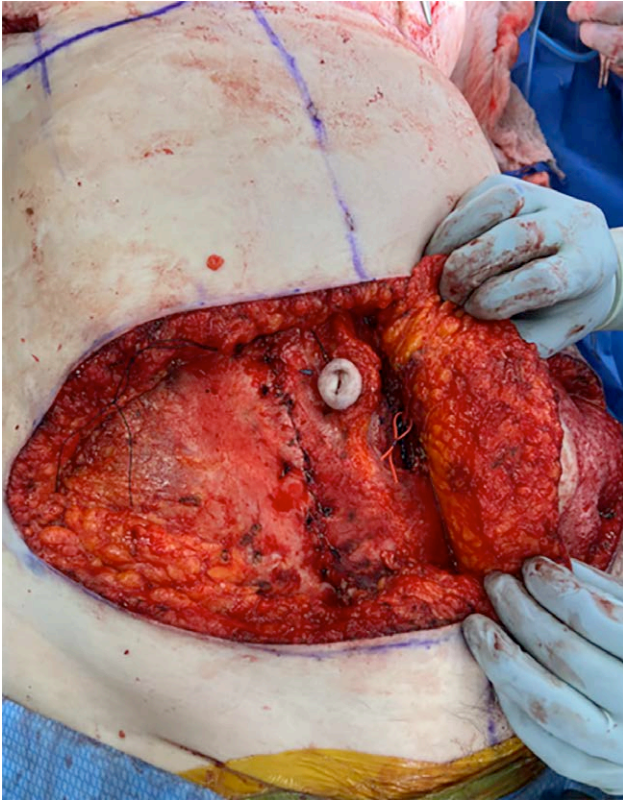Since the first mastectomy was done by Halstead in 1882, leaving behind a missing breast and a large chest wall defect, there has been dramatic development in the possibilities for breast reconstruction following the extirpative procedure.<sup>16</sup> Breast reconstruction has been shown to greatly increase patient satisfaction and well-being after mastectomy.<sup>17</sup> Initial attempts at breast reconstruction in the early 20th century used lipomas, autologous fat grafting, breast shifting, pectoralis minor flaps, and latissimus dorsi flaps, all generally resulting in large scars and suboptimal aesthetic results.<sup>16</sup> Over the last 30 years, there has been a resurgence in development of autologous breast reconstruction techniques and significant progress in the field. The DIEP flap breast reconstruction technique has become the gold standard for autologous breast reconstruction.<sup>2</sup> In a DIEP flap breast reconstruction, a patient's abdominal subcutaneous tissue and skin are harvested on a pedicle supplied by the DIEP artery and vein, which run along the deep surface of the rectus abdominis muscle. In a traditional DIEP flap procedure, a long fascial incision is typically necessary to retrieve the full length of the vascular



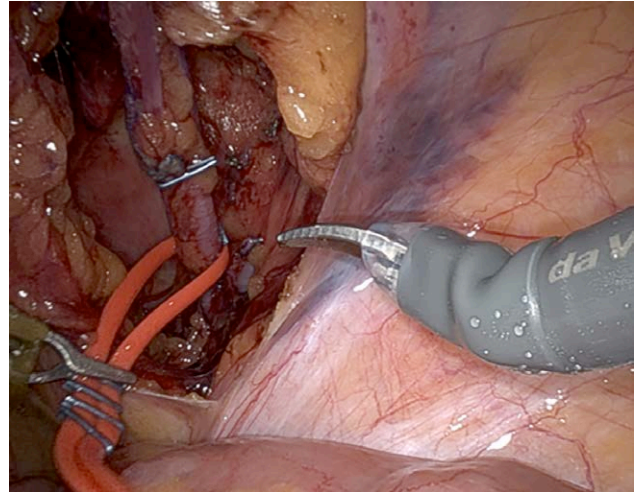
**Fig. 6.** The vascular anatomy of a patient can vary by laterality as it pertains to the intramuscular course of the pedicle. The intramuscular course of the pedicle transitions into the submuscular plane well below the arcuate line, obviating the benefit from robotic assistance. Nonetheless, the authors perform fascial sparing techniques on all patients, facilitated by headlights and appropriate instrumentation.

pedicle. This can lead to postoperative bulging, higher rates of hernias, and overall disruption of core strength and comfort, particularly when dissection proceeds below the arcuate line.<sup>2</sup> With the use of the robotic system, the pedicle can be dissected posteriorly in the intraperitoneal plane, allowing for minimization of the fascial disruption and maximization of the pedicle length, which can provide better patient donor site outcomes.<sup>2,18</sup> In the robotic DIEP flap procedure, the superficial tissue flap is elevated, then the perforator vessels are dissected using a fascial incision that is only long enough to facilitate the intramuscular dissection of the pedicle. Once the posterior sheath is identified, port access and insufflation of the peritoneal cavity is obtained; the robot is docked and targeted; and finally, robotic dissection of the rest of the pedicle that lies posterior to the rectus abdominis muscle is performed within the peritoneal cavity.<sup>18</sup> Through the use of this technique, smaller segments of the rectus fascia are disrupted, and there is no level of the anterior abdominal wall that does not have support from either an intact anterior rectus fascia or an intact posterior rectus fascia.

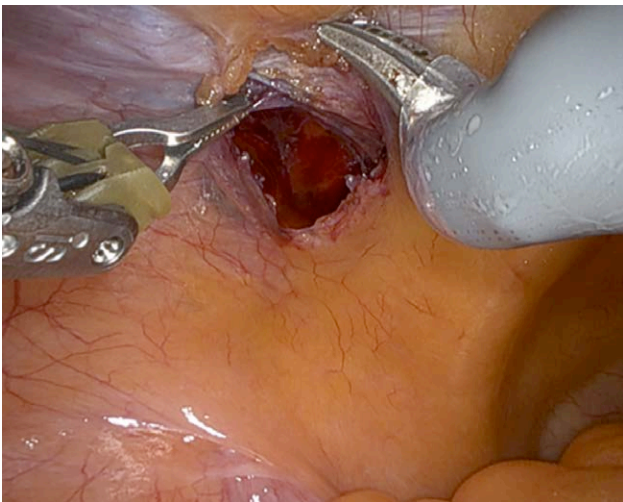
The robotic DIEP flap was pioneered and championed by Dr. Jesse Selber.<sup>1,2</sup> Due to the vast benefits of performing DIEP flap breast reconstruction robotically, plastic



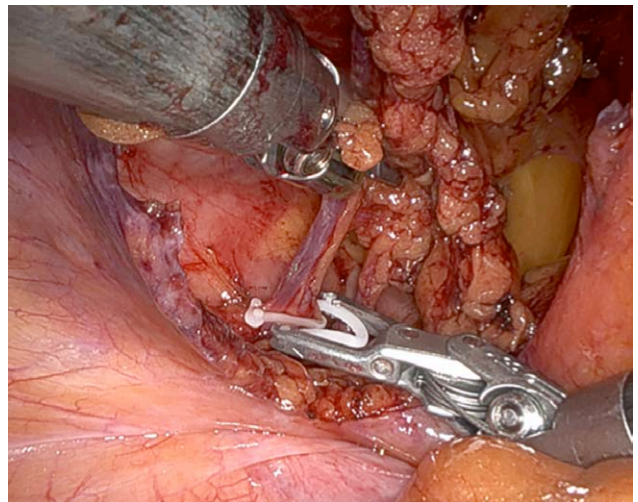
**Fig. 7.** A red vessel loop is placed circumferentially around the pedicle and passed through to the most proximal portion of the visualized pedicle.



**Fig. 9.** The red vessel loop is retrieved intraabdominally. It is used to facilitate dissection around the pedicle without directly manipulating it.



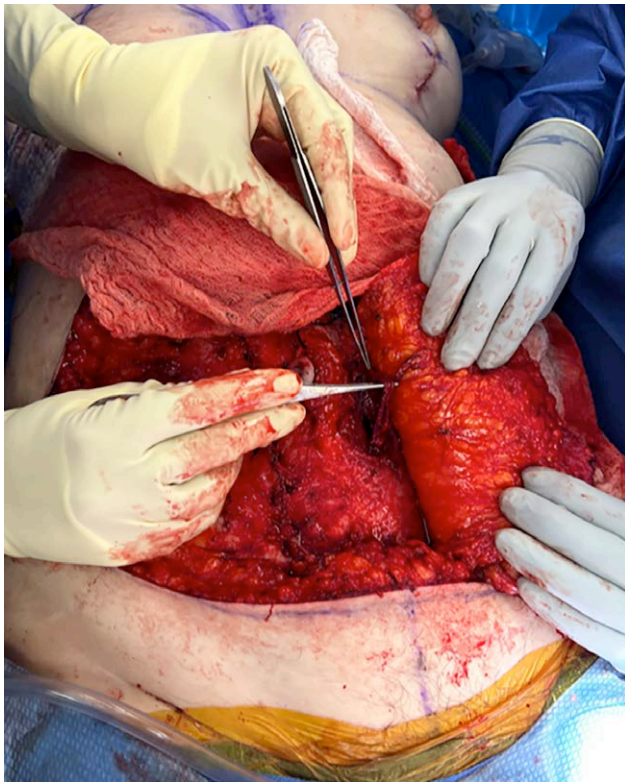
**Fig. 8.** After docking the robot and going intraabdominal, the peritoneum is opened to expose the vessels.



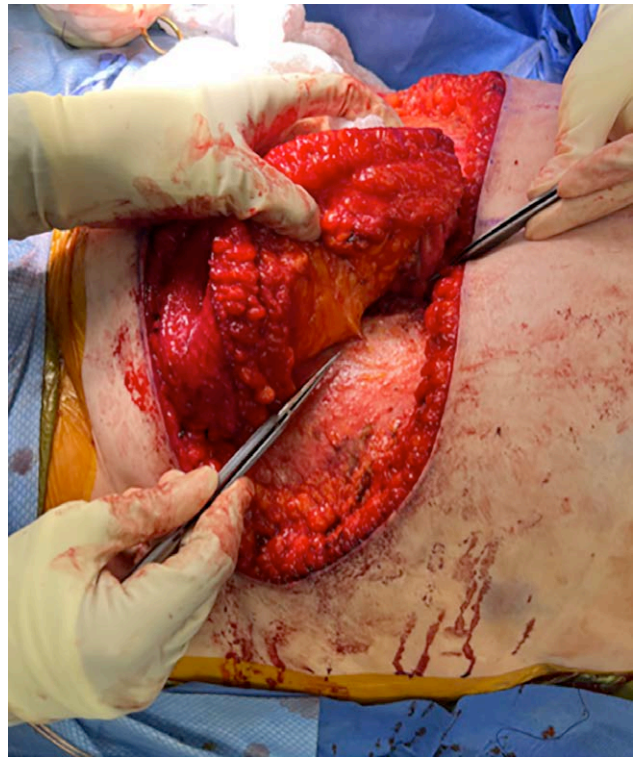
**Fig. 10.** A medium-large Weck Hem-o-lok clip applier is used to ligate the vessels.

surgeons have begun to incorporate this technique into their practice. Selber and colleagues published a case series of 21 patients, whereby the mean fascial incision and pedicle length were  $3.6 \pm 1.6$  cm and  $13.3 \pm 1$  cm, respectively.<sup>2</sup> The mean console time was  $44.8 \pm 9.3$  minutes.<sup>2</sup> There were no bulges or hernias.<sup>2</sup> Daar et al described a series of four patients undergoing robotic-assisted DIEP

flaps and demonstrated that there were no flap losses and no abdominal site morbidity following the breast reconstructions.<sup>19</sup> Additionally, Wittesaele et al. performed a retrospective review of all robotic DIEP flap reconstructions at their institution and demonstrated that although the learning curve was steep, there were no intraabdominal complications or flap failures in 10 robotic DIEP flap procedures.<sup>20</sup> In a retrospective matched study, Lee et al found a significantly reduced intensity of postoperative pain after robotic DIEP flap procedures compared with traditional DIEP flap procedures, as well as reduced use of fentanyl and length of hospital stay postoperatively in the robotic DIEP flap group.<sup>21</sup> These studies demonstrate the potential for robotic DIEP flaps to offer improved outcomes and simplified postoperative care, providing fuel for the technique to continue to gain further popularity



**Fig. 11.** After vessel ligation, but before peritoneal closure, the vascular pedicle is removed from the anterior open approach.



**Fig. 12.** An additional perforator is kept in situ based off the opposite row to perfuse the flap in bilateral cases.

in the field of plastic surgery as more surgeons become familiarized with the technique.

Unfortunately, not all patients are candidates for robotic DIEP flap breast reconstruction. If a woman has received extensive prior abdominal surgery, it is unlikely that she will be able to undergo a robotic DIEP procedure due to scarring near the pedicle. It is also necessary for patients to have the appropriate vascular anatomy, which is confirmed via preoperative imaging with either magnetic resonance angiogram or computed tomography angiogram.<sup>18</sup> The optimal candidate will have a dominant perforator, or closely grouped perforators, with a short intramuscular course.<sup>2,22</sup> In a patient with a perforator that has a long intramuscular course relative to the total pedicle length, or multiple, diffusely placed perforators, the benefits of performing the DIEP flap procedure using a robotic technique would likely be limited. At the time of article preparation, five major US centers and several international centers are performing intraperitoneal robotic DIEPs nationally, including MD Anderson, Northwell Health, University of Pittsburgh, Cleveland Clinic, and Corewell Health

#### Operative Technique

The technique for the robotic DIEP begins in the standard open fashion. The abdominal flaps are raised based on the perforator that has been selected from preoperative imaging (Fig. 5). The vessel is dissected down

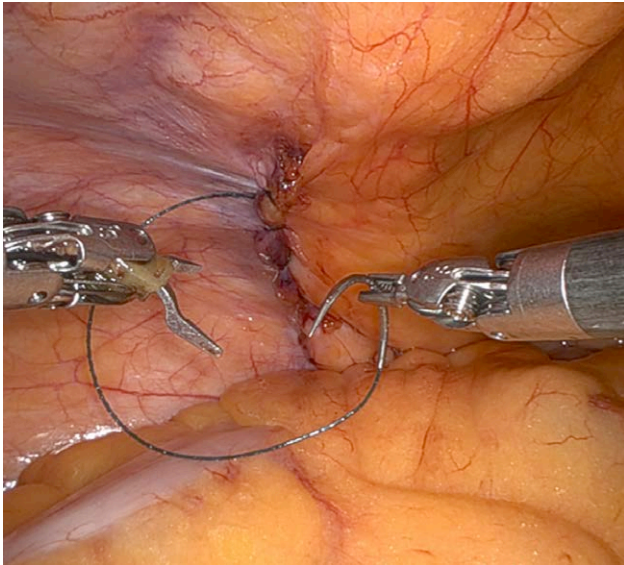
to the posterior surface of the rectus muscle (submuscular plane). With careful selection of preoperative patients with favorable anatomy where the perforator has a short intramuscular course, the fascial incision can be typically limited to 2–3 cm (Fig. 6). A loose vessel loop is placed circumferentially around the pedicle (Fig. 7). This will be retrieved intraabdominally and used during the robotic pedicle dissection.

At this point, access into the intraperitoneal cavity is gained by an open Hassan or Veress needle, depending on surgeon preference. The AirSeal port is inserted, and pneumoperitoneum is established at 15 mm Hg. The camera is placed through this port, and three additional 8-mm robotic ports are placed into the abdomen under direct visualization. Port placement is on the contralateral side of the intended flap harvest, on a line between the anterior axillary line and the anterior superior iliac spine. The middle port is placed between these two. Alternatively, the ports can be placed in similar fashion to robotic transabdominal preperitoneal repair (rTAPP) for inguinal hernia repair. This allows for single docking to harvest both pedicle without undocking the robot.

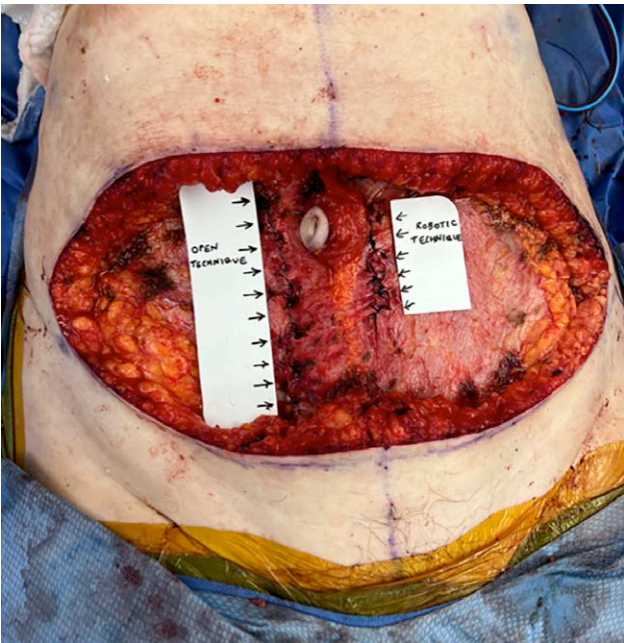
Monopolar scissors and fenestrated bipolar graspers or monopolar scissors and microdissector are used to dissect out the pedicle intraabdominally (see Video 1 [online], which shows intraabdominal dissection done with monopolar scissors and fenestrated bipolar graspers.) First, the origin of the pedicle is identified at the level of the external iliac vessels. The peritoneum is incised, and the vessels are dissected proximally (Fig. 8). To prevent any damage

to the pedicle, the previously placed vessel loop is retrieved and utilized to facilitate the dissection, without injuring the pedicle (Fig. 9). All side branches are either clipped using microclips or bipolar device. (See Video [online].)

Once the pedicle is completely freed, it is clipped and divided distally, then removed through the external fascial opening (Figs. 10 and 11). To prevent the flap from being ischemic (after it is clipped with robotic assistance), a separate perforator is kept in situ to perfuse the flap (Fig. 12). Alternatively, the superior continuation of the



**Fig. 13.** After the vascular pedicle is removed from the anterior approach, the peritoneum is closed with robotic assistance.



**Fig. 14.** Fascial closure of the robotic technique is compared with that of the open traditional technique.

pedicle is preserved. These are later ligated when the flap is ready to be transferred for microsurgery.

The posterior rectus sheath is closed robotically with the use of barbed suture, the robot is undocked, and the fascial incisions from the robotic port sites are closed externally with figure of eight sutures (Fig. 13). Once the flap has been harvested, the remainder of the operation continues as a traditional DIEP flap procedure (Fig. 14).

## ROBOTIC MICROSURGERY AND LYMPHATIC SURGERY

Robotic systems can enhance small vessel microsurgery secondary to robotic-assisted tremor elimination, magnification, and 5:1 motion scaling.<sup>23</sup> Robotic techniques have been used in nerve repair, microneural surgery, specifically in shoulder and brachial plexus surgery, lymphaticovenous bypass for lymphedema surgery, and microsurgical anastomosis in breast reconstruction.<sup>1,2</sup> These supermicrosurgical techniques involve anastomosis of vessels of a caliber less than 1 mm. In addition, robotic assistance in microsurgery brings robotic breast surgery one step closer to a complete robotically assisted oncologic and reconstructive process.

Neil Tanna, MD, MBA

Northwell Health  
Great Neck, NY

E-mail: [neiltanna@gmail.com](mailto:neiltanna@gmail.com)

Instagram: @drneiltanna

Facebook: @drneiltanna

## DISCLOSURE

The authors have no financial interest to declare in relation to the content of this article.

## REFERENCES

1. Ibrahim AE, Sarhane KA, Selber JC. New frontiers in robotic-assisted microsurgical reconstruction. *Clin Plast Surg.* 2017;44:415–423.
2. Bishop SN, Selber JC. Minimally invasive robotic breast reconstruction surgery. *Gland Surg.* 2021;10:469–478.
3. Muaddi H, Hafid ME, Choi WJ, et al. Clinical outcomes of robotic surgery compared to conventional surgical approaches (laparoscopic or open): a systematic overview of reviews. *Ann Surg.* 2021;273:467–473.
4. Lira RB, Kowalski LP. Robotic head and neck surgery: beyond TORS. *Curr Oncol Rep.* 2020;22:88.
5. Mohamed SE, Noureldine SI, Kandil E. Alternate incision-site thyroidectomy. *Curr Opin Oncol.* 2014;26:22–30.
6. Aitzetmüller MM, Klietz ML, Dermietzel AF, et al. Robotic-assisted microsurgery and its future in plastic surgery. *J Clin Med.* 2022;11:3378.
7. Clemens MW, Kronowitz S, Selber JC. Robotic-assisted latissimus dorsi harvest in delayed-immediate breast reconstruction. *Semin Plast Surg.* 2014;28:20–25.
8. Bailey EA, Bishop SN. Minimally invasive surgery in breast reconstruction: the past and future. In: Sözen APS, Emir APS, eds. *Breast Cancer Updates.* Great Neck, NY: IntechOpen; 2023.
9. Selber JC. Robotic nipple-sparing mastectomy: the next step in the evolution of minimally invasive breast surgery. *Ann Surg Oncol.* 2019;26:10–11.
10. Lee J, Park HS, Lee H, et al. Post-operative complications and nipple necrosis rates between conventional and robotic nipple-sparing mastectomy. *Front Oncol.* 2020;10:594388.



11. Toesca A, Peradze N, Manconi A, et al. Robotic nipple-sparing mastectomy for the treatment of breast cancer: feasibility and safety study. *Breast (Edinburgh, Scotland)*. 2017;31:51–56.
12. Filipe MD, de Bock E, Postma EL, et al. Robotic nipple-sparing mastectomy complication rate compared to traditional nipple-sparing mastectomy: a systematic review and meta-analysis. *J Robot Surg*. 2022;16:265–272.
13. Loh ZJ, Wu TY, Cheng FTF. Evaluation of the learning curve in robotic nipple-sparing mastectomy for breast cancer. *Clin Breast Cancer*. 2021;21:e279–e284.
14. Lai HW, Toesca A, Sarfati B, et al. Consensus statement on robotic mastectomy—expert panel from international endoscopic and robotic breast surgery symposium (IERBS) 2019. *Ann Surg*. 2020;271:1005–1012.
15. Chen K, Zhang J, Beeraka NM, et al. Robot-assisted minimally invasive breast surgery: recent evidence with comparative clinical outcomes. *J Clin Med*. 2022;11:1827.
16. Homsy A, Rüegg E, Montandon D, et al. Breast reconstruction: a century of controversies and progress. *Ann Plast Surg*. 2018;80:457–463.
17. Yueh JH, Slavin SA, Adesiyun T, et al. Patient satisfaction in post-mastectomy breast reconstruction: a comparative evaluation of DIEP, TRAM, latissimus flap, and implant techniques. *Plast Reconstr Surg*. 2010;125:1585–1595.
18. Kurlander DE, Le-Petross HT, Shuck JW, et al. Robotic DIEP patient selection: analysis of CT angiography. *Plast Reconstr Surg Glob Open*. 2021;9:e3970.
19. Daar DA, Anzai LM, Vranis NM, et al. Robotic deep inferior epigastric perforator flap harvest in breast reconstruction. *Microsurgery*. 2022;42:319–325.
20. Wittesaele W, Vandervoort M. Implementing the robotic deep inferior epigastric perforator flap in daily practice: a series of 10 cases. *J Plast Reconstr Aesthet Surg*. 2022;75:2577–2583.
21. Lee MJ, Won J, Song SY, et al. Clinical outcomes following robotic versus conventional DIEP flap in breast reconstruction: a retrospective matched study. *Front Oncol*. 2022;12:989231.
22. Selber JC. The Robotic DIEP Flap. *Plast Reconstr Surg*. 2020;145:340–343.
23. Katz RD, Taylor JA, Rosson GD, et al. Robotics in plastic and reconstructive surgery: use of a telemanipulator slave robot to perform microvascular anastomoses. *J Reconstr Microsurg*. 2006;22:53–57.