



Extra-Axial Cystic Meningioma without Dural Attachment in an Adult: Case Report and Review of Literature

Batuk Diyora¹ Sanjay Kukreja¹ Gagan Dhal¹ Kavin Devani¹ Mehool Patel¹ Ravi Wankhede¹

¹Department of Neurosurgery, Lokmanya Tilak Municipal General Hospital, Sion, Mumbai, Maharashtra, India

Address for correspondence Batuk Diyora, DNB, Department of Neurosurgery, Lokmanya Tilak Municipal General Hospital, Second floor, College Building, Sion, Mumbai 400022, Maharashtra, India (e-mail: bddiyora@gmail.com; batuk73@yahoo.co.in).

AJNS 2022;17:173–177.

Abstract

Intraparenchymal meningiomas, meningiomas without dural attachment, and cystic meningioma are atypical and extremely rare, especially in adults. Only four cases of intraparenchymal cystic meningioma without dural attachment have been reported. A 47-year-old female presented with an altered sensorium. She had a progressive bifrontal headache for 2 months. Computed tomography scan of the brain showed an 8 cm × 6 cm cystic lesion with a solid component in the left frontoparietal region with a midline shift. The solid part of the lesion was enhancing on contrast but the cyst rim was not. Intraoperatively, the cyst was filled with amber-colored fluid, which was drained, and the solid component was completely excised. Histopathological examination of the solid tumor component confirmed cystic meningioma. At 2 years of follow-up, she has no evidence of recurrence. We report the fifth case of this very rare entity and review the literature.

Keywords

- ▶ cyst
- ▶ tumor
- ▶ meningioma
- ▶ intraparenchymal
- ▶ deep sylvian fissure
- ▶ dural attachment

Introduction

Meningiomas are commonly derived from dural-based arachnoid cells and hence are usually attached to the dura.¹ Rarely, meningiomas may present without any dural attachment.^{2,3} Meningiomas without dural attachment most commonly occur in the ventricles and rarely from the parenchyma.^{4,5} Intraparenchymal meningiomas are extremely rare in “meningiomas without dural attachment” as classified by Cushing and Eisenhardt.⁶ They are usually solid tumors.⁷ Cystic meningiomas are rare tumors accounting for 1.7 to 7% of meningiomas.^{8,9} Children have higher incidences of cystic meningiomas, intraparenchymal meningiomas, and meningiomas without dural attachment.¹⁰ Cystic meningioma without dural attachment in an adult is very

rare. We report the case of this very rare entity and review the literature.

Materials and Methods

A 47-year-old female presented with an altered sensorium. She had a history of progressive bifrontal headache for 2 months. On general examination, her vital signs were within normal limits. On neurological examination, she was confused, not following verbal commands, and was partially opening her eyes on painful stimuli. Her pupils were 3 mm in size bilaterally and normally reacted to light. Planters were extensor on both sides. Fundoscopy revealed papilledema. Computed tomography (CT) scan of the brain showed an 8 cm × 6 cm cystic lesion in the left frontoparietal

DOI <https://doi.org/10.1055/s-0042-1751010>.
ISSN 2248-9614.

© 2022. Asian Congress of Neurological Surgeons. All rights reserved.

This is an open access article published by Thieme under the terms of the Creative Commons Attribution-NonDerivative-NonCommercial-License, permitting copying and reproduction so long as the original work is given appropriate credit. Contents may not be used for commercial purposes, or adapted, remixed, transformed or built upon. (<https://creativecommons.org/licenses/by-nc-nd/4.0/>)

Thieme Medical and Scientific Publishers Pvt. Ltd., A-12, 2nd Floor, Sector 2, Noida-201301 UP, India

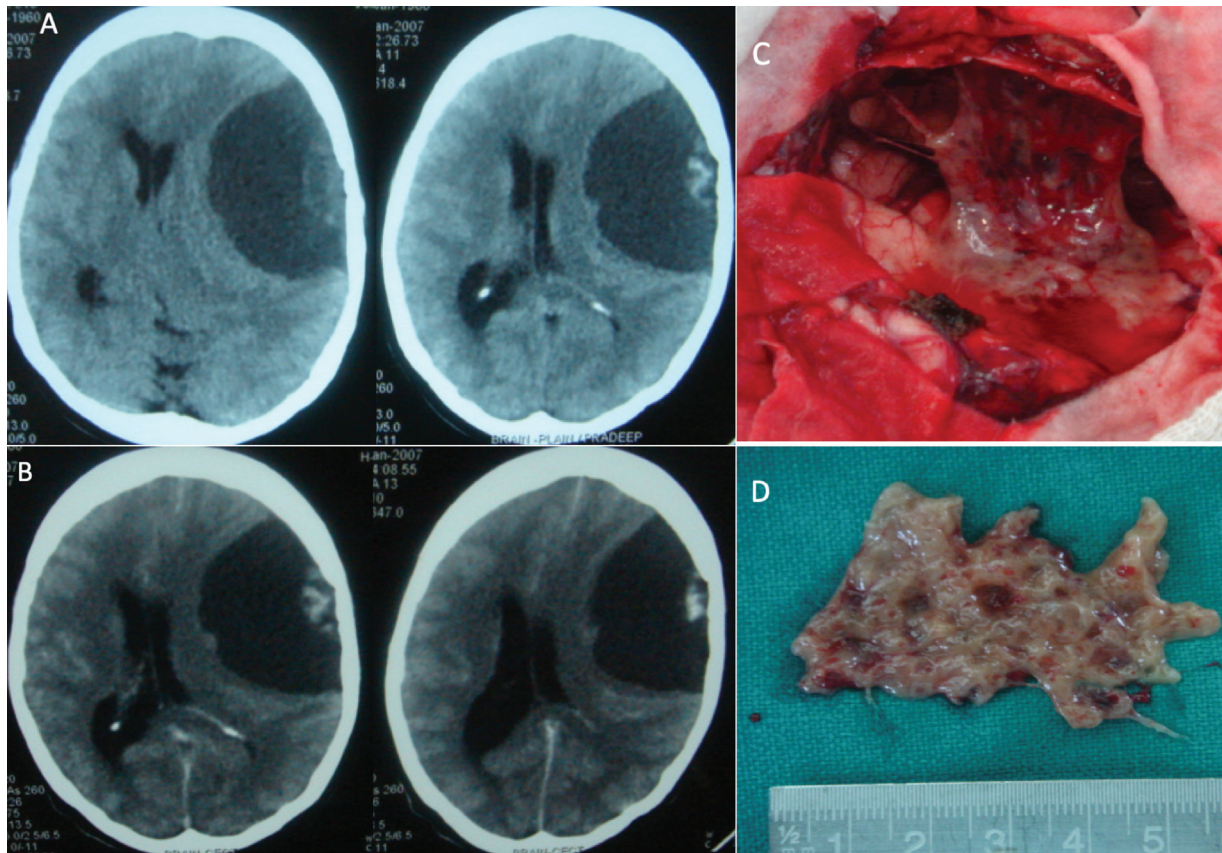


Fig. 1 Computed tomography scan of the brain showing an 8 cm × 6 cm size cystic lesion in the left frontoparietal region with a solid and cystic component (A). The solid component of the lesion was enhancing on contrast, but the cystic was not (B). The ipsilateral frontal horn was significantly compressed with a midline shift of 1.5 cm. Intraoperative photomicrograph showing an extra-axial solid component lying over the brain parenchyma following cyst decompression and was weakly adherent to the arachnoid trabeculae without dural attachment (C). It was brownish-yellow, soft, fleshy, minimally vascular solid mass (D).

region with a solid component (► **Fig. 1A**). The solid part of the lesion was enhancing on contrast but the cyst rim was not enhancing (► **Fig. 1B**). The ipsilateral frontal horn was significantly compressed with a midline shift of 1.5 cm. She underwent excision of the lesion under general anesthesia. Left frontoparietal craniotomy was performed and the bone flap was raised. The bone and dura were found to be normal. On incising the dura, a gush of amber-colored fluid drained out. The further dural opening revealed that the solid component was lying over the cerebral parenchyma. There was no evidence of dural attachment (► **Fig. 1C**). The lesion was completely extra-axial. There was no clear cyst wall. At a few places, the solid component was weakly adherent to the arachnoid trabeculae but there was no adhesion between the tumor and the brain parenchyma (► **Fig. 1C**). A brownish yellow, soft, fleshy, minimally vascular solid mass was removed (► **Fig. 1D**). A water-tight dural closure was performed and the wound was closed in layers.

Histopathological examination of the solid tumor component showed nests of monotonous cells separated by loose fibrovascular tissue. The tumor cells showed dispersed chromatin and indistinct cytoplasm. Occasional nuclear holes and nucleomegaly were noted along with whorling. The fibrovascular tissue showed capillary proliferation and cystic changes (► **Fig. 2**). Focal calcification was also noted. Nuclear atypia and

mitosis were not seen. Immunohistochemistry revealed diffusing positive for vimentin, and MIB-1 was less than 1%.

Postoperatively, the patient became conscious and made a slow and progressive recovery in the first 72 hours. On the

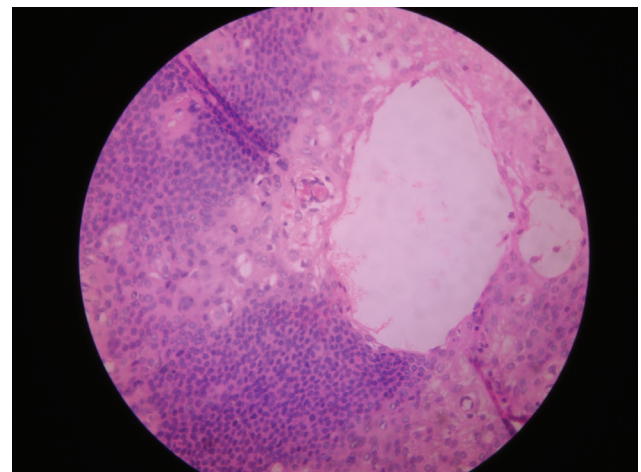


Fig. 2 Histopathological photomicrograph (hematoxylin and eosin stain) showing nests of monotonous cells separated by loose fibrovascular tissue. The tumor cells showed dispersed chromatin and indistinct cytoplasm. These features are suggestive of cystic meningioma.

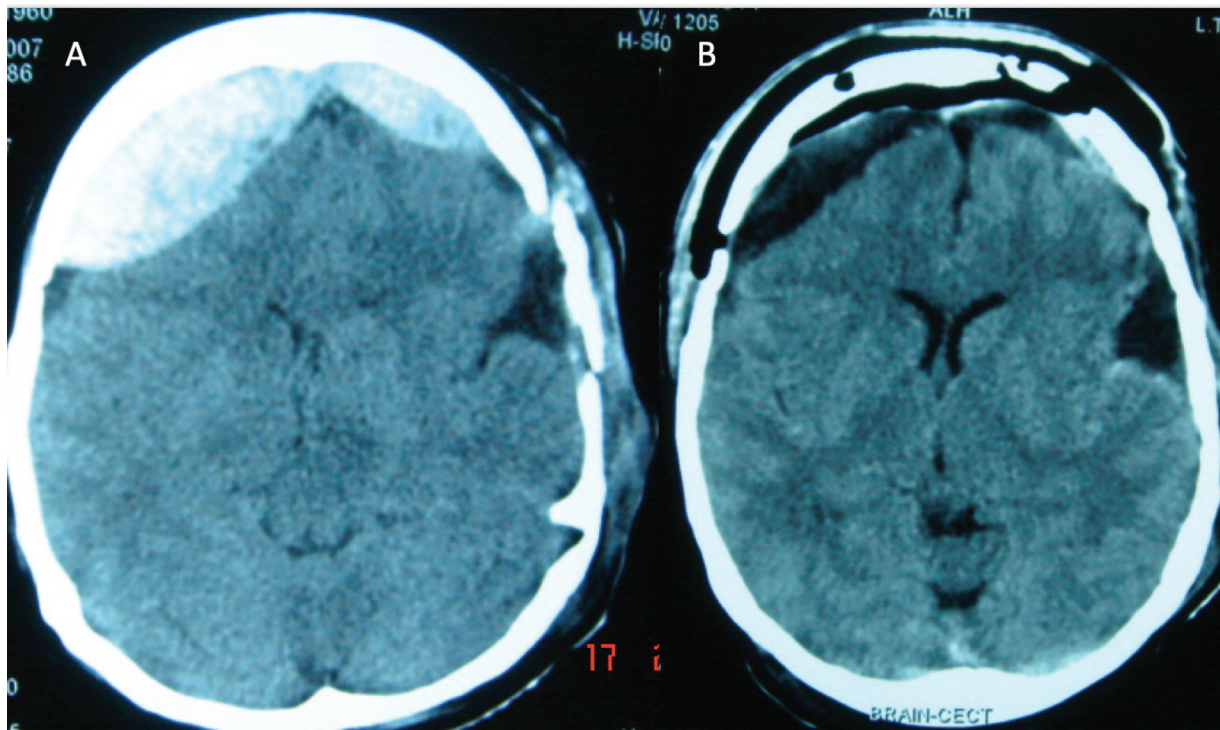


Fig. 3 Postoperative computed tomography (CT) scan of the brain showing bifrontal extradural hematoma (A). CT scan of the brain after the evacuation of the bifrontal hematoma showing no evidence of lesion with reversal of midline shift (B).

fourth postoperative day, she again became unconscious. An urgent CT scan brain was performed that revealed bilateral extradural hematomas (► **Fig. 3A**). Bifrontal craniotomy was performed and extradural hematomas removed. Postoperative CT scan after evacuation of clot revealed no evidence of lesion with reversal of midline shift (► **Fig. 3B**). She made a significant clinical recovery without any neurological deficit. At 2 years of follow-up, she has no clinical signs of recurrence.

Discussion

Meningiomas without dural attachment can be classified into five types: intraventricular meningioma, pineal region meningioma, deep sylvian fissure meningioma, intraparenchymal or subcortical meningioma, and others.¹¹ They probably originate from ectopic meningeothelial cells, which are not directly adjacent to the dura mater.¹² They are more common in males. Meningiomas without dural attachment most commonly occur in the ventricles. However, they may also occur in the sylvian fissure, pineal region, and even in the brain parenchyma.^{11,13–15} Intraparenchymal meningiomas are rare intracranial tumors and only 27 cases of intraparenchymal meningiomas have been reported.^{4,5} They arise from the arachnoid cells of the pia mater, which are supplied by the perforating blood vessels on entry to the brain sulci.¹⁶ Intraparenchymal meningiomas are most commonly present with seizures. The most common location is the frontal lobe. Fibroblastic meningioma is the most common histologic subtype of intraparenchymal meningiomas. Most of the intraparenchymal meningiomas are World Health Organiza-

tion grade I meningioma.^{9,17} Intraparenchymal meningioma with no connection to the dura is very rare in adults.^{4,7}

Cystic meningiomas are rare tumors accounting for 1.7 to 7% of meningiomas.⁸ The cysts in meningioma may be intra- or extratumoral. Cystic meningiomas are commonly located at the cerebral convexity and usually are of fibrous histology.⁷ Cysts most widely develop in fibroblastic and meningeothelial meningiomas.⁵ Cystic meningiomas are classified into four types—(1) centrally located intratumoral cyst, (2) peripherally located intratumoral cyst, (3) peritumoral cyst with walls consisting of both adjacent parenchyma and the tumor, and (4) peritumoral cyst with walls formed by the arachnoid, while the cyst remains separated from the tumor by a distinct capsule.¹⁸ Various theories have been proposed for cyst formation in a meningioma. Intratumoral cysts may be the outcome of microcystic degeneration, ischemic necrosis, intratumoral hemorrhage, or intratumoral metastasis, and peritumoral cysts originate from peritumoral edema, widening of the subarachnoid space, demyelination, or peritumoral hemorrhage.^{9,19}

The frequency of atypical meningioma among cystic meningioma is 12%, higher than that among all meningiomas, and suggests that atypical meningioma tends to form a cyst compared with other subtypes.²⁰ Review of the histological classification of 69 cystic meningiomas showed meningeotheliomatous (42.0%) and fibroblastic (27.5%) lesions were the most common types. Lesions were malignant in 7.2% of cases.²¹ Kolluri et al suggested that sarcomatous and angioblastic meningiomas are more frequently associated with cyst formation.²²

Meningioma may be extremely difficult to distinguish at the preoperative diagnosis from glioma, metastatic brain

tumor, lymphoma, subdural sarcoid mass, or other intra-axial lesions, especially if located far from the para- or intraventricular regions or the sylvian fissure.²³ Cystic meningioma is difficult to distinguish from a glioma with cystic changes or a metastatic neoplasm. One should consider intraparenchymal meningioma in the differential diagnosis of an intra-axial lesion in a child. The presence of cyst formation and heterogeneous enhancement mimic other neoplasms, such as gliomas, hemangioblastomas, and metastatic tumors.

CT and magnetic resonance imaging (MRI) are characteristics of typical meningioma and include a well-circumscribed, homogeneously enhancing extra-axial mass. The presence of an associated cyst and peritumoral edema is uncommon imaging feature that may make it difficult to distinguish the tumor from a primary intra-axial glial neoplasm.²⁴ In intraparenchymal meningioma, CT and MRI demonstrate no typical features, so preoperative diagnosis is difficult. Enhancement of the cyst wall strongly suggests the presence of tumor cells, but the absence of enhancement of the cyst wall does not exclude the presence of tumor cells in the cyst wall. Enhancement on CT or MRI indicates the presence of tumor cells in the cyst wall, and the enhancement depends on the presence and number of tumor cells.²⁵

For meningiomas, the primary treatment is surgery.²⁶ Complete tumor resection is the most important factor in the prevention of tumor recurrence.²⁷ Resection of the entire cyst wall is optimum, even if neuroimaging does not show enhancement of the cyst wall. However, the cyst wall often adheres tightly to the surrounding brain tissue and may be difficult to remove without damaging the adjacent brain tissue.^{28,29} After total resection of tumor and cyst wall, the cure rate is not significantly different between cystic and solid meningioma.³⁰ Radiation therapy is beneficial in the treatment of residual meningiomas,³¹ or meningiomas of the skull base.³² Radiotherapy for atypical or malignant meningioma is recommended immediately after the initial surgery.³³ The recurrence of a meningioma depends on the extent of removal, location of the tumor, and histological subtype.¹⁴ The extent of resection seems to be the most critical factor influencing the prognosis of a meningioma.

Funding

None.

Conflict of Interest

None declared.

References

- Graziani N, Donnet A, Vincentelli F, Dechambenoit G, Grisoli F. [Deep sylvian meningioma. Apropos of a case. Review of the literature]. *Neurochirurgie* 1992;38(03):179-182
- Zhao SL, Li Y, Tian XY, Li Z, Huang Q, Li B. Intraparenchymal cystic chordoid meningioma: a case report and review of the literature. *Neuropathology* 2011;31(06):648-653
- Cecchi PC, Campello M, Rizzo P, Mair K, Schwarz A. Atypical meningioma of the sylvian fissure. *J Clin Neurosci* 2009;16(09):1234-1239
- Shimbo D, Kato T, Takeda M, Ikeda H. Intraparenchymal meningioma in a child. *Neurol Med Chir (Tokyo)* 2011;51(11):793-797
- Jiang XB, Ke C, Han ZA, et al. Intraparenchymal papillary meningioma of brainstem: case report and literature review. *World J Surg Oncol* 2012;10:10
- Cushing H, Eisenhardt L. *Meningiomas Without Dural Attachment*. Springfield, Illinois: Charles C Thomas; 1938:133-168
- Shimizu K, Furuhashi S, Sasai S, Tominaga S, Takamiya Y. Intracerebral cystic meningioma—case report. *Neurol Med Chir (Tokyo)* 1999;39(07):530-533
- Sridhar K, Ravi R, Ramamurthi B, Vasudevan MC. Cystic meningiomas. *Surg Neurol* 1995;43(03):235-239
- Odake G. Cystic meningioma: report of three patients. *Neurosurgery* 1992;30(06):935-940
- Germano IM, Edwards MS, Davis RL, Schiffer D. Intracranial meningiomas of the first two decades of life. *J Neurosurg* 1994;80(03):447-453
- Zhang J, Chi LY, Meng B, Li F, Zhu SG. Meningioma without dural attachment: case report, classification, and review of the literature. *Surg Neurol* 2007;67(05):535-539
- Chang JH, Kim JA, Chang JW, Park YG, Kim TS. Sylvian meningioma without dural attachment in an adult. *J Neurooncol* 2005;74(01):43-45
- Crouse SK, Berg BO. Intracranial meningiomas in childhood and adolescence. *Neurology* 1972;22(02):135-141
- Drake JM, Hendrick EB, Becker LE, Chuang SH, Hoffman HJ, Humphreys RP. Intracranial meningiomas in children. *Pediatr Neurosci* 1985-1986;12(03):134-139
- Merten DF, Gooding CA, Newton TH, Malamud N. Meningiomas of childhood and adolescence. *J Pediatr* 1974;84(05):696-700
- Wada T, Suzuki M, Beppu T, et al. A case of subcortical meningioma. *Acta Neurochir (Wien)* 2000;142(02):209-213
- Mori Y, Shibuya M, Sugita K, Nagasaka T. [Deep sylvian meningioma: a case report of a child]. *No Shinkei Geka* 1994;22(12):1147-1151
- Nauta HJ, Tucker WS, Horsey WJ, Bilbao JM, Gonsalves C. Xanthochromic cysts associated with meningioma. *J Neurol Neurosurg Psychiatry* 1979;42(06):529-535
- Dell S, Ganti SR, Steinberger A, McMurtry J III. Cystic meningiomas: a clinicoradiological study. *J Neurosurg* 1982;57(01):8-13
- Senboku N, Asahara T, Uchida M, Yagishita T, Naganuma H. Atypical meningioma with large cyst. Case report. *Neurol Med Chir (Tokyo)* 2006;46(03):147-151
- Takara K, Cho K, Mori K, Maeda M. Intraventricular, cystic, atypical meningioma. *Neurol Med Chir (Tokyo)* 1997;37(11):856-860
- Kolluri VRS, Reddy DR, Reddy PK, Naidu MR, Devi S. CT-findings in cystic meningiomas. *Acta Neurochir (Wien)* 1987;87(1-2):31-33
- Lanotte M, Perez R, Boccaletti R, Castellano I, Cassoni P, Ducati A. Atypical growth pattern of a meningioma in an adult. *Neurol Med Chir (Tokyo)* 2007;47(08):360-363
- Mittal A, Layton KF, Finn SS, Snipes GJ, Opatowsky MJ. Cystic meningioma: unusual imaging appearance of a common intracranial tumor. *Proc Bayl Univ Med Cent* 2010;23(04):429-431
- Ueno Y, Tanaka A, Nakayama Y, Nomoto Y. Intracerebral cyst associated with meningioma. *Clin Neurol Neurosurg* 1999;101(04):271-274
- Lund-Johansen M, Scheie D, Muller T, Lundar T, Helseth E. Neurosurgical treatment of meningiomas in children and young adults. *Childs Nerv Syst* 2001;17(12):719-723
- Im SH, Wang KC, Kim SK, et al. Childhood meningioma: unusual location, atypical radiological findings, and favorable treatment outcome. *Childs Nerv Syst* 2001;17(11):656-662
- Zee CS, Chen T, Hinton DR, Tan M, Segall HD, Apuzzo ML. Magnetic resonance imaging of cystic meningiomas and its surgical implications. *Neurosurgery* 1995;36(03):482-488

- 29 Carvalho GA, Vorkapic P, Biewener G, Samii M. Cystic meningiomas resembling glial tumors. *Surg Neurol* 1997;47(03):284–289, discussion 289–290
- 30 Wan X, Jiang B, Ma Z, Wang J, Hou Y, Liu Y. [Diagnosis and treatment of cystic meningioma]. *Zhong Nan Da Xue Xue Bao Yi Xue Ban* 2010;35(09):1009–1012
- 31 Goldsmith BJ, Wara WM, Wilson CB, Larson DA. Postoperative irradiation for subtotally resected meningiomas. A retrospective analysis of 140 patients treated from 1967 to 1990. *J Neurosurg* 1994;80(02):195–201
- 32 Nutting C, Brada M, Brazil L, et al. Radiotherapy in the treatment of benign meningioma of the skull base. *J Neurosurg* 1999;90(05):823–827
- 33 Milosevic MF, Frost PJ, Laperriere NJ, Wong CS, Simpson WJ. Radiotherapy for atypical or malignant intracranial meningioma. *Int J Radiat Oncol Biol Phys* 1996;34(04):817–822