

Frontal Sinus Fractures: Evidence and Clinical Reflections

Christopher D. Lopez, MD*
 Ricardo Rodriguez Colon, BS†
 Joseph Lopez, MD, MBA*
 Paul N. Manson, MD*
 Eduardo D. Rodriguez, MD, DDS†

Background: Despite significant advances in the management of frontal sinus fractures, there is still a paucity of large-cohort data, and a comprehensive synthesis of the current literature is warranted. The purpose of this study was to present an evidence-based overview of frontal sinus fracture management and outcomes.

Methods: A comprehensive literature search of PubMed and MEDLINE was conducted for studies published between 1992 and 2020 investigating frontal sinus fractures. Data on fracture type, intervention, and outcome measurements were reported.

Results: In total, 456 articles were identified, of which 53 met our criteria and were included in our analysis. No statistically significant difference in mechanism of injury, fracture pattern, form of management, or total complication rate was identified. We found a statistically significant increase in complication rates in patients with nasofrontal outflow tract injury compared with those without.

Conclusions: Frontal sinus fracture management is a challenging clinical situation, with no widely accepted algorithm to guide appropriate management. Thorough clinical assessment of the fracture pattern and associated injuries can facilitate clinical decision-making. (*Plast Reconstr Surg Glob Open* 2022;10:e4266; doi: 10.1097/GOX.0000000000004266; Published online 18 April 2022.)

INTRODUCTION

Frontal sinus fractures constitute 5%–15% of all craniofacial fractures.^{1–4} Landmark advances in management include division of fracture subtypes based on anatomic components (eg, anterior versus posterior wall), establishing the importance of fracture displacement, nasofrontal outflow tract (NFOT) involvement, presence of cerebrospinal fluid (CSF) leak, and computed tomography (CT) imaging for management.^{5,6} Indeed, statistically powered data have established that the degree of NFOT injury is critical for predicting frontal sinus fracture complications.⁷ Injury severity has dramatically lessened since the advent and adoption of vehicular safety belts and airbags.⁸ Consequently, a contemporary shift in paradigm secondary to less-severe injury patterns has resulted in the adoption of conservative approaches that preserve

the sinus, such as nonsurgical management of posterior table fractures and endoscopic repair of NFOT and/or posterior table fractures.^{9–13} Although valuable, the utility of these reports are unclear, given that the majority of these reports are underpowered, heterogeneous, and often contradictory.

Large-cohort studies have helped define the relationship between the extent of NFOT injury and fracture patterns, in addition to their effects on complication rates.⁷ Statistically significant data support an evidence-based treatment algorithm for management of frontal sinus fracture. Obstruction is the most clinically significant radiographic finding of NFOT injury; the majority of patients with NFOT injury who developed complications had evidence of obstruction at the time of presentation.^{6,8} When obstruction was present with an additional radiographic finding indicative of NFOT injury, either anterior ethmoid cell fracture and/or frontal sinus floor fracture, rates of complications after observation, and reconstruction management in these patients was 100%.⁷ These findings collectively suggest that management of NFOT with evidence of obstruction, and in particular with additional radiographic evidence of NFOT injury, should focus on obliteration and cranialization. Observation, however, can be done safely in the absence of NFOT obstruction. Since this large-cohort study in 2008, there have been few additional studies of similar scale, limiting innovation on evidence-based management guidelines.

From the *Department of Plastic and Reconstructive Surgery, The Johns Hopkins University School of Medicine, Baltimore, Md.; †Hansjörg Wyss Department of Plastic Surgery, New York University Langone Health, New York, NY.

Received for publication January 9, 2022; accepted February 22, 2022.

Copyright © 2022 The Authors. Published by Wolters Kluwer Health, Inc. on behalf of The American Society of Plastic Surgeons. This is an open-access article distributed under the terms of the [Creative Commons Attribution-Non Commercial-No Derivatives License 4.0 \(CCBY-NC-ND\)](#), where it is permissible to download and share the work provided it is properly cited. The work cannot be changed in any way or used commercially without permission from the journal.

DOI: 10.1097/GOX.0000000000004266

Disclosure: The authors have no financial interest to declare in relation to the content of this article.

The paucity of large-cohort data investigating frontal sinus fractures has made it challenging to provide updated, evidence-based management guidelines. Indeed, recent reports favoring endoscopic approaches¹³ have been contested on account of limited cohorts and other factors such as a paucity of severe fracture patterns.¹⁴ To date, the need for large-scale data remains unaddressed. The largest retrospective cohort is from 2008 and includes more than 850 patients,⁷ while the next-largest report, from 2000, is less than a third of that size. Very few studies, the most recent of which is from 2013, have included more than 100 patients.^{3,15–19} A comprehensive synthesis of the data currently available has yet to be presented. To aid surgical decision-making, this article presents a systematic, evidence-based review of all frontal sinus fracture reports in the literature and offers perspectives based on both data and extensive experience from the senior authors, in addressing this unique clinical challenge.

METHODS

Literature Search

A comprehensive search in accordance with the Preferred Reporting Items for Systematic Reviews and Meta-Analyses guidelines was performed, querying two databases (PubMed and Medline) through 2020. The following search terms “frontal sinus” AND “fracture” OR “trauma” OR “injury” OR “involvement” were utilized, and additional articles were extrapolated from identified articles.

Selection Criteria

Two independent reviewers (CDL, RRC) analyzed all queried results for relevancy. Any conflicts between the two reviewers were discussed and a consensus was agreed upon. Articles reporting on data regarding frontal sinus fracture injuries, management, and outcomes were included. We excluded studies that lacked relevant information on mechanism of injury (MOI), fracture pattern, and management, along with non-English articles, cadaveric studies, case reports, technical papers, and abstracts/conference proceedings.

Data Extraction and Analysis

Included articles were examined, and data on MOI, fracture pattern, fracture management, NFOT involvement, CNS injury, and complications were recorded. Additional patient information was collected, including patient sample size, demographics, and follow-up length. Lastly, author and year of publication were documented. Studies that included the same subset of patients as a larger study by the same group were counted only once with the larger study included, so as to not double count patients and subsequently bias the data. We used a two-sided unpaired student *t*-test to assess for difference in means of continuous variables, and the Pearson chi-square test to assess for difference in proportions between categorical variables. All statistical analyses were performed using IBM SPSS (version 26), and statistical significance was reported as a *P* value less than 0.05.

Takeaways

Question: Despite significant advances in the management of frontal sinus fractures a paucity of large-cohort data remains. The purpose of our study was to present an evidence-based overview of frontal sinus fracture management and outcomes.

Findings: Over the past 25 years, there have been no significant changes in the fracture patterns, mechanisms of injury, treatment, or overall complications of frontal sinus injuries. However, more complications were seen in patients with nasofrontal outflow tract injury, highlighting the importance of this anatomic area.

Meaning: Frontal sinus fracture management is a challenging clinical situation that should be guided by thorough assessment of the fracture pattern and associated fractures.

RESULTS

Description of Studies

Our initial database search based on our search parameters yielded 449 articles, but only 53 met inclusion criteria and were included in our study (Fig. 1). We organized included articles into 5-year increments for analysis. One article was from 1991 to 1995, four from 1996 to 2000, six from 2001 to 2005, 11 from 2006 to 2010, 20 from 2011 to 2015, and 11 from 2016 to 2020. The majority of patients included in these articles were men in their early 30s (Table 1). The majority of articles were classified as below level II quality of evidence, based on Oxford’s Level of Evidence, and included retrospective reviews, systematic reviews, and case reports. A risk of bias assessment was performed using the National Institute of Health Quality Assessment Tool for Case Series Studies; all studies were deemed to be of acceptable quality.

Mechanism of Injury

The most common MOIs were passengers in motor vehicle accidents (MVA) and blunt trauma (assault and falls), with each reported in 47 articles (88.7%). We identified a trend toward a decrease in the average number of frontal sinus fractures due to MVA, from 53.6% (218/407) in 1996–2000 to 33.3% (209/627) in 2016–2020, along with an increase in blunt trauma, from 28.8% (117/407) in 1996–2000 to 42.1% (264/627) in 2016–2020 (Table 2). This difference was not statistically significant (MVA *P* = 0.942, blunt trauma *P* = 0.815).

Fracture Pattern

Nondisplaced anterior table fractures (29.6%) were the most frequently reported fracture type, followed by nondisplaced anterior table and posterior table (AT/PT) fractures (25.6%), and displaced AT/PT fractures (24.5%) (Table 3). We found a statistically significant change in displaced posterior table fractures over the study period

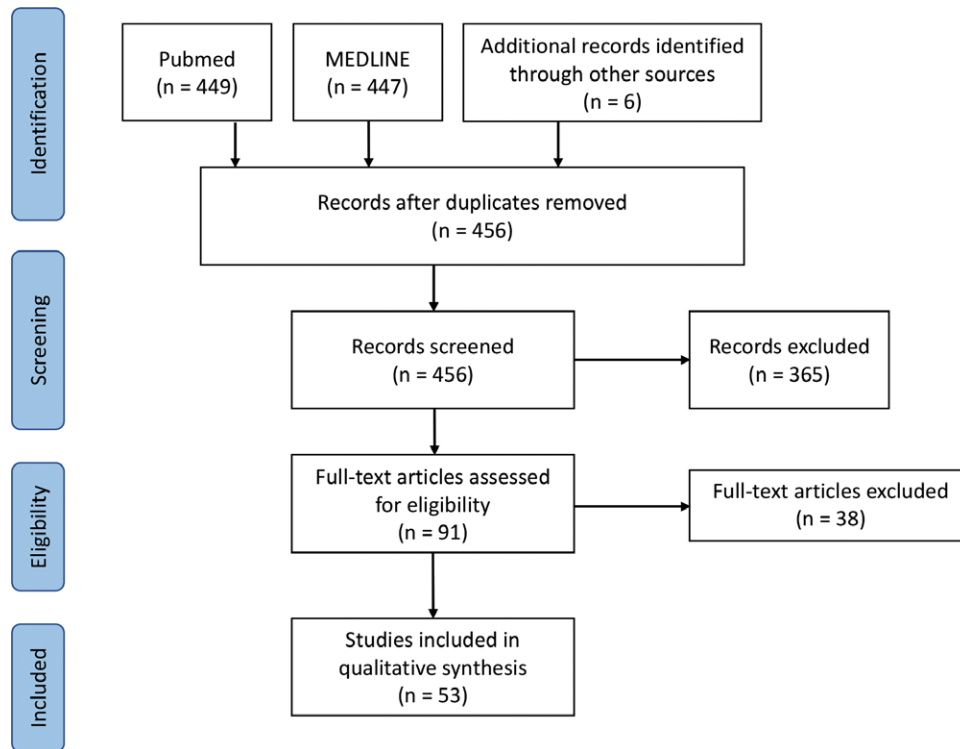


Fig. 1. Preferred Reporting Items for Systematic Reviews and Meta-Analyses flow chart of included studies.

Table 1. Demographics of Included Studies

Year Range	No. Studies	Age (mean ± SD)	Total No. Presented	Time to Follow-up (mo)	No. Men	% Men	No. Women	% Women
92–95	1	29.6	5	9	3	60	2	40
96–00	4	32.3 ± 4.8	101.7 ± 61.9	55.7 ± 32.7	88.8 ± 55.2	87.4 ± 6.4	13.0 ± 8.0	12.6 ± 6.4
01–05	6	32.5 ± 5.3	17.3 ± 13.1	20.4 ± 14.7	15.0 ± 10.6	88.8 ± 7.2	2.3 ± 2.9	11.1 ± 7.2
06–10*	11	33.2 ± 6.2	127.7 ± 245.8	12.2 ± 5.6	47.7 ± 39.3	90.1 ± 6.9	7.1 ± 7.1	9.9 ± 6.9
11–15*	20	34.3 ± 3.3	44.7 ± 64.9	18.0 ± 18.8	42.2 ± 58.2	87.0 ± 12.9	6.5 ± 9.7	13.0 ± 12.9
16–20*	11	33.0 ± 4.5	57.0 ± 81.3	20.8 ± 14.0	53.7 ± 76.1	87.5 ± 16.2	8.0 ± 9.1	15.0 ± 10.8

*Articles in which gender was not identified.

($P = 0.041$); all other fracture patterns demonstrated no statistically significant difference in prevalence.

Interventions

We found nonoperative management to be the most common form of management (32.9%), followed by reconstruction (27.8%), obliteration of the frontal sinus (18.8%), and cranialization (17.2%) (Table 4). There was no statistically significant difference in the frequency of management type used from 1995 to 2020.

Complications

The overall complication rate of all studies was 9.3%. When comparing the complication rate between those with NFOT injury with those without, we found a higher complication rate associated with NFOT involvement ($P < 0.001$) (Fig. 2). However, we found no difference in complication rate across the forms of management in patients with NFOT injury (all P values > 0.05). There was an increase in complications with longer clinical follow-up (Fig. 3).

Table 2. Mechanisms of Injury per 5-Year Increments

Years	Total No. Patients	MOI MVA Passenger	MOI MVA Pedestrian	MOI Motorcycle	MOI Blunt Trauma	MOI Gunshot	MOI Other	MOI Unknown
92–95	5	0 (0.0%)	0 (0.0%)	0 (0.0%)	0 (0.0%)	0 (0.0%)	2 (40.0%)	3 (60.0%)
96–00	407	218 (53.6%)	0 (0.0%)	1 (0.3%)	117 (28.8%)	27 (6.6%)	44 (10.8%)	0 (0.0%)
01–05	104	44 (42.3%)	2 (1.9%)	6 (5.8%)	31 (29.8%)	1 (1.0%)	14 (13.5%)	6 (5.8%)
06–10	1405	627 (44.6%)	68 (4.8%)	140 (10.0%)	267 (19.0%)	73 (5.2%)	215 (15.3%)	15 (1.1%)
11–15	893	341 (38.2%)	15 (1.7%)	55 (25.6%)	229 (25.6%)	9 (1.0%)	231 (25.9%)	13 (1.5%)
16–20	627	209 (33.3%)	42 (6.7%)	0 (0.0%)	264 (42.1%)	29 (4.6%)	77 (12.3%)	6 (1.0%)
Totals	3441	1439 (41.8%)	127 (3.7%)	202 (5.9%)	908 (26.4%)	139 (4.0%)	583 (16.9%)	43 (1.2%)

Table 3. Frontal Sinus Fracture Type per 5-Year Increments

Years	AT	AT Displaced	PT	PT Displaced	AT/PT	AT/PT Displaced
92-95	0 (0.0%)	0 (0.0%)	0 (0.0%)	0 (0.0%)	0 (0.0%)	5 (100.0%)
96-00	82 (20.2%)	130 (31.9%)	9 (2.2%)	3 (0.7%)	39 (9.6%)	140 (34.4%)
01-05	45 (43.3%)	34 (32.7%)	0 (0.0%)	0 (0.0%)	14 (13.5%)	11 (10.6%)
06-10	402 (28.6%)	162 (11.5%)	38 (2.7%)	28 (2.0%)	353 (25.1%)	414 (29.5%)
11-15	316 (35.4%)	108 (12.1%)	34 (3.8%)	0 (0.0%)	261 (29.2%)	173 (19.4%)
16-20	173 (27.6%)	68 (10.9%)	70 (11.2%)	0 (0.0%)	214 (34.1%)	101 (16.1%)
Totals	1018 (29.6%)	502 (14.6%)	151 (4.4%)	31 (0.9%)	881 (25.6%)	844 (24.5%)
P values	0.740	0.090	0.416	0.041	0.744	0.220

AT, anterior table; PT, posterior table.

The bold *p*-value denotes statistical significance of posterior table displacement.

Table 4. Management Type per 5-Year Increments

Years	Reconstruction	Cranialization	Obliteration	Osteoneogenesis	Nonsurgical	Other
92-95	0 (0.0%)	0 (0.0%)	5 (100.0%)	0 (0.0%)	0 (0.0%)	0 (0.0%)
96-00	133 (32.7%)	68 (16.7%)	96 (23.6%)	11 (2.7%)	97 (23.8%)	2 (0.5%)
01-05	37 (35.6%)	5 (4.8%)	44 (42.3%)	0 (0.0%)	18 (17.3%)	0 (0.0%)
06-10	248 (17.7%)	300 (21.4%)	345 (24.6%)	22 (1.6%)	471 (33.5%)	3 (0.2%)
11-15	405 (45.4%)	144 (16.1%)	110 (12.3%)	0 (0.0%)	230 (25.8%)	4 (0.5%)
16-20	132 (21.1%)	76 (12.1%)	48 (7.7%)	0 (0.0%)	317 (50.6%)	54 (8.6%)
Totals	955 (27.8%)	593 (17.2%)	648 (18.8%)	33 (1.0%)	1133 (32.9%)	63 (1.8%)

DISCUSSION

Frontal Sinus Management

The management of frontal sinus fractures remains challenging and often necessitates interdisciplinary collaboration from specialties such as plastic surgery, neurosurgery, and otolaryngology. We briefly summarize currently available treatment options below, which range from observation to cranialization.

Conservative management often includes clinical follow-up with CT scans or endoscopic treatments to recanalize the NFOT.²⁰ Patients can also be started on nasal decongestants to promote drainage from the sinuses.²¹ If complications ultimately arise, these patients are often managed endoscopically.^{11,22,23}

Obliteration involves removal of all the mucosa in the sinus, burring of sinus walls to eliminate mucosal invaginations, plugging of the NFOT, and filling of the sinus cavity with either fat, muscle, bone, or alloplasts, effectively removing the sinus as a functional unit. The choice of

obliteration material is controversial. Bone grafts encourage ossification of the sinus, while galeal and pericranial flaps provide vascularized tissue to the site of injury^{3,24-26} (Fig. 4). Conversely, fat (a nonvascularized option) relies on the vascular bed of the sinus for vascularization, which in cases of comminuted fractures has decreased blood supply. Additionally, some may choose to do nothing following stripping of the mucosa and allow for osteoneogenesis of the sinus, with the bone forming scar tissue.²⁷

Cranialization, first described in 1978 by Donald and Bernstein, involves the surgical removal of the nasofrontal ducts, posterior table of the frontal sinus, and all mucosa within the sinus.²⁸ This results in brain expansion into the sinus space, which becomes part of the intracranial cavity. Cranialization facilitates wide exposure and access to the cranial base, both of which are important in assessing and repairing complex facial fractures. Moreover, this procedure allows for elimination of the sinus, and consequently removes a potential source of long-term complications (Figs. 5, 6).

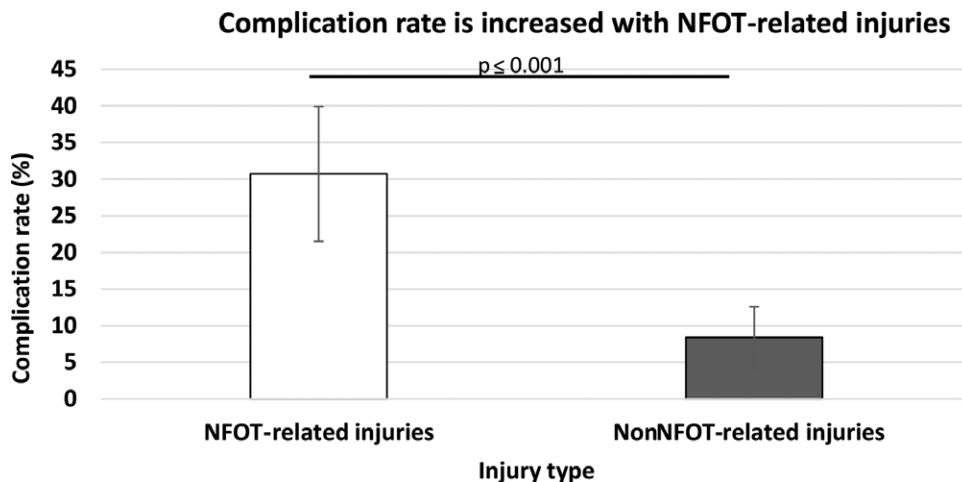


Fig. 2. Complication rate based on the presence of NFOT injury.

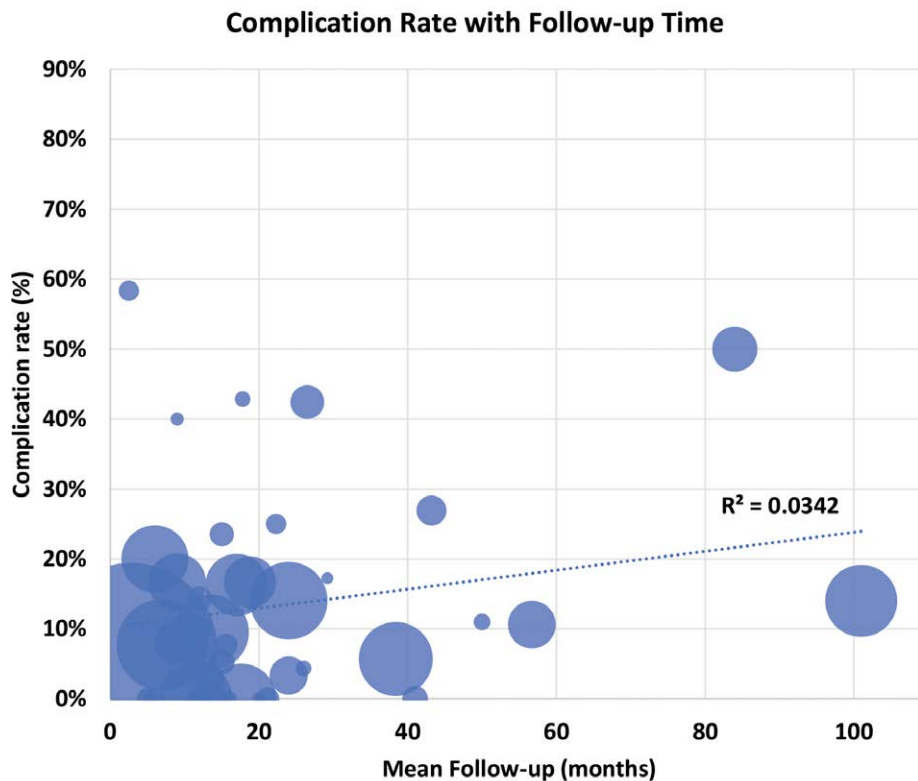


Fig. 3. Relationship of complications and follow-up length.

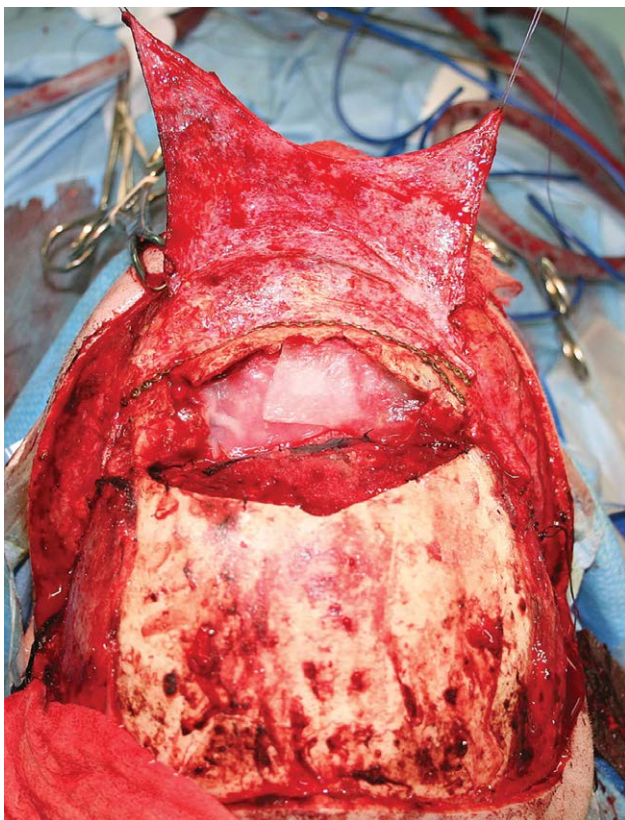


Fig. 4. Intraoperative view of pericranial flap for NFOT obliteration. Published with permission from and copyrights retained by Eduardo D. Rodriguez, MD, DDS.

The last operative form of management (reconstruction) can be performed either open or endoscopically. In reconstruction, the NFOT and mucosa are preserved, and the fracture is stabilized. Open reconstruction employs traditional surgical access to the sinus, often through a coronal incision, whereas newer endoscopic approaches require a smaller incision. Fractures that are more displaced and associated with a contour deformity are more likely to be managed via an open approach. Endoscopic approach limits in the extent of fracture reduction possible. Currently, there is a lack of studies that directly compare clinical outcomes of the two approaches.²⁹

Intervention Selection

Treatment decisions often depend on several key factors: the fracture pattern (type, comminution, degree of displacement), NFOT injury, neurological status at the time of presentation, and the presence of CSF leak.^{1,3,6,30–35} Consistent with previously published literature, our findings showed an increase in complication rate with NFOT injury, which further supports the importance of thorough evaluation of the NFOT involvement. Preoperatively, a thorough evaluation consists of CT imaging to assess for obstruction, frontal sinus floor fracture, and associated anterior ethmoid complex fracture.^{36–38} Interestingly, we found no difference in complication rate between the various forms of management when looking only at patients with NFOT injury. This highlights the importance of assessing the extent of associated injuries and the patency of the NFOT to aid in selecting the appropriate management.

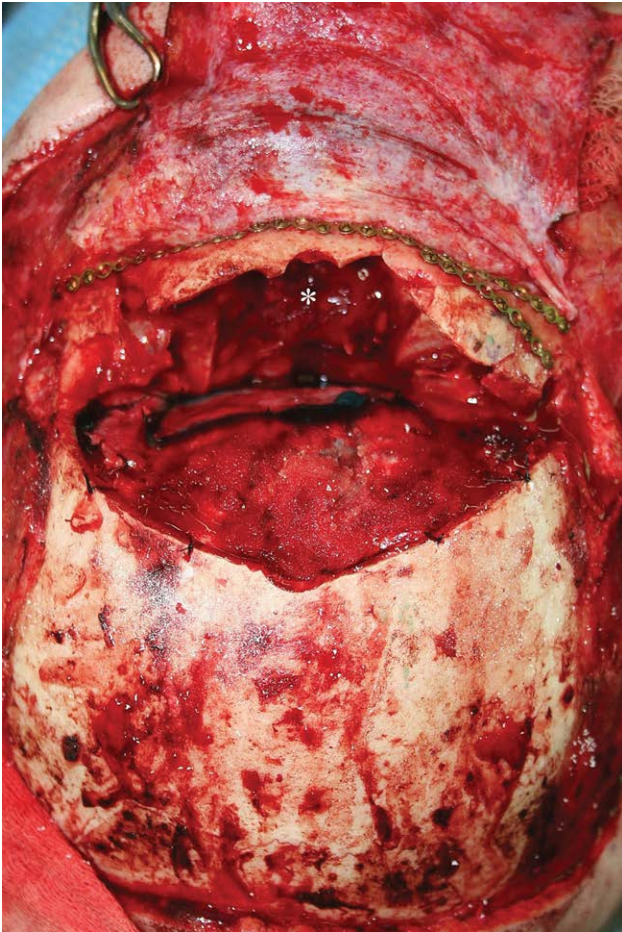


Fig. 5. Intraoperative cranialization. *Denotes the frontal sinus cavity. Published with permission from and copyrights retained by Eduardo D. Rodriguez, MD, DDS.

Although our findings lack statistical significance, which we believe is due to the heterogeneity of the reported data, we observed some changes in the literature that we present qualitatively in this study. Namely, for certain fracture patterns, there has been an increase in the use of more conservative approaches, such as observation and endoscopic technique. In patients with frontal sinus fractures not requiring surgical intervention, yet with NFOT obstruction, it is possible to manage these patients expectantly with medical therapy and observation. In the literature, a small prospective study found around 70% of these will have spontaneous ventilation of the frontal sinus.²³ However, this was a prospective study with a mean follow-up of 17.8 months. Therefore, it could not identify mucocoeles, a serious long-term complication of frontal sinus fracture management that can take over a decade to develop. In those that do not spontaneously ventilate, they can often be successfully managed with endoscopic approaches.²³ Moreover, in patients without NFOT injury, previous work has shown the efficacy of observation in select patients with several different fracture patterns, including displaced and nondisplaced anterior wall, displaced and nondisplaced posterior wall, and nondisplaced AT/PT wall fractures.⁷ Our data support

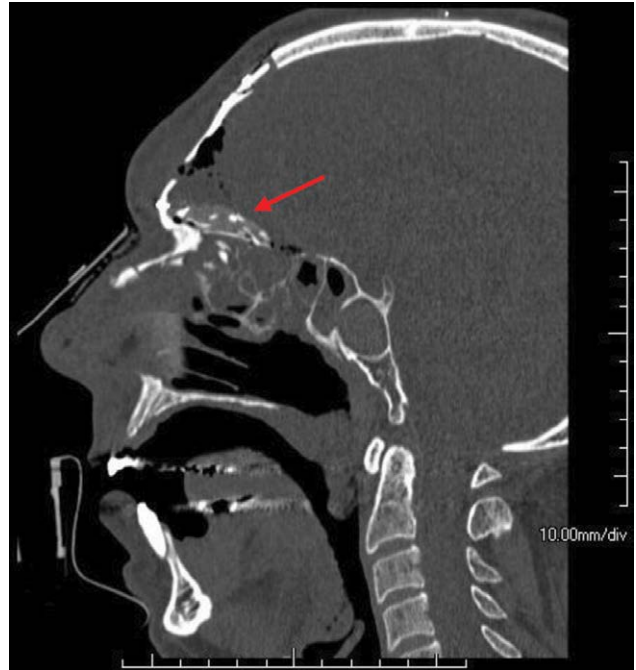


Fig. 6. CT scan following cranialization with calvarial bone graft seal. Published with permission from and copyrights retained by Eduardo D. Rodriguez, MD, DDS.

this trend toward observation and endoscopic management for select patient populations; however, our findings on increased rates of complications in patients with NFOT involvement further demonstrate the need to thoroughly evaluate extent of fracture involvement before pursuing conservative management.

Challenges

The array of injuries associated with frontal sinus fractures may complicate management of these fractures. Frontal sinus injuries often result from high energy injuries, as the frontal bone requires double the force of other facial bones to fracture³⁹ (Fig. 7). Consequently, injuries causing frontal sinus fractures can also cause associated midfacial fractures or extend posteriorly as frontobasilar fractures, in addition to intracranial and bodily injuries, all of which complicate the management of these patients.^{39–41} Importantly, frontobasilar fractures have been shown to be associated with two potentially significant acute complications (CSF fistula and meningitis), further complicating management.⁴ Anatomically, frontal sinus fractures prove challenging to manage, both due to the location of the frontal sinus and its association with the intracranial space via the diploic veins (veins of Breschet).⁴² Furthermore, some of the complications are often difficult to predict and quantify, and may not present until a decade after initial injury^{6,43–45} (Figs. 8, 9).

Guiding Principles of Management

Currently, numerous treatment algorithms exist with little consensus on the ideal treatment algorithm.^{5,6,46,47} Moreover, as demonstrated by this article, no significant difference exists among selected interventions or

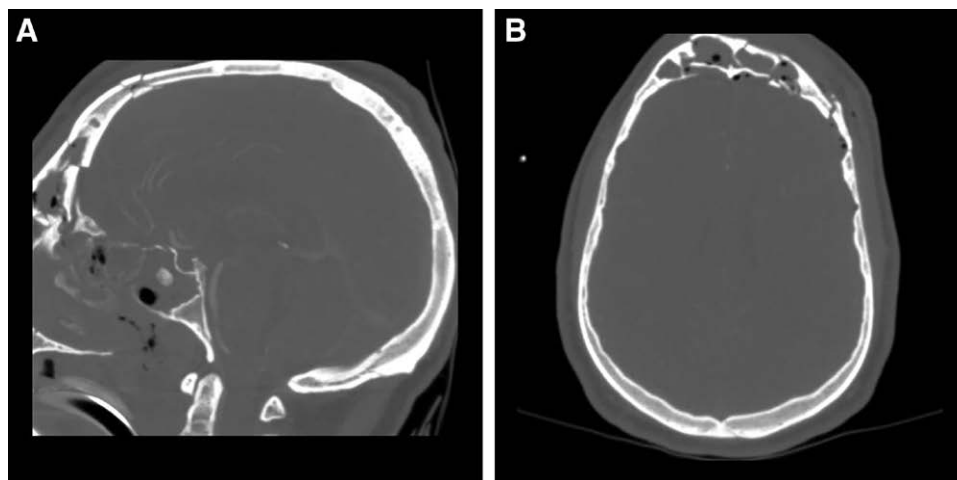


Fig. 7. CT image of severe comminuted anterior table and posterior table fracture. A, Sagittal view. B, Axial view. Published with permission from and copyrights retained by Eduardo D. Rodriguez, MD, DDS.

associated complication rates under similar clinical conditions. Together, these findings highlight that no single evidence-based approach to managing frontal sinus fractures currently exists. However, from the senior authors' extensive experience with these fractures, a lack of long-term follow-up data likely plays a significant role in this outcome. Chronic indolent infections that require intervention have been reported over a decade after initial frontal sinus management, yet follow-up data available in the literature range from 9 to 55 months. In the senior authors' experience, it is the key to identify certain factors for the successful management of these fractures and prevention of long-term complications. Preoperative management should utilize CT imaging to assess fracture extent, associated fractures, NFOT obstruction, and CSF leak. Intraoperatively, adequate visualization best ensures successful surgical management and aids in prevention of long-term complications. The frontal sinuses are lined with mucosa and communicate with the nasal cavity via the NFOT. The mucosa produces secretions that are swept toward the nasal cavity by cilia located on the surface of

the sinuses. From the senior authors' experience, there is likely a critical area of mucosa that needs to be injured to compromise sinus function. The injured mucosa becomes scarred, and the cilia of the sinus likely do not regenerate, compromising the ability to properly sweep sinus contents. However, the extent of injury/percentage of damage to the frontal sinus required remains unknown. Violation of these mucosal surfaces or disruption of sinus outflow can result in complications if not managed properly. Specifically, successful cranialization and obliteration require meticulous burring of the mucosa and careful plugging of the NFOT. Pouring methylene blue into the sinus and observing for release out of the nose can be used for intraoperative NFOT evaluation. Furthermore, if there is unilateral NFOT obstruction, the contralateral side can provide adequate drainage. However, in addition to confirming patency of the contralateral side, presence of any bony septum between the frontal sinus cavities must be assessed and taken down if present. Complications such as mucocoeles, which usually result from improper fracture management, may not present for years. Presentation

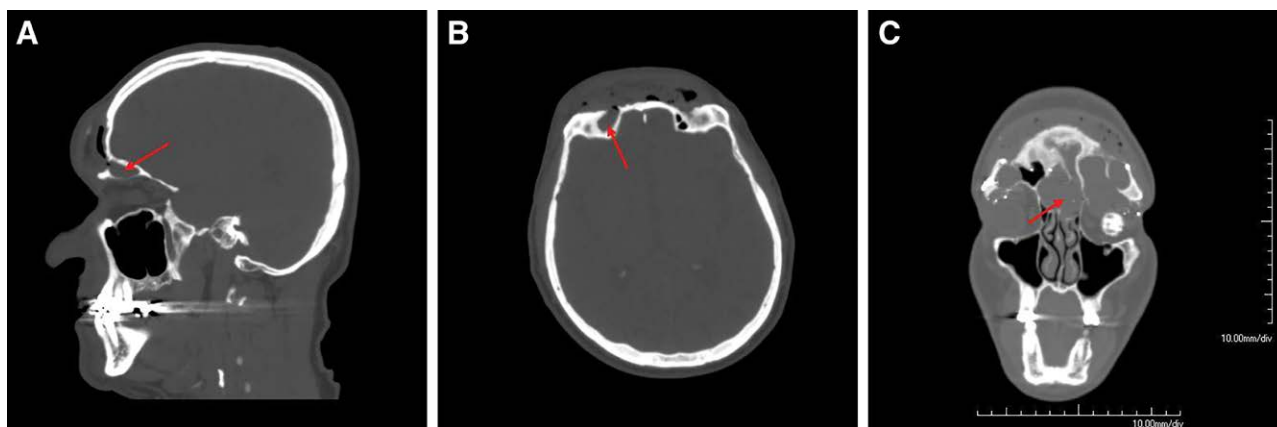


Fig. 8. CT scan showing mucocoele. A (sagittal view) and B (axial view) demonstrate mucocoele communication with the remnant frontal sinus (red arrow). C (coronal view) demonstrates mucocoele (red arrow) causing displacement of left eye prosthesis. Published with permission from and copyrights retained by Eduardo D. Rodriguez, MD, DDS.

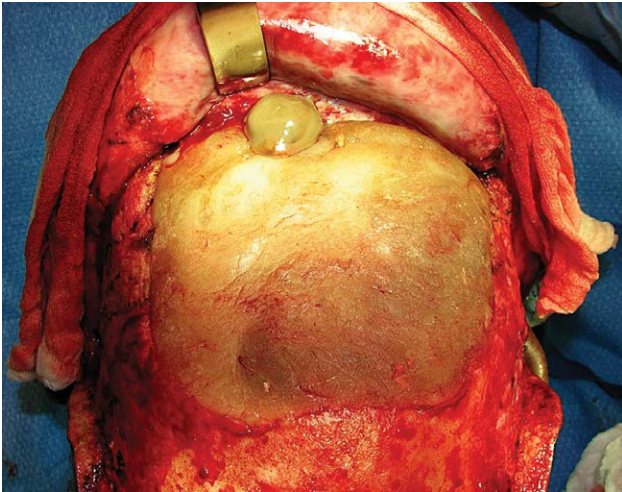


Fig. 9. Intraoperative mucocele. Published with permission from and copyrights retained by Eduardo D. Rodriguez, MD, DDS.

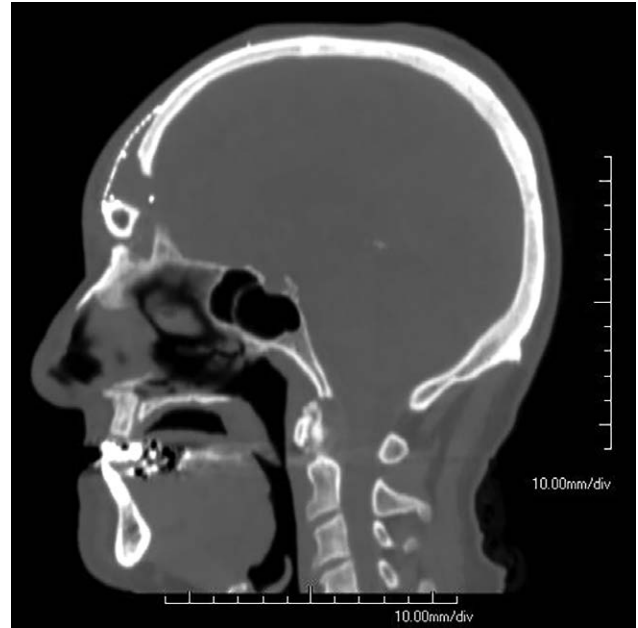


Fig. 10. CT scan free fibula for persistent frontal sinus infection management. Published with permission from and copyrights retained by Eduardo D. Rodriguez, MD, DDS.

may include pressure or mass-like symptoms, in addition to more indolent symptoms, such as visual disturbances, nasal obstruction, or pain resulting from bone destruction.^{6,44,48,49}

The management of these complications is a unique but important clinical scenario. In the senior authors' experience, chronic frontal sinus infections can present as late as a decade after initial frontal sinus management. Factors such as incomplete partitioning of the upper aerodigestive system and the anterior cranial base or insufficient mucosal removal both have been noted to result in indolent infection.^{6,15,30,35,43} Management frequently involves removal of hardware from prior interventions and sinus reobliteration or ablation. An array of interventions from sinus ablation to sinus reobliteration and nonvascularized bone grafts have been commonly used. However, in the senior authors' experience, these interventions have limited effectiveness in chronic infections and a more aggressive, definitive approach to these challenges is warranted. Several case series have presented successful management of persistent frontal sinus infections, with free fibular flap in a single stage.^{45,50,51} The attached hallucis longus obliterates the sinus and occludes the NFOT, while the free fibula bone reconstructs the horizontal buttress. The rich vascular supply of the fibula flap offers a local environment optimized for wound healing and prevention of osteomyelitis, and its mechanical properties offer excellent skeletal stability (Fig. 10).

At this point of discussion, surgeon comfort level and experience with the array of interventions should be considered. The various forms of frontal sinus fracture management can all be successful, including nonoperative management (when selected under appropriate clinical circumstance) and with meticulous surgical execution (when surgery is chosen). However, in the setting of chronic, indolent infection, free bony tissue transfer can be a powerful, definitive treatment modality that has only been described in limited case series. Expert recommendations and clinical pearls can be found in Tables 5-6.

Limitations

Our study is limited by the potential exclusion of any non-English articles or articles not identified by our search parameters. Additionally, the heterogeneity of data reporting and surgical technique makes statistical analysis challenging. Furthermore, the complication rate data are limited by the length of follow-up in each article,

Table 5. Expert Recommendations

Preoperative	Imaging (CT) 1. Fracture extent 2. NFOT obstruction a. Gross outflow tract obstruction b. Frontal sinus floor fracture c. Anterior table medial wall fracture 3. CSF leak 4. Associated fractures
Intraoperative	Visualization 1. NFOT a. Can be aided with use of methylene blue 2. Unilateral NFOT obstruction a. Assess for bony septum and remove if present Meticulous surgical technique 1. Burring of mucosa 2. NFOT plugging
Follow-up	Clinical sign of mucocele 1. Frontal pressure/mass-like symptoms 2. Forehead erythema 3. Visible purulent drainage 4. Periorbital pain 5. Persistent infections Indolent signs of mucocele 1. Visual disturbances 2. Orbital dystopia/ocular dysfunction 3. CNS involvement Prompt identification and management 1. CT imaging 2. Hardware removal and debridement 3. Free fibula for reconstruction a. Obliterates sinus b. Restoration of horizontal buttress

CNS: central nervous system.

Table 6. Clinical Pearls

When confronted with a frontal sinus fracture, the fracture pattern should be classified, with attention paid to the involvement and extent of injury to the anterior wall, posterior wall, and NFOT involvement. Treatment decisions will be based on the analysis of fracture classifications following an algorithmic approach, as previously described by Rodriguez et al.¹⁴

When the decision to operate is made based on the algorithm, the sooner it is performed the better.

Severe comminution of both the anterior and posterior wall is rarely reconstructable and should be treated with additional concern and have the sinus defunctionalized.

Disruption of a critical amount of the mucosal cilia impairs the normal functioning of the sinus and should be managed with defunctionalization of the sinus and NFOT.

as complications associated with frontal sinus fracture may not present for years.

CONCLUSIONS

Frontal sinus fracture management is a challenging clinical situation with varied management techniques. Although, to date, there is no widely accepted treatment algorithm, there are important guiding principles that can be used to guide management selection, such as the fracture pattern and extent of NFOT injury, which should be thoroughly evaluated upon patient presentation.

Eduardo D. Rodriguez, MD, DDS

Hansjörg Wyss Department of Plastic Surgery
NYU Langone Health, 222 E 41st Street, 6th Floor
New York, NY 10017
E-mail: eduardo.rodriguez@nyulangone.org

Paul N. Manson, MD

Department of Plastic and Reconstructive Surgery
Johns Hopkins School of Medicine
601 N. Caroline St, 8th Floor
Baltimore, MD 21287
E-mail: pmanson@jhmi.edu

REFERENCES

- Wilson BC, Davidson B, Corey JP, et al. Comparison of complications following frontal sinus fractures managed with exploration with or without obliteration over 10 years. *Laryngoscope*. 1988;98:516–520.
- Raveh J, Laedrach K, Vuillemin T, et al. Management of combined frontonasal-orbital/skull base fractures and telecanthus in 355 cases. *Arch Otolaryngol Head Neck Surg*. 1992;118:605–614.
- Gerbino G, Roccia F, Benech A, et al. Analysis of 158 frontal sinus fractures: current surgical management and complications. *J Craniomaxillofac Surg*. 2000;28:133–139.
- Manson PN, Stanwix MG, Yaremchuk MJ, et al. Frontobasal fractures: anatomical classification and clinical significance. *Plast Reconstr Surg*. 2009;124:2096–2106.
- Manson PN, Markowitz B, Mirvis S, Dunham M, Yaremchuk M. Toward CT-based facial fracture treatment. *Plast Reconstr Surg*. 1990;85:202–212; discussion 213–214.
- Rohrich RJ, Hollier LH. Management of frontal sinus fractures. Changing concepts. *Clin Plast Surg*. 1992;19:219–232.
- Rodriguez ED, Stanwix MG, Nam AJ, et al. Twenty-six-year experience treating frontal sinus fractures: a novel algorithm based on anatomical fracture pattern and failure of conventional techniques. *Plast Reconstr Surg*. 2008;122:1850–1866.
- Weathers WM, Wolfswinkel EM, Hatfeg DA, et al. Frontal sinus fractures: a conservative shift. *Cranio Trauma Reconstr*. 2013;6:155–160.
- Choi M, Li Y, Shapiro SA, et al. A 10-year review of frontal sinus fractures: clinical outcomes of conservative management of posterior table fractures. *Plast Reconstr Surg*. 2012;130:399–406.
- Freeman JL, Winston KR. Breach of posterior wall of frontal sinus: management with preservation of the sinus. *World Neurosurg*. 2015;83:1080–1089.
- Emara TA, Elnashar IS, Omara TA, et al. Frontal sinus fractures with suspected outflow tract obstruction: a new approach for sinus preservation. *J Craniomaxillofac Surg*. 2015;43:1–6.
- Chouake RJ, Miles BA. Current opinion in otolaryngology and head and neck surgery: frontal sinus fractures. *Curr Opin Otolaryngol Head Neck Surg*. 2017;25:326–331.
- Grayson JW, Jeyarajan H, Illing EA, et al. Changing the surgical dogma in frontal sinus trauma: transnasal endoscopic repair. *Int Forum Allergy Rhinol*. 2017;7:441–449.
- Shankar K, Thakar A, Sharma SC. In Response to “Changing the surgical dogma in frontal sinus trauma: transnasal endoscopic repair” by Grayson et al. *Int Forum Allergy Rhinol*. 2017;7:1108.
- Ioannides C, Freihofer HP. Fractures of the frontal sinus: classification and its implications for surgical treatment. *Am J Otolaryngol*. 1999;20:273–280.
- Strong EB, Pahlavan N, Saito D. Frontal sinus fractures: a 28-year retrospective review. *Otolaryngol Head Neck Surg*. 2006;135:774–779.
- Bell RB, Dierks EJ, Brar P, et al. A protocol for the management of frontal sinus fractures emphasizing sinus preservation. *J Oral Maxillofac Surg*. 2007;65:825–839.
- Tedaldi M, Ramieri V, Foresta E, et al. Experience in the management of frontal sinus fractures. *J Craniofac Surg*. 2010;21:208–210.
- Bellamy JL, Molendijk J, Reddy SK, et al. Severe infectious complications following frontal sinus fracture: the impact of operative delay and perioperative antibiotic use. *Plast Reconstr Surg*. 2013;132:154–162.
- Koento T. Current advances in sinus preservation for the management of frontal sinus fractures. *Curr Opin Otolaryngol Head Neck Surg*. 2012;20:274–279.
- Echo A, Troy JS, Hollier LH Jr. Frontal sinus fractures. *Semin Plast Surg*. 2010;24:375–382.
- Kanowitz SJ, Batra PS, Citardi MJ. Comprehensive management of failed frontal sinus obliteration. *Am J Rhinol*. 2008;22:263–270.
- Smith TL, Han JK, Loehrl TA, et al. Endoscopic management of the frontal recess in frontal sinus fractures: a shift in the paradigm? *Laryngoscope*. 2002;112:784–790.
- Grahne B. Chronic frontal sinusitis treated by autogenous osteoplasty. *Acta Otolaryngol*. 1971;72:215–219.
- Parhiscar A, Har-El G. Frontal sinus obliteration with the pericranial flap. *Otolaryngol Head Neck Surg*. 2001;124:304–307.
- Thaller SR, Donald P. The use of pericranial flaps in frontal sinus fractures. *Ann Plast Surg*. 1994;32:284–287.
- Mickel TJ, Rohrich RJ, Robinson JB Jr. Frontal sinus obliteration: a comparison of fat, muscle, bone, and spontaneous osteoneogenesis in the cat model. *Plast Reconstr Surg*. 1995;95:586–592.
- Donald PJ, Bernstein L. Compound frontal sinus injuries with intracranial penetration. *Laryngoscope*. 1978;88(2 Pt 1):225–232.
- Le P, Martinez R, Black J. Frontal sinus fracture management meta-analysis: endoscopic versus open repair. *J Craniofac Surg*. 2021;32:1311–1315.
- Chen KT, Chen CT, Mardini S, et al. Frontal sinus fractures: a treatment algorithm and assessment of outcomes based on 78 clinical cases. *Plast Reconstr Surg*. 2006;118:457–468.

31. Schultz RC, de Camara DL. Athletic facial injuries. *JAMA*. 1984;252:3395–3398.
32. Larrabee WF Jr, Travis LW, Tabb HG. Frontal sinus fractures—their suppurative complications and surgical management. *Laryngoscope*. 1980;90(11 Pt 1):1810–1813.
33. Montgomery WW. Surgery of the frontal sinuses. *Otolaryngol Clin North Am*. 1971;4:97–126.
34. Snyderman CH, Scioscia K, Carrau RL, et al. Hydroxyapatite: an alternative method of frontal sinus obliteration. *Otolaryngol Clin North Am*. 2001;34:179–191.
35. Wolfe SA, Johnson P. Frontal sinus injuries: primary care and management of late complications. *Plast Reconstr Surg*. 1988;82:781–791.
36. Harris L, Marano GD, McCorkle D. Nasofrontal duct: CT in frontal sinus trauma. *Radiology*. 1987;165:195–198.
37. Heller EM, Jacobs JB, Holliday RA. Evaluation of the frontonasal duct in frontal sinus fractures. *Head Neck*. 1989;11:46–50.
38. Landsberg R, Friedman M. A computer-assisted anatomical study of the nasofrontal region. *Laryngoscope*. 2001;111:2125–2130.
39. Nahum AM. The biomechanics of maxillofacial trauma. *Clin Plast Surg*. 1975;2:59–64.
40. Wallis A, Donald PJ. Frontal sinus fractures: a review of 72 cases. *Laryngoscope*. 1988;98(6 Pt 1):593–598.
41. Duvall AJ III, Porto DP, Lyons D, et al. Frontal sinus fractures. Analysis of treatment results. *Arch Otolaryngol Head Neck Surg*. 1987;113:933–935.
42. Remmler D, Boles R. Intracranial complications of frontal sinusitis. *Laryngoscope*. 1980;90(11 Pt 1):1814–1824.
43. Manolidis S, Hollier LH Jr. Management of frontal sinus fractures. *Plast Reconstr Surg*. 2007;120(7 Suppl 2):32S–48S.
44. Weitzel EK, Hollier LH, Calzada G, et al. Single stage management of complex fronto-orbital mucoceles. *J Craniofac Surg*. 2002;13:739–745.
45. Rodriguez ED, Stanwix MG, Nam AJ, et al. Definitive treatment of persistent frontal sinus infections: elimination of dead space and sinonasal communication. *Plast Reconstr Surg*. 2009;123:957–967.
46. Kelly KJ, Manson PN, Vander Kolk CA, et al. Sequencing LeFort fracture treatment (organization of treatment for a panfacial fracture). *J Craniofac Surg*. 1990;1:168–178.
47. Manson PN, Crawley WA, Hoopes JE. Frontal cranioplasty: risk factors and choice of cranial vault reconstructive material. *Plast Reconstr Surg*. 1986;77:888–904.
48. Abrahamson IA Jr, Baluyot ST, Tew JM Jr, et al. Frontal sinus mucocele. *Ann Ophthalmol*. 1979;11:173–178.
49. LaRossa DD, Noone RB, Jackson P. Facial deformity from frontal sinus mucocele: single stage surgical correction. Case report. *Plast Reconstr Surg*. 1977;60:917–919.
50. Bluebond-Langner R, Jackowe D, Rodriguez ED. Simultaneous obliteration and treatment of infected frontal sinus fractures: novel use of the fibula flap. *J Craniofac Surg*. 2007;18:680–683.
51. Sinno S, Rodriguez ED. Definitive management of persistent frontal sinus infections and mucocele with a vascularized free fibula flap. *Plast Reconstr Surg*. 2017;139:170–175.