

# Treatment of unstable hips with the Tübingen splint in early postnatal period: radiological mid-term results of 75 hips with mean follow-up of 5.5 years

Hannes Kubo<sup>1\*</sup>

Lisa Oezel<sup>1\*</sup>

David Latz<sup>1</sup>

Martin Hufeland<sup>1</sup>

Erik Schiffner<sup>1</sup>

Hakan Pilge<sup>2</sup>

Ruediger Krauspe<sup>3</sup>

Bettina Westhoff<sup>1</sup>

## Abstract

**Purpose** For treatment of unstable hips, the Tübingen splint is a treatment option. After the initial treatment, regular radiological follow-up examinations are recommended but there is a lack of long-term outcome studies. Therefore, the further development of unstable hips treated with the Tübingen splint were evaluated.

**Methods** From 2004 to 2015 116 patients with 161 unstable hips treated with the Tübingen splint were evaluated. Inclusion criteria were: 1) successfully treated unstable hip (type D, III and IV); 2) pelvic radiographs at the age of one to  $\leq$  two, two to  $\leq$  four and four to  $\leq$  eight years. The acetabular index (ACI) of all and the centre-edge angle (CEA) of the third radiograph were measured and classified according to the Tönnis classification.

**Results** A total of 53 patients with 75 unstable hips (type D 34 (45.3%), III 33 (44.0%), IV 8 (10.7%)) were included. In comparison of the first, second and third radiograph, an increase of normal findings was seen in 31 (41.3%) to 53 (70.7%) and 60 (80.0%) hips, respectively. However, a decrease of slightly dysplastic hips from 31 (41.3%) to 19 (25.3%) and 14 (18.7%) respectively and severely dysplastic hips from 13 (17.3%) to three (4.0%) and one (1.3%) hip respectively was detected. In

comparison of first to second radiograph, 32 hips improved and five hips deteriorated and of second to third radiograph 16 hips improved and six hips deteriorated. The Tönnis classification of ACI compared with CEA showed no significant differences ( $p = 0.442$ ).

**Conclusion** This study shows a good development of unstable hips treated with the Tübingen splint with mean follow-up 5.5 years. Nevertheless, unexpected deteriorations could be identified. The CEA is an alternative to the ACI.

*Level of evidence: IV*

Cite this article: Kubo H, Oezel L, Latz D, Hufeland M, Schiffner E, Pilge H, Krauspe R, Westhoff B. Treatment of unstable hips with the Tübingen splint in early postnatal period: radiological mid-term results of 75 hips with mean follow-up of 5.5 years. *J Child Orthop* 2020;14:252-258. DOI: 10.1302/1863-2548.14.200074

**Keywords:** developmental dysplasia of the hip; unstable hips; Tübingen splint; acetabular index; centre-edge angle

## Introduction

Several treatment options are established for the initial treatment of developmental dysplasia of the hip (DDH).<sup>1,2</sup> The therapy is usually based on the degree of severity of the dysplasia of the affected hip joint. Here, the ultrasound classification according to Graf is well established and provides basic information of the biomechanical situation.<sup>3,4</sup> This method is easy to apply, non-invasive, has no radiation exposure and shows a good interrater reliability. Graf classified the DDH into ultrasound stable (hip type I to IIc) and unstable hips (hip type D to IV). The ultrasound examination according to Graf is part of the neonatal screening programme which was introduced in Central Europe in the middle of the 1990s. Here, all children undergo a general clinical and ultrasound examination between the fourth and sixth week of life. Children with risk factors e.g. breech position or positive family history get a selective screening up to the third day of life. For treatment of unstable hips, the Tübingen splint has shown favourable outcomes. The splint consists of synthetic shells for the thighs and string of pearls, which are variable in size (Fig. 1). Initially, the splint was only used to treat ultrasound stable hips type IIa, IIb and IIc.<sup>5</sup> However, in further studies

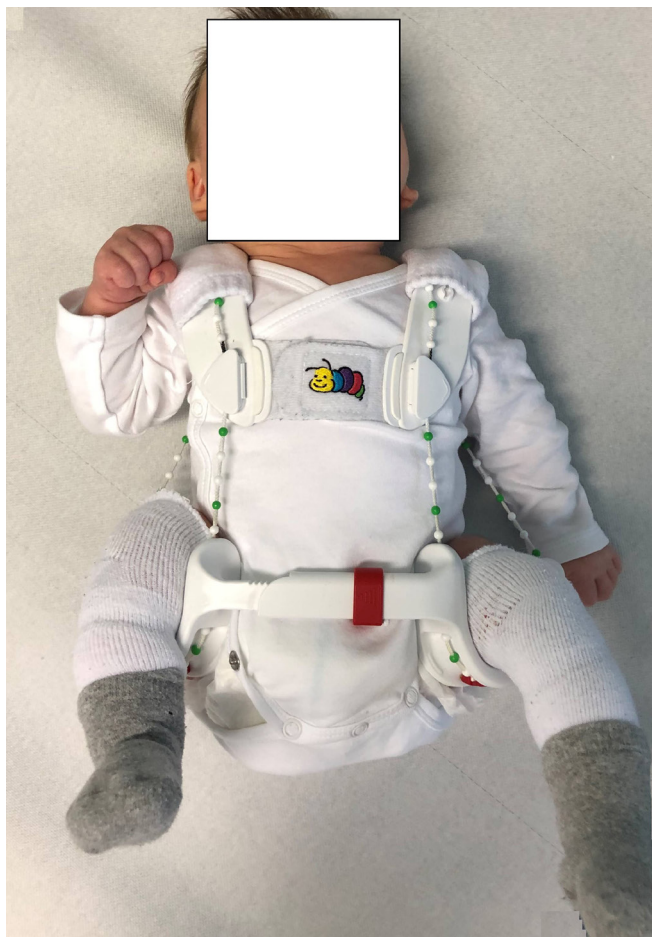<sup>1</sup> Medical Faculty, Department of Orthopaedics and Trauma Surgery, University of Duesseldorf, Duesseldorf, Germany

<sup>2</sup> Orthopaedicum Munich, Munich, Germany

<sup>3</sup> Orthopaedics Department, University Duesseldorf, Duesseldorf, Germany

\*These authors contributed equally to the work.

Correspondence should be sent to Hannes Kubo, University of Duesseldorf, Medical Faculty, Department of Orthopaedics and Trauma Surgery, Moorenstr. 5, D-40225 Duesseldorf, Germany. E-mail: hannes.kubo@med.uni-duesseldorf.de

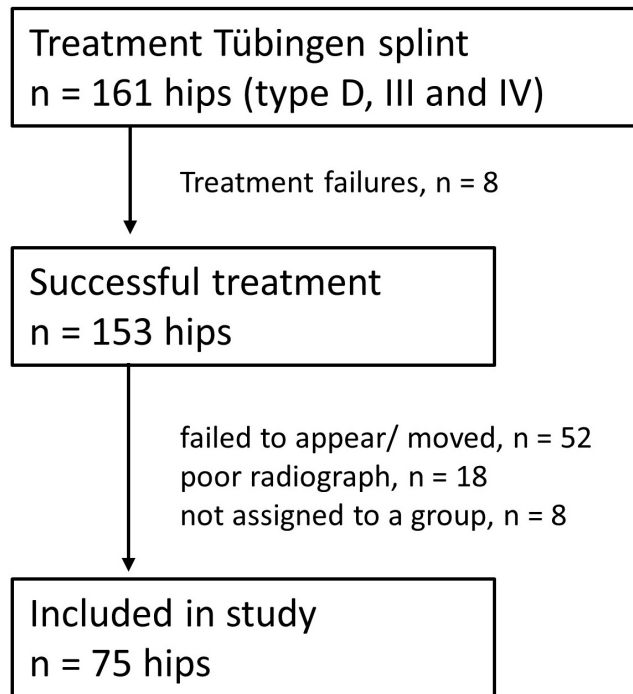


**Fig. 1** Two-month-old male infant with ultrasound unstable hips (bilateral, hip type D) treated with Tübingen splint.

successful treatment of unstable hips with the Tübingen splint was reported.<sup>6-8</sup> The results were similar to other treatment modalities such as Fettweis plaster or Pavlik harness and, therefore, it seems to be a reliable alternative treatment option in early diagnosed unstable hips.<sup>9,10</sup>

After the initial treatment, regular follow-up examinations are recommended.<sup>11,12</sup> Here, a residual dysplasia might be detected and if necessary, surgical treatment can be performed to prevent an early degeneration of the joint. Various control algorithms are discussed in order to determine useful time points for the control examinations. There is wide agreement for standard anteroposterior (AP) pelvic radiographs to accurately measure the degree of potential residual dysplasia since clinical examination will not reveal dysplastic findings.<sup>13</sup> Various angles and indices for evaluation and radiological assessment of the hips have been described. Especially, the acetabular index (ACI) and centre-edge angle (CEA) are validated for the analysis of DDH.<sup>14,15</sup>

The aim of this study is primarily to examine the further development of unstable hips, which were successfully treated with the Tübingen splint. Furthermore, the coher-



**Fig. 2** Study protocol.

ence of the ACI and the CEA is evaluated to allow for reliable examination of those hips in future studies applying the appropriate measurement over time.

## Material and methods

### Patients

From 1<sup>st</sup> May 2004 to 28<sup>th</sup> February 2015 116 consecutive patients with 161 unstable hips (45 bilateral) were treated at our department with the Tübingen splint.

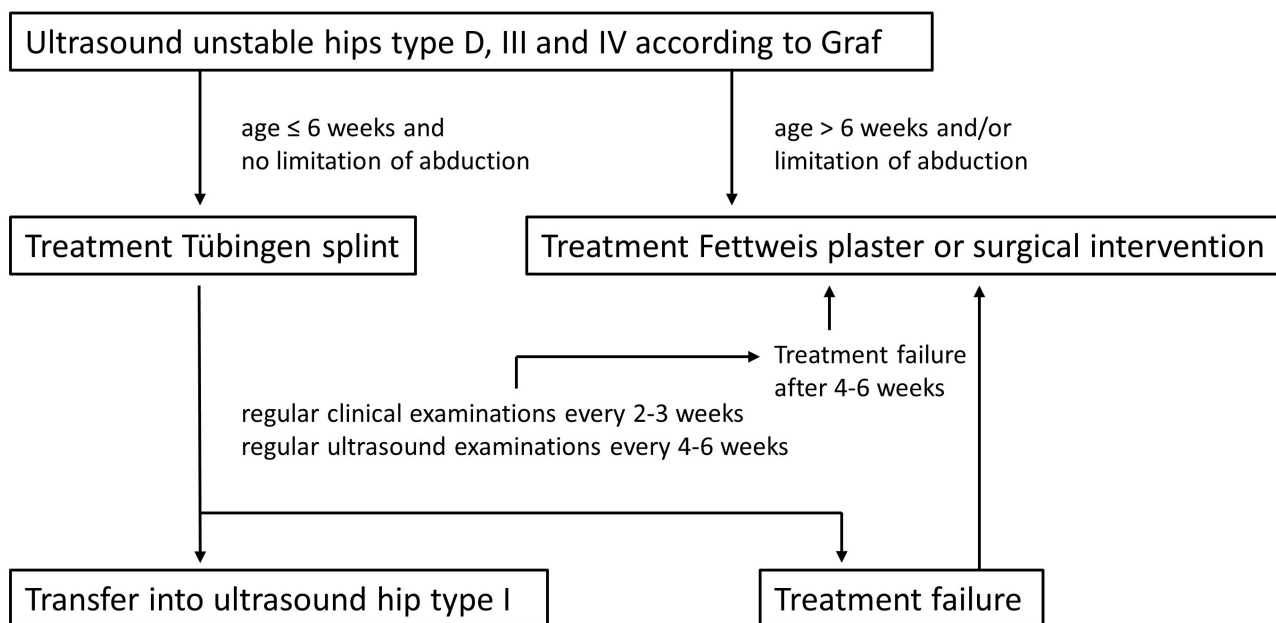
Inclusion criteria for this retrospective study were: 1) unstable hips (type D, III and IV) which were successfully treated with the Tübingen splint; and 2) regular AP pelvic radiographs at the age of one to ≤ two years, two to ≤ four years and four to ≤ eight years.

Patients with secondary hip dysplasia due to neurological disorders or syndromes were excluded.

There were eight treatment failures after therapy with the Tübingen splint. A total of 78 hips missed our inclusion criteria or did not appear at the appointment (Fig. 2).

### Treatment protocol for Tübingen splint

In our department patients with unstable hips (ultrasound hip type D, III and IV according to Graf) can be treated with the Tübingen splint (Fig. 3). The prerequisites for this alternative therapy method are early start of treatment within the first six weeks of life. Furthermore, the affected hips must not have any limitation abduction in the clini-



**Fig. 3** Treatment protocol of unstable hips (type D, III and IV) with the Tübingen splint.

cal examination. Patients older than six weeks or patients with limitation of abduction were treated with the Fettweis plaster or undergo a surgical intervention (open reduction). The splint is applied at 90° to 100° flexion and 40° to 50° abduction. After application of the Tübingen splint, there were regular clinical controls every two to three weeks with additional ultrasound examinations every four to six weeks. The patients had to wear the splint initially 24 hours per day, seven days a week. In the initial period the parents were advised that the splint must not be taken off –not even for changing diapers or for bathing. If there was no improvement of the ultrasound findings after four to six weeks, the treatment was changed to therapy with Fettweis plaster. A successful treatment with the Tübingen splint is achieved if the hip can be transferred into an ultrasound stable hip with an alpha angle of > 65° (according to the maturation curve of Tschauner et al).<sup>16</sup>

### Methods

The ACI is measured as an angle using a line through the Y-gap of the pelvis (Hilgenreiner line) and a line to the lateral edge of the acetabular roof (Fig. 4). The CEA is defined as the angle between a line perpendicular to a horizontal line which passes through the centre of the femoral head and a second line from the centre of the femoral head to the lateral edge of the acetabular roof (Fig. 4). The CEA is established especially in children and adolescents with a closed or not clearly measurable Y-gap and can be used by the age of four years. For both ACI and CEA, Tönnis et al<sup>17-19</sup> developed classifications to divide the hips into different degrees of dysplasia: the ACI is divided into normal find-

ings (< 1 SD), slightly dysplastic (1 SD to 2 SD) and severely dysplastic hips (> 2 SD) depending on age and gender. The CEA is also subdivided into normal findings, slightly pathological and severely pathological hips depending on age. According to Tönnis,<sup>18</sup> in patients under eight years of age a CEA of 20° or higher is normal, slightly pathological between 15° and 19° and severely pathological below 15°. The ACI of all three radiographs and the CEA of the third radiograph was measured and classified by the first and second author according to the Tönnis classification. In addition, both classifications of the third radiographs (ACI and CEA) were analyzed to evaluate differences.

All radiographs were further screened for avascular necrosis (AVN) of the femoral head according to the criteria of Kalamchi and McEwen.<sup>20</sup>

### Statistical analysis

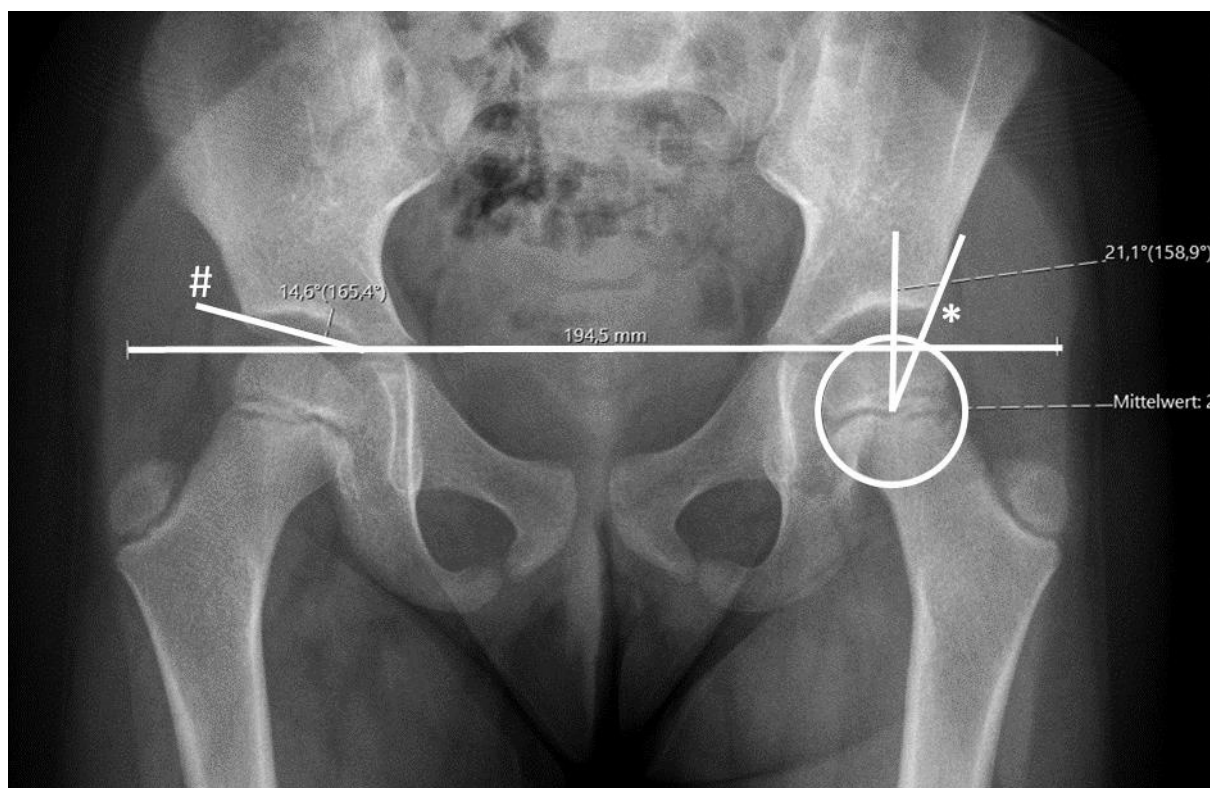
The data were evaluated using SPSS 25 (IBM Corp., Armonk, New York). The statistical analysis was done using Student's *t*-test ( $p \leq 0.05$  was considered as significant). The interrater reliability was analyzed using Cohen's Kappa.

## Results

### Treatment with Tübingen splint

The initial ultrasound hip type of all hips ( $n = 161$ ) was in 79 (49.1%) cases type D, in 67 (41.6%) type III and in 15 (9.3%) type IV. Mean age at the start of treatment was 23.0 days (SD 14.4; 0 to 42). The mean treatment period was 104.0 days (SD 35.9; 42 to 208). In 153 hips (95.0%)





**Fig. 4** Measurement of acetabular index (#, ACI) and centre-edge angle (\*, CEA). The ACI is measured using the Hilgenreiner line and the acetabular roof line. The CEA is defined as the angle from a perpendicular line through the centre of the femoral head and the acetabular edge.

a successful transfer into an ultrasound stable hip type I with a mean alpha angle of  $69.3^\circ$  (SD  $2.5^\circ$ ;  $65^\circ$  to  $76^\circ$ ) was achieved. In eight cases (5.0%) the treatment failed.

#### Treatment failures

The initial ultrasound hip type of the treatment failures was in 1/79 (1.3%) cases type D, in 3/67 (4.5%) cases type III and in 4/15 (26.7%) cases type IV. All of them showed an unsatisfactory result in the first ultrasound control. The therapy was changed and a closed reduction with subsequent application of a Fettweis plaster was performed. Until now, all hips show a good development in the control examinations. A surgical intervention was not necessary.

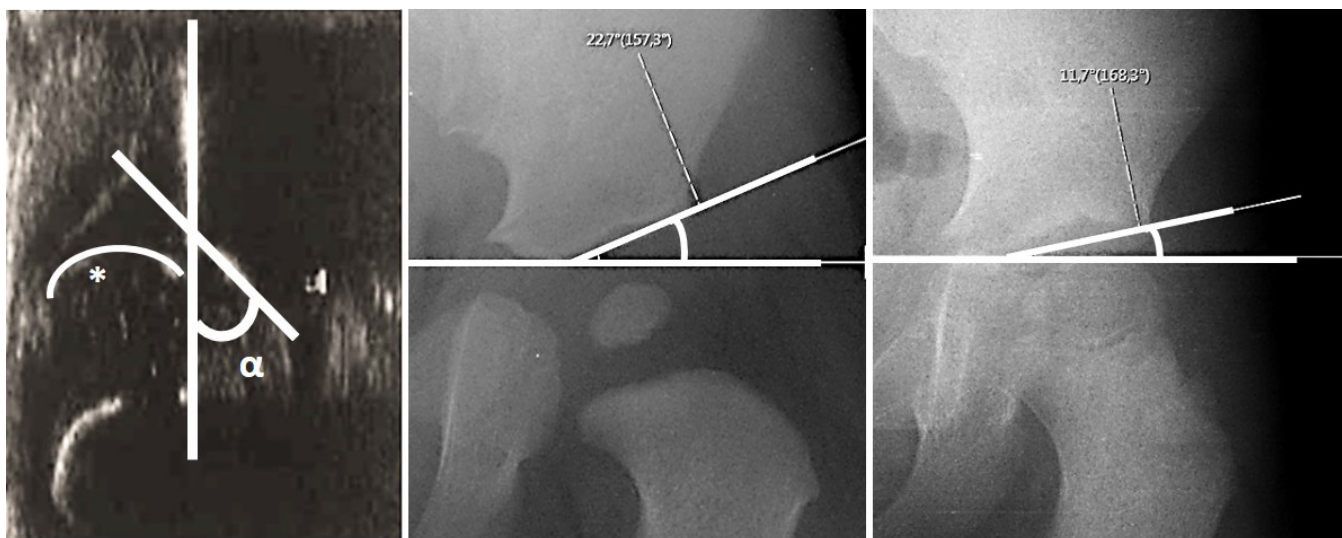
#### Development of the ACI over the study period of four to eight years

In all, 53 patients with 75 initially unstable hips (bilateral 22) were examined for radiological follow-up. The initial ultrasound hip type was in 34 (45.3%) cases type D, in 33 (44.0%) type III and in 8 (10.7%) type IV. The patient's mean age at the first radiograph was 1.2 years (SD 2.0; 1.0 to 1.8), 2.7 years (SD 5.7; 2.0 to 4.0) at the second and 5.5 years (SD 9.9; 4.3 to 7.6) at the third.

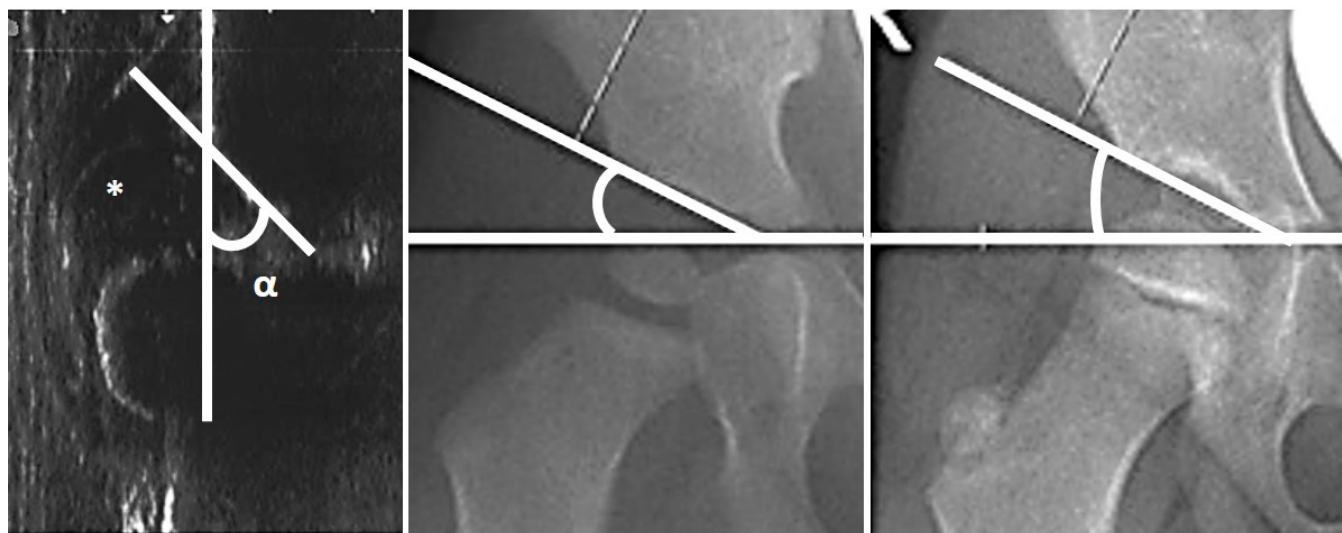
In a comparison of first versus second radiograph we found that in the first radiograph, classification of the hips

according to Tönnis et al<sup>18</sup> revealed in 31 (41.3%) cases normal findings, in 31 (41.3%) cases slightly dysplastic hips and in 13 (17.4%) cases severely dysplastic hips (Fig. 5). At the age of two to four years, 53 (70.7%) hips showed normal findings, 19 (25.3%) had a slightly dysplastic hip and 3 (4.0%) showed a severely dysplastic hip. Overall, 32 (42.7%; 22 slightly and ten severely dysplastic hips) hips improved, 38 (50.7%; 26 normal findings, nine slightly and three severely dysplastic findings) hips stayed on the same level and five (6.6%; all normal findings into slightly dysplasia) deteriorated. The initial ultrasound hip type of the deteriorating hips was in two cases a hip type D, in one case a hip type III and in two cases hips type IV.

The examination of the third radiograph showed in 60 (80.0%) cases normal findings, in 14 (18.7%) cases slightly and in one (1.3%) case severely dysplastic hips. The comparison of second versus third radiograph showed that a total of 14 (18.7%; 11 slightly and three severely dysplastic hips) hips improved compared with the second radiograph. In all, 55 (73.3%; 48 normal findings, seven with slight dysplasia) stayed on the same level. A deterioration was seen in six (8.0%; five normal findings into slight dysplasia and one slightly dysplastic hip into severe dysplasia) hips. The initial ultrasound hip type of the deteriorating hips was in four cases a hip type III and in two



**Fig. 5** Development after dislocation to normal findings of an infant with initial left hip type IV: initial ultrasound image, radiological control after 1.2 years (acetabular index (ACI) 22.7°) and 5.0 years (ACI 11.7°) ( $\alpha$ , alpha angle; \*, femoral head).



**Fig. 6** Development to a stable but still dysplastic hip of an infant with initial right hip type III: initial ultrasound image, radiological control after 1.2 years (acetabular index (ACI) 26.1°) and 5.5 years (ACI 26.9°) ( $\alpha$ , alpha angle; \*, femoral head).

cases a hip type IV and all cases did not show any deterioration before (Fig. 6). The five hips which deteriorated during the first interval remained at the same level in three cases and improved in two cases. In four cases a surgical therapy was recommended but was not accepted by the parents at this time. In all cases, which deteriorated, close follow-up radiographs were recommended. The interrater reliability showed a high accordance with 0.84.

#### ACI and CEA of the third radiograph

The hips were classified according to the CEA criteria in 63 (84.0%) cases as normal, in 11 (14.7%) cases as slightly pathological and in one (1.3%) case as severely pathological hips (Table 1). Hips with extremely pathological findings were not detected. The analysis of both parameters

(ACI and CEA) did not show significant differences ( $p = 0.442$ ). Accordance was given in 60 (80.0%) and inconsistency in 15 (20.0%) hips. In case of inconsistency, the CEA was rated better in 9/15 cases and worse in 6/15 cases.

#### AVN

An AVN of the femoral head type I was detected in only two hips in the second radiograph. Both cases had an ultrasound hip type IV initially.

## Discussion

This study is the first description of a radiological short-term outcome up to a mean age of 5.5 years of ultrasound unstable hips type D, III and IV which were successfully

**Table 1** Comparison of acetabular index (ACI) and centre-edge angle (CEA) of radiographs of children with unstable hips at mean age of 5.5 years (sd 9.9). No significant difference (n.s.) between ACI and CEA

Tönnis classification	ACI (%)	CEA (%)
Normal findings	60 (80.0)	63 (84.0)
Slight dysplasia/ slight pathologic	14 (18.7)	11 (14.7)
Severe dysplasia/ severe pathologic	1 (1.3)	1 (1.3)
Student's <i>t</i> -test	n.s. ( $p = 0.442$ )	-
Accordance	60/75 (80.0) vs 15/75 (20.0)	-

treated using the Tübingen splint according to a strict treatment protocol (see treatment protocol). Overall, the hips improved by 42.7% between the first and second radiological control and by 18.7% between the second and third control. Moreover, an increase of normal findings (31 to 60) and a decrease of severely dysplastic hips (13 to one) were observed. However, deteriorations were detected after the first and second radiograph (five to six). This supports the hypothesis that deteriorations – even in improved DDH – are possible until maturation of the hip joint. These developments were also seen in other studies that examined treatment of DDH with other treatment modalities. These results foster the recommendation of regular radiological follow-up examinations in numerous other studies.<sup>21,22</sup> Here, an improvement of unstable hips after treatment with the Tübingen splint up to the age of 48 months was seen. Currently, it can be assumed that the therapy of ultrasound unstable hips with the Tübingen splint is a good treatment option when started early. The Tübingen splint offers a number of advantages in comparison with other treatment options such as Fettweis plaster or Pavlik harness: the splint is easy to handle, easy to clean and adjustable depending on age and size of the child. Furthermore, the Fettweis plaster requires in-hospital treatment and short anaesthesia. Many surgeons also use invasive arthrography to confirm perfect reduction of the hip.<sup>10</sup> The Pavlik harness is considered to be complicated in handling and cleaning. Nevertheless, all of them – Tübingen splint, Fettweis plaster and Pavlik harness – show similar good success rates in treating unstable hip joints.<sup>23,24</sup>

AVN is a common complication and seems to be lower in the case treated with the Tübingen splint in comparison with other modalities, although a direct comparison is not possible due to the different study groups.<sup>25</sup> In our study, the AVN rate with 2.6% can be considered very low with only minor changes. But the complete AVN rate cannot be determined since this can only be detected after a longer observation period.

According to the leading expert opinion of the societies of paediatric orthopaedics, regular AP pelvic radiographs as control after initial therapy of unstable hips are mandatory.<sup>11</sup> Currently, this is the only way to identify

and subsequently treat persistent hip dysplasia or even deteriorated hips. Overall, DDH still represents the greatest risk factor for secondary osteoarthritis.<sup>26</sup> In addition, radiograph controls with modern technology have a very low radiation dose in children's radiology since the introduction of digital radiography and should be accepted when considering the advantages and disadvantages (e.g. secondary osteoarthritis) for the patients.<sup>27-29</sup> Our study also detected unexpected deteriorations in the radiograph control at varying time points which supports the recommendation for regular radiograph controls.

The analysis of ACI and CEA showed an agreement of 80% in the classifications with a tendency towards better results with CEA measurements but without statistical significance between ACI and CEA. Furthermore, there was no inconsistency of more than 1° of severity. Overall, both measurements and classifications revealed similar results. This is particularly important for further long-term studies, since the ACI may no longer be used in older age. However, it should be noted that the examinations are based on different classifications either ACI or CEA. Other limitations of this study are the absence of a control group and the limited comparisons with other studies due to different patient groups which were included in the studies, e.g. owing to age at diagnosis, age at treatment and different ultrasound hip types.

## Conclusion

This study shows a promising development of ultrasound unstable hips treated with the Tübingen splint in the early postnatal period until a mean age of 5.5 years. Nevertheless, there were unexpected deteriorations, which foster the need of regular radiological controls. The CEA is an alternative to the ACI at the age of four to eight years and enables follow-up studies of the same hips into adulthood.

Received 14 April 2020; accepted after revision 21 May 2020.

## COMPLIANCE WITH ETHICAL STANDARDS

### FUNDING STATEMENT

No benefits in any form have been received or will be received from a commercial party related directly or indirectly to the subject of this article.

### OA LICENCE TEXT

This article is distributed under the terms of the Creative Commons Attribution-Non Commercial 4.0 International (CC BY-NC 4.0) licence (<https://creativecommons.org/licenses/by-nc/4.0/>) which permits non-commercial use, reproduction and distribution of the work without further permission provided the original work is attributed.

### ETHICAL STATEMENT

**Ethical approval:** All procedures performed in studies involving human participants were in accordance with the ethical standards of the institutional and/or



national research committee and with the 1964 Helsinki declaration and its later amendments or comparable ethical standards (ethics committee vote of the university, study number: 2019-486).

**Informed consent:** Due to the retrospective nature of this study, informed patient consent was not required.

#### ICMJE CONFLICT OF INTEREST STATEMENT

None declared.

#### AUTHOR CONTRIBUTIONS

HK: Analyzed and interpreted data, Designed and wrote the paper.

LO: Acquired and analyzed data.

DL: Acquired data.

MH: acquired data.

ES: Acquired data.

HP: Analyzed data.

RK: Interpreted data, Designed and supervised the project.

BW: Interpreted data, Designed and supervised the project.

#### REFERENCES

- Swarup I, Penny CL, Dodwell ER.** Developmental dysplasia of the hip: an update on diagnosis and management from birth to 6 months. *Curr Opin Pediatr* 2018;30:84-92.
- Yang S, Zusman N, Lieberman E, Goldstein RY.** Developmental dysplasia of the hip. *Pediatrics* 2019;143:e20181147.
- Schams M, Labruyère R, Zuse A, Walensi M.** Diagnosing developmental dysplasia of the hip using the Graf ultrasound method: risk and protective factor analysis in 11,820 universally screened newborns. *Eur J Pediatr* 2017;176:1193-1200.
- Graf R.** Hip sonography: background; technique and common mistakes; results; debate and politics; challenges. *Hip Int* 2017;27:215-219.
- Bernau A.** The Tübingen hip flexion splint in the treatment of hip dysplasia. *Z Orthop Ihre Grenzgeb* 1990;128:432-435.
- Seidl T, Lohmaier J, Hölker T, et al.** Reduction of unstable and dislocated hips applying the Tübingen hip flexion splint? *Orthopade* 2012;41:195-199.
- Kubo H, Pilge H, Weimann-Stahlschmidt K, et al.** Use of the Tübingen splint for the initial management of severely dysplastic and unstable hips in newborns with DDH: an alternative to Fettweis plaster and Pavlik harness. *Arch Orthop Trauma Surg* 2018;138:149-153.
- Pavone V, Testa G, Riccioli M, et al.** Treatment of developmental dysplasia of hip with Tübingen hip flexion splint. *J Pediatr Orthop* 2015;35:485-489.
- Zajonz D, Strobel S, Wojan M, et al.** Pavlik harness for the treatment of congenital hip dysplasia types D III and IV. *Orthopade* 2016;45:72-80.
- Weber M, Morgenthaler M.** The treatment of hip dysplasia or dislocation with Fettweis' immobilization cast. *Z Orthop Ihre Grenzgeb* 1994;132:260-271.
- Sarkissian EJ, Sankar WN, Zhu X, Wu CH, Flynn JM.** Radiographic follow-up of DDH in infants: are x-rays necessary after a normalized ultrasound? *J Pediatr Orthop* 2015;35:551-555.
- Modaressi K, Erschbamer M, Exner GU.** Dysplasia of the hip in adolescent patients successfully treated for developmental dysplasia of the hip. *J Child Orthop* 2011;5:261-266.
- Multerer C, Döderlein L.** Congenital dysplasia and dislocation of the hip: proven and new procedures in diagnostics and therapy. *Orthopade* 2014;43:733-741.
- Li Y, Guo Y, Li M, et al.** Acetabular index is the best predictor of late residual acetabular dysplasia after closed reduction in developmental dysplasia of the hip. *Int Orthop* 2018;42:631-640.
- Firth GB, Robertson AJF, Ramguthy Y, Ramachandran M, Schepers A.** Prognostication in developmental dysplasia of the hip using the ossific nucleus center edge angle. *J Pediatr Orthop* 2018;38:260-265.
- Tschauner C, Klapsch W, Baumgartner A, Graf R.** Maturation curve of the ultrasonographic alpha angle according to Graf's untreated hip joint in the first year of life. *Z Orthop Ihre Grenzgeb* 1994;132:502-504.
- Miao M, Cai H, Hu L, Wang Z.** Retrospective observational study comparing the international hip dysplasia institute classification with the Tonnis classification of developmental dysplasia of the hip. *Medicine (Baltimore)* 2017;96:e5902.
- Tönnis D, Itoh K, Heinecke A, Behrens K.** The management of congenital hip luxation with arthrographic control, an individual risk-reducing and time-saving method. I. Choice of method and risk assessment based on arthrographic findings. *Z Orthop Ihre Grenzgeb* 1984;122:50-61.
- Tönnis D.** Röntgenuntersuchung und arthrographie des hüftgelenks im kleinkindesalter. *Orthopade* 1997;26:49-58.
- Kalamchi A, MacEwen GD.** Avascular necrosis following treatment of congenital dislocation of the hip. *J Bone Joint Surg [Am]* 1980;62-A:876-888.
- Kubo H, Pilge H, Nepp K, Westhoff B, Krauspe R.** Development of unstable hips after treatment with the Tübingen splint: mid-term follow-up of 83 hip joints. *Arch Orthop Trauma Surg* 2018;138:629-634.
- Dornacher D, Cakir B, Reichel H, Nelitz M.** Early radiological outcome of ultrasound monitoring in infants with developmental dysplasia of the hips. *J Pediatr Orthop B* 2010;19:27-31.
- Kubo H, Pilge H, Weimann-Stahlschmidt K, et al.** Use of the Tübingen splint for the initial management of severely dysplastic and unstable hips in newborns with DDH: an alternative to Fettweis plaster and Pavlik harness. *Arch Orthop Trauma Surg* 2018;138:149-153.
- Shaw KA, Moreland CM, Olszewski D, Schrader T.** Late acetabular dysplasia after successful treatment for developmental dysplasia of the hip using the Pavlik method: a systematic literature review. *J Orthop* 2018;16:5-10.
- Tönnis D.** Ischemic necrosis as a complication of treatment of C.D.H. *Acta Orthop Belg* 1990;56:195-206.
- Furnes O, Lie SA, Espehaug B, et al.** Hip disease and the prognosis of total hip replacements. A review of 53,698 primary total hip replacements reported to the Norwegian Arthroplasty Register 1987-99. *J Bone Joint Surg [Br]* 2001;83-B:579-586.
- Schmitz MR, Murtha AS, Clohisy JC, ANCHOR Study Group.** Developmental dysplasia of the hip in adolescents and young adults. *J Am Acad Orthop Surg* 2020;28:91-101.
- Mohammed Ali A, Hogg P, England A.** Dose optimisation in paediatric radiography - Using regression models to investigate the relative impact of acquisition factors on image quality and radiation dose. *Phys Med* 2019;68:61-68.
- Hernandez PA, Wells J, Usheva E, et al.** Early-onset osteoarthritis originates at the chondrocyte level in hip dysplasia. *Sci Rep* 2020;10:627.