



## CASE REPORT

# **REVISED** Case Report: Massive epistaxis from juvenile angiofibroma in an adolescent with severe haemophilia A [version 2; peer review: 3 approved]

Jose Florencio F. Lapeña , Olivia Agnes D. Mejia 

Otorhinolaryngology, Philippine General Hospital, University of the Philippines, Ermita, Manila, 1000, Philippines

**V2** First published: 05 Sep 2019, 8:1593  
<https://doi.org/10.12688/f1000research.20147.1>  
 Latest published: 04 Oct 2019, 8:1593  
<https://doi.org/10.12688/f1000research.20147.2>

## Abstract

Epistaxis may be profuse in individuals with normal bleeding parameters, but in an individual with haemophilia, it may be life-threatening. It is even more dangerous when epistaxis is caused by an undetected concomitant juvenile angiofibroma, and only one such case has been reported in the English literature. We report another case, of an 18-year-old Filipino adolescent with severe haemophilia A who was referred for repeated massive epistaxis. The epistaxis had been attributed to his haemophilia and managed with nasal packing, multiple blood transfusions and Factor VIII administration. After two years of unsuccessful management, nasal endoscopy was performed for the first time, revealing an intranasal mass. Imaging showed a right intranasal vascular tumour supplied mainly by the right sphenopalatine artery. He subsequently underwent preoperative embolization and endoscopic excision of the tumour with Factor VIII transfused pre-, intra-, and post-operatively, and recombinant Factor VII added post-operatively. Final histopathology was consistent with juvenile angiofibroma. There has been no nasal obstruction or recurrence of epistaxis seven years since the surgery. Clinicians should be more meticulous in assessing epistaxis in any patient with a bleeding disorder and investigate more subtle symptoms such as nasal obstruction. Verification of the source by direct visualization and ancillary diagnostic techniques (such as imaging) when indicated should be the standard of care for all patients presenting with epistaxis, whether or not a concomitant bleeding disorder exists. A high index of suspicion for juvenile angiofibroma should be maintained in adolescent males with epistaxis and nasal obstruction.


## Keywords

epistaxis, juvenile angiofibroma, haemophilia a, male adolescents, nasal endoscopy, nasal surgical procedures, computed tomography angiography

## Open Peer Review

Reviewer Status 

	Invited Reviewers		
	1	2	3
<b>version 2</b> (revision) 04 Oct 2019			
<b>version 1</b> 05 Sep 2019	 report	 report	 report

1. **Alberto Maria Saibene** , University of Milan, Milan, Italy
2. **J. Paul Moxham**, University of British Columbia, Vancouver, Canada
3. **Robert G. Berkowitz**, Royal Children's Hospital, Melbourne, Parkville, Australia

Any reports and responses or comments on the article can be found at the end of the article.

**Corresponding author:** Jose Florencio F. Lapeña ([jflapena@up.edu.ph](mailto:jflapena@up.edu.ph))

**Author roles:** **Lapeña JFF:** Conceptualization, Data Curation, Formal Analysis, Funding Acquisition, Supervision, Writing – Original Draft Preparation, Writing – Review & Editing; **Mejia OAD:** Conceptualization, Data Curation, Formal Analysis, Investigation, Resources, Visualization, Writing – Original Draft Preparation

**Competing interests:** No competing interests were disclosed.

**Grant information:** The authors applied for reimbursement of Article Processing Charges by the University of the Philippines Manila. *The funders had no role in study design, data collection and analysis, decision to publish, or preparation of the manuscript.*

**Copyright:** © 2019 Lapeña JFF and Mejia OAD. This is an open access article distributed under the terms of the [Creative Commons Attribution License](#), which permits unrestricted use, distribution, and reproduction in any medium, provided the original work is properly cited.

**How to cite this article:** Lapeña JFF and Mejia OAD. **Case Report: Massive epistaxis from juvenile angiofibroma in an adolescent with severe haemophilia A [version 2; peer review: 3 approved]** F1000Research 2019, 8:1593 <https://doi.org/10.12688/f1000research.20147.2>

**First published:** 05 Sep 2019, 8:1593 <https://doi.org/10.12688/f1000research.20147.1>

**REVISED Amendments from Version 1**

1. In response to Reviewer 3 (to emphasise that the prolonged hospitalisation was due to pre-operative problems), the Case presentation has added the statement "Post-operative recovery was uneventful, and the patient was discharged within a week of surgery (after two months in hospital)."

2. Following the recommendations of Reviewer 1, the statement "On the other hand, epistaxis guidelines<sup>5</sup> do recommend 'anterior rhinoscopy with headlight following nasal decongestion' escalating to 'rigid endoscopy or microscopy ... where anterior rhinoscopy fails to identify a bleeding point.'" was added to the Discussion, for which an additional reference<sup>6</sup> was cited:

National ENT Trainee Research Network. The British Rhinological Society multidisciplinary consensus recommendations on the hospital management of epistaxis. *J Laryngol Otol.* 2017;131(12):1142–1156. 10.1017/S0022215117002018.

**Any further responses from the reviewers can be found at the end of the article**

**Introduction**

Juvenile angiofibroma (JA) is a benign vascular tumour accounting for 0.5% of all head and neck neoplasms<sup>1</sup>. It occurs almost exclusively in adolescent males nine to 19-years-old, with a mean age at diagnosis of 15 years<sup>2</sup>. The clinical presentation involves unilateral epistaxis, nasal obstruction, and an intranasal mass. Epistaxis may be profuse and require nasal packing, vasopressors, antifibrinolytics and transfusions, even in individuals with normal bleeding parameters. However, with haemophilia, such epistaxis is more difficult to control and can be life-threatening. To our knowledge, only one case of JA in a haemophiliac has been reported in the English literature<sup>3</sup>. We report another case here.

**Case presentation**

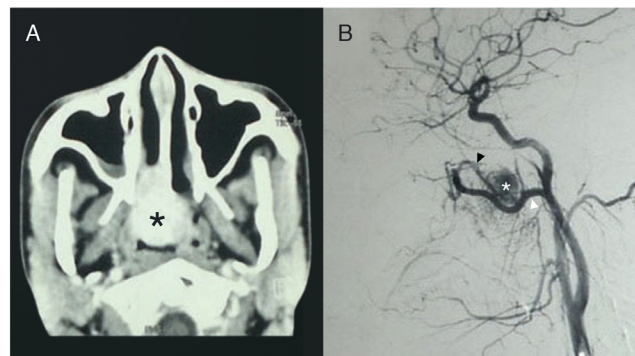
An 18-year-old male Filipino adolescent was referred to the Department of Otorhinolaryngology of the Philippine General Hospital for recurrent epistaxis. Previously diagnosed with severe haemophilia A at age 16, he initially presented with recurrent right nasal congestion and an episode of predominantly right-sided epistaxis described as sudden and profuse, amounting to 1500 ml. At that time, he was admitted to a provincial hospital and received blood and cryoprecipitate transfusions. Following discharge, epistaxis of 100 ml recurred almost daily, requiring nasal packs, repeated hospitalizations of one to two weeks in duration, and transfusions. Cryoprecipitate was often used to control the bleeding since plasma-derived Factor VIII (pFVIII) was seldom available due to shortage of supply and cost. His past history also included hemarthroses and gum bleeding since early childhood, but his symptoms were initially ignored and later only attributed to haemophilia although nasal congestion gradually progressed to obstruction.

After two years of such management, nasal endoscopy performed for the first time by a visiting otorhinolaryngologist revealed a right intranasal mass. He was referred to our institution and admitted with an impression of JA (Radkowski IA) and severe haemophilia A. Following admission, he suffered from

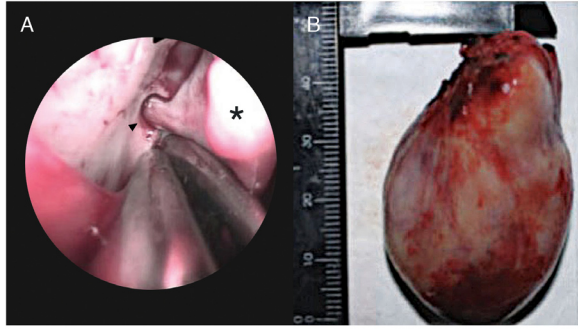
hypovolemic shock several times due to difficulty in acquiring blood, cryoprecipitate and Factor VIII. With previous Factor VIII Assay levels less than 1%, 1900 units of Factor VIII concentrate were empirically administered (calculated by weight) to raise levels to normal. His condition was compounded by development of Factor VIII antibodies because of previous, repeated cryoprecipitate transfusions in a suboptimal health-care setting. Although his baseline inhibitor titre had been negative, the preoperative inhibitor titre following multiple transfusions with various blood products was positive 3.5 Bethesda units (BU), necessitating pre-, intra- and post-operative transfusion with recombinant Factor VII (rFVIIa) in addition to higher doses of Factor VIII. Unfortunately, rFVIIa only became available post-operatively.

Contrast-enhanced computed tomography (CT) scans showed a hyperdense right intranasal mass corroborated by preoperative embolization angiography as an intranasal vascular tumour supplied by the right sphenopalatine artery and internal maxillary artery (IMA) (Figure 1A and 1B). The vast majority (90%) of the blood supply arose from distal sphenopalatine branches of the right IMA, while the remaining 10% came from both ascending pharyngeal arteries (Figure 1B).

Within 24 hours post-embolization, the patient underwent endoscopic surgery under general endotracheal anaesthesia with Sevoflurane. Factor VIII was given before, during, and after surgery, with recombinant Factor VII added post-operatively. Intraoperatively, a fleshy, vascular 4.7 × 3.2 × 2.7 cm mass was seen arising from the right sphenopalatine foramen. The sphenopalatine artery was cauterized and ligated, and the mass was delivered trans-orally (Figure 2A and 2B). Intraoperative blood loss was 300cc and post-operative bleeding was negligible. In total, the patient received 39,500 units of commercially available pFVIII, 24 mg of rFVIIa, 22 units of packed red blood cells (PRBC), 301 units of cryoprecipitate, 1 unit of whole blood



**Figure 1.** **A.** CECT Scan showing enhancing nasopharyngeal mass (asterisk) and **B.** Angiography showing vascular tumour (asterisk) supplied by sphenopalatine (black arrowhead) and internal maxillary (white arrowhead) arteries. Adobe Photoshop CC 20.01 release was used to erase identifying patient details, remove pixelated areas from black background, and enhance contrast to sharpen image (applied to entire image).

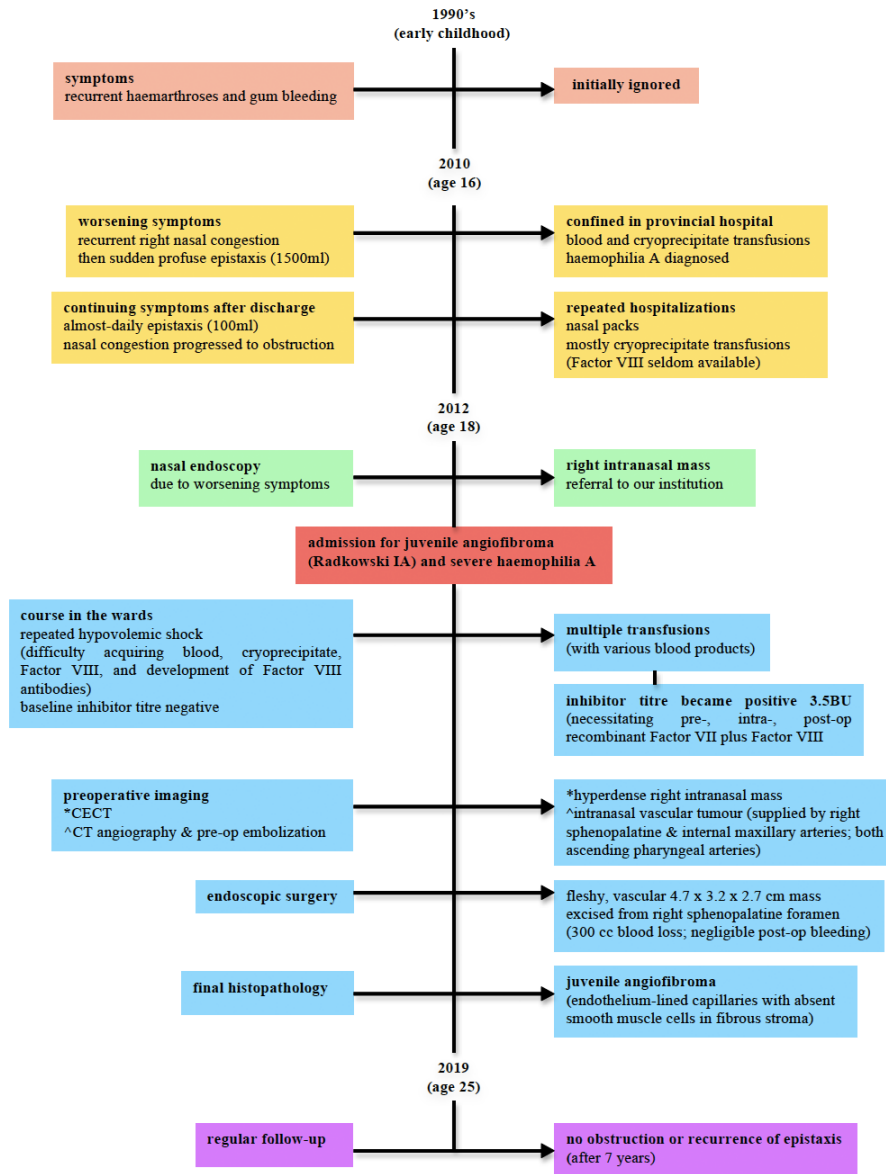


**Figure 2.** **A.** Intraoperative endoscopic view of the sphenopalatine artery (black arrowhead) supplying the mass (black asterisk) and **B.** Gross specimen measuring 4.7 × 3.2 × 2.7 cm. Adobe Photoshop CC 20.01 release was used to erase identifying patient details and sharpen the image (applied to entire image 2**B**).

and 3 units of fresh frozen plasma (FFP). Final haematoxylin-eosin stained histopathology findings showed endothelium-lined capillaries with absent smooth muscle cells in a fibrous stroma, consistent with JA. Post-operative recovery was uneventful and the patient was discharged within a week of surgery (after two months in hospital). He has followed up regularly, with no evidence of tumour on nasal endoscopy and no recurrence of nasal obstruction or epistaxis reported by the patient for seven years. He has completed a vocational course at college and is well. **Figure 3** summarizes the timeline.

**Discussion**

To our knowledge, there is only one previous case of JA and concomitant haemophilia in the English literature, twice reported by Ozturk *et al.* in 1999<sup>3</sup> and by Celiker *et al.* in 2004<sup>4</sup>. In their case, the preliminary diagnosis of JA was



**Figure 3.** Timeline summarising important information from the case presentation.

confirmed by biopsy at a different medical centre, where massive haemorrhage jeopardized the patient's life. On referral to their institution, preoperative embolization, surgical excision, and adequate Factor VIII replacement saved the patient<sup>4</sup>.

Similarly, significant risk to our patient's life was posed by delayed diagnosis from hasty attribution of epistaxis to haemophilia alone, and not the possibility of a vascular tumour such as JA. Per haemophilia management guidelines, the long history of "spontaneous bleeding into joints or muscles" in our patient corresponded to the baseline Factor VIII assay clotting factor level of "<1 IU/dL or <1% of normal" seen in severe haemophilia<sup>5</sup>. While recent-onset of bleeding from "mucous membranes in the mouth, gums, nose, and genitourinary tract" was serious, massive bleeding with "neck/throat" involvement was "life-threatening." This degree of epistaxis should not have been expected in patients with haemophilia A alone, where major bleeding from these areas only occurs 5–10% of the time<sup>5</sup>. Moreover, the symptom of nasal obstruction was long-overlooked. Unfortunately, two full years passed before the underlying tumour was discovered.

Current haemophilia guidelines<sup>5</sup> advise otolaryngologist referral only for "persistent or recurrent" epistaxis, but the emphasis in this recommendation is for control of bleeding only and not to investigate a different underlying cause such as JA. On the other hand, epistaxis guidelines<sup>6</sup> do recommend "anterior rhinoscopy with headlight following nasal decongestion" escalating to "rigid endoscopy or microscopy ... where anterior rhinoscopy fails to identify a bleeding point." Our experience demonstrates that vascular lesions causing epistaxis may

remain undetected when presumptively attributed to pre-existing bleeding disorders and are likely to remain undetected unless sought.

In conclusion, although haemophilia guidelines do not mention vascular lesions such as JA, a high index of suspicion should be maintained in adolescent males with epistaxis and nasal obstruction. Per epistaxis guidelines, clinicians should carefully assess the cause of epistaxis in any patient with a bleeding disorder, and direct visualization of the source should be attempted (and verified by ancillary diagnostic techniques such as imaging when indicated) in all patients with epistaxis, regardless of the presence of a concomitant bleeding disorder.

### Data availability

All data underlying the results are available as part of the article and no additional data are required.

### Consent

Written informed consent for publication of his clinical details and clinical images was obtained from the patient.

---

### Acknowledgements

We acknowledge Dr. Arsenio Claro A. Cabungcal and Dr. Alzhes R. Buelva for their surgical contributions to patient care, Dr. Cheryl Lyn A. Diez for her expertise in haematology that made the surgery possible, and Mary Angeline R. Bagabaldo for her expert assistance with the deidentification, contrast-improvement, sharpening, labelling, and layout of the Figures.

### References

1. Lund VJ, Stammberger H, Nicolai P, *et al.*: **European position paper on endoscopic management of tumours of the nose, paranasal sinuses and skull base.** *Rhinol Suppl.* 2010; **22**: 1–143.  
[PubMed Abstract](#)
2. Nicolai P, Schreiber A, Bolzoni Villaret A: **Juvenile angiofibroma: evolution of management.** *Int J Pediatr.* 2012; **2012**: 412545.  
[PubMed Abstract](#) | [Publisher Full Text](#) | [Free Full Text](#)
3. Oztürk MA, Haznedaroğlu IC, Oztürk MH, *et al.*: **Nasopharyngeal angiofibroma in a patient with haemophilia A: a bleeding tumour in a bleeding-prone patient.** *Haemophilia.* 1999; **5**(3): 207–8.  
[PubMed Abstract](#) | [Publisher Full Text](#)
4. Celiker V, Basgul E, Karagoz AH, *et al.*: **Anesthesia in a patient with nasopharyngeal angiofibroma and hemophilia A.** *J Cardiothorac Vasc Anesth.* 2004; **18**(6): 819.  
[PubMed Abstract](#) | [Publisher Full Text](#)
5. Srivastava A, Brewer AK, Mauser-Bunschoten EP, *et al.*: **Guidelines for the management of hemophilia.** *Haemophilia.* 2013; **19**(1): e1–47.  
[PubMed Abstract](#) | [Publisher Full Text](#)
6. National ENT Trainee Research Network: **The British Rhinological Society multidisciplinary consensus recommendations on the hospital management of epistaxis.** *J Laryngol Otol.* 2017; **131**(12): 1142–1156.  
[PubMed Abstract](#) | [Publisher Full Text](#)

# Open Peer Review

Current Peer Review Status:   

---

Version 1

Reviewer Report 24 September 2019

<https://doi.org/10.5256/f1000research.22132.r53497>

© 2019 Berkowitz R. This is an open access peer review report distributed under the terms of the [Creative Commons Attribution License](#), which permits unrestricted use, distribution, and reproduction in any medium, provided the original work is properly cited.



**Robert G. Berkowitz**

Department of Otolaryngology, Royal Children's Hospital, Melbourne, Parkville, Vic, Australia

The authors report a case of juvenile angiofibroma (JA) occurring in a patient with haemophilia, where severe epistaxes were ascribed to the bleeding disorder and no underlying cause was sought for a period of two years. Following transfer to the author's institution, the JA was managed successfully by surgery with pre-operative embolisation and optimisation of haemophilia therapy. There were no surgical complications and the patient has remained symptom free after long term follow-up.

This represents only the second reported case of JA occurring in a patient with haemophilia. The report underscores the importance of considering a separate explanation for epistaxis in a patient with an underlying coagulopathy, and particularly where there are other symptoms suggestive of intra-nasal pathology.

The article is well written and carries a clear message. Minor points for the authors to consider providing further information are:

- It is implied, but not actually stated, that during the two year period where the JA was overlooked, the patient's haemophilia was poorly controlled (which presumably contributed to overlooking the diagnosis of JA). Is this the case?
- If treatment proceeded uneventfully, why did the patient require hospitalisation for a period of 2 months?

**Is the background of the case's history and progression described in sufficient detail?**

Yes

**Are enough details provided of any physical examination and diagnostic tests, treatment given and outcomes?**

Yes

**Is sufficient discussion included of the importance of the findings and their relevance to**



**future understanding of disease processes, diagnosis or treatment?**

Yes

**Is the case presented with sufficient detail to be useful for other practitioners?**

Yes

**Competing Interests:** No competing interests were disclosed.

**Reviewer Expertise:** paediatric otolaryngology and airway disorders

**I confirm that I have read this submission and believe that I have an appropriate level of expertise to confirm that it is of an acceptable scientific standard.**

Author Response 02 Oct 2019

**Jose Florencio Lapeña**, University of the Philippines, Ermita, Manila, Philippines

We thank the reviewer for his kind review and for raising minor (but important) points for consideration:

1. *"It is implied, but not actually stated, that during the two year period where the JA was overlooked, the patient's haemophilia was poorly controlled (which presumably contributed to overlooking the diagnosis of JA). Is this the case?"*

Yes, *"during the two year period where the JA was overlooked, the patient's haemophilia was poorly controlled (which presumably contributed to overlooking the diagnosis of JA)."* We were hoping the first paragraph conveyed a sense of this poor control without being overly dramatic. As mentioned in the Case presentation, this can be attributed to inadequate factor VIII replacement therapy (*"seldom available due to shortage of supply and cost"*).

Indeed, *"this makes the case even more interesting, and highlights that not only when there is a known coagulopathy present, and even when it is not being adequately treated, a possible intra-nasal cause should still be considered."*

2. *"If treatment proceeded uneventfully, why did the patient require hospitalisation for a period of 2 months?"*

I hope we did not give the impression that *"treatment proceeded uneventfully."* Our *"patient require(d) hospitalisation for a period of 2 months"* because of a very stormy preoperative course wherein *"he suffered from hypovolemic shock several times due to difficulty in acquiring blood"* and blood products, and *"his condition was compounded by development of Factor VIII antibodies."* He also *"received 39,500 units of commercially available pFVIII, 24 mg of rFVIIa, 22 units of packed red blood cells (PRBC), 301 units of cryoprecipitate, 1 unit of whole blood and 3 units of fresh frozen plasma (FFP)."*

We have revised the Case presentation by adding the statement *"Post-operative recovery was uneventful and the patient was discharged within a week of surgery (after two months in hospital)."* to clarify that the prolonged hospitalisation was due to the stormy pre-operative course.

**Competing Interests:** We have no competing interests to disclose.

Reviewer Report 23 September 2019

<https://doi.org/10.5256/f1000research.22132.r53498>

© 2019 Moxham J. This is an open access peer review report distributed under the terms of the [Creative Commons Attribution License](#), which permits unrestricted use, distribution, and reproduction in any medium, provided the original work is properly cited.



**J. Paul Moxham**

Division of Otolaryngology-Head and Neck Surgery, University of British Columbia, Vancouver, BC, Canada

This is an excellent and well written case report about a young adult with a hematologic disorder and a coexisting angiofibroma. It delves into the difficulties this case presents to the treating surgeon, reviews the relevant literature (of which there is only one previous report), and reminds us that just because someone has a bleeding disorder does not mean they cannot also have a rare vascular tumour.

**Is the background of the case's history and progression described in sufficient detail?**

Yes

**Are enough details provided of any physical examination and diagnostic tests, treatment given and outcomes?**

Yes

**Is sufficient discussion included of the importance of the findings and their relevance to future understanding of disease processes, diagnosis or treatment?**

Yes

**Is the case presented with sufficient detail to be useful for other practitioners?**

Yes

**Competing Interests:** No competing interests were disclosed.

**Reviewer Expertise:** I am an Academic Pediatric Otolaryngologist at BC Children's Hospital and an Associate Clinical Professor of Surgery at the University of British Columbia in Vancouver, Canada. I am a member of the Triological Society and the American Society of Pediatric Otolaryngology. My main areas of interest are bone growth factors in craniofacial models.

**I confirm that I have read this submission and believe that I have an appropriate level of expertise to confirm that it is of an acceptable scientific standard.**



Author Response 02 Oct 2019

**Jose Florencio Lapeña**, University of the Philippines, Ermita, Manila, Philippines

We thank the reviewer for his clear and concise review, recapitulating the main theme and "take-home" message of our case report "*that just because someone has a bleeding disorder does not mean they cannot also have a rare vascular tumour.*"

**Competing Interests:** We have no competing interests to disclose.

Reviewer Report 09 September 2019

<https://doi.org/10.5256/f1000research.22132.r53496>

© 2019 Saibene A. This is an open access peer review report distributed under the terms of the [Creative Commons Attribution License](#), which permits unrestricted use, distribution, and reproduction in any medium, provided the original work is properly cited.



**Alberto Maria Saibene** 

Department of Otolaryngology, San Paolo Hospital, University of Milan, Milan, Italy

The Authors present a compelling case report where the concomitance of a rare sinonasal vascular tumour, i.e. a juvenile angiofibroma, and haemophilia A delayed diagnosis and complicated clinical management. As the authors correctly demonstrate in the report, a sub-optimal healthcare setting led to haemophilia first diagnosis delay and, foremost, delayed the identification of the neoplasm despite the recurrence of profuse bleeding.

The article is well written, both by a grammar and literary standpoint, and present all clinical information on diagnosis and management in a complete fashion.

The clinical management is sound and clinical decisions are consistent with current guidelines and good clinical practice.

The article could be publishable in this present form, but I'd like to point out a couple of ideas that might add some teaching relevance to the article:

- First of all, it might be worth mentioning that in good rhinologic practice, performing sinonasal tumors biopsies without adequate imaging can result to harmful or fatal incidents. Had the clinicians decided to perform a biopsy in an outpatient setting, a massive epistaxis could have led to serious complications for this patient, without helping further clinical decisions. This is the case of the - correctly cited - case report already published by Ozturk.
- Secondly, while it is true that haemophilia guidelines do not advise routine evaluation for epistaxis, on the other hand epistaxis guidelines<sup>1</sup> do recommend for a thorough evaluation of the patient in order to identify the bleeding source in all case, starting with anterior rhinoscopy and escalating to nasal endoscopy whenever the source of bleeding cannot be easily identified. Therefore, it is worth mentioning that correct management of all epistaxis cases required identification of the bleeding source.

- Last, while the CT scan the authors provided allows a good depiction of the clinical picture, it would be interesting to see whether the CT scans showed enlargement of the sphenopalatine foramen. While such enlargement is not constant in all JA patients, an enlargement >3mm in presence of a unilateral sinonasal mass can point the diagnosis towards JA.

In conclusion, this is an extremely interesting article well deserving publication, with an interesting teaching value that could be further increased with some more information as above stated.

## References

1. National ENT Trainee Research Network: The British Rhinological Society multidisciplinary consensus recommendations on the hospital management of epistaxis. *J Laryngol Otol.* **131** (12): 1142-1156 [PubMed Abstract](#) | [Publisher Full Text](#)

### Is the background of the case's history and progression described in sufficient detail?

Yes

### Are enough details provided of any physical examination and diagnostic tests, treatment given and outcomes?

Yes

### Is sufficient discussion included of the importance of the findings and their relevance to future understanding of disease processes, diagnosis or treatment?

Yes

### Is the case presented with sufficient detail to be useful for other practitioners?

Yes

**Competing Interests:** No competing interests were disclosed.

**Reviewer Expertise:** Otolaryngology, rhinology, head and neck surgery

**I confirm that I have read this submission and believe that I have an appropriate level of expertise to confirm that it is of an acceptable scientific standard.**

Author Response 02 Oct 2019

**Jose Florencio Lapeña**, University of the Philippines, Ermita, Manila, Philippines

We thank the reviewer for his excellent review and valuable comments and recommendations:

1. *"First of all, it might be worth mentioning that in good rhinologic practice, performing sinonasal tumors biopsies without adequate imaging can result to harmful or fatal incidents. Had the clinicians decided to perform a biopsy in an outpatient setting, a massive epistaxis could have led to serious complications for this patient, without helping further clinical decisions. This is the case of the - correctly cited - case report already published by Ozturk."*

Yes, indeed. A biopsy in the case of our patient would have been catastrophic (and we have witnessed this happen to patients of other unsuspecting physicians). Any nasal mass suspicious for angiofibroma should not be manipulated (unless in the operating theatre under double set-up). However, we felt that mentioning this important management caveat would detract from the main message of initial diagnosis necessitating visualising the bleeding source (directed toward general practitioners, primary care providers, family physicians, and paediatricians), and opted to reiterate the point in our response to the review instead.

2. *"Secondly, while it is true that haemophilia guidelines do not advise routine evaluation for epistaxis, on the other hand epistaxis guidelines (1) do recommend for a thorough evaluation of the patient in order to identify the bleeding source in all case, starting with anterior rhinoscopy and escalating to nasal endoscopy whenever the source of bleeding cannot be easily identified. Therefore, it is worth mentioning that correct management of all epistaxis cases required identification of the bleeding source."*

We have added the statement *"On the other hand, epistaxis guidelines(6) do recommend 'anterior rhinoscopy with headlight following nasal decongestion' escalating to 'rigid endoscopy or microscopy ... where anterior rhinoscopy fails to identify a bleeding point.' "* to the Discussion, for which the additional reference (6) provided by the reviewer was cited:

National ENT Trainee Research Network. The British Rhinological Society multidisciplinary consensus recommendations on the hospital management of epistaxis. *J Laryngol Otol.* 2017;131(12):1142-1156. 10.1017/S0022215117002018.

3. *"Last, while the CT scan the authors provided allows a good depiction of the clinical picture, it would be interesting to see whether the CT scans showed enlargement of the sphenopalatine foramen. While such enlargement is not constant in all JA patients, an enlargement >3mm in presence of a unilateral sinonasal mass can point the diagnosis towards JA."*

We totally agree that the educational value of the article can be enhanced by mentioning that *"in the presence of a unilateral sinonasal mass,"* such an enlargement of the sphenopalatine foramen *"can point to the diagnosis of JA."* However (and in relation to the first point above), we opted to maintain the primary focus of our discussion and perhaps encourage our non-otolaryngologist colleagues to consider urgent referrals to ENT surgeons following initial diagnosis in such cases.

**Competing Interests:** We have no competing interests to disclose.

The benefits of publishing with F1000Research:

- Your article is published within days, with no editorial bias
- You can publish traditional articles, null/negative results, case reports, data notes and more
- The peer review process is transparent and collaborative
- Your article is indexed in PubMed after passing peer review
- Dedicated customer support at every stage

For pre-submission enquiries, contact [research@f1000.com](mailto:research@f1000.com)

**F1000Research**