

Transiently elevated estimated pulmonary pressures in a patient with complete heart block undergoing permanent pacing: a case report

Robert Harvey *, Adrian Chong, John Hill, and Dariusz Korczyk

Cardiology Department, Princess Alexandra Hospital, 199 Ipswich Road, Woolloongabba, Brisbane, Queensland 4102, Australia

Received 31 October 2019; first decision 4 December 2019; accepted 12 March 2020; online publish-ahead-of-print 26 May 2020

Background

Complete heart block (CHB) is a frequent cause for acute admission in older patients with significant cardiac conduction disease. Common presenting symptoms are syncope and dyspnoea. Some patients may exhibit clinical and radiological signs of left ventricular (LV) decompensation, despite preserved LV ejection fraction on transthoracic echocardiography (TTE) and absent pre-existing LV dysfunction.

Case summary

In this clinical report, we present a case of CHB associated with transient but severe elevation in pulmonary artery systolic pressure, measured as the equivalent right ventricular systolic pressure (RVSP = 99 mmHg) by TTE in the absence of right ventricular outflow tract obstruction, that subsequently 'normalized' after implantation of a permanent pacemaker. After searching our echocardiogram database, we did find other cases with similar findings.

Discussion

There is limited literature describing transient acute elevation in estimated pulmonary pressures in the setting of new CHB that is subsequently reversed by permanent pacing. The true prevalence and mechanism of transient estimated pulmonary pressure as a result of CHB remains unknown. Based on our limited assessment, we postulate that the acute elevation in estimated pulmonary pressures is predominantly related to a compensatory augmentation of RV stroke volume and is caused by the underlying bradycardia and need to maintain forward cardiac output. This phenomenon may require further investigation and validation in future studies.

Keywords

Complete heart block • Pulmonary hypertension • Echocardiogram • RVSP • Permanent pacemaker
• Case report • Stroke volume

Learning points

- There is limited literature describing transient acute elevation in estimated pulmonary pressure in the setting of new complete heart block (CHB) that is subsequently reversed by permanent pacing.
- Alterations in intracardiac flows and pressures because of atrioventricular (AV) dissociation due to CHB are plausible underpinning mechanisms for transient elevation in estimated pulmonary pressure in this state, since both symptoms and deranged haemodynamics often resolve after restoration of synchronous AV conduction with dual-chamber pacing.
- Marked increases found in the right ventricular outflow tract velocity-time integral measurements in CHB would indicate a significant increase in right-sided stroke volume and therefore blood flow through the pulmonary vasculature as a compensatory response to maintain adequate cardiac output during periods of bradycardia.

* Corresponding author. Tel: +61 419856445, Email: robert.harvey@health.qld.gov.au

Handling Editor: Alexander Ghanem

Peer-reviewers: Subhi Akleh, Georgia Daniel, and Suzan Hatipoglu

Compliance Editor: Rahul Mukherjee

Supplementary Material Editor: Ross Thomson

© The Author(s) 2020. Published by Oxford University Press on behalf of the European Society of Cardiology.

This is an Open Access article distributed under the terms of the Creative Commons Attribution Non-Commercial License (<http://creativecommons.org/licenses/by-nc/4.0/>), which permits non-commercial re-use, distribution, and reproduction in any medium, provided the original work is properly cited. For commercial re-use, please contact journals.permissions@oup.com

Introduction

Complete heart block (CHB) is a frequent cause for acute admission in older patients with significant cardiac conduction disease. Common presenting symptoms are syncope and dyspnoea. Some patients may exhibit clinical and radiological signs of left ventricular (LV) decompensation, despite preserved LV ejection fraction on transthoracic echocardiography (TTE) and absent pre-existing LV dysfunction. Alterations in intracardiac flows and pressures because of atrioventricular (AV) dissociation due to CHB are plausible underpinning mechanisms since both symptoms and deranged haemodynamics often resolve after restoration of synchronous AV conduction with dual-chamber pacing. In this clinical report we present a case of CHB associated with transient but severe elevation in estimated pulmonary artery systolic pressure, measured as the equivalent right ventricular systolic pressure (RVSP) by TTE in the absence of right ventricular outflow tract (RVOT) obstruction, that subsequently 'normalized' after implantation of a permanent pacemaker (PPM).

Timeline

1 week prior to presentation	Insidious onset of dyspnoea and lethargy
Upon presentation	Complete heart block on presenting ECG as well as evidence of left ventricular failure on chest x-ray. An isoprenaline infusion was commenced
Day 1 of admission	Transthoracic echocardiogram (TTE) was performed which revealed markedly elevated estimated pulmonary artery pressures. A permanent pacemaker was then placed
4 weeks post-discharge	TTE was repeated—estimated pulmonary artery pressures had normalized. Normal pulmonary artery and right heart pressures and dynamics were confirmed on right heart catheterization

Case presentation

A 68-year-old female with no previous medical history or comorbidities was admitted with a 1-week history of progressive dyspnoea in the context of CHB disclosed by 12-lead electrocardiogram (ECG). There were no clinical examination findings suggestive of pulmonary hypertension but there was evidence of LV failure. She was commenced on an intravenous infusion of isoprenaline for chronotropic support. A TTE was performed to exclude structural heart disease and confirmed normal biventricular size and systolic function. There was, however, moderate tricuspid regurgitation (TR) and her peak TR jet

velocity (TR vel) was measured at 4.6 m/s resulting in an estimated RVSP of 99 mmHg [assuming a mean right atrial pressure (RAP) of 15 mmHg]. Interestingly, her RVOT velocity-time integral (VTI) was also incidentally noted to be significantly elevated at 23.9 cm (see [Figure 1](#)). An urgent computed tomography pulmonary angiogram reported no evidence of pulmonary embolism (PE) and, importantly, demonstrated no evidence of pulmonary arterial dilatation that is often associated with chronic pulmonary hypertension. She proceeded on to implantation of a permanent dual-chamber PPM with no complications.

The patient returned for further invasive assessment of her possible pulmonary hypertension 4 weeks later. Her repeat TTE revealed reductions in TR severity to mild, TR vel to 2.9/s, with parallel decreases in her RAP to 3 mmHg and estimated RVSP to 37 mmHg. Her RVOT VTI was similarly measured lower at 14 cm. Right heart catheterization (RHC) confirmed relatively normal pulmonary haemodynamics with an invasive mean RAP of 4 mmHg, pulmonary arterial systolic/diastolic pressures of 20/6 mmHg, mean pulmonary arterial pressure of 12 mmHg, mean pulmonary capillary wedge pressure of 3 mmHg, cardiac output (by thermodilution) of 4.4 L/min, and calculated pulmonary vascular resistance (PVR) of 2.0 Wood units.

We subsequently reviewed our echocardiographic database and identified 250 patients who had CHB and underwent pre-PPM implantation TTE studies. Two further patients from this cohort with both baseline and post-PPM TTEs demonstrated similar haemodynamic profiles of initial elevation in TR vel, RAP, RVSP, and RVOT VTI, which then significantly improved post-restoration of AV synchrony by permanent pacing (see [Table 1](#)).

Discussion

There is limited literature describing transient elevation in estimated pulmonary artery pressure in the setting of new CHB that is subsequently reversed by permanent pacing. An animal study with a rat model assessing the effects of CHB on myocardial function, morphology, and energy metabolism observed a 2.5-fold increase in pulsed-wave Doppler velocities in the pulmonary artery consistent with increased stroke volume but did not document changes in TR vel or pulmonary pressures.² Stack et al.³ performed invasive RHC in eight patients with CHB and studied their intracardiac haemodynamics both at baseline and with intravenous isoprenaline infusions. Four (50%) patients exhibited elevated baseline RV systolic/diastolic pressures, systemic/pulse pressures, and systemic/PVRs along with increased stroke volumes. Isoprenaline resulted in mild increases in RV and pulmonary arterial pressures but also significant improvement in cardiac output with a corresponding fall in PVR values. No assessment of left atrial pressure (LAP) was undertaken.

The TTE parameters observed in this small series of patients with CHB and associated transient elevation in estimated pulmonary pressures offer potential mechanistic insights into the effects of AV uncoupling on intracardiac haemodynamics. Marked increases in the RVOT VTI in CHB would indicate a significant increase in right-sided stroke volume and therefore blood flow through the pulmonary

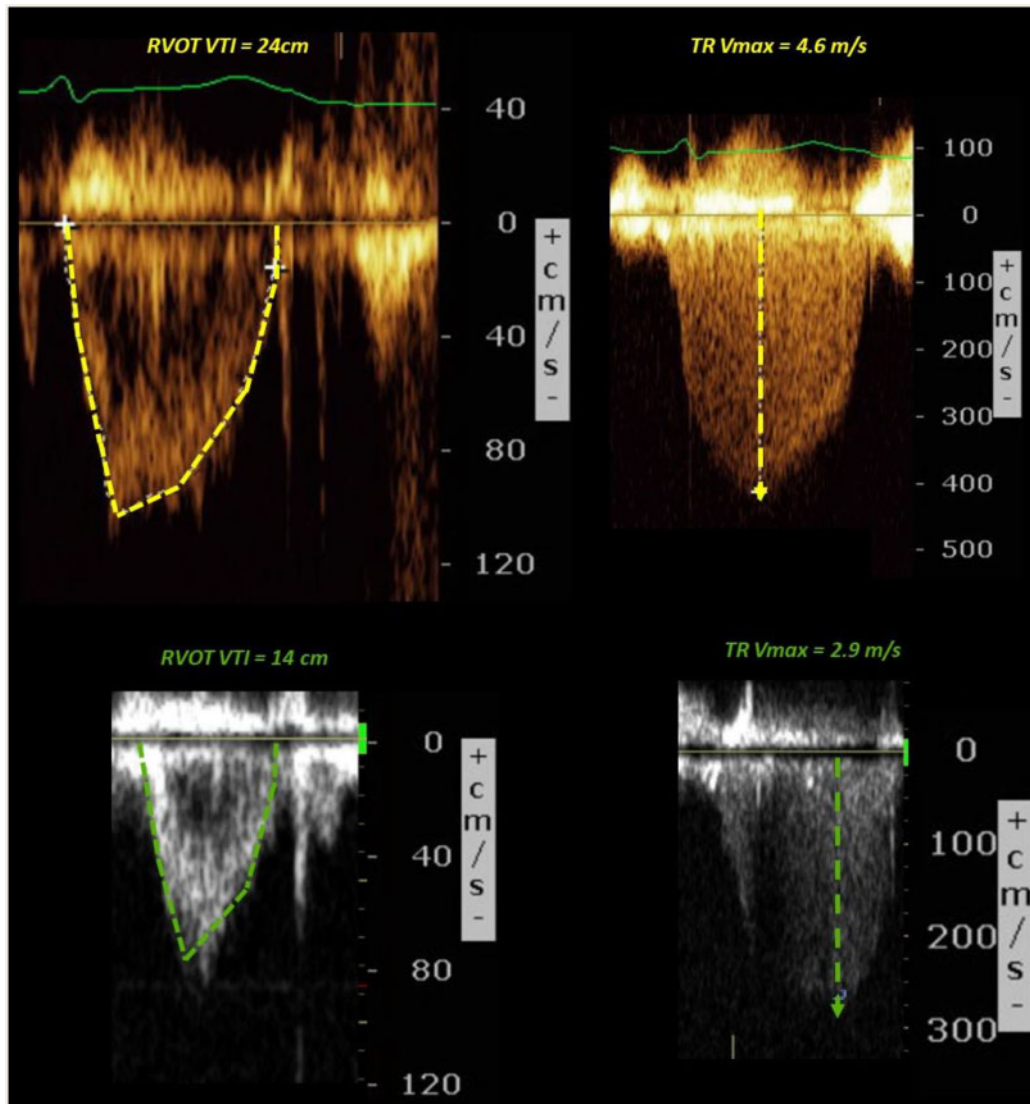


Figure 1 Right ventricular outflow tract velocity-time integral and tricuspid regurgitation Vmax in complete heart block (top) and then post-pacing (bottom).

vasculature as a compensatory response to maintain adequate cardiac output during periods of bradycardia. Non-invasive TTE estimation of PVR ($10 \times \text{TR vel}/\text{RVOT VTI}$) consistently demonstrated normal values and therefore no evidence of pulmonary vascular remodelling to suggest the presence of chronic pulmonary hypertension.⁴ It is possible that the patients with CHB who develop elevated estimated pulmonary pressures in response have impaired adaptation of pulmonary arterial relaxation to increased volume loading.⁵

However, this hypothesis does not entirely account for the pulmonary venous congestion that can complicate the clinical presentation of CHB. Volume loading in CHB may exacerbate pre-existing LV diastolic dysfunction. Impaired AV mechanical coupling, even with PR interval prolongation and preserved 1:1 AV conduction, can compromise

effectiveness of LV filling resulting in increased LAP, which can cause dyspnoea, and diastolic mitral valve regurgitation.⁶ So, it is reasonable to propose that these effects are amplified when the LA and LV are completely uncoupled in CHB. Unfortunately, TTE assessment of LAP by conventional diastolic parameters (including E/e') has not been validated in CHB, precluding its utility in our series of patients.⁷ Similarly, the use of the pulmonary to left atrial ratio, which would have been useful to differentiate pre- from post-capillary pulmonary hypertension, could not be applied.⁸ Nonetheless, the combination of ventricular volume loading due to bradycardia and elevated LAP due to AV dissociation may account for the elevation of estimated pulmonary pressures, pulmonary congestion, and therefore rapid reversibility with corrective AV-synchronous pacing.

Table 1 Echocardiographic parameters pre- and post-pacing in three patients

TTE parameter (pre-/post-PPM)	Case 1	Case 2	Case 3
TR vel	4.6/2.9	3.7/3.0	3.3/2.5
RVSP	99/36	64/39	47/29
RAP	15/3	8/3	3/3
mPAP	62/24	41/26	31/20
RVOT VTI	23.9/14	22.8/16.4	25/16
PVR	1.9/2.1	1.6/1.8	1.3/1.6
e' septal	16.9/10.8	6/4.7	9.4/6.5
E/e' septal	10/8	25/15	10/9
LAVI	63/46	76/63	46/40
RVS'	19/12	13/13	21/14
LVEF	75/60	60/57	65/60

E/e' septal, ratio of the mitral inflow E-velocity to e' septal (unitless); e' septal, early diastolic mitral annular velocity by pulsed-wave tissue Doppler (cm/s); LAVI, left atrial volume indexed for body surface area (mL/m²); LVEF, left ventricular ejection fraction (%); mPAP, mean pulmonary artery pressure as calculated by $[(0.61 \times \text{RVSP}) + 2]$ (mmHg)¹; PPM, permanent pacemaker; PVR, pulmonary vascular resistance (Wood units); RAP, right atrial pressure (mmHg); RVOT VTI, right ventricular outflow tract velocity-time integral (cm); RVS', peak systolic velocity of the tricuspid annulus by pulsed-wave tissue Doppler (cm/s); RVSP, right ventricular systolic pressure (mmHg); TR vel, tricuspid regurgitant jet peak velocity (m/s); TTE, transthoracic echocardiography.

Conclusion

The true prevalence and mechanism of transient elevation in estimated pulmonary artery pressure as a result of CHB remains unknown. Based on our limited assessment, we postulate that the acute elevation in estimated pulmonary pressures is predominantly related to a compensatory augmentation of RV stroke volume and is caused by the underlying bradycardia and need to maintain forward cardiac output. There also exists an undefined contribution from increase in LAP by several possible mechanisms consequent on loss of AV synchrony. This phenomenon may require further investigation and validation in future studies. From a practical point of view, the finding of unexplained elevation in estimated pulmonary artery pressure in patients with CHB warrants exclusion of PE in patients with pre-existing left bundle branch abnormality, and echocardiographic reassessment after PPM implantation. Restoration of ventricular rate and AV coupling by appropriate pacing may resolve the elevation in estimated pulmonary artery pressure, avoiding the need for further extensive and costly down-stream testing.

Lead author biography



Dr Robert Harvey is a final year Cardiology Advanced Trainee Registrar from the Princess Alexandra Hospital in Brisbane, Australia. He began dual training in Intensive Care Medicine and Physician training and then moved to specialize in Cardiology. He will complete training and attain his Cardiology Fellowship in the year 2020.

Supplementary material

Supplementary material is available at *European Heart Journal - Case Reports* online.

Slide sets: A fully edited slide set detailing this case and suitable for local presentation is available online as [Supplementary data](#).

Consent: The author/s confirm that written consent for submission and publication of this case report including image(s) and associated text has been obtained from the patient in line with COPE guidance.

Conflict of interest: none declared.

References

- Chemla D, Castelain V, Humbert M, Hebert JL, Simonneau G, Lecarpentier Y, Herve P. New formula for predicting mean pulmonary artery pressure using systolic pulmonary artery pressure. *Chest* 2004;**126**:1313–1317.
- Gizurason S, Lorentzon M, Ramunddal T, Waagstein F, Bergfeldt L, Omerovic E. Effects of complete heart block on myocardial function, morphology, and energy metabolism in the rat. *Eurospace* 2007;**9**:411–416.
- Stack M, Rader B, Sobol B, Farber S, Eichna L. Cardiovascular hemodynamic functions in complete heart block and the effect of isopropyl norepinephrine. *Circulation* 1958;**17**:526–536.
- Abbas AE, Franey LM, Marwick T, Maeder MT, Kaye D, Vlahos AP, Serra W, Al-Azizi K, Schiller NB, Lester SJ. Noninvasive assessment of pulmonary vascular resistance by Doppler Echocardiography. *J Am Soc Echocardiogr* 2013;**26**:1170–1177.
- Komori A, Ayusawa M, Kato M, Nakamura T, Takahashi S. Congenital complete atrioventricular block with pulmonary hypertension. *Pediatr Int* 2017;**59**:1095–1096.
- Barold SS, Ilcicil A, Leonelli F, Herweg B. First-degree atrioventricular block. *J Interv Card Electrophysiol* 2007;**17**:139–152.
- Nagueh SF, Smiseth OA, Appleton CP, Byrd BF, Dokainish H, Edvardsen T, Flachskampf FA, Gillebert TC, Klein AL, Lancellotti P, Marino P, Oh JK, Popescu BA, Waggoner AD. Recommendations for the evaluation of left ventricular diastolic function by echocardiography: an update from the American Society of Echocardiography and the European Association of Cardiovascular Imaging. *J Am Soc Echocardiogr* 2016;**29**:277–314.
- Scalia GM, Scalia IG, Kierle R, Beaumont R, Cross DB, Feenstra J, Burstow DJ, Fitzgerald BJ, Platts DG. ePLAR—The echocardiographic pulmonary to left atrial ratio—a novel non-invasive parameter to differentiate pre-capillary and post-capillary pulmonary hypertension. *Int J Cardiol* 2016;**212**:379–386.