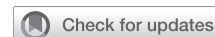

Preliminary results in tracheal replacement using stented aortic matrices for primary extensive tracheal cancer



Ilaria Onorati, MD,^{a,b,c} Dana M. Radu, MD,^{a,b,c} Ana Maria Santos Portela, MD,^a Marine Peretti, MD,^a Patrice Guiraudet, MD,^a Jeremy Bardet, MD,^a Olivia Freynet, MD,^d Morgane Didier, MD,^d Yurdagül Uzunhan, MD, PhD,^{b,d} Kader Chouahnia, MD,^e Boris Duchemann, MD, PhD,^e Valérian Bourinet, MD,^f Hervé Dutau, MD, PhD,^g Jean-Philippe Berthet, MD, PhD,^h Charles-Hugo Marquette, MD, PhD,ⁱ François Tronc, MD, PhD,^j Myriam Locatelli Sanchez, MD,^k Christophe Trésallet, MD, PhD,^l Clément Fournier, MD, PhD,^m Nicolas Vénissac, MD, PhD,ⁿ Makoto Miyara, MD, PhD,^o Eric Vicaut, MD, PhD,^p and Emmanuel Martinod, MD, PhD^{a,b,c}

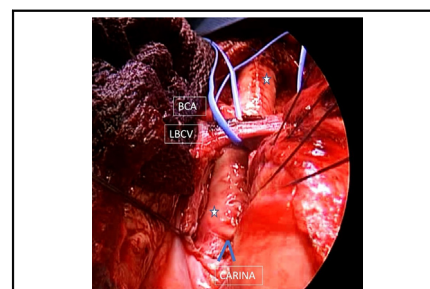
ABSTRACT

Objective: Recent studies have demonstrated the feasibility and favorable long-term results of tracheobronchial replacement using stented cryopreserved aortic allografts. We propose to investigate the outcomes of this emerging technique in the subgroup of patients with extensive tracheal cancer.

Methods: This study was based on 13 patients with primary extensive tracheal cancer extracted from the prospective registry TRITON-01 (ClinicalTrials.gov Identifier: NCT04263129), which included 40 patients in total. We analyzed early and late outcomes in this subset of patients.

Results: From March 2019 to September 2022, 13 patients were included in the study. There were 9 female and 4 male patients, with a mean age of 53.9 years [36-71 years]. They had tracheal replacement for extended adenoid cystic carcinoma (n = 11), squamous cell carcinoma (n = 1), and mucoepidermoid carcinoma (n = 1). A venovenous extracorporeal membrane oxygenation was used in the 6 last cases. The mean length of resection was 81 mm [50-120 mm]. There was no 30-day postoperative mortality. A complete resection (R0) was achieved in 11 patients. The main late complications consisted of tracheal granulomas related to the stent and requiring repeated bronchoscopies (n = 9), pneumonia (n = 3), airway infection (n = 1), bronchoesophageal fistula (n = 1), mechanical stent obstruction requiring change (n = 2), and mediastinitis treated by antibiotics, drainage, and omentoplasty (n = 1). With a maximal follow-up of 3 years and 7 months, cancer recurrence was observed in 2 patients. All patients were alive at last follow-up except 2 (84.6%).

Conclusions: Airway replacement using stented CAA represents a feasible and promising solution for extensive tracheal cancer. (JTCVS Techniques 2023;21:227-36)



Per-operative view (sternotomy) showing a total airway replacement using a stented CAA.

CENTRAL MESSAGE

Airway replacement using stented CAA represents a feasible and promising approach for extensive tracheal cancer.

PERSPECTIVE

Airway replacement using a stented CAA can offer a viable treatment for some patients with extensive tracheobronchial cancer considered “unresectable” with the potential to even achieve R0 margins.

See Discussion on Page 237.

From the ^aChirurgie Thoracique et Vasculaire, ^dPneumologie, ^eOncologie, and ^fChirurgie Digestive et Endocrinienne, Assistance Publique - Hôpitaux de Paris, Hôpitaux Universitaires Paris Seine-Saint-Denis, Hôpital Avicenne, Université Sorbonne Paris Nord, Faculté de Médecine SMBH, Bobigny, France; ^bInserm UMR1272, Hypoxie et Poumon, Université Sorbonne Paris Nord, Faculté de Médecine SMBH, Bobigny, France; ^cUniversité Paris Cité, Fondation Alain Carpentier, Laboratoire de Recherche Bio-chirurgicale, AP-HP, Hôpital Européen Georges Pompidou, Paris, France; ^dPneumologie, Centre Hospitalier Universitaire Sud Saint-Pierre, La Réunion, France; ^ePneumologie, Assistance Publique - Hôpitaux de Marseille, Hôpital Universitaire Nord, Marseille, France; ^fChirurgie Thoracique, Université Côte d'Azur, CHU Nice, Nice, France; ^gPneumologie, Université Côte d'Azur, CHU Nice, Marseille, France; ^hChirurgie Thoracique, Hôpitaux Universitaires de Lyon, Lyon, France; ⁱPneumologie, Hôpitaux Universitaires de Lyon, Lyon, France; ^jPneumologie and ^kChirurgie Thoracique, Hôpitaux Universitaires de Lille, Lille, France; ^lDépartement d'Immunologie, Sorbonne Université, Inserm, Centre d'Immunologie et des Maladies Infectieuses (CIMI-Paris), AP-HP, Hôpital Pitié-Salpêtrière, Paris, France; and ^mAP-HP, Unité de Recherche Clinique, Hôpitaux Saint-Louis-Lariboisière-Fernand Widal, Université Paris Cité, Paris, France.

Funded by Assistance Publique - Hôpitaux de Paris.

Clinical trial registry number: TRITON-01 study, [ClinicalTrials.gov](https://clinicaltrials.gov/ct2/show/study/NCT04263129) Identifier NCT04263129.

Read at the 103rd Annual Meeting of The American Association for Thoracic Surgery, Los Angeles, California, May 6-9, 2023.

Received for publication Feb 28, 2023; revisions received April 30, 2023; accepted for publication May 2, 2023; available ahead of print June 23, 2023.

Address for reprints: Prof Emmanuel Martinod, MD, PhD, Assistance Publique - Hôpitaux de Paris, Hôpitaux Universitaires Paris Seine Saint-Denis, Hôpital Avicenne, Chirurgie Thoracique et Vasculaire, Faculté de Médecine SMBH, Université Sorbonne Paris Nord, 125 rue de Stalingrad 93009 BOBIGNY cedex, Paris, France (E-mail: emmanuel.martinod@aphp.fr).

2666-2507

Copyright © 2023 The Author(s). Published by Elsevier Inc. on behalf of The American Association for Thoracic Surgery. This is an open access article under the CC BY-NC-ND license (<http://creativecommons.org/licenses/by-nc-nd/4.0/>). <https://doi.org/10.1016/j.jtc.2023.05.021>

Abbreviations and Acronyms

ACC	= adenoid cystic carcinoma
CAA	= cryopreserved aortic allograft
DFS	= disease-free survival
ECMO	= extracorporeal membrane oxygenation
SCC	= squamous cell carcinoma

To view the AATS Annual Meeting Webcast, see the URL next to the webcast thumbnail.

In accordance with the few databases available, primary tracheal cancers are rare tumors, occurring at a rate of 2.6 new cases per one million people per year.^{1,2} Squamous cell carcinoma (SCC) represents the predominant histology, exhibits a male predisposition, and is usually observed between 50 and 70 years of age. Adenoid cystic carcinoma (ACC) is noted equally in both sexes or with female predominance according to the different studies and mainly in the fourth and fifth decades. Both SCC and ACC constitute more than 60% of all primary tracheal tumors. Mucoepidermoid carcinoma is found approximately in 0.1% to 0.2% of all pulmonary neoplasms, and, similarly to ACC and pleomorphic adenoma, arises from minor salivary gland tissue, most often in the central airways.

When feasible, surgery consisting in the resection of the tumoral airway segment with end-to-end anastomosis is the best treatment choice for tracheal cancer.^{1,2} In extensive tracheal cancer with involvement of more than 50% of the length of trachea, the surgical treatment cannot be the standard approach because of the necessity of more complex tracheal reconstructions, requiring airway replacement. At diagnosis, almost 1 in 3 cases of tracheal cancer is considered unresectable by the standard technique, and this is mainly due to the extent of airway involvement.³ In this article, we focus only on extended tracheobronchial cancer cases that are not accessible to standard techniques of reconstruction because of the length of the airway involvement. Currently, in the absence of a tracheal substitute, this subset of patients can only have palliative treatment.

In recent studies, our team demonstrated the feasibility and favorable long-term results of tracheobronchial replacement using stented cryopreserved aortic allografts (CAAs) for extended benign and malignant lesions with no other therapeutic option.^{4,5} We propose to investigate the outcomes of this emerging technique in the subgroup of patients with extensive primary tracheal cancer.

METHODS**Patient Selection**

This retrospective analysis was based on 13 patients with primary tracheal-extended cancer extracted from the prospective registry TRITON-01 ([ClinicalTrials.gov](https://clinicaltrials.gov) Identifier: NCT04263129), which included 40 patients in total. Among these 13 patients, 3 had never been reported elsewhere. The TRITON-01 registry was conducted by our team to evaluate the results of tracheal replacement using stented CAA in patients with tracheal and/or bronchial lesions that are benign or malignant and cannot benefit from standard surgical resections but need an airway substitute.

The TRITON-01 study has confirmed that airway bioengineering with stented CAA can be used as usual care in our center.⁵ It corroborated our previous experimental and clinical encouraging results over a 25-year period.^{6,7}

Ethical Considerations

All patients provided informed written consent for the publication of their study data, and the study was approved by the PARIS-NORD Institutional Ethical Review Board (no. IRB00006477) on December 5, 2019.

Preoperative Evaluation and Treatment

Airway replacement using a stented CAA was proposed after a standard preoperative evaluation, including a cervicothoracic computed tomography scan (Figure 1), a flexible bronchoscopy, a positron emission tomography associated with cerebral imaging, a laryngeal evaluation, and cardiopulmonary tests. If necessary, an echo-endoscopy was performed to evaluate esophageal invasion by the tracheal cancer. For each case, the use of this emerging approach was approved by a multidisciplinary team. All patients underwent rigid bronchoscopy in our center before surgery to obtain the histologic documentation and to better evaluate the length of the tracheobronchial invasion.

Treatment consisted in the radical resection of the tumoral tracheobronchial segment, followed by reconstruction using our technique for airway replacement (Figure 2), which is described in our previous publications.^{4,5} To summarize in brief, we used a CAA with a silicone stent placed and fixed through the operating field to avoid collapse. At the end of the operations, the grafts were covered with a local muscle flap to promote neovascularization and potentially avoid fistulization. Venovenous extracorporeal membrane oxygenation (ECMO) was used intraoperatively, when deemed necessary by the complexity of the reconstruction, to perform the surgery quicker, in good conditions, without complex airway manipulations to preserve ventilation. The absence of tumor at the airway margins was confirmed by frozen sections, which were performed systematically.

Statistical Analysis

We used descriptive statistics due to the nature of the study. Quantitative variables are described by their mean and standard deviation or median and quartiles; qualitative variables are described by percentages and associated 95% 2-sided interval.

RESULTS

From October 2009 to October 2022, 40 patients were included in the TRITON-01 study and had airway replacements. Most patients (n = 27, 67.5%) were operated in the last 3 years. Among these patients, a subgroup of 13 patients with primary tracheal extensive carcinoma was identified between March 2019 and September 2022. There were 9 female and 4 male patients, with a mean age of 53.9 years [36-71 years]. They had tracheal replacement for extended ACC

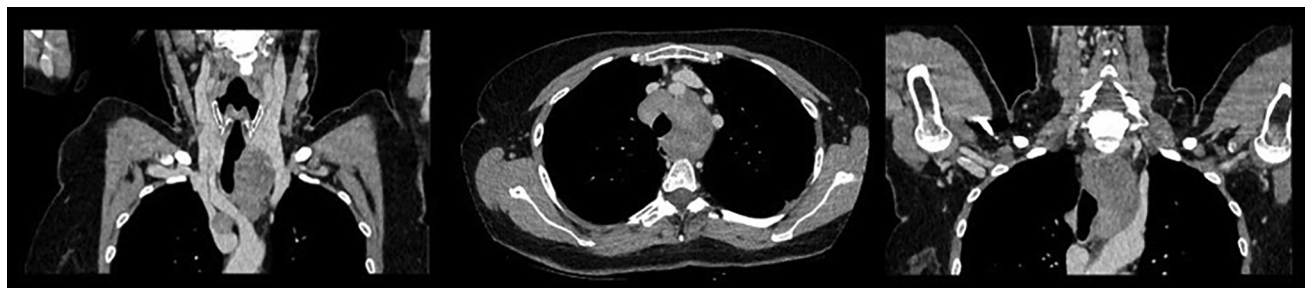

FIGURE 1. Shown is a large ACC invading the entire trachea, computed tomography scan (coronal and axial planes). ACC, Adenoid cystic carcinoma.

(n = 11), SCC (n = 1) and mucoepidermoid carcinoma (n = 1). Data regarding patient characteristics, preoperative treatment, and indication for airway replacement are presented in [Table 1](#).

Surgery and Postoperative Outcomes

A right thoracotomy was performed in 9 cases (airway replacement type 2 for tracheobronchial lesions with involvement of middle and lower trachea and carina) and a sternotomy in 4 cases (airway replacement type 1 for upper-middle tracheal lesions, airway replacement type 3 for lesions involving the entire trachea), in 2 (airway replacement type 3 for lesions involving the entire trachea) of which the cancer involved the entire trachea and the carina ([Figure 3](#)). A venovenous ECMO was used in the 6 last cases. The mean length of resection was 81 mm [50-120 mm]. Tracheal surgery was associated with a carinal resection followed by a primary reconstruction in 6 cases, an upper lobectomy in 1 case, and a bilobectomy in 1 case. Data concerning surgery and outcomes are shown in [Table 2](#).

Intraoperatively, the resection was judged to be complete when airway margins were found to be disease free at frozen section and no statement in the operative note indicated that the resection was incomplete. Overall, the definitive reports showed that 11 patients had a complete

resection (R0, ie, no residual tumor) and 2 had a microscopic residual tumor (R1). Lymph node dissection was performed in all cases. Definitive pathologic examination reported the lymph nodes were disease-free in all cases. Histologic examination showed the presence of peritracheal extension of the tumor, more frequently in ACC, with perineural growth observed in 5 of these cases ([Table 3](#)). In the 2 cases of R1 margins and in the only patient with recurrent ACC who died (but with R0 margins at time of resection), histologic examination showed a perineural growth by the tumor.

Concerning stent management, patients routinely received aerosolized saline solution at least 3 times a day to moisten the secretions and prevent airway obstruction. We decided to perform bronchoscopy only in case of respiratory symptoms (shortness of breath, dyspnea, mucus plugging) but not systematically. Of the 13 patients, 8 experienced in-hospital postoperative complications ([Table 2](#)), 4 of whom were minor complications (bronchial infections treated by antibiotics, mucus plugging). The mean hospital length of stay was 22.5 days, ranging from 8 to 87 days. No patients died within the first 30 days after surgery. A postoperative adjuvant radiotherapy with a dose of 54 Gy was given in 1 patient (no. 6) with R1 resection.

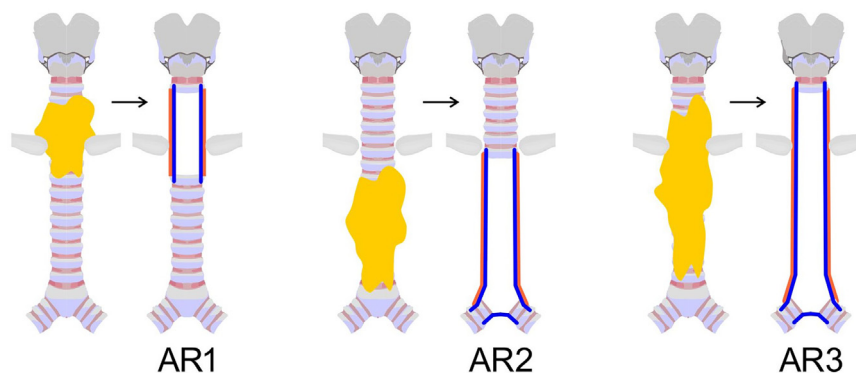


FIGURE 2. Shown is a schematic representation of the different types of airway replacement: AR1 (airway replacement type 1 for upper-middle tracheal lesions); AR2 (airway replacement type 2 for tracheobronchial lesions with involvement of middle and lower trachea and carina); and AR3 (airway replacement type 3 for lesions involving the entire trachea).

TABLE 1. Patient characteristics and description of lesions

Patient no.	Sex	Age, y	Medical history	Type of airway disease	Description of lesions and localization
1	F	39	None	Extended adenoid cystic carcinoma	Tracheobronchial lesion, middle and lower trachea, carina, esophageal adventitia
2	F	49	Surgical resection of a benign breast tumor and uterine cysts	Extended adenoid cystic carcinoma	Tracheobronchial lesion, middle and lower trachea, carina
3	F	51	Short QT syndrome	Extended adenoid cystic carcinoma	Tracheobronchial lesion, lower trachea, carina, right main bronchus and upper-lobe bronchus
4	M	36	Appendectomy, prostatic adenoma, resection of a thoracic ganglioneuroma	Extended adenoid cystic carcinoma	Entire trachea except the first ring, esophageal adhesions
5	F	71	Poliomyelitis, type 2 diabetes, past smoker (26 PY), COPD	Extended squamous cell carcinoma	Tracheobronchial lesion, middle and lower trachea, esophageal adventitia
6	M	55	Hypertension, gastroesophageal reflux disease, venous surgery	Extended adenoid cystic carcinoma	Tracheobronchial lesion, middle and lower trachea, carina
7	M	60	Inguinal hernia	Extended adenoid cystic carcinoma	Tracheobronchial lesion, middle and lower trachea
8	F	59	Hypertension	Extended adenoid cystic carcinoma	Tracheobronchial lesion, middle and lower trachea
9	F	56	None	Extended adenoid cystic carcinoma	Entire trachea from cricoid cartilage to carina
10	F	59	Past smoker (94 PY) and alcohol use disorder, COPD, appendectomy, cat-scratch disease, cranial trauma, anaphylactic reaction to bee stings	Extended adenoid cystic carcinoma	Tracheal lesion, middle and lower trachea
11	F	60	Hypertension, gastroesophageal reflux disease	Extended mucoepidermoid carcinoma	Tracheal lesion, middle and lower trachea
12	F	60	Thyroidectomy, diabetes 2	Extended adenoid cystic carcinoma	Right middle and upper bronchus and lower and middle trachea lesion
13	M	45	Past smoker (25 PY)	Extended adenoid cystic carcinoma	Upper middle tracheal lesion

All patients benefited from conventional bronchoscopic debulking as preoperative treatment. Indication for airway replacement was not accessible to conventional surgery. *F*, Female; *M*, male; *PY*, pack-years; *COPD*, chronic obstructive pulmonary disease.

Follow-up and Late Outcomes

Patients were periodically followed-up every 3 months the first year, 6 months the second year, and once a year thereafter. Follow-up consisted in flexible bronchoscopy and CT scan (Figures 3, B, 4, and E1). In case of respiratory symptoms (shortness of breath, dyspnea, mucus plugging), the flexible and/or rigid bronchoscopy was systematically performed.

The main late complication consisted of tracheal granulomas related to the presence of the airway stent and requiring repeated bronchoscopies in 9 patients for desobstruction (Figure 4), pneumonia ($n = 3$), airway infection ($n = 1$), bronchoesophageal fistula ($n = 1$), mechanical stent obstruction requiring change ($n = 2$), and mediastinitis treated by antibiotics, drainage and omentoplasty ($n = 1$).⁸

Concerning the occurrence of stent-related granulomas, there was a high variability between patients.

In October 2022, with a maximal follow-up of 3 years and 7 months, the stent was changed in 4 patients and removed in 2 at 1 year and 3 months or 3 years and 6 months (Figure E2). A cancer recurrence was observed in 2 patients. All patients were alive except 2 (84.6%). One patient died of sepsis with multiple organ failure 3 months after tracheal resection for a SCC complicated by an obstructive left bronchus granuloma requiring stenting and a bronchoesophageal fistula repaired surgically under ECMO. The second patient died after a redo surgery for ACC recurrence, 28 months after an entire tracheal resection and reconstruction. Data concerning follow-up are presented in Table 3.

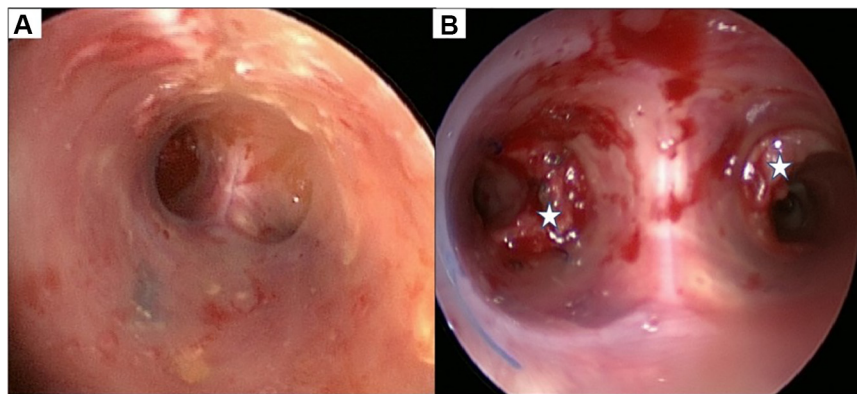


FIGURE 3. A, Rigid bronchoscopy the aspect of tracheobronchial stented CAA (AR2); B, aspect of carina and main bronchi after resection of granulomas (stars). CAA, Cryopreserved aortic allograft.

DISCUSSION

The present study showed that extensive primary tracheal cancer can benefit from airway replacement using a CAA. Without the possibility of replacement, the treatment of these lesions is very challenging and lacks valid guidelines. The TRITON-01 study allowed to better define the management of patients requiring airway bioengineering with CAA from indication to long-term postoperative follow-up.⁵ Besides its feasibility, this technique allows an R0 resection in most cases of primary tracheal cancer.

Complete resection in ACC and SCC is associated with improved survival.³ Surgery is conventionally performed when the tumor is “resectable,” meaning that the involved segment can be resected (up to 5-6 cm of length) and reconstructed with end-to-end anastomosis. The most common contraindication to tracheal cancer surgery is the extent of airway involvement, and even in the event of possible resection, the surgical margins are frequently affected by residual tumor.^{3,9,10} Our technique addresses these patients considered “unresectable,” offering a tracheal substitute, without the need for immunosuppressive therapy. In our series, the length of airway resection ranges from 50 to 120 mm, with resection of carina in 6 cases and of the lung in 2 cases requiring 1 lobectomy and 1 bilobectomy. Four patients had grade 1 to 2 complications according to the American Thoracic Society (pneumonia, atrial fibrillation, mucus plugging) and 4 patients (30%) presented grade 3 to 4 complications, without mortality within the first 30 days. We reported one in-hospital death at 87 days after surgery. Regarding late complications, most were related to the stent, especially granulation tissue formation. Nine patients required iterative bronchoscopic procedures for desobstruction and sometimes stent changing (n = 4, 30%). All patients breathed and spoke normally through the stented aortic matrix without tracheostomy. In other series, morbidity was similar with grade 3 to 4 complications

estimated at 34% for complex surgery¹¹; mortality within 30 days after surgery was estimated at 10% to 11%.^{3,12}

Previous studies showed that surgery was correlated to a significantly better survival than nonsurgical treatment,^{3,9,10} demonstrated by an overall 5-year and 10-year survival rates, in case of resected tracheobronchial ACC, of 52% to 88.7% for R0 resections and 29% to 43.2% for R1 resections. In unresectable patients, the overall 5-year and 10-year survival rates were 33% and 10%, respectively. In cases in which resection presented negative airway margins, survival was greater. The complete resection of tracheobronchial ACC is possible in one half of the standard surgical cases, and the tumor tends to recur locally or metastasize even 10 years after surgery.^{13,14}

Adjuvant radiotherapy is currently used when positive margins (R1 or R2, grossly positive margins) are found at histologic examination.^{10,12-14} Patients with grossly positive airway margins had significantly worse survival than patients with grossly negative resection margins.^{11,12} In 1996, Regnard and colleagues¹⁵ published a multi-institutional French study in which complete or incomplete resection for ACC was associated with a 5-year survival of 82% (36 patients) and 63% (26 patients), respectively.

Gaissert and colleagues³ published the largest series of 270 tracheal cancer, with 135 patients affected by ACC, treated during 40 years; 71% of these patients were treated by resection with a 5-year overall survival of 52% for ACC. Radiotherapy was administered in 70% of the patients postoperatively. When the extended tracheal cancer was judged unresectable, radiotherapy alone was recommended, with 33% rate of 5-year overall survival.^{3,16} Unresectable ACC presents an increasingly difficult problem to control because of the long localization throughout different body's region (neck, thorax). In these cases, primary radiotherapy has given mixed results, with a rate of local control ranging between 20% and 70%.^{17,18} Recently, another group described

TABLE 2. Surgery and outcomes

Patient no.	Date of operation	Operation and type of airway replacement (AR), length of resection, mm	Surgical approach	Mortality within the first 30 d	Hospital length of stay, d	Morbidity within the first 30 d
1	March 2019	AR2, 60	Thoracotomy	No	10	No
2	March 2019	AR2, 50	Thoracotomy	No	8	No
3	May 2019	Right upper lobectomy AR2, 60	Thoracotomy	No	11	No
4	January 2020	AR3, 110	Sternotomy	No	17	Pneumonia treated by antibiotics, atrial fibrillation
5	June 2020	AR2, 110	Thoracotomy	No	87	Acute lung edema, chest drainage for pleural effusion, pericardial drainage for acute pericarditis, renal insufficiency
6	January 2021	AR2, 70	Thoracotomy	No	12	Pneumonia treated by antibiotics, left bronchial obstruction requiring stent fenestration under venovenous ECMO
7	January 2021	AR2, 110	Thoracotomy	No	16	Pneumonia treated by antibiotics, benign COVID-19 infection
8	June 2021	VV ECMO AR2, 80	Thoracotomy	No	29	Bronchial infection treated by antibiotics, bilateral vocal cord paralysis, deep venous thrombosis
9	September 2021	VV ECMO AR3, 120	Sternotomy	No	27	Vasoplegic syndrome due to ECMO, acute stent obstruction requiring rigid bronchoscopy
10	September 2021	VV ECMO AR1, 80	Sternotomy	No	35	Mucus plugging
11	March 2022	VV ECMO AR2, 50	Thoracotomy	No	13	No
12	April 2022	VV ECMO Right upper bilobectomy AR2, 80	Thoracotomy	No	18	Bronchial infection treated by antibiotics
13	September 2022	VV ECMO AR1, 75	Sternotomy	No	9	No

AR2, Airway replacement type 2; AR3, airway replacement type 3; COVID-19, coronavirus disease 2019; VV, venovenous; ECMO, extracorporeal membrane oxygenation; AR1, airway replacement type 1.

outcomes after extended resection for tracheobronchial ACC in 59 patients, included throughout 50 years, treated by surgery (complex and standard resections) with an overall 5-year survival of 81.5% and a 5-year disease-free survival (DFS) of 65%.¹⁴ They found that T4 tumors and positive margins were associated with poorer survival. In the R1 subgroup, survival was better with adjuvant radiotherapy.

Another important feature to take into consideration is the influence of pathologic characteristics, especially for ACC, on long-term survival. Honings and colleagues¹¹ detected and underlined the importance of extramural airway extension, perineural tumoral growth and radial resection margins as prognostic factors for both survival and DFS in a consecutive series of patients undergoing surgical

TABLE 3. Histologic findings and long-term follow-up

Patient no.	Peritracheal histologic findings	Cancer pathology according to airway margins	Stent removed?	Last follow-up (from the date of operation to October 12, 2022, mo)	Status	Recurrence	Postoperative adjuvant treatment
1	Perineural growth	R0 resection	No	43	Alive	No	No
2	Mucosal growth	R0 resection	Yes, 42 mo	43	Alive	No	No
3	Peritracheal tissue invasion	R0 resection	No, changed at 24 mo	41	Alive	Yes, 25 mo after surgery	No
4	Peritracheal tissue invasion	R0 resection	No	33	Dead	Yes, 28 mo after surgery	No
5	Peritracheal tissue invasion	R0 resection	No	3	Dead	No	No
6	Perineural growth	R1 resection	No, changed at 6 mo	22	Alive	No	RT
7	Perineural growth	R0 resection	No	22	Alive	No	No
8	Mucosal growth	R0 resection	Yes, changed at 4 mo, removed 15 mo	16	Alive	No	No
9	Peritracheal tissue invasion	R0 resection	No	13	Alive	No	No
10	Mucosal growth	R0 resection	No	12	Alive	No	No
11	Inflammatory reaction	R0 resection	No	7	Alive	No	No
12	Perineural growth	R1 resection	No, changed at 4 mo	6	Alive	No	No
13	Perineural growth	R0 resection	No	1	Alive	No	No

R0 indicates no residual tumor was found during pathological examination of the resected specimens; R1 indicates microscopic residual tumor. RT, Radiotherapy.

treatment for primary tracheal ACC. Peritracheal involvement by cancer showed by perineural growth and extramural extension through the tracheal adventitia were important prognostic factors. Histologic findings describing tumor radial behavior and invasion should be considered in staging system of tracheal ACC.^{2,19} In their study, Honings and colleagues¹¹ observed a tendency of this tumor to grow through the tracheal wall beyond the adventitia in most of cases. This fact is probably linked to extremely close or positive radial resection margins. Invasion through the adventitia was a significant prognostic factor for both overall survival and DFS. In our series, 9 patients had a peritracheal

involvement by the tumor: 2 of them were found R1 at histologic examination, and other 2 patients experienced recurrence 2 years after surgery. Our reconstructive method proposes a radical treatment for these patients often considered “unresectable” to achieve R0 margins. However, we can argue about the role of adjuvant postoperative treatment in case of massive peritracheal tissue invasion, especially in these cases with extensive tracheobronchial involvement by primary tracheal carcinoma.

In previous studies, due the rarity of the pathology, the period of observation was very long (40 or 50 years), with surgical techniques and radiotherapy that evolved during

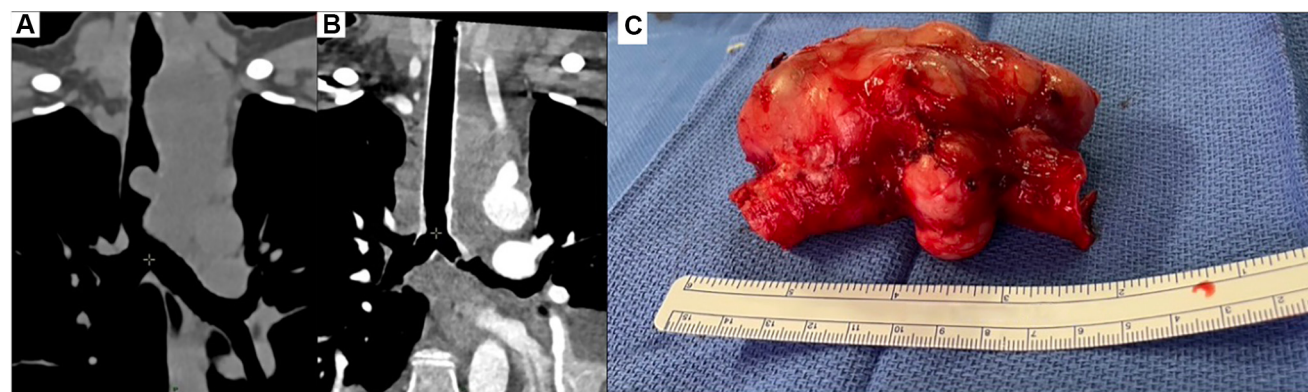
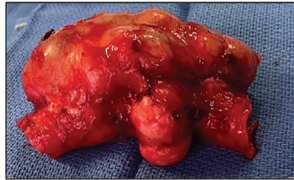

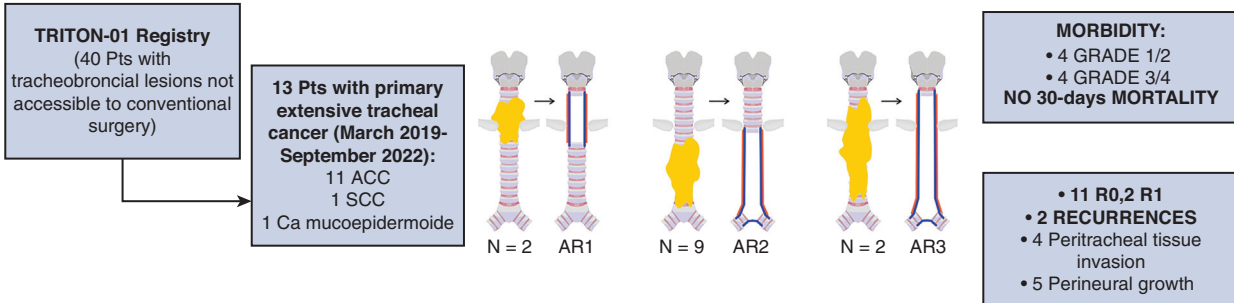
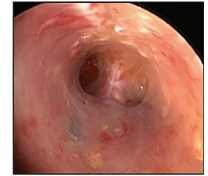FIGURE 4. A, Large ACC involving the entire trachea and carina, CT scan (coronal plane); B, postoperative aspect of the same patient benefit from AR3 at CT scan (coronal plane); and C, same tumor after resection. ACC, Adenoid cystic carcinoma; CT, computed tomography; AR3, airway replacement type 3.



@AATSJournals



Preliminary Results in Tracheal Replacement Using Stented Aortic Matrices for Primary Extensive Tracheal Cancer



Airway replacement using a stented CAA can offer a radical treatment for some patients with extensive primary tracheal cancer often considered “unresectable” to achieve R0 margins.

Postoperative adjuvant radiotherapy needs to be discussed in case of positive surgical (R1/R2) margins and/or massive peritracheal tissue invasion.

FIGURE 5. Summary of preliminary results in tracheal replacement using stented aortic matrices for primary extensive tracheal cancer. ACC, Adenoid cystic carcinoma; SCC, squamous cell carcinoma; AR1, airway replacement type 1; AR2, airway replacement type 2; AR3, airway replacement type 3; CAA, cryopreserved aortic allograft.

this time. Thus, we excluded series with similar cases that were probably managed differently from a surgical and/or radiotherapy perspective. Nowadays, there are different solutions that should be considered: airway replacement by aortic allografts represents a feasible surgical solution to achieve radical resection of extensive tumors. The histologic description and findings should be systematically reported especially for extensive ACC. The use of radiotherapy has also increased in last decades, and it could represent a useful tool even in case of R0 airway margins but with important peritracheal tumor invasion.

Limitations

The limits of this series included mainly the small number of patients, the heterogeneity of tracheal cancer, even if 85% of these were ACC, and a maximal follow-up of 43 months. In the future, with a larger series and longer follow-up, we might be able to better define outcomes for these particular patients.

CONCLUSIONS

Complete (R0) resection is frequently difficult to achieve in extensive tracheobronchial lesions. Airway replacement

using stented CAA represents a feasible and promising solution for extensive primary tracheal cancer (Figure 5). A larger patient experience is necessary to define the optimal management of such extensive primary tracheal tumors.

Webcast

You can watch a Webcast of this AATS meeting presentation by going to: <https://www.aats.org/resources/airway-replacement-using-stented-aortic-matrices-for-extensive-tracheal-cancer>.



Conflict of Interest Statement

The authors reported no conflicts of interest. The Journal policy requires editors and reviewers to disclose conflicts of interest and to decline handling or reviewing manuscripts for which they may have a conflict

of interest. The editors and reviewers of this article have no conflicts of interest.

References

1. Grillo HC. Primary tracheal neoplasms. In: Grillo HC, ed. *Surgery of the Trachea and Bronchi*. BC Decker Inc; 2004:207-47.
2. Urdaneta AI, Yu JB, Wilson LD. Population based cancer registry analysis of primary tracheal carcinoma. *Am J Clin Oncol*. 2011;34:32.
3. Gaissert HA, Grillo HC, Shadmehr MB, Wright CD, Gokhale M, Wain JC, et al. Long-term survival after resection of primary adenoid cystic and squamous cell carcinoma of the trachea and carina. *Ann Thorac Surg*. 2004;78:1889-96.
4. Martinod E, Chouahnia K, Radu DM, Joudiou P, Uzunhan Y, Bensidhoum M, et al. Feasibility of bioengineered tracheal and bronchial reconstruction using stented aortic matrices. *JAMA*. 2018;319:2212-22.
5. Martinod E, Radu DM, Onorati I, Portela AMS, Peretti M, Guiraudet P, et al. Airway replacement using stented aortic matrices: long-term follow-up and results of the TRITON-01 study in 35 adult patients. *Am J Transplant*. 2022;22:2961-70.
6. Martinod E, Paquet J, Dutau H, Radu DM, Bensidhoum M, Abad S, et al. In vivo tissue engineering of human airways. *Ann Thorac Surg*. 2017;103:1631-40.
7. Martinod E, Seguin A, Holder-Espinasse M, Kambouchner M, Duterque-Coquillaud M, Azorin JF, et al. Tracheal regeneration following tracheal replacement with an allogenic aorta. *Ann Thorac Surg*. 2005;79:942-8.
8. Gómez-Caro A, Benkirane T, Martinod E, Berthet JP. Mediastinitis after a cryopreserved allograft tracheal transplant treated by transposition of the major omentum. *Eur J Cardiothorac Surg*. 2022;62:438.
9. Yang H, Yao F, Tantai J, Zhao Y, Tan Q, Zhao H. Resected tracheal adenoid cystic carcinoma: improvements in outcome at a single institution. *Ann Thorac Surg*. 2016;101:294-300.
10. Wu Q, Xu F. Rapid response to radiotherapy in unresectable tracheal adenoid cystic carcinoma: a case report. *World J Clin Cases*. 2021;9:9535-41.
11. Honings J, Gaissert HA, Weinberg AC, Mark EJ, Wright CD, Wain JC, et al. Prognostic value of pathologic characteristics and resection margins in tracheal adenoid cystic carcinoma. *Eur J Cardiothorac Surg*. 2010;37:1438-44.
12. Estephan J, Mercier O, de Montpreville VT, Hanna A, Leymarie N, Pechoux CL, et al. Retrospective study of outcomes after extended resection for tracheobronchial adenoid cystic carcinoma. *J Thorac Cardiovasc Surg*. [https://www.jtcvs.org/article/S0022-5223\(22\)01171-0/fulltext](https://www.jtcvs.org/article/S0022-5223(22)01171-0/fulltext)
13. Kanematsu T, Yohena T, Uehara T, Ushijima C, Asoh H, Yoshino I, et al. Treatment outcome of resected and nonresected primary adenoid cystic carcinoma of the lung. *Ann Thorac Cardiovasc Surg*. 2002;8:74-7.
14. Yang Y, Ran J, Wang Y, Zhou Z, Chen D, Feng Q, et al. Intensity modulated radiation therapy may improve survival for tracheal-bronchial adenoid cystic carcinoma: a retrospective study of 133 cases. *Lung Cancer*. 2021;157:116-23.
15. Regnard JF, Fourquier P, Levasseur P. Results and prognostic factors in resections of primary tracheal tumors: a multicenter retrospective study. The French Society of Cardiovascular Surgery. *J Thorac Cardiovasc Surg*. 1996;111:808-13.
16. Lee JH, Jung EJ, Jeon K, Koh WJ, Suh GY, Chung MP, et al. Treatment outcomes of patients with adenoid cystic carcinoma of the airway. *Lung Cancer*. 2011;72:244-9.
17. Jaso J, Malhotra R. Adenoid cystic carcinoma. *Arch Pathol Lab Med*. 2011;135:511-5.
18. Marks LB, Bentzen SM, Deasy JO, Kong FMS, Bradley JD, Vogelius IS, et al. Radiation dose-volume effects in the lung. *Int J Radiat Oncol Biol Phys*. 2010;76:S70-6.
19. Bhattacharyya N. Contemporary staging and prognosis for primary tracheal malignancies: a population-based analysis. *Otolaryngol Neck Surg*. 2004;131:639-42.

Key Words: extensive tracheal cancer, adenoid cystic carcinoma, tracheal replacement, squamous cell carcinoma, aortic allograft

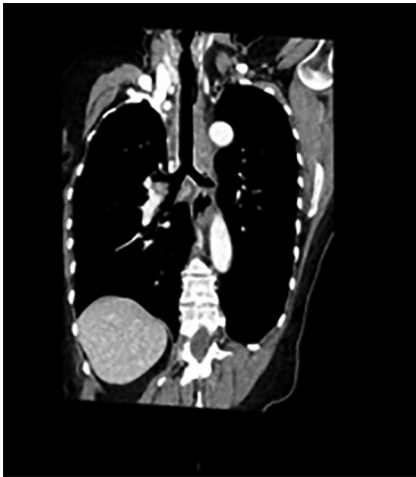

FIGURE E1. Shown is a case of a stented aortic matrix after airway replacement at CT scan (coronal plane) that benefited from AR2. *CT*, Computed tomography; *AR2*, airway replacement type 2.

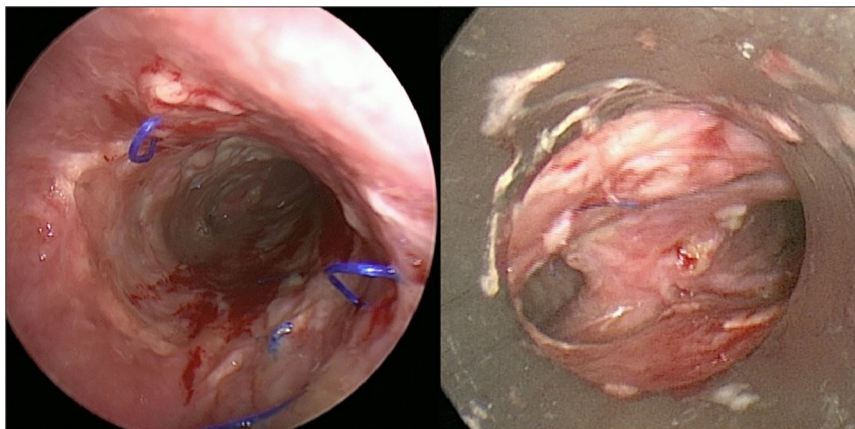


FIGURE E2. Shown, on rigid bronchoscopy, is a neotrachea after stent removal.