



Received: 2014.12.14
Accepted: 2015.01.11
Published: 2015.04.19

Authors' Contribution:

- A** Study Design
- B** Data Collection
- C** Statistical Analysis
- D** Data Interpretation
- E** Manuscript Preparation
- F** Literature Search
- G** Funds Collection

A Case of Congenital Uterine Arterio-Venous Malformation Managed by Hysterectomy

Rohit Bhoil^{ABCDEF}, Vandana Raghuvanshi^A, Suhas Basavaiah^{GE}

Department of Radiodiagnosis, Indira Gandhi Medical College, Shimla, India

Author's address: Rohit Bhoil, Department of Radiodiagnosis, Indira Gandhi Medical College, Shimla, India, e-mail: rohitbhoil@gmail.com

Summary

Background:

A uterine arteriovenous malformation (AVM) is a rare cause of uterine bleeding. It may have varied presentations ranging from being completely asymptomatic; to features of congestive heart failure to vaginal bleeding which may at times life be threatening. Clinical findings in such cases are often un-reliable; requiring a high index of suspicion to make the diagnosis. Sonographic gray scale features are non-specific requiring confirmation with colour and spectral Doppler.

Case Report:

We report a case of a 46-year-old lady who presented with heavy vaginal bleeding and ultrasound/colour Doppler evidence of uterine AVM managed by abdominal hysterectomy, describing the imaging features on ultrasound and Doppler. We also discuss in brief about this uncommon but serious condition which the radiologist/gynaecologist may encounter in their practise.

Conclusions:

Uterine AV Malformation is a rare but potentially life-threatening cause of menorrhagia which must be kept in the differential diagnosis of sudden and massive vaginal bleeding. Ultrasound remains the modality of choice in diagnosing the condition which requires a high index of clinical suspicion. Color and spectral Doppler ultrasound should be used to supplement the findings and to confirm the diagnosis.

MeSH Keywords:

Arteriovenous Malformations • Hysterectomy • Ultrasonography, Doppler, Color • Uterine Hemorrhage

PDF file:

<http://www.polradiol.com/abstract/index/idArt/893299>

Background

Dysfunctional uterine bleeding (DUB) is a common presentation in the emergency department, having a wide differential diagnosis. Most of the patients with DUB are hemodynamically stable and can usually be evaluated on an outpatient basis. Uterine arteriovenous malformations, which may sometimes be life-threatening, are rare entities in gynaecology. Their true incidence is unknown [1], with only over 100 cases reported till date [2]. In the literature, the description of uterine AVM is only in the form of case reports or case series involving few patients. It has been roughly predicted that their incidence is less than 4.5% [1]. They may have different presentations, the most common of which is vaginal bleeding, but other presentations such as features of heart failure, postmenopausal bleeding, and an asymptomatic mass may also be noted [3]. We describe a case of a 46-year-old female who presented with heavy vaginal bleeding and ultrasound/colour Doppler evidence of uterine AVM managed by abdominal hysterectomy.

Case Report

A 46-year-old female with a history of depressive illness presented to the emergency department with severe vaginal bleeding which had been gradually increasing for the last two days. She had a history of slight spotting for 3–4 days before the onset of that heavy bleeding. She also complained of cramping abdominal pain and generalised weakness and malaise. Previously, also in the last 6–7 years she had multiple episodes of light spotting in between her menstrual cycles but this was the first time she experienced heavy blood loss prompting her to visit hospital. She had one spontaneous abortion at the age of 34 years at 8 weeks' gestation, after which she never conceived. There was no history of any uterine instrumentation, surgery or a direct uterine trauma.

At the time of presentation she had a pulse rate of 86 beats per minute and her blood pressure was 118/64 mmHg. Her respiratory rate was 24 per minute. Her pulse oximetry

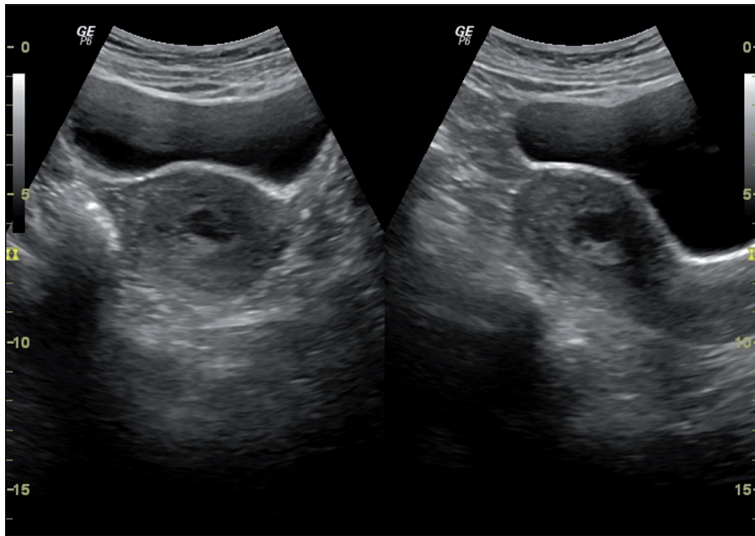


Figure 1. Transverse and longitudinal gray scale ultrasound images of the uterus showing multiple tortuous serpiginous anechoic areas in the myometrium which were most pronounced in the fundic region.

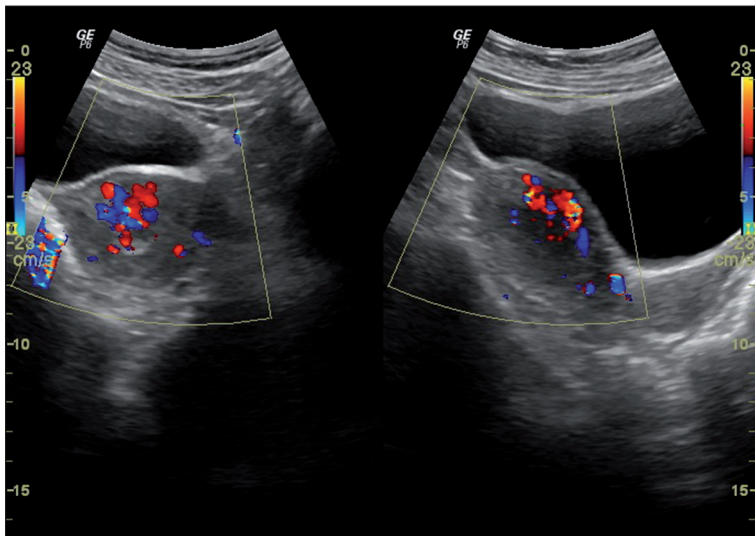


Figure 2. Transverse and longitudinal colour Doppler evaluation of these lesions depicted mixed arteriovenous waveforms with colour aliasing.

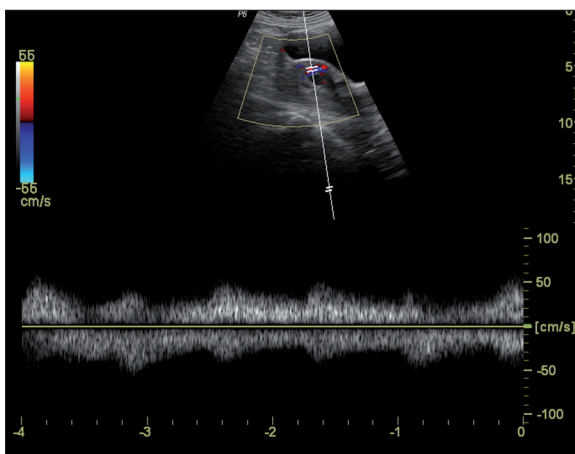


Figure 3. On spectral analysis the flow was of high-velocity and low-resistance type.

was 100% in room air and her oral temperature was 101 F (38.33°C). She had Hb of 8.5 gm/dL and her haematocrit was 35%. Her urine pregnancy test was negative. On examination she was well oriented and awake. There was evidence

of supra-pubic tenderness though her abdomen was soft. Her vaginal examination disclosed dark blood and clots. Her speculum examination showed mild fresh bleeding and per vaginum examination revealed that cervical movements were tender, and marked forniceal tenderness was present. General examination of other systems, including cardiac and respiratory systems, was essentially normal.

After the initial emergent management, the patient was referred for ultrasound examination which revealed multiple tortuous serpiginous anechoic areas in the myometrium which were most pronounced in the fundic region (Figure 1). Colour Doppler evaluation of those lesions demonstrated mixed arteriovenous waveforms with colour aliasing (Figure 2). The flow was of high velocity and low resistance on spectral analysis (Figure 3). Based on those imaging features, a diagnosis of uterine AV malformation was made. Mild free fluid was seen in the pelvis. Bilateral adnexae were normal. The rest of the abdominal ultrasound examination was normal.

In view of her peri-menopausal age and no desire to preserve fertility, the patient opted for removal of the uterus.

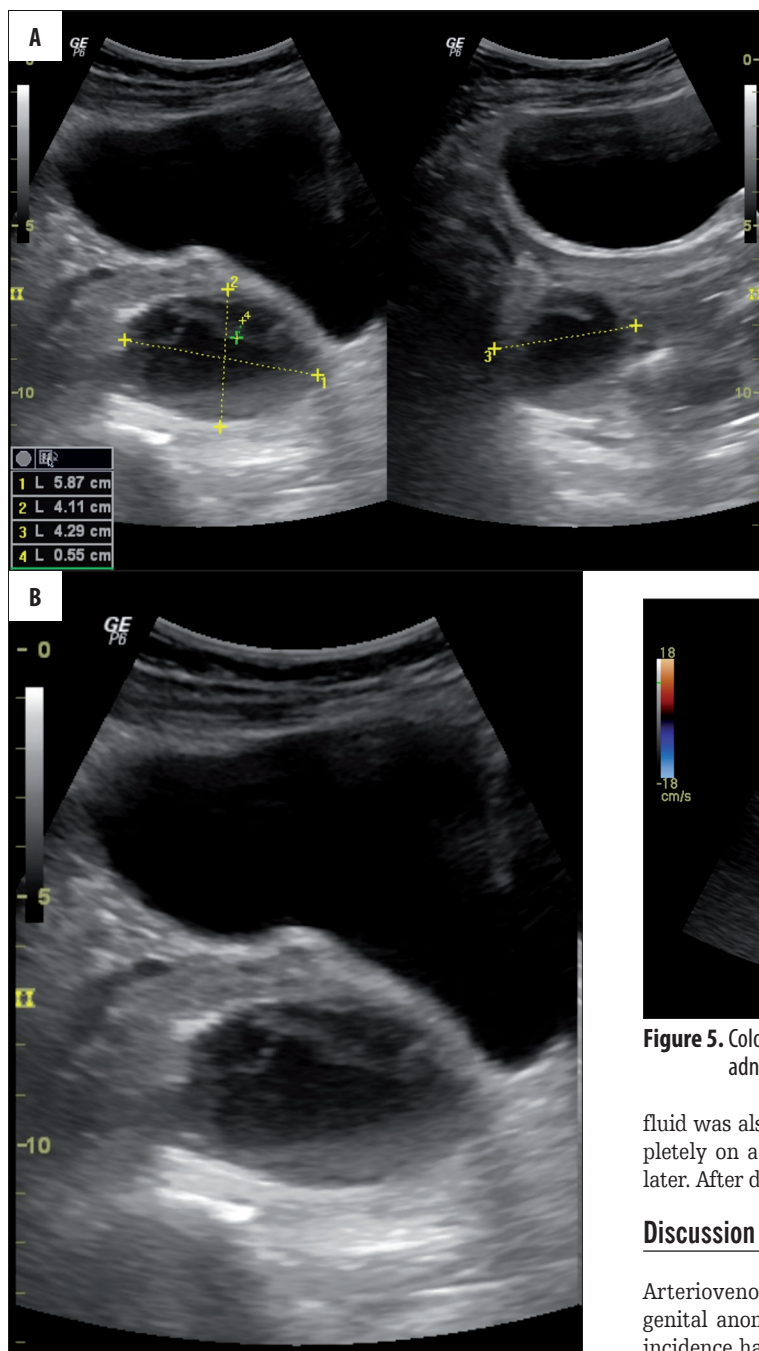


Figure 4. (A, B) Complex cysts in the right adnexa with internal echoes and septa

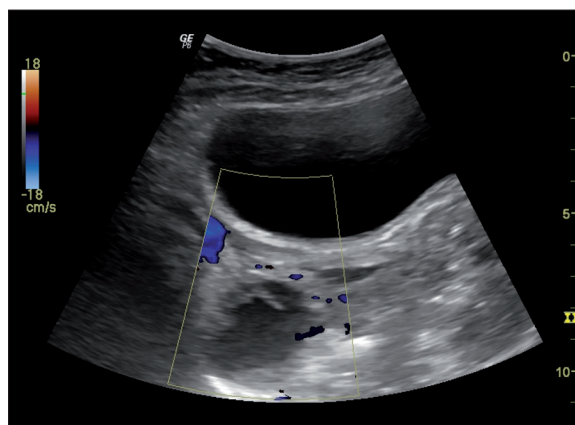


Figure 5. Colour Doppler shows no internal vascularity in the right adnexal cyst with minimal peripheral vascularity.

She underwent abdominal hysterectomy. Microscopic examination of the uterus showed that the endometrium was in the proliferative phase and the myometrium showed multiple ecstatic vessels of varying calibre some of which were extending up to the serosa.

On the 6th postoperative day, the patient complained of pain in the lower abdomen and also developed fever of up to 102 F (38.89°C). Ultrasound of the pelvic region showed cysts in the right adnexa (Figure 4A, 4B). Those were complex in nature, showing internal echoes and septations giving a reticular lace-like appearance, with no flow on colour Doppler and minimal peripheral vascularity (Figure 5). Those imaging features were consistent with haemorrhagic cysts. Mild free

fluid was also noted in the pelvis. Those cysts resolved completely on a follow-up ultrasound scan performed 6 weeks later. After discharge the patient had no further complaints.

Discussion

Arteriovenous malformations of the uterus are rare congenital anomalies whose true incidence is unknown. Their incidence has been roughly estimated to be around 4.5% [1]. These may be either congenital or acquired. Congenital malformations are a result of abnormal embryologic angiogenesis leading to the formation of multiple abnormal connections between arteries and veins [4]; acquired AVMs (also known as traumatic AVMs) are formed due to multiple small fistulae between arteries and veins and occur as a result of previous uterine instrumentation, gestational trophoblastic disease, choriocarcinoma, endometrial carcinoma, cervical cancer, infection or uterine surgery and trauma [3,5]. Imaging features in both forms are similar and patient history is helpful in distinguishing the two. They most commonly affect women in the reproductive age group [6].

Uterine AVMs have a wide spectrum of clinical presentations ranging from a completely asymptomatic one, to

vaginal bleeding which is the most common presentation and may be severe at times. They may also present with features of congestive heart failure and postmenopausal bleeding [3]. The acquired form may be noted if bleeding occurs after spontaneous abortion or gestational trophoblastic disease. In such scenarios a high degree of clinical suspicion is required for their diagnosis because any procedure like dilatation and curettage may further aggravate the bleeding [7].

Ultrasound is the initial imaging of choice in case of abnormal vaginal bleeding. Gray scale sonography shows multiple heterogeneously hypoechoic or anechoic tortuous spaces in the myometrium in a case of AVM. Colour Doppler ultrasonography reveals a meshwork of vessels producing a "color mosaic" pattern with high- and low-velocity flows in different directions [8]. Spectral Doppler shows low-resistance and high-peak systolic velocities with continuous high flow throughout the systole and diastole [1,8].

Sonographic appearance of AVM is non-specific; a similar picture can also be seen in case of retained products of conception and gestational trophoblastic disease [1]. Uterine AVMs may also be seen in these settings. However, in the latter group, β -hCG will be positive whereas in case of AVMs it will be negative. Therefore a diagnosis of a uterine AVM should be based on patient history, negative β -hCG findings, and the characteristic color and spectral Doppler features.

On MRI, characteristic features of uterine AVM include a bulky uterus with a focal heterogenous mass with disruption of the junctional zone and multiple serpiginous flow voids in the myometrium which show intense enhancement in post-contrast images. MRI provides accurate anatomical details as well as relation with surrounding structures. However, it has obvious disadvantages, i.e. limited availability and being expensive. Both of these disadvantages are a major constraint in its wide-spread use, especially in the developing countries. Angiography is the gold standard in the diagnostics [8,9] of AVM, depicting complex vascular connections supplied by hypertrophied feeding arteries and early drainage through enlarged, tortuous and hypertrophic veins [9]. It has an added advantage of embolisation in the same setting. However, it is invasive,

requires expertise, and the cath lab is available only at few places. Therefore, ultrasound combined with Doppler evaluation remains the investigation of choice in the diagnostics of uterine AVM.

Treatment options for patients with uterine AVM include medical management, trans-catheter arterial embolization or hysterectomy. The decision is based largely on the clinical status of the patient and her desire to preserve fertility, and also on the availability of services and patient affordability [10].

In patients with single or few episodes of bleeding and who are otherwise stable, management should be conservative. Oral contraceptive pills [11] and intra-uterine devices [12] have been found to be useful. Haemodynamically unstable and anaemic patients should be offered angiography and embolisation. It is a very good treatment option with a high success rate, fewer complications, and it preserves fertility. In patients with severe vaginal bleeding, especially in the presence of hemodynamic instability, it is of vital importance to start aggressive resuscitation with fluids and blood products. Temporary emergent measures like tamponade with a Foley catheter may be performed to manage life-threatening hemorrhage [1]. Hysterectomy remains the definitive treatment, especially in symptomatic patients without desired fertility, as was the case in our patient.

Congenital AVMs should ideally be treated with hysterectomy or embolization as they carry a higher risk of recurrent and severe blood loss. Conservative management should be reserved for incidentally discovered asymptomatic congenital cases and in the correct clinical setting should be offered to cases of acquired AVMs.

Conclusions

Uterine AV malformation is a rare but potentially life-threatening cause of menorrhagia which must be included in the differential diagnosis of sudden and massive vaginal bleeding. Ultrasound remains the modality of choice in diagnosing the condition which requires a high index of clinical suspicion. Color and spectral Doppler ultrasound should be used to supplement the findings and to confirm the diagnosis.

References:

- O'Brien P, Neyastani A, Buckley AR et al: Uterine arteriovenous malformations: from diagnosis to treatment. *J Ultrasound Med*, 2006; 25: 1387-92
- Hickey M, Fraser IS: Clinical implications of disturbances of uterine vascular morphology and function. *Baillieres Clin Obstet Gynaecol*, 2000; 14: 937-51
- Hoffman MK, Meilstrup JW, Shackelford DP et al: Arteriovenous malformations of the uterus: an uncommon cause of vaginal bleeding. *Obstet Gynecol Surv*, 1997; 52: 736-40
- Selby ST, Haughey M: Uterine arteriovenous malformation with sudden heavy vaginal hemorrhage. *West J Emerg Med*, 2013; 14: 411-14
- Fleming H, Ostör AG, Pickel H et al: Arteriovenous malformations of the uterus. *Obstet Gynecol*, 1989; 73: 209-14
- Goldrath MH: Uterine tamponade for the control of acute uterine bleeding. *Am J Obstet Gynecol*, 1983; 147: 869-72
- Chuong CJ, Brenner PF: Management of abnormal uterine bleeding. *Am J Obstet Gynecol*, 1996; 175: 787-92
- Grivell M, Reid M, Mellor A: Uterine arteriovenous malformations: a review of current literature. *Obstet Gynecol Surg*, 2005; 60: 761-67
- Vogelzang RL, Nemcek AA Jr, Skrtic Z et al: Uterine arteriovenous malformations: primary treatment with therapeutic embolization. *J Vasc Interv Radiol*, 1991; 2: 517-22
- McLachlan MS, Bird CC, Naiem EA et al: Uterine cirroid aneurysm. *Br J Obstet Gynaecol*, 1978; 85: 390-95
- Khatree MHD, Titz H: Medical treatment of a uterine arteriovenous malformation. *Obstet Gynecol*, 1999; 39: 378-80
- Timmerman D, Van den Bosch T, Peeraer K et al: Vascular malformations in the uterus: ultrasonographic diagnosis and conservative management. *Eur J Obstet Gynecol Reprod Biol*, 2000; 92: 171-78