

Received: 2020.02.21

Accepted: 2020.03.26

Available online: 2020.04.11

Published: 2020.05.16

Heart Transplantation Under Biventricular Mechanical Circulatory Support for Fulminant Myocarditis After a Bee Sting: A Case Report

Authors' Contribution:

Study Design A
Data Collection B
Statistical Analysis C
Data Interpretation D
Manuscript Preparation E
Literature Search F
Funds Collection G

EF 1 **Yu-san Chien**
BCD 1 **Shih-chieh Chien**
BC 2 **Yih-shang Chen**
ADE 3 **Jiun-yi Li**

1 Department of Critical Care, Mackay Memorial Hospital, Taipei, Taiwan
2 Department of Cardiovascular Surgery, National Taiwan University Hospital, Taipei, Taiwan
3 Department of Cardiovascular Surgery, Mackay Memorial Hospital, Taipei, Taiwan

Corresponding Author: Jiun-yi Li, e-mail: jyl5891@gmail.com

Conflict of interest: None declared

Patient: Female, 36-year-old
Final Diagnosis: Cardiogenic shock • myocarditis
Symptoms: Fever
Medication: —
Clinical Procedure: Mechanical circulatory support
Specialty: Surgery

Objective: Unusual clinical course
Background: Venom related fulminant myocarditis is uncommon. The clinical course varies, and histopathology is usually unclear, however, refractory cardiogenic shock is rare.

Case Report: We reported a case of a 36-year-old female who developed fever and cardiogenic shock 3 days after a bee sting. Cardiac angiography showed patent coronary arteries and severely compromised left ventricular function. Her hemodynamics remained unstable under high dose inotropic agents and intra-aortic balloon pump support. In-hospital cardiac arrest occurred 4 hours after admission and she received extracorporeal cardiopulmonary resuscitation. Her peripheral venoarterial extracorporeal membrane oxygenation (VA ECMO) was shifted to bilateral ventricular assisted devices (VAD) due to progressive right heart failure. The endomyocardial biopsy result was compatible with the picture of hypersensitivity myocarditis. Her heart went into persistent standstill under mechanical circulatory support. She underwent heart transplantation on hospital day 49 and remained clinically stable 6 months after discharge.

Conclusions: This is the first reported case of fulminant hypersensitivity myocarditis following a bee sting. ECMO and VAD could be used as bridge to a successful heart transplantation.

MeSH Keywords: Bee Venoms • Heart-Assist Devices • Myocarditis

Full-text PDF: <https://www.amjcaserep.com/abstract/index/idArt/923684>




1241



—



3



15



Background

Acute heart failure following bee or wasp sting is rare [1,2]. Possible mechanisms include direct toxic effects of venom or medication that results in high levels of plasma adrenalin, anaphylaxis, and hypersensitivity [3]. Here we reported a case of a biopsy proven fulminant myocarditis in a 36-year-old female who developed fatal cardiogenic shock 3 days after a bee sting.

Case Report

A 36-year-old previously healthy female was stung once by an unknown Hymenoptera that resulted in local swelling and erythema at dorsum of her right hand. Spiking fever started within 6 hours despite sting site gradually became unidentifiable. She visited a local clinic where oral steroid (prednisolone 20 mg/day) and antibiotics were prescribed. She came to our emergency department 3 days later for persistent on-and-off fever. She presented with high temperature (38.9°C), tachycardia, and hypotension (blood pressure 80/52 mmHg) at triage. Electrocardiography showed atrial fibrillation with rapid ventricular rate around 130 beats per minute and diffuse ST elevation. Chest radiography showed normal cardiothoracic ratio without signs of infiltrates or congestion. Hemogram did not show eosinophilia, leukocytosis, leukopenia, or left shift. MB isoenzyme of creatinine kinase (CK-MB) and cardiac troponin-I elevated to 96.0 ng/mL and 8.0 ng/mL, respectively. C-reactive protein was 10.5 mg/L and procalcitonin was 0.32 ng/mL. NT-proBNP was 20 700 pg/mL. Echocardiography showed global hypokinesia of left ventricle with an ejection fraction of 30.6%, and no pericardial effusion. Emergent cardiac catheterization did not reveal coronary artery lesions or vasospasm. Intra-aortic balloon pumping was inserted during the procedure for cardiogenic shock. Hypotension progressed accompanied with ventricular tachycardia and ventricular fibrillation, then in-hospital cardiac arrest followed. Manual cardiopulmonary resuscitation was unsuccessful for 25 minutes and percutaneous cardiopulmonary support (PCPS, CAPIOX® Centrifugal Pump Controller SP-200, Terumo) was used. Spontaneous circulation was established 25 minutes later with full recovery of consciousness.

Rapid influenza antigen test (Directigen EZ Flu A+B test; BD, Franklin Lakes, NJ, USA), sputum cultures, blood cultures, and serology tests for respiratory viruses sampled at admission were all negative. On hospital day 2, serum levels of CK-MB and troponin-I peaked at >303 ng/mL and >81 ng/mL, respectively. Follow-up echocardiography 24 hours after initiation of PCPS showed deteriorated left ventricular function, persistent closure of aortic valves and intra-cardiac thrombi in both left atrium and left ventricle, about 24 hours after initiation of mechanical support (Figure 1). On day 3, shock progressed with multi-organ failure. Continuous venovenous hemodialysis

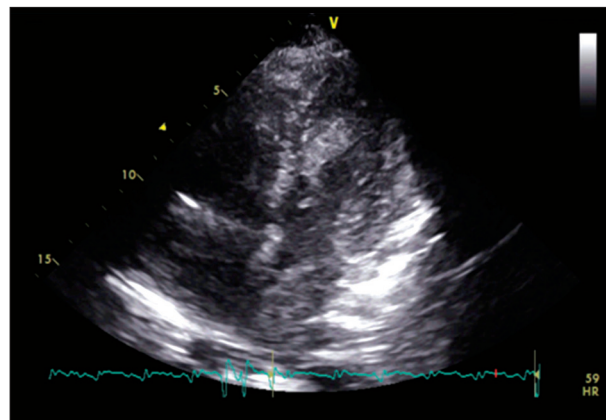


Figure 1. Intra-cardiac thrombi in both left atrium and left ventricle were noticed on apical 4 chamber view of echocardiography 24 hours after initiation of peripheral cardiopulmonary support.

was applied due to metabolic acidosis and oliguria. On day 4, right ventricular function also became seriously depressed and electric activity of heart gradually disappeared. PCPS was therefore shifted to bi-ventricular mechanical supports via cannulations to right atrium, pulmonary trunk, apex of left ventricle, and ascending aorta. Both systems were established using MEDTRONIC Affinity CP Centrifugal blood pumps. Due to pulmonary hemorrhage with severe consolidation of bilateral lungs (Figure 2), a membrane oxygenator was used to achieve adequate oxygenation. Blood flow rate was set at 3.5 L/minute that could maintain mean arterial blood pressure at around 65 mmHg. Endomyocardial biopsy of left ventricle was performed and pathology revealed significant inflammation composed of mainly lymphocytes and some eosinophils. Myocyte damage with necrosis was present but not extensive (Figure 3). In terms of ventilator settings, driving pressure and plateau pressure were set at around 15 and 30 cmH₂O respectively for lung protection. Fiber bronchoscopy was used repeatedly to remove obstructing blood clots in the major airway. On hospital day 13, electric activity of the patient's heart remained absent, and both blood pumps were shifted to Levitronix Centri-Mag (Levitronix LLC, Waltham, MA, USA) ventricular assist systems for better support. The patient was transferred to a transplant center and registered as a candidate for heart transplantation. On day 14 another cannula was inserted into the left common femoral vein for inflow augmentation of right VAD. From day 14 to day 48, the patient suffered from episodes of massive bleeding from the mediastinum and vagina, sternum wound infection with abscess formation, pressure sore infections, and progressive hyperbilirubinemia. Her condition stabilized after debridement, surgical hemostasis, and strong antibiotics use. She underwent 5 courses of therapeutic plasma exchange to prevent antibody mediated rejection and received orthotopic heart transplantation on day 49. Pathologic study of the patient's heart showed pancarditis of both ventricles and no

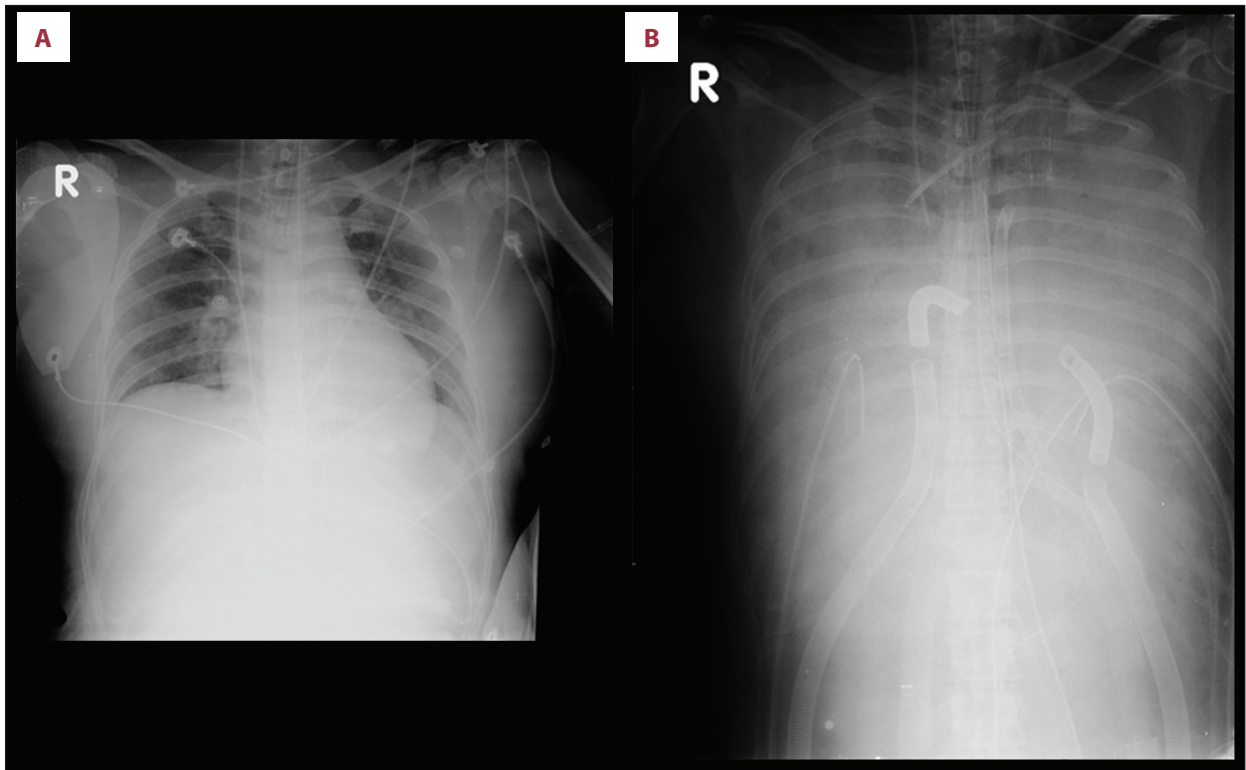


Figure 2. Chest radiography before (A) and after (B) bilateral ventricular assisted device. Bilateral diffuse consolidation B came from severe pulmonary hemorrhage.

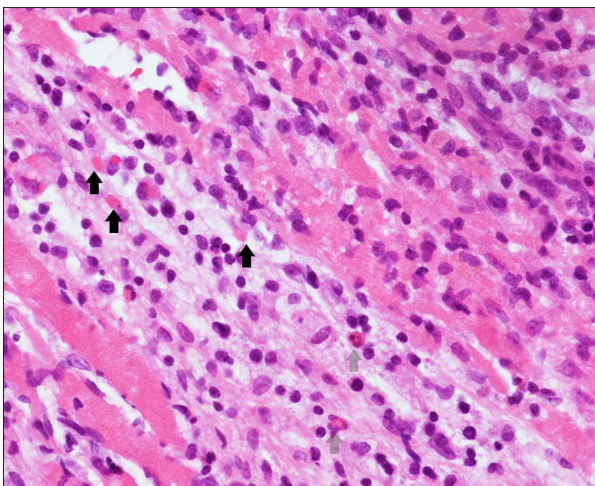


Figure 3. Endomyocardial biopsy taken 6 days after bee sting showed diffuse inflammatory cell infiltrates. Solid black arrows indicate eosinophils, and light grey arrows indicate neutrophils.

specific change of the 3 coronary arteries. VA ECMO was kept till day 58 for post-operative heart failure. Repeated endomyocardial biopsy after transplantation showed no evidence of cellular or humoral rejection. She experienced episodes of septic shock under immunosuppression thereafter and received exploratory laparoscopy and appendectomy on day 93. Extubation

was performed on day 96 and she was discharged on day 101. She remained clinically stable at 3-month follow-up.

Discussion

Clinical manifestation of a Hymenoptera sting varies from localized redness and swelling of sting site, systemic allergic reactions, to fatal anaphylaxis. Cardiac involvement is rare, and the mechanism remained unclear [4]. Kounis syndrome, including vasospastic allergic angina, allergic myocardial infarction, and coronary artery stent thrombosis with occluding thrombus infiltrated by eosinophils and/or mast cells, has been reported to cause deteriorated left ventricular function after bee stings [5–7]. In our patient, both coronary angiography at admission and pathologic study after heart transplantation did not show coronary artery stenosis or allergic thrombi, so she was less likely to be a case of Kounis syndrome. Stress induced cardiomyopathy or Takotsubo disease, could happen after insect bites too, but most reported cases happened after epinephrine injection [8–10]. Our patient had no symptoms of anaphylaxis and no adrenergic medication was prescribed at the time of the bee sting. Her echocardiography did not show typical apical hypokinesis, either. We therefore excluded Takotsubo cardiomyopathy.

Bee or wasp sting related acute myocarditis has been reported occasionally, though most cases were diagnosed clinically without endomyocardial biopsy, and therefore the pathophysiology remains unclear [1,2]. In Marburg Myocarditis Registry comprising records of 1098 biopsied patients with suspected myocarditis or inflammatory dilated cardiomyopathy, none of them was found to be the result of venom induced hypersensitivity reaction [11]. Major histopathologic findings of hypersensitivity myocarditis, according to the analysis of autopsy specimens of 69 cases with drug allergy by Burke et al., included significant mixed lympho-histiocytic infiltrates, presence of eosinophils, and absence fibrosis or granulation tissue. Small foci of myocyte necrosis were present in 54% of patients and non-necrotizing vasculitis was present in 41%. Right ventricle was involved in all but 3 cases and 52% had liver involvement [12]. Our patient's myocardial biopsy taken 6 days after the bee sting showed severe inflammation with lymphocytes and some eosinophils. Myocardial necrosis was not extensive. The picture was compatible with hypersensitivity myocarditis. Clinical course of hypersensitivity myocarditis ranged from mild heart failure symptoms to cardiogenic shock, but most are self-limiting after removal of insulting factor [13]. In patients with intractable cardiogenic shock, mechanical circulatory support

has been proven to be an effective treatment [14]. One study reported half of their adult patients experienced myocardial recovery under either venoarterial extracorporeal membrane oxygenation (VA ECMO) or ventricular assist device (VAD) while 6% of them eventually required heart transplantation [15]. To our knowledge, this is the first reported case of bee sting related fulminant hypersensitivity myocarditis. The patient's heart function rapidly deteriorated and went into standstill. ECMO and bilateral VAD were used to bridge to a successful heart transplantation.

Conclusions

Hypersensitivity myocarditis following bee sting is rare. When myocardia patients do not recover and a patient cannot be weaned from mechanical circulatory support, transplantation could be an effective therapeutic option.

Conflict of interest

None.

References:

1. Kaushal S, Singh S: Wasp bite related myocarditis: A rare manifestation. *Sri Lankan Journal of Anaesthesiology*, 2017; 26: 59–60
2. Dinamithra N, Sivansuthan S: Giant Asian honeybee stings induced acute myocarditis: A case report. *Anuradhapura Medical Journal*, 2013; 7(1): 12–15
3. Agrawal A, Kumar A, Consul S, Yadav A: Scorpion bite, a sting to the heart! *Indian J Crit Care Med*, 2015; 19(4): 233–36
4. Gueron M, Iliia R, Margulia G: Arthropod poisons and the cardiovascular system. *Am J Emerg Med*, 2000; 18(6): 708–14
5. Bharadwaj P, Joshi A, Banerji A, Singh N: Kounis syndrome: Acute myocardial injury caused by multiple bee stings. *Med J Armed Forces India*, 2016; 72(Suppl. 1): S178–81
6. Aminiahidashti H, Laali A, Samakoosh AK, Gorji AMH: Myocardial infarction following a bee sting: A case report of Kounis syndrome. *Ann Card Anaesth*, 2016; 19(2): 375–78
7. Memon S, Chhabra L, Masrur S, Parker MW: Allergic acute coronary syndrome (Kounis syndrome). *Proc (Bayl Univ Med Cent)*, 2015; 28(3): 358–62
8. Ghanim D, Adler Z, Qarawani D et al: Takotsubo cardiomyopathy caused by epinephrine-treated bee sting anaphylaxis: A case report. *J Med Case Rep*, 2015; 9(1): 247
9. Mishra S, Mishra A, Mishra JP: Bee sting: A rare cause of Takotsubo cardiomyopathy. *Int J Cardiol*, 2016; 223: 787–89
10. Geppert G, Radke PW, Kurowski V et al: [Wasp sting, adrenaline injection and acute thoracic pain: An unusual case of stress-induced (tako-tsubo) cardiomyopathy]. *Med Klin (Munich)*, 2010; 105(4): 246–48 [in German]
11. Maisch B, Alter P: Treatment options in myocarditis and inflammatory cardiomyopathy: Focus on IV immunoglobulins. *Herz*, 2018; 43(5): 423–30
12. Burke AP, Saenger J, Mullick F, Virmani R: Hypersensitivity myocarditis. *Arch Pathol Lab Med*, 1991; 115(8): 764–69
13. Grabellus F, Hoffmeier A, Schmitz KJ et al: Resolved hypersensitivity myocarditis after ventricular circulatory assist. *Ann Thorac Surg*, 2003; 76(6): 2102–4
14. Mody KP, Takayama H, Landes E et al: Acute mechanical circulatory support for fulminant myocarditis complicated by cardiogenic shock. *J Cardiovasc Transl Res*, 2014; 7(2): 156–64
15. Ting M, Wang CH, Tsao CI et al: Heart transplantation under mechanical circulatory support for acute fulminant myocarditis with cardiogenic shock: 10 years' experience of a single center. *Transplant Proc*, 2016; 48(3): 951–55