

Protective effect of *Atriplex suberecta* extract against oxidative and apoptotic hepatotoxicity

MOHAMMAD K. PARVEZ¹, AHMAD H. ARBAB¹, MOHAMMED S. AL-DOSARI¹, ADNAN J. AL-REHAILY¹, PERWEZ ALAM¹, KHALID E. IBRAHIM², MANSOUR S. ALSAID^{1,3} and SYED RAFATULLAH³

¹Department of Pharmacognosy, College of Pharmacy, King Saud University; ²Department of Zoology, College of Science, King Saud University; ³Medicinal, Aromatic and Poisonous Plants Research Center, College of Pharmacy, King Saud University, Riyadh 11451, Saudi Arabia

Received August 20, 2017; Accepted January 3, 2018

DOI: 10.3892/etm.2018.5919

Abstract. *Atriplex suberecta* I. Verd is a known phytomedicinal species of *Atriplex*; however, studies into its bioactivity remain inconclusive. The *in vitro* and *in vivo* antioxidative and hepatoprotective potential of *A. suberecta* ethanol-extract (ASEE) was assessed in the present study. 1,1-diphenyl-2-picrylhydrazyl radical scavenging and β -carotene bleaching assays revealed that ASEE possesses free radical scavenging and anti-lipid peroxidative activities. These results were supported by the *in vitro* protection of HepG2 hepatoblastoma cells via abating 2,7-dichlorofluorescein-activated oxidative and apoptotic molecules (caspase-3/-7). In carbon tetrachloride-treated rats, the oral administration of ASEE significantly normalized serum biomarkers of liver function (serum glutamate oxaloacetate, serum pyruvate transaminase, alkaline phosphatase, γ -glutamyl transferase and bilirubin) and the lipid profile (total cholesterol, high-density lipoprotein, low-density lipoprotein, triglycerides and malondialdehyde), including tissue non-protein sulphhydryl and total protein levels. These results were also supported by liver histopathology, which demonstrated that the therapeutic effect of ASEE was comparable to silymarin. Furthermore, phytochemical analysis of ASEE revealed the presence of flavonoids, alkaloids, tannins and saponins. Rutin, an antioxidant flavonoid, was identified using the validated high-performance thin-layer chromatography method. In conclusion, this is the first report on the therapeutic potential of *A. suberecta* against chemical-induced oxidative stress and liver damage.

Introduction

The liver is a vital organ that serves a role in the metabolism of endogenous and exogenous substances where physiological

imbalances cause cellular oxidative stress and the formation of toxic free radicals (1). Increased accumulation of intracellular reactive oxygen and nitrogen species together with decreased antioxidant defense results in hepatotoxicity that may progress to liver dysfunction, carcinoma and failure (1). Therefore, developing preventive therapeutic strategies against hepatic oxidative stress and toxicity remains an important issue. Plants contain a number of bioactive secondary metabolites, including flavonoids, polyphenols, alkaloids, saponins and terpenoids, which possess radical scavenging and hepatoprotective activities (2-6).

The genus *Atriplex* (subfamily Chenopodiaceae), commonly known as lagoon or sprawling saltbush are widely distributed in arid and semi-arid regions, including the Middle East (7). Globally, ~400 species of *Atriplex* herbs and shrubs have been recognized (7,8). Of these, the protein-rich shoots of *A. halimus* are an important fodder for sheep, goats and camels (9). In addition, the protein-rich leaves of *A. lampa* have been proposed as a potential dietary supplement for animals and humans (10). In traditional medicine, *A. halimus* decoction has been used to treat syphilis (11) and its leaves have been used to treat heart disease, diabetes and rheumatism in the Arabian Peninsula (12). In addition, methanol and hexane extracts of the aerial parts of *A. halimus* have been demonstrated to have antimicrobial activity (13). A previous study, in which phytochemical analysis was performed on the aerial parts of *A. halimus*, revealed the presence of myricetin, quercetin, isorhamnetin glycosides, phenolic acids and esters (14). Recently, triterpenoids isolated from *A. laciniata* demonstrated antibacterial, antioxidant and antiurease activities (15), including anticholinesterase effects against Alzheimer's and other neurological disorders (16). The fungicidal effects of *A. semibaccata*, *A. portulacoides* and *A. inflata* have been previously reported (17) and the molluscicidal and larvicidal activities of *A. inflata* have also been identified (18). Furthermore, Godevac *et al* (19) revealed that flavonoid glycosides isolated from the aerial parts of *A. littoralis* exhibited protection against *in vitro* biochemical and cytogenetic damage to human lymphocytes (19).

In Saudi Arabia, of the 10 reported species of saltbush, *A. coriacea*, *A. dimorphostegia*, *A. farinosa*, *A. glauca*, *A. halimus*, *A. leucoclada* and *A. tatarica* are native, whereas *A. canescens*, *A. semibaccata* and *A. suberecta* were introduced

Correspondence to: Dr Mohammad K. Parvez, Department of Pharmacognosy, College of Pharmacy, King Saud University, 23/B2 King Khaled Road, Riyadh 11451, Saudi Arabia
E-mail: khalid_parvez@yahoo.com; mohkhalid@ksu.edu.sa

Key words: *Atriplex suberecta*, antioxidant, hepatoprotection, anti-apoptotic, high-performance thin-layer chromatography, rutin

and naturalized (20). *A. suberecta* L. Verd is a herb with thin and narrow leaves, separate male and female flowers and capsulated fruits (20,21). Compared with other species, there have been few phytochemical and bioactivity studies on *A. suberecta*. To the best of our knowledge, the only previous study into *A. suberecta* leaf protein concentrate, suggested its nutritional value was due to its high lysine content (21). The aim of the present study was to investigate the *in vitro* and *in vivo* antioxidative and hepatoprotective potential of *A. suberecta* ethanol-extract (ASEE), including standardization and validation by chromatography.

Materials and methods

Collection of plant material and extract preparation. The clean and healthy aerial shoots of *Atriplex suberecta* L. Verd were collected from Jazan (Saudi Arabia) and authenticated (voucher specimen no. 16386) by a plant taxonomist at the College of Pharmacy, King Saud University (Riyadh, Saudi Arabia). Briefly, the air-dried leaf powder (300 g) was soaked in 70% ethanol (Merck KGaA, Darmstadt, Germany) for 2 days at room temperature and filtered (Whatman® Filter paper, grade 1; Sigma-Aldrich; Merck KGaA, Darmstadt, Germany). The extraction process was repeated twice with the same solvent, followed by evaporation using a rotary evaporator (BÜCHI Labortechnik AG, Flawil, Switzerland) under reduced pressure at 40°C. The obtained semi-solid ASEE (31.5 g) was stored at -20°C prior to use.

Human hepatoblastoma cell cultures and drugs. The human hepatoblastoma cell line, HepG2 (22) was maintained in RPMI-1640 medium (Gibco; Thermo Fisher Scientific, Inc., Waltham, MA, USA), supplemented with 10% heat-inactivated bovine serum (Gibco; Thermo Fisher Scientific, Inc.), 1X penicillin-streptomycin (Gibco; Thermo Fisher Scientific, Inc.) and 1X sodium pyruvate (GE Healthcare Life Sciences, Logan, UT, USA) at 37°C in a humidified chamber containing 5% CO₂. Silymarin, 2,7-dichlorofluorescein (DCFH), ascorbic acid (all Sigma-Aldrich; Merck KGaA) and gallic acid (Fluka; Honeywell International Inc., Morris Plains, NJ, USA) were also purchased.

Free-radical scavenging activity of ASEE. The free-radical scavenging ability of ASEE against 1,1-diphenyl-2-picrylhydrazyl (DPPH) was evaluated quantitatively as described previously (23) with minor modifications. In brief, 100 µl of different concentrations (31.25, 62.5, 125 and 250 µg/ml) of the ASEE was mixed with 40 µl DPPH (0.2 mM in methanol) in a 96-well microplate. The control was prepared using the solvent (methanol) only in addition to the same amount of DPPH reagent to remove any inherent solvent effect. Ascorbic acid was used as the standard. Following 30 min incubation at 25°C the decrease in absorbance (Abs) was measured at λ=517 nm using a microplate reader (ELx800; BioTek Instruments, Inc., Winooski, VT, USA). The experiment was performed in triplicate and the radical scavenging activity was calculated from the following equation: Percentage radical scavenging activity = [1 - (Abs_{sample}/Abs_{control})] x 100.

Lipid peroxidation assay. The lipid peroxidation activity of ASEE was evaluated using the β-carotene bleaching method

as previously described (24) with minor modifications. Briefly, 0.25 mg β-carotene was dissolved in 0.5 ml chloroform and added to flasks containing 12.5 µg linoleic acid and 100 mg Tween-40. The chloroform was evaporated at 43°C using a Savant™ Universal SpeedVac™ Vacuum system concentrator (Thermo Fisher Scientific, Inc.). The resultant mixture was immediately diluted to 25 ml with distilled water and agitated vigorously for 2-3 min to form an emulsion. A 200 µl aliquot of the emulsion was added to a 96-well plate containing 50 µl ASEE or 500 µg/ml gallic acid (standard). A control containing solvent (emulsion) was also prepared. The test was performed in triplicate and the plate was incubated at 50°C for 2 h. The Abs was read at λ=470 nm at 30 min intervals using a microplate spectrophotometer. The antioxidant activity was estimated using two different methods; initially the kinetic curve was obtained by plotting Abs of each sample against time and then the antioxidant activity was expressed as percentage inhibition of lipid peroxidation using the following equation: Percentage inhibition = [(As120 - Ac120)/(Ac0 - Ac120)] x 100, where As120 and Ac120 are the Abs of the sample and control at 120 min, respectively, and Ac0 is the Abs of the control at 0 min.

In vitro hepatoprotection assay of ASEE. HepG2 cells were seeded in a 96-well flat-bottom plate (0.5x10⁵ cells/well) and grown for 24 h as described above. Liver cytotoxicity was induced by DCFH (IC₅₀ 100 µg/ml) treatment as previously described (25). ASEE was initially dissolved in DMSO (200 mg/ml) and further diluted in RPMI-1640 medium to prepare four doses (25, 50, 100 and 200 µg/ml) and an untreated control containing DMSO only (volume equivalent to 200 µg/ml ASEE). As determined previously (data not shown), the final concentration of DMSO used never exceeded >0.1% and therefore was tolerated by the cultured cells. The culture monolayers were replaced with culture medium containing DCFH (100 µg/ml) and a dose of ASEE, including the untreated as well as the DCFH only-treated controls. The treated cells were incubated for 48 h at 37°C in a CO₂ incubator, followed by an MTT assay (TACS MTT Cell Proliferation Assay kit, Trevigen, Gaithersburg, MD, USA) according to the manufacturer's instructions. Briefly, MTT reagent (10 µl/well) was added to the cells and incubated for 3 h. The lysis buffer (100 µl/well) was gently added and further incubated for ~1.5 h. The Abs was recorded at λ=570 nm by a microplate reader, and data was analyzed using non-linear regression (Excel software 2010; Microsoft Corporation, Redmond, WA, USA) to determine the percentage cell survival as follows: Percentage cell survival = [(Abs_{sample} - Abs_{blank})/(Abs_{control} - Abs_{blank})] x 100.

Anti-apoptotic signaling assay of ASEE. To determine the anti-apoptotic effect of ASEE, caspase-3 and -7 activation was measured using an Apo-ONE® homogenous caspase-3/-7 assay kit (Promega Corporation, Madison, WI, USA) following the manufacturer's protocol. Briefly, HepG2 toxicity was induced with DCFH (100 µg/ml) and treated with ASEE (25, 50, 100 and 200 µg/ml) for 48 h as described above. Caspase-3/-7 reagent (100 µl/per well) was added and mixed by gently rocking the culture plate. Treated cultures were incubated for 5-6 h in the dark at room temperature and the Abs was measured at λ=570 nm. Non-linear regression analysis was

performed to determine the percentage cell proliferation and caspase activity as follows: Percentage cell proliferation = $[(\text{Abs}_{\text{sample}} - \text{Abs}_{\text{blank}})/(\text{Abs}_{\text{control}} - \text{Abs}_{\text{blank}})] \times 100$.

Animals and acute toxicity test. A total of 30 male Wistar rats (weight, 200-220 g; age, 8-9 weeks) received from the Experimental Animal Care Center, King Saud University (Riyadh, Saudi Arabia) were kept in polycarbonate cages in a sterile room under a controlled 12 h dark/light cycle at $25 \pm 2^\circ\text{C}$ with 50-60% humidity. The animals were provided standard rodent chow diet (Grain Silos & Flour Mills Org., Riyadh, Saudi Arabia) and water *ad libitum*. The animals were divided into five test groups ($n=6/\text{group}/\text{cage}$) that were each fed different doses of ASEE (50, 100, 250 and 500 mg/kg.bw), including a control group that was fed normal saline instead of ASEE. All ASEE treated rats, including the control group were observed continuously and uninterruptedly for 1 h and then at 30 min intervals for 4 h for any gross behavioral change and general motor activities, including writhing, convulsion, response to tail pinching, gnawing, pupil size and feeding behavior, and additionally monitored for up to 72 h for any mortality. No behavioral change was observed in the treated or control rats. The present study was approved by the Ethics Committee of the Experimental Animal Care Society (King Saud University, Riyadh, Saudi Arabia) and adhered to its guidelines.

Experimental design and treatment. Upon acclimatization to the laboratory conditions for 1 week, the rats ($n=30$) were randomized and assorted into five groups (GI-GV) with 6 rats in each group. The GI group was fed orally with normal saline (1 ml) and served as the untreated control, the GII group received carbon tetrachloride (CCl_4) in liquid paraffin (1:1) only, 1.25 m/kg intraperitoneally (IP). The GIII, GIV and GV groups also received CCl_4 and the GIII and GIV were also treated with ASEE 100 and 200 mg/kg, respectively whereas GV was treated with silymarin (10 mg/kg) used as a comparison to the current experimental and clinical standard (23,26). All treatment was administered for 3 weeks

Rat sacrifice, blood collection and liver tissue preparation. Following 3 weeks of treatment, rats (weight, 200-220 g) were anesthetized with pentobarbital sodium (50 mg/kg, intraperitoneally; Sigma-Aldrich; Merck KGaA) and sacrificed by cervical dislocation. Death was confirmed by monitoring the heartbeat, absence of withdrawal to paw pinch and non-response of pupils to light. While under anesthesia, rats blood was collected with a 23G needle via cardiac puncture and sera were separated at $1,000 \times g$ for 10 min at 4°C , and stored at -20°C until biochemical analysis. The livers were quickly removed and fixed in 10% neutral buffered formalin (NBF) for 48 h at room temperature. The fixed specimens were processed overnight for dehydration, clearing and paraffin impregnation using an automatic tissue processor (Sakura Finetek Europe B.V., The Netherlands) and cut into $4\text{-}\mu\text{m}$ -thick sections using a rotary microtome (RM2245; Leica Microsystems GmbH, Wetzlar, Germany).

Estimation of serum marker enzymes, bilirubin, lipid profile and total protein. Serum glutamate oxaloacetate (SGOT) (Reflotron GOT, cat. no. 10745120; Roche Diagnostics GmbH,

Mannheim, Germany), serum pyruvate transaminase (SGPT) (Reflotron GPT, cat. no. 10745138; Roche Diagnostics GmbH), alkaline phosphatase (ALP) (Reflotron ALP, cat. no. 11622773; Roche Diagnostics GmbH), γ -glutamyl transferase (GGT) (Reflotron GGT, cat. no. 10745081; Roche Diagnostics GmbH), bilirubin (Reflotron BIL, cat. no. 10905321; Roche Diagnostics GmbH), total cholesterol (TC) (Reflotron Cholesterol, cat. no. 10745065; Roche Diagnostics GmbH), triglycerides (TG) (Reflotron TG, cat. no. 10745049; Roche Diagnostics GmbH) and high-density lipoproteins (HDL) (Reflotron HDL Cholesterol, cat. no. 11208756; Roche Diagnostics GmbH) were estimated using test-specific commercial kits and a Reflotron Plus Analyzer (Woodley Equipment Co., Ltd., Horwich, Lancashire, UK). Very low-density lipoproteins (VLDL) and low-density lipoproteins (LDL) were calculated using the two following standard formulas: $\text{TG}/5$ and $[\text{Cholesterol} - (\text{VLDL} + \text{HDL})]$, respectively. The serum total protein (TP) was estimated using a kit (Crescent Diagnostics, Jeddah, Saudi Arabia) and the following equation: $\text{TP} = (\text{Abs}_{\text{sample}}/\text{Abs}_{\text{standard}}) \times \text{concentration of standard}$.

Determination of tissue malondialdehyde (MDA) and non-protein sulfhydryl (NP-SH). For tissue MDA the method reported by Utley *et al* (27) was followed. Briefly, the liver tissues were homogenized in 0.15 M KCl at 40°C (Potter-Elvehjem type C homogenizer) to give a 10% w/v homogenate. The Abs of the solution was then read at $\lambda=532$ nm and the MDA content (nmol/g wet tissue) was calculated by reference to a standard curve of MDA solution. Hepatic NP-SH was measured according to the method of Sedlak and Lindsay (28). The tissues were homogenized in ice-cold 0.02 mM EDTA and the Abs ($\lambda=412$ nm) was measured following the addition of 5,5'-dithio-bis(2-nitrobenzoic acid) against the control.

Microscopy and histopathological evaluation. Morphological investigation of the cultured HepG2 cells was performed under a microscope to investigate any changes in the cells cultured with different concentrations of ASEE and DCFH at 24 and 48 h post-treatment. The sections of liver tissues fixed in NBF (for 48 h at room temperature) were stained with hematoxylin and eosin for 2-3 min at room temperature as previously described (29). Tissue sections were histopathologically examined under a light microscope (OMX1200C; Nikon Corporation, Tokyo, Japan) and images (at magnifications $\times 200$ and $\times 400$) were captured using a mounted digital camera.

Qualitative phytochemical screening of ASEE. Phytochemical screening tests for major secondary metabolites, including alkaloids, flavonoids, tannins and saponins were performed using standard procedures as described previously (30-32). Briefly, for alkaloids 0.5 mg ASEE was dissolved in 2% hydrochloric acid (Sigma-Aldrich, Merck KGaA) and filtered. Fresh Mayer's reagent (0.68 g mercuric chloride and 2.5 g potassium iodide; Sigma-Aldrich; Merck KGaA) prepared in distilled water (50 ml, final volume) was added to the 3 ml ASEE solution in a test tube. The formation of a yellow precipitate confirmed the presence of alkaloids. For flavonoids, 5 ml ASEE solution was treated with several drops of 20% sodium hydroxide (Sigma-Aldrich; Merck KGaA) in a test tube. The appearance of an intense yellow color that turned colorless

following the addition of diluted hydrochloric acid was indicative of flavonoids. For tannins, 0.25 mg ASEE was dissolved in 10 ml water in a test tube and several drops of 5% ferric chloride (Sigma-Aldrich; Merck KGaA) were added. The development of a brown-green or blue-black color indicated the presence of tannins. For saponins, 0.5 mg ASEE was dissolved in 10 ml water in a test tube and agitated vigorously to form a thick persistent froth, which represented a positive result for saponin.

Standardization of ASEE by the validated high-performance thin-layer chromatography (HPTLC) method. The reverse phase (RP)-HPTLC method was used to standardize the 70% ethanol extract of *A. subrecta* as described previously (33). The chromatography was performed on a 10x10 cm precoated silica gel F254 RP-HPTLC plate using rutin as the standard reference. Several mobile phases were tried to obtain a good resolution and separation of the different compounds present in the ASEE. Based on observations, acetonitrile and water were selected in the ratio of 4:6 as a suitable mobile phase to perform the standardization of ASEE. The standard and the samples were applied on the HPTLC plate by an Automatic TLC Sampler-4 (CAMAG Chemie-Erzeugnisse & Adsorptionstechnik AG, Muttenz, Switzerland). The plate was developed under controlled condition in an Automated Developing Chamber-2 and scanned by TLC Scanner-3 ($\lambda=363$ nm) (both CAMAG Chemie-Erzeugnisse & Adsorptionstechnik AG).

Statistical analysis. Data are presented as the mean \pm standard error of three (*in vitro*) and six (*in vivo*) determinants. Total variation present in a set of data was estimated by one-way analysis of variance followed by Dunnett's post hoc test. Excel 2010 (Microsoft, Tulsa, OK, USA) was used to analyze the data. $P<0.05$ was considered to indicate a statistically significant difference.

Results

Antioxidant activity of ASEE. The DPPH radical scavenging activity of ASEE was observed to be dose-dependent and 15.9, 51.1, 65.9 and 71.5% at concentrations of 31.25, 62.5, 125 and 250 $\mu\text{g/ml}$, respectively, compared with ascorbic acid (Fig. 1). Similarly, in the β -carotene-linoleic acid assay ASEE significantly inhibited lipid peroxidation in a dose-dependent manner ($P<0.01$, $P<0.001$; Fig. 2) confirming its antioxidative potential.

In vitro cytoprotective and anti-apoptotic effect of ASEE on HepG2 cells. Visual observation under a microscope revealed the marked cytotoxic effect of DCFH on the HepG2 cells, which was indicated by apoptosis or altered morphology compared with the untreated cells (data not shown). However, treatment with ASEE resulted in morphological recovery against DCFH toxicity at 24 and 48 h (data not shown). An MTT assay revealed attenuation of the HepG2 cells toxicity by ASEE in a dose-dependent manner (Fig. 3A). Treatment with 50, 100 and 200 $\mu\text{g/ml}$ ASEE significantly restored the cells proliferation to 68, 76 and 110%, respectively compared with the untreated cells ($P<0.001$; Fig. 3A). Furthermore, in the anti-apoptotic signaling assay, ASEE at doses of 50, 100 and 200 $\mu\text{g/ml}$ significantly

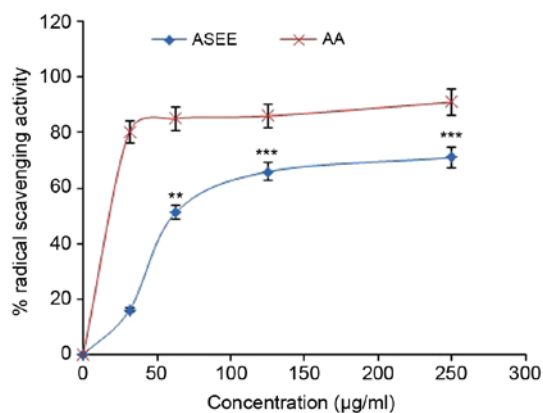


Figure 1. *In vitro* 1,1-diphenyl-2-picrylhydrazyl (DPPH) radical scavenging activity of different concentrations of ASEE and AA (standard control). Data are presented as the mean \pm standard error of the mean ($n=3$). ** $P<0.01$, *** $P<0.001$ vs. AA. ASEE, *Atriplex subrecta* ethanol-extract; AA, ascorbic acid.

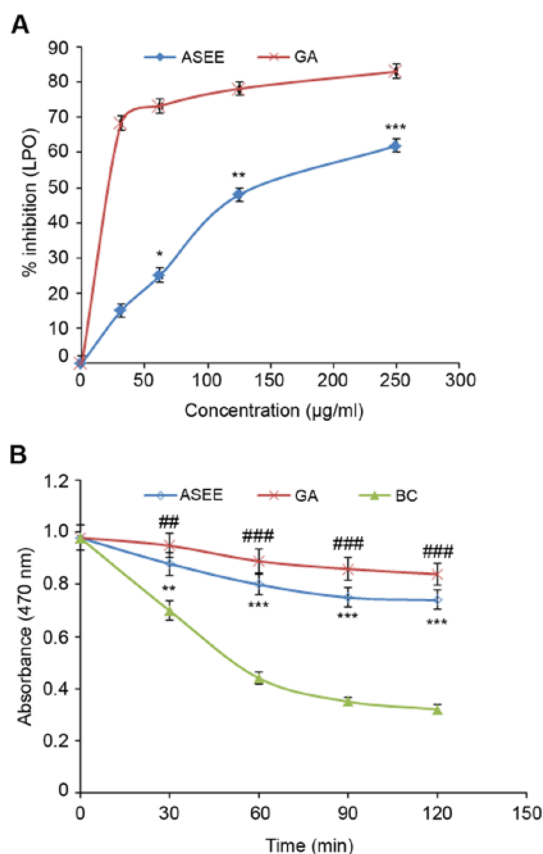


Figure 2. *In vitro* anti-lipid peroxidation activity of ASEE assayed by the β -carotene-linoleic acid bleaching method. (A) β -carotene bleaching rate in the presence of 250 $\mu\text{g/ml}$ ASEE, GA (standard) or BC. (B) Percentage inhibition of lipid peroxidation by different concentrations of ASEE and GA. Data are presented as the mean \pm standard error of the mean ($n=3$). # $P<0.05$, ## $P<0.01$, ### $P<0.001$ vs. BC. * $P<0.05$, ** $P<0.01$, *** $P<0.001$ vs. GA. ASEE, *Atriplex subrecta* ethanol-extract; GA, gallic acid; BC, blank control; LPO, anti-lipid peroxidation activity.

downregulated caspase-3/-7 activity to 76, 43 and 18%, respectively compared with the DCFH-only group ($P<0.001$; Fig. 3B).

Normalization of liver biochemical markers by ASEE. The acute toxicity test revealed the toleration of ASEE

Table I. Effect of ASEE on CCl₄-induced hepatotoxicity-associated parameters in rats.

Treatment group	Dose (mg/kg)	SGOT (U/l)	SGPT (U/l)	ALP (U/l)	GGT (U/l)	Bilirubin (mg/dl)
Control	0	107.45±5.31	28.83±2.2	321.66±13.88	4.06±0.32	0.54±0.01
CCl ₄	0	294.83±8.33 ^b	230.83±9.62 ^b	515.16±13.70 ^b	12.85±0.98 ^b	2.16±0.08 ^b
ASEE + CCl ₄	100	309.33±5.93 ^c	209±7.47 ^c	509.66±12.48 ^c	13±0.53 ^c	2.08±0.05 ^c
ASEE + CCl ₄	200	286±6.29 ^c	193±6.52 ^d	467±11.00 ^c	10.66±0.38 ^c	1.91±0.06 ^a
Silymarin + CCl ₄	10	136.66±6.00 ^e	85.66±4.31 ^e	396.33±7.62 ^e	5.58±0.28 ^e	1.06±0.06 ^e

All values represent mean ± standard error of the mean. ^aP<0.01, ^bP<0.001 vs. the control group. ^cP<0.05, ^dP<0.01, ^eP<0.001 vs. the CCl₄ only group. Analysis of variance, followed by Dunnett's multiple comparison test. SGOT, serum glutamate oxaloacetate; SGPT, serum pyruvate transaminase; ALP, alkaline phosphatase; GGT, γ -glutamyl transferase; CCl₄, carbon tetrachloride; ASEE, *Atriplex suberecta* ethanol-extract.

Table II. Effect of ASEE on CCl₄-induced lipid profile change in rats.

Treatment group	Dose mg/kg	Cholesterol (mg/dl)	Triglycerides (mg/dl)	HDL (mg/dl)	LDL (mg/dl)	VLDL (mg/dl)
Control	0	109.83±3.94	59.01±2.74	55.18±2.4	42.84±3.22	11.8±0.54
CCl ₄	0	206±4.53 ^a	151.16±4.61 ^a	26.25±1.79 ^a	149.51±4.28 ^a	30.23±0.92 ^a
ASEE + CCl ₄	100	192.33±7.03 ^b	133.83±5.61 ^c	26.91±1.3 ^b	138.65±8.21 ^b	26.76±1.12 ^c
ASEE + CCl ₄	200	169.83±5.28 ^d	120±6.67 ^d	26.85±1.14 ^b	118.98±5.94 ^c	24±1.33 ^d
Silymarin + CCl ₄	10	147.66±4.88 ^d	110.16±5.26 ^d	40.41±2.97 ^c	85.21±5.98 ^d	22.02±1.05 ^d

All values represent mean ± standard error of the mean. ^aP<0.001 vs. the control group. ^bP<0.05, ^cP<0.01, ^dP<0.001 vs. the CCl₄ only group. Analysis of variance, followed by Dunnett's multiple comparison test. CCl₄, carbon tetrachloride; ASEE, *Atriplex suberecta* ethanol-extract; HDL, high-density lipoprotein; LDL, low-density lipoprotein; VLDL, very-low-density lipoprotein.

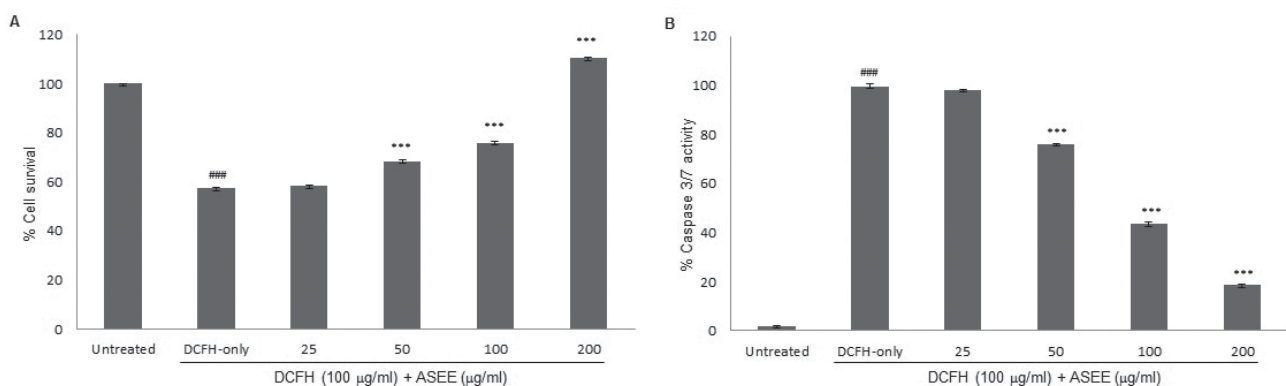


Figure 3. *In vitro* hepatoprotection of HepG2 cells by ASEE. (A) MTT-cell proliferation assay demonstrating the attenuation of DCFH-induced oxidative damage. (B) Apoptotic assay demonstrating the inhibition of DCFH-induced caspase-3/-7 activation. ASEE, *Atriplex suberecta* ethanol-extract; DCFH, 2,7-dichlorofluorescein. Data are presented as the mean ± standard error of the mean (n=3). ###P<0.001 vs. untreated group; ***P<0.001 vs. DCFH-only group.

(500 mg/kg.bw) and healthy survival of the animals (data not shown). Furthermore, the therapeutic potential of ASEE (100 and 200 mg/kg.bw) was examined against CCl₄-induced *in vivo* hepatotoxicity. In CCl₄-only treated rats, serum SGOT, SGPT, GGT ALP and bilirubin levels were significantly elevated compared with the control group (P<0.001; Table I), which demonstrated significant hepatotoxicity. By contrast, the administration of ASEE (200 mg/kg) significantly normalized these parameters in line with silymarin, compared with the control group (P<0.01 and P<0.001; Table I). The SGOT, SGPT, GGT ALP and bilirubin levels in the ASEE (200 mg/kg)

+CCl₄ groups were significantly reduced compared with the CCl₄ only group (P<0.05, P<0.01 and P<0.001). In addition, in the CCl₄-injured rats with altered serum lipid profiles, ASEE (200 mg/kg) treatment significantly reduced the cholesterol, TG and VLDL levels, and improved the HDL level, which was comparable to that of the silymarin treated group (P<0.01 and P<0.001; Table II). Furthermore, compared with the increase in MDA level, a decrease in NP-SH tissue and decrease in TP concentrations in the CCl₄ only group was indicated. ASEE (200 mg/kg) significantly normalized these parameters in CCl₄-injured rats (P<0.01 and P<0.001; Table III).

Table III. Effect of ASEE on biochemical parameters of liver tissues in CCl₄-treated rats.

Treatment group	Dose (mg/kg)	MDA (nmol/g)	NP-SH (nmol/g)	TP (g/l)
Control	0	0.50±0.02	7.39±0.53	113.76±2.81
CCl ₄	0	4.82±0.29 ^b	3.86±0.44 ^b	49.11±1.82 ^a
ASEE + CCl ₄	100	4.63±0.21 ^c	5.38±0.47 ^d	46.30±2.59
ASEE + CCl ₄	200	3.54±0.24 ^d	5.70±0.44 ^d	65.06±2.58 ^e
Silymarin + CCl ₄	10	1.37±0.16 ^e	6.52±0.31 ^e	91.81±4.08 ^e

All values represent mean ± standard error of the mean. ^aP<0.05, ^bP<0.001 vs. the control group. ^cP<0.05, ^dP<0.01, ^eP<0.001 vs. the CCl₄ only group. Analysis of variance, followed by Dunnett's multiple comparison test. CCl₄, carbon tetrachloride; ASEE, *Atriplex suberecta* ethanol-extract; MDA, malondialdehyde; NP-SH, non-protein sulfhydryl; TP, total protein.

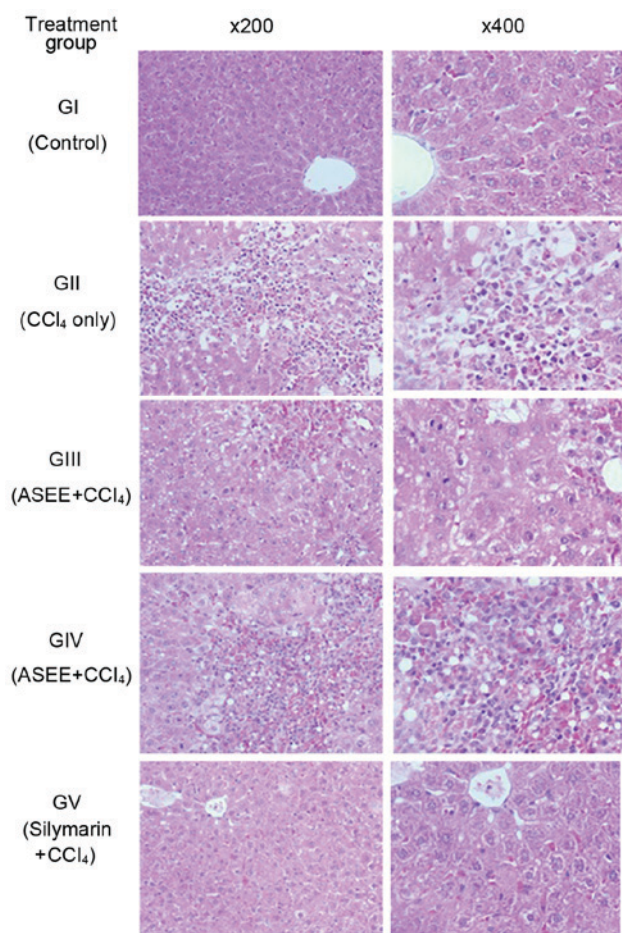


Figure 4. Histopathology of rat livers from all groups. Histopathology analysis revealed rat livers with healthy tissues, normal hepatocytes and central vein (panel GI), CCl₄-injured tissue with necrosis and fatty degenerative changes (panel GII), tissue with congested central vein with necrosis and fatty changes following ASEE supplementation in CCl₄-treated animals (panels GIII and GIV), liver with normal hepatocytes and fully recovered central vein following silymarin supplementation in CCl₄-treated animals (panel GV). CCl₄, carbon tetrachloride; ASEE, *Atriplex suberecta* ethanol-extract.

Histopathological improvement by ASEE. The rat liver histopathological analysis revealed CCl₄-induced necrotic and fatty degenerative changes (panel GII; Fig. 4) as compared to the control group (panel GI; Fig. 4). In the ASEE group

(100 mg/kg.bw/day), congested central vein with mild necrosis and fatty changes were observed (panel GIII; Fig. 4). In addition, the higher dose of ASEE (200 mg/kg.bw/day) normalized the hepatocyte lesion and resulted in a full recovery (panel GIV; Fig. 4), comparable to that observed in the silymarin group (panel GV; Fig. 4). The histopathological data therefore confirmed the *in vivo* hepatoprotective efficacy of ASEE.

Phytochemical screening of ASEE. The qualitative phytochemical screening revealed the presence of flavonoids, alkaloids, tannins and saponins in ASEE (data not shown).

Chromatographic quantification of rutin in ASEE. ASEE was further standardized by a validated RP-HPTLC method using rutin as an antioxidant biomarker. Of the various solvent combinations tested, acetonitrile and water (4:6; v/v) was indicated as the optimal mobile phase for the estimation of rutin in ASEE (Fig. 5A and B). A sharp and compact spot of rutin was identified at R_f=0.67 (Fig. 5C), with clear separation along with different phytoconstituents of ASEE (Fig. 5D) at the optimized mobile phase volume (20 ml) and saturation time (20 min). The estimated content of rutin in ASEE was 1.94 µg/mg (dry weight).

Discussion

Cellular oxidative stress is a process where reactive oxygen and nitrogen species, common toxic products of redox reactions, are increased (1). Oxidative stress is closely associated with the occurrence and development of various conditions, including cirrhosis and carcinoma, which are chronic liver diseases (34). The healthy body has a set of hepatic antioxidant enzymes to prevent and neutralize free-radical induced cellular damage (35). However, exposure to a hepatotoxic agent may cause the generation of free radicals to exceed the protective effects of the antioxidant enzymes (34,35). The effectiveness of hepatoprotective agents is therefore dependent on their ability to attenuate the harmful free radicals and to maintain normal liver functions (3,4,34). In the present study, the *in vitro* and *in vivo* antioxidative and hepatoprotective potential of ASEE was investigated.

DPPH is a molecule containing a stable free radical, which upon receiving an electron from antioxidant agents undergoes reduction in the intensity of its purple solution, and hence in

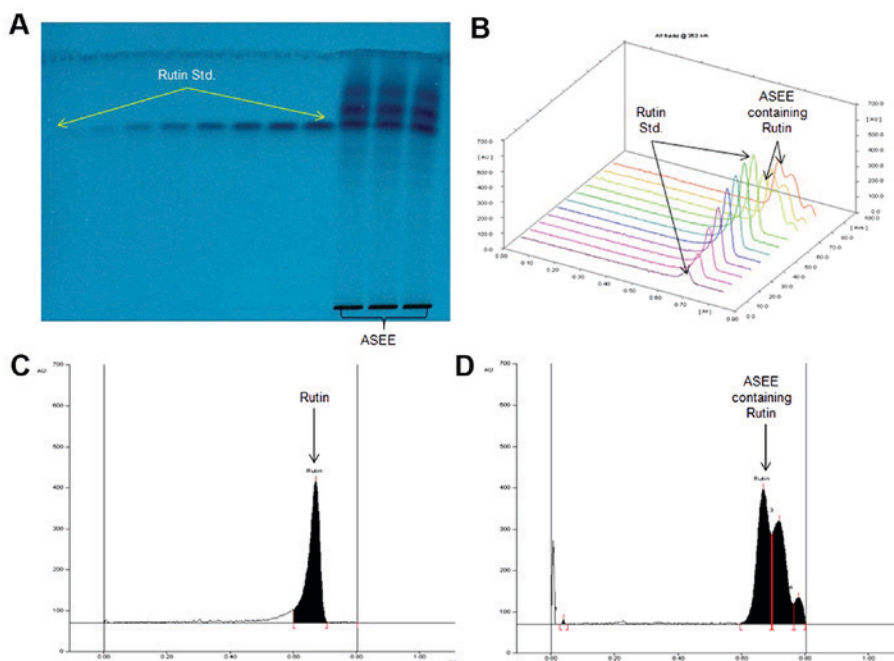


Figure 5. Quantification of rutin in ASEE by validated RP-HPTLC at $\lambda=363$ nm (mobile phase-acetonitrile: water, 4:6, v/v). (A) Pictogram of developed HPTLC plate. (B) 3-D display of all tracks. (C) Chromatogram of standard rutin ($1 \mu\text{g}$ spot-1), peak 1 ($R_f=0.67$). (D) Chromatogram of ASEE containing rutin (peak 2; $R_f=0.67$). RP-HPTLC, reverse-phase high-performance thin-layer chromatography; ASEE, *Atriplex suberecta* ethanol-extract.

absorbance (23). As it is recommended to conduct more than one *in vitro* assay (36), in the present study the antioxidant activity of ASEE was also confirmed by β -carotene bleaching. In the β -carotene bleaching method linoleic acid generated free radicals attack unsaturated β -carotene to undergo oxidation and subsequently cause it to lose its orange color. During *in vitro* DPPH free radical scavenging and β -carotene-linoleic acid bleaching assays, ASEE demonstrated antioxidant activity that appeared to be close to the levels of ascorbic and galic acids. Notably, flavonol glycosides from the aerial parts of *A. halimus* have been revealed to have a clear DPPH radical scavenging ability (37). In addition, septanosides isolated from *A. portulacoides* have recently been highlighted for their *in vitro* antioxidant activity using DPPH, ABTS⁺, Fe³⁺ and catalase assays (38).

DCFH is typically used to estimate *in vitro* oxidative stress generated by free-radicals through the oxidation of DCFH into the fluorescent DCF (39). In addition, it is also used as a potent cytotoxic agent against an array of human cell lines (25). In the *in vitro* hepatoblastoma cell culture model used in the present study, ASEE promoted HepG2 cell proliferation and recovery against DCFH-toxicity in a dose-dependent manner. Apoptotic cell death caused by reactive oxygen or nitrogen molecules is a well known phenomenon (34,35). In the present study the apoptotic-signaling assay revealed a dose-dependent inhibition of caspase-3/-7 activation by ASEE against DCFH-induced HepG2 cell death. In conclusion, ASEE exhibited a promising antioxidative and cytoprotective salutation against chemical-toxicity.

To further confirm the *in vitro* effects, the *in vivo* therapeutic potential of ASEE was examined in CCl₄-injured livers of Wistar rats. CCl₄ is a common hepatotoxin used in the experimental study of liver diseases that induces free-radical generation in liver tissues (23,26). Clinically, CCl₄-induced acute hepatotoxicity manifests as jaundice and elevated

levels of liver enzymes, followed by hepatic necrosis (40). In a previous study, *A. lentiformis* ethanol and n-butanol extracts were reported to have antioxidant activities, including normalization of liver functions by a significant increase in serum alanine transferase levels (41). In the present study, the significant elevation of serum SGOT, SGPT, GGT, ALP, bilirubin and TP was observed in CCl₄-treated rats, which indicates damage to the hepatic tissues. Treatment with ASEE demonstrated its therapeutic ability to normalize the serum biomarkers via attenuation of CCl₄ toxicity at a comparable level to treatment with silymarin. In addition to this, ASEE also normalized the serum cholesterol, TC, LDL and HDL levels in the CCl₄ treated rats.

MDA is used as a marker for lipid peroxidation of the cell membrane, which may cause cell damage (42). The level of MDA was reduced in ASEE treated rats suggesting its cytoprotective and curative activities against CCl₄. In addition, the liver NP-SH level in CCl₄-treated animals was significantly diminished compared with the control group, suggesting oxidative hepatocellular damage. The administration of ASEE or silymarin replenished NP-SH in the CCl₄-treated animals demonstrating its protective activity.

The histopathological changes observed in the liver tissues revealed that the administration of ASEE caused the recovery of hepatic damage. This was revealed by the presence of normal hepatic cords and the absence of necrosis and lesser fatty infiltration in CCl₄-treated rats. These results indicate the *in vivo* hepatoprotective effects of ASEE by abating the chemical-induced oxidative and apoptotic pathways.

Furthermore, the antioxidative and hepatoprotective activities of ASEE may be attributed to the presence of antioxidant flavonoids, alkaloids, polyphenols and saponins as confirmed by the qualitative phytochemical screening. The hepatoprotective activity of flavonoids is due to their ability to scavenge

and reduce cellular free radicals. Rutin, a natural bioflavonoid that is distributed in a range of medicinal plants, is known for its pharmacological properties, including strong its antioxidant and anti-lipid peroxidative activities (43,44). Previously, the *in vivo* hepatoprotective efficacy of rutin in CCl₄-treated BALB/cN mice has been reported (45). The identification of rutin in *A. subrecta* by the validated HTPLC method is in agreement with previous findings and endorses its therapeutic attribution to the prevention and treatment of liver diseases. In conclusion, to the best of our knowledge this is the first investigation into the hepatoprotective effects of *A. subrecta* and it has revealed its promising antioxidative and hepatoprotective potential against chemical-induced *in vitro* and *in vivo* liver injury. These results were supported by the phytochemical analysis and identification of rutin, a well-known antioxidant flavonoid in the plant. Therefore, *A. subrecta* may be a valuable source of natural antioxidant or health protective agent to manage oxidative stress-associated diseases. However, further investigation into its phytochemical properties and active principles, including an assessment of any other therapeutic contributions is required.

Acknowledgements

The authors would like to thank Mr. Malik Saud from the College of Pharmacy, King Saud University (Riyadh, Saudi Arabia) for his assistance with animal care.

Funding

The study was supported by the Deanship of Scientific Research, King Saud University, Riyadh, Saudi Arabia (grant no. RG-1435-053).

Availability of data and materials

All data generated or analyzed during this study are included in this published article.

Authors' contributions

MKP conceptualized and designed the study, participated in the *in vitro* and *in vivo* experiments, analyzed the data and wrote the manuscript. AHA performed the *in vitro* experiments, analyzed data and contributed to writing the paper. MSAD and AJAR collected and extracted the plant material and participated in phytochemical analysis. PA performed the HPTLC study and analyzed data. KEI performed the liver histopathology. MSA and SR participated in the *in vivo* study and data analysis. All authors read and approved the final manuscript.

Ethics approval and consent to participate

The present study was approved by the Ethics Committee of the Experimental Animal Care Society (King Saud University, Riyadh, Saudi Arabia) and adhered to its guidelines.

Consent for publication

Not applicable.

Competing interests

The authors declare that they have no competing interests.

References

- Williams R: Global challenges in liver disease. *Hepatology* 44: 521-526, 2006.
- Aniya Y, Koyama T, Miyagi C, Miyahira M, Inomata C, Kinoshita S and Ichiba T: Free radical scavenging and hepatoprotective actions of the medicinal herb, *Crassocephalum crepidioides* from the Okinawa Islands. *Biol Pharm Bull* 28: 19-23, 2005.
- Farghali H, Canová NK and Zakhari S: Hepatoprotective properties of extensively studied medicinal plant active constituents: Possible common mechanisms. *Pharm Biol* 53: 781-791, 2015.
- Katikova Olu, Kostin IaV and Tishkin VS: Hepatoprotective effect of plant preparations. *Eksp Klin Farmakol* 65: 41-43, 2002 (In Russian).
- Ahmad N, Fazal H, Abbasi BH, Anwar S and Basir A: DPPH free radical scavenging activity and phenotypic difference in hepatoprotective plant (*Silybum marianum* L.). *Toxicol Ind Health* 29: 460-467, 2013.
- Olalye MT and Rocha JB: Commonly used tropical medicinal plants exhibit distinct *in vitro* antioxidant activities against hepatotoxins in rat liver. *Exp Toxicol Pathol* 58: 433-438, 2007.
- Le Houerou HN: The role of saltbushes (*Atriplex* spp.) in arid land rehabilitation in the Mediterranean Basin: A review. *Agroforest Sys* 18: 107-148, 1992.
- Khalil JK, Sawaya WN and Hyder SZ: Nutrient composition of *Atriplex* leaves grown in Saudi-Arabia. *J Range Manage* 39: 104-107, 1986.
- Walker DJ, Lutts S, Sánchez-García M and Correal E: *Atriplex halimus* L.: Its biology and uses. *J Arid Environ* 100: 111-121, 2001.
- Fernández SS, Padilla AP and Mucciarelli S: Protein extraction from *Atriplex lampa* leaves: Potential use as forage for animals used for human diets. *Plant Foods Hum Nutr* 54: 251-259, 1999.
- Rolleston JD: I. The folk-lore of venereal disease. *Br J Vener Dis* 18: 1-13, 1942.
- Said O, Fulder S, Khalil K, Azaizeh H, Kassis E and Said B: Maintaining a physiological blood glucose level with 'Glucoselevel', a combination of four anti-diabetes plants used in the traditional arab herbal medicine. *Evid Based Complement Alternat Med* 5: 421-428, 2008.
- Abdel Rahman SM, Abd-Ellatif SA, Deraz SF and Khalil AA: Antibacterial activity of some wild medicinal plants collected from western Mediterranean coast, Egypt: Natural alternatives for infectious disease treatment. *Afr J Biotechnol* 10: 10733-10743, 2011.
- Clauser M, Dall'Acqua S, Loi MC and Innocenti G: Phytochemical investigation on *Atriplex halimus* L. from Sardinia. *Nat Prod Res* 27: 1940-1944, 2013.
- Ali B, Tabassum R, Riaz N, Yaqoob A, Khatoon T, Tareen RB, Jabbar A, Nasim FU and Saleem M: Bioactive triterpenoids from *Atriplex lasiantha*. *J Asian Nat Prod Res* 17: 843-850, 2015.
- Kamal Z, Ullah F, Ayaz M, Sadiq A, Ahmad S, Zeb A, Hussain A and Imran M: Anticholinesterase and antioxidant investigations of crude extracts, subsequent fractions, saponins and flavonoids of *Atriplex laciniata* L.: Potential effectiveness in Alzheimer's and other neurological disorders. *Biol Res* 48: 21, 2015.
- Boughalleb N, Trabelsi L and Harzallah-Skhiri F: Antifungal activity from polar and non-polar extracts of some Chenopodiaceae wild species growing in Tunisia. *Nat Prod Res* 23: 988-997, 2009.
- Hamed N, Njeh F, Damak M, Ayadi A, Mezghani-Jarraya R and Hammami H: Molluscicidal and larvicidal activities of *Atriplex inflata* aerial parts against the mollusk *Galba truncatula*, intermediate host of *Fasciola hepatica*. *Rev Inst Med Trop Sao Paulo* 57: 473-479, 2015.
- Godevac D, Stanković J, Novaković M, Anđelković B, Dajić-Stevanović Z, Petrović M and Stanković M: Phenolic compounds from *Atriplex littoralis* and their radiation-mitigating activity. *J Nat Prod* 78: 2198-2204, 2015.
- Al-Turki TA, Omer S and Ghafoor A: A synopsis of the genus *Atriplex* L. (Chenopodiaceae) in Saudi Arabia. *Feddes Repertorium* 111: 261-293, 2000.

21. Cid JA, Petenatti E, Arellano M, Muzaber J and de Mucciarelli SL: Biological value of protein from leaves of *Atriplex suberecta*. Arch Latinoam Nutr 41: 421-427, 1991 (In Spanish).
22. López-Terrada D, Cheung SW, Finegold MJ and Knowles BB: HepG2 is a hepatoblastoma-derived cell line. Hum Pathol 40: 1512-1515, 2009.
23. Lee YJ, Kim DB, Lee J, Cho JH, Kim B, Choi HS, Lee BY and Lee OH: Antioxidant activity and anti-adipogenic effects of wild herbs mainly cultivated in Korea. Molecules 18: 12937-12950, 2013.
24. Miller HE: A simplified method for the evaluation of antioxidants. J Am Oil Chem Soc 48: 91, 1971.
25. Arbab AH, Parvez MK, Al-Dosari MS, Al-Rehaily AJ, Al-Sohaibani M, Zaroug EE, AlSaid MS and Rafatullah S: Hepatoprotective and antiviral efficacy of *Acacia mellifera* leaves fractions against hepatitis B virus. Biomed Res Int 2015: 929131, 2015.
26. Parveen R, Baboota S, Ali J, Ahuja A, Vasudev SS and Ahmad S: Effects of silymarin nanoemulsion against carbon tetrachloride-induced hepatic damage. Arch Pharm Res 34: 767-774, 2011.
27. Utley HG, Bernheim F and Hochstein P: Effect of sulfhydryl reagents on peroxidation in microsomes. Arch Biochem Biophys 18: 29-32, 1967.
28. Sedlak J and Lindsay RH: Estimation of total, protein-bound, and nonprotein sulfhydryl groups in tissue with Ellman's reagent. Anal Biochem 25: 192-205, 1968.
29. Culling CF: Handbook of Histopathological and Histochemical Techniques. 3rd edition. Butterworth-Heinemann, Oxford, UK, 1974.
30. Satyajit D, Sarkar ZL and Gray AI: Natural Products Isolation. 2nd edition. Humana Press, Totowa, NJ, 2006.
31. Kar A: Pharmacognosy and Pharmacobiotechnology. 2nd edition. New Age International, New Delhi, India, 2007.
32. Tiwari P, Mandeep BK, Kaur KG and Kaur H: Phytochemical screening and extraction: A review. Interl Pharma Sci 1: 98-1062, 2011.
33. Alam P, Parvez MK, Arbab AH and Al-Dosari MS: Quantitative analysis of rutin, quercetin, naringenin and gallic acid by validated RP- and NP-HPTLC methods for the quality control of anti-HBV active extract of *Guiera senegalensis*. Phrm Biol 55: 1317-1323, 2017.
34. Wang Z, Li Z, Ye Y, Xie L and Li W: Oxidative stress and liver cancer: Etiology and therapeutic targets. Oxid Med Cell Long 2016: 7891574, 2016.
35. Rahman K: Studies on free-radicals, antioxidants, and co-factors. Clin Interv Aging 2: 219-236, 2007.
36. Kedare SB and Singh RP: Genesis and development of DPPH method of antioxidant assay. J Food Sci Technol 48: 412-422, 2011.
37. Kabbash A and Shoeib N: Chemical and biological investigation of some secondary metabolites in *Atriplex halimus* growing in Egypt. Nat Prod Commun 7: 1465-1468, 2012.
38. Ben Nejma A, Nguir A, Ben Jannet H, Hamza MA, Daïch A, Othman M and Lawson AM: New septanoside and 20-hydroxyecdysone septanoside derivative from *Atriplex portulacoides* roots with preliminary biological activities. Bioorg Med Chem Lett 25: 1665-1670, 2015.
39. Rota C, Chignell CF and Mason RP: Evidence for free radical formation during the oxidation of 2'-7'-dichlorofluorescein to the fluorescent dye 2'-7'-dichlorofluorescein by horseradish peroxidase: Possible implications for oxidative stress measurements. Free Radic Biol Med 27: 873-881, 1999.
40. Tirkey N, Pilkhwal S, Kuhad A and Chopra K: Hesperidin, a citrus bioflavonoid, decreases the oxidative stress produced by carbon tetrachloride in rat liver and kidney. BMC Pharmacol 5: 2, 2005.
41. Awaad AS, Maitland DJ, Donia AR, Alqasoumi SI and Soliman GA: Novel flavonoids with antioxidant activity from a Chenopodiaceae plant. Pharm Biol 50: 99-104, 2012.
42. Suhail M, Suhail S, Gupta BK and Bharat V: Malondialdehyde and antioxidant enzymes in maternal and cord blood, and their correlation in normotensive and preeclamptic women. J Clin Med Res 1: 150-157, 2009.
43. Janbaz KH, Saeed SA and Gilani AH: Protective effect of rutin on paracetamol- and CCl4-induced hepatotoxicity in rodents. Fitoterapia 73: 557-563, 2002.
44. Hosseinzadeh H and Nassiri-Asl M: Review of the protective effects of rutin on the metabolic function as an important dietary flavonoid. J Endocrinol Invest 37: 783-788, 2014.
45. Domitrović R, Jakovac H, Vasiljev Marchesi V, Vladimir-Knežević S, Cvijanović O, Tadić Z, Romić Z and Rahelić D: Differential hepatoprotective mechanisms of rutin and quercetin in CCl(4)-intoxicated BALB/cN mice. Acta Pharmacol Sin 33: 1260-1270, 2012.



This work is licensed under a Creative Commons Attribution-NonCommercial-NoDerivatives 4.0 International (CC BY-NC-ND 4.0) License.