

Access this article online	
Quick Response Code:	
	
Website: www.e-tjo.org	
DOI: 10.4103/tjo.tjo_12_20	

Alteration of expression pattern of transient receptor potential vanilloid 2 and transient receptor potential vanilloid 3 in ocular surface neoplasm

Ai Izutani-Kitano¹, Yuka Okada^{2*}, Kana Ichikawa², Peter Sol Reinach³, Shizuya Saika²

Abstract:

PURPOSE: We determined if the immunohistochemical expression pattern of transient receptor potential vanilloid (TRPV) family members and TRP ankyrin 1 (TRPA1) differs among a healthy conjunctival epithelium and diseased epithelia.

MATERIALS AND METHODS: Subjects include a normal conjunctival epithelium, pterygium epithelium, epithelial dysplasia or carcinoma *in situ*.

RESULTS: TRPV1, TRPV4 or TRPA1 was detected in both the cytoplasm and nuclei, or in either the nuclei or cytoplasm, of these different epithelial layers, respectively. There was no difference in the expression pattern of these three TRP isoforms. On the other hand, the expression patterns of TRPV2 and TRPV3 differed dramatically among these different subjects. TRPV2 was observed in the basal layer epithelium of a normal conjunctiva and pterygium. Its pattern was scattered in this region, although TRPV2 was absent throughout most of the dysplastic epithelium. TRPV2 was detected only in some of the suprabasal epithelial cells of a carcinoma *in situ*. TRPV3 was faintly detected in the cytoplasm of all the cell layers and also in the nuclei of some of the basal cells in a normal conjunctiva and in the pterygia epithelium, while *in situ* it was uniformly expressed in all of the dysplasia and carcinoma nuclei in all epithelial cell layers.

CONCLUSION: These results suggest that TRPV2 and TRPV3 expression pattern analysis might be potential diagnostic markers of ocular surface epithelial disorders.

Keywords:

Carcinoma *in situ*, conjunctiva, dysplasia, epithelium, human, immunohistochemistry, transient receptor potential

Introduction

Epithelial neoplasm may occur in the ocular surface epithelium. Although histological diagnosis is based on the analysis of simple histology, more definitive, but a simple diagnostic tool is needed to avoid misdiagnose and define the border between neoplastic and unaffected epithelia.^[1-3]

The transient receptor potential (TRP)

This is an open access journal, and articles are distributed under the terms of the Creative Commons Attribution-NonCommercial-ShareAlike 4.0 License, which allows others to remix, tweak, and build upon the work non-commercially, as long as appropriate credit is given and the new creations are licensed under the identical terms.

For reprints contact: WKHLRPMedknow_reprints@wolterskluwer.com

channel superfamily consists of six different subfamilies in different animal types.^[4,5] Each subfamily contains a set of members, each of which is widely and differentially expressed in various tissues. Each TRP member has signature activating ligands, and some are thermosensitive and mediate pleiotropic functions in the maintenance of tissue homeostasis and pathobiology of diseases. Some of the functions that TRP channels modulate include cell migration, proliferation, cell death, and nerve function.

How to cite this article: Izutani-Kitano A, Okada Y, Ichikawa K, Reinach PS, Saika S. Alteration of expression pattern of transient receptor potential vanilloid 2 and transient receptor potential vanilloid 3 in ocular surface neoplasm. Taiwan J Ophthalmol 2020;10:106-10.

¹Department of Ophthalmology, Kihoku Hospital, Wakayama Medical University, Wakayama, ²Department of Ophthalmology, School of Medicine, Wakayama Medical University, Wakayama, Japan, ³School of Ophthalmology and Optometry, Wenzhou Medical University, Wenzhou, China

*Address for correspondence:

Dr. Yuka Okada, Department of Ophthalmology, Wakayama Medical University School of Medicine, 811-1 Kimiidera, Wakayama, 641-0012, Japan.
E-mail: yokada@wakayama-med.ac.jp

Submission: 15-10-2019
Accepted: 14-03-2020
Published: 19-05-2020

These cell behaviors exert cell type-specific actions, such as tissue repair, tumor growth, or modulation of inflammation.^[6] The TRP channel superfamily includes TRP vanilloid (V1–V4), TRP canonical[®], TRP melastatin (M), TRP polycystin (P), TRP mucolipin (ML), TRP no-mechanoreceptor potential (N), and TRP ankyrin (A) subfamily. Each member of these subfamilies exhibits a specific expression pattern in human skin, which could be altered in neoplastic cells of cutaneous malignancy.^[7-9] The transient receptor potential vanilloid (TRPV) 3 signal is one of those whose expression is variable in these different cell types and reportedly involved in regulating corneal epithelial proliferation.^[10] We previously reported that TRP members are expressed in corneal layers^[11] and that these components modulate inflammatory fibrosis induced by an alkali burn. This tissue is composed of stratified epithelium and stroma and an innermost endothelial single-cell layer.^[12-16] Although the expression pattern of TRP family members in healthy cornea and conjunctiva as well as pterygium was described,^[17,18] there are no available reports describing their expression pattern in ocular surface neoplastic lesions.

We previously reported that alterations of the expression pattern of components of the activator protein-1 transcription factor, one of the major signaling transmitters consisted of c-Fos and C-Jun proteins, could provide a marker of the level of malignancy in ocular surface neoplasm.^[1] In the current study, we examined the differential expression pattern of different TRP superfamily members. The results show that the TRPV2 and TRPV3 expression pattern is dissimilar between malignant and dysplastic cells and that in healthy conjunctival or pterygium epithelium.

Materials and Methods

The study was approved by the Institutional Review Board of Wakayama Medical University, Wakayama, Japan (Approval Number 1490), and complied fully with the Declaration of Helsinki.

Subjects

Samples were collected from each patient at the Department of Ophthalmology, Wakayama Medical University Hospital, Wakayama, Japan, after receiving their informed consent between 2010 and 2015 [Table 1]. Excised tissue was fixed in 10% formalin and routinely embedded in paraffin. Sections were cut, rehydrated, and processed for histological diagnosis and immunohistochemistry for each of the following TRP superfamily members (TRPV1, TRPV2, TRPV3, TRPV4, and transient receptor potential ankyrin [TRPA] 1), as previously reported.^[1] In brief, each primary antibody was allowed to react overnight at 4°C. Antibody complex was visualized with Vector stain ABC kit (Vector

Laboratories, CA, USA). Light microscopy was used to examine TRP channel expression patterns. The procedure of the antigen retrieval was not performed. Negative control staining was performed with the omission of the primary antibodies. Antibodies used are listed in Table 2.

Results

Histology

Histology by hematoxylin and eosin staining indicated the diagnosis of each sample. Frames a, b, c, and d in Figure 1 show healthy bulbar conjunctiva, primary pterygium, epithelial dysplasia, and carcinoma *in situ*, respectively. Immunohistochemistry showed specific TRP expression patterns in each of the tissue samples, as described below. Negative control staining was performed with the omission of the primary antibody (data not shown).

Transient receptor potential vanilloid 1, transient receptor potential vanilloid 4, and transient receptor potential ankyrin 1

TRPV1 was mainly delimited in the cytoplasm of the epithelial cells throughout the layers in a normal healthy subject, pterygium, epithelial dysplasia, and carcinoma *in situ* [Figure 2a-d]. TRPV4 immunoreactivity was present in the nuclei of each of the epithelial cell layers in a normal healthy subject, pterygium, epithelial dysplasia, and carcinoma *in situ* [Figure 2e-h]. TRPA1 was detected in the cytoplasm and nuclei of epithelial cells in all the specimens regardless of the diagnosis [Figure 2i-l].

Transient receptor potential vanilloid 2

The TRPV2 expression pattern differed dramatically among tissue samples obtained from subjects with a

Table 1: Details of the subjects

Case #	Diagnosis	Age	Gender
1	Healthy bulbar conjunctiva	28	Female
2	Healthy bulbar conjunctiva	62	Female
3	Pterygium	71	Female
4	Pterygium	71	Female
5	Epithelial dysplasia	73	Male
6	Epithelial dysplasia	74	Male
7	Carcinoma <i>in situ</i>	57	Male
8	Carcinoma <i>in situ</i>	81	Female
9	Carcinoma <i>in situ</i>	85	Male

Table 2: Primary antibodies used in the study

Primary antibody	Company	Dilution rate	Host
TRPV1	Neuromics	1:100	Rabbit
TRPV2	ATLAS	1:200	Rabbit
TRPV3	Bioss	1:200	Rabbit
TRPV4	Abcam	1:200	Rabbit
TRPA1	Osenses	1:100	Rabbit

TRPV: Transient receptor potential vanilloid, TRPA: TRP ankyrin 1

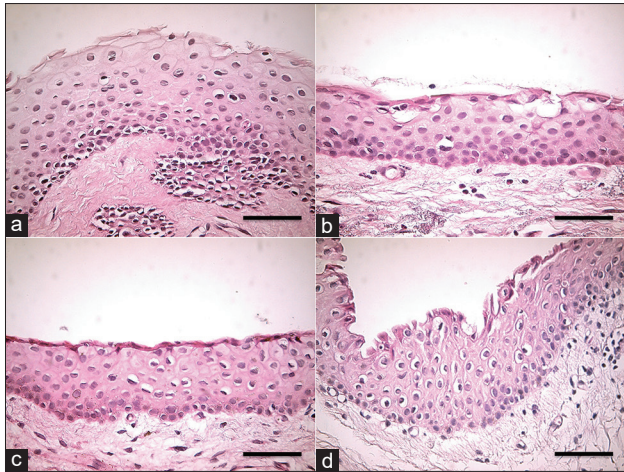


Figure 1: Histological characterization of hematoxylin and eosin staining patterns in different ocular tissue types. Frames a, b, c, and d show healthy bulbar conjunctiva, pterygium, epithelial dysplasia, and carcinoma *in situ*, respectively. Scale bar designates 100 μm

different diagnosis. This TRP isoform was observed in the cytoplasm of the epithelial basal layer cells of a normal healthy conjunctiva [Figure 3a] and pterygium [Figure 3b]. In a sample of epithelial dysplasia, some of the basal epithelial cells expressed TRPV2 in the cytoplasm, while others did not stain for it [Figure 3c]. On the other hand, carcinoma *in situ* exhibited quite a unique TRPV2 expression pattern. It was detected in some of the neoplastic suprabasal cells but was absent in the basal cells and superficial cells [Figure 3d].

Transient receptor potential vanilloid 3

The TRPV3 expression pattern also markedly differed among tissue samples obtained from subjects with a different diagnosis. This TRP channel isoform was present in the cytoplasm of the epithelial cells in all its layers and also in the nuclei of some of the basal cells but less frequently in the conjunctival and pterygium suprabasal cell nuclei [Figure 4a and b]. In epithelial dysplasia tissue samples and carcinoma *in situ*, TRPV3 expression was present in all of the epithelial cell layers in all their nuclei [Figure 4c and d].

Discussion

In our current study, we detected some of the TRP superfamily members; namely, TRPV1–4 and TRPA1 isoform were found in both normal ocular surface epithelial and ocular surface pathology. The following expression patterns were identified: (1) the TRPV1, TRPV4, and TRPA1 expression patterns were similar among healthy conjunctival epithelium, pterygium epithelium, and ocular surface epithelial dysplasia and *in situ* carcinoma and (2) TRPV2 and TRPV3 expression patterns were quite dissimilar among these different tissue types, although the number of the samples

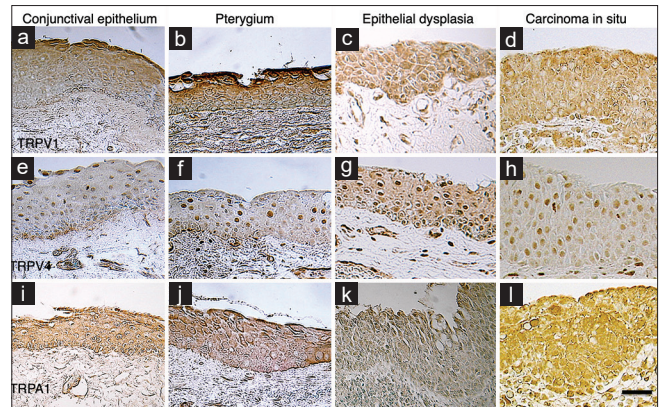


Figure 2: Immunohistochemical characterization of transient receptor potential vanilloid 1, transient receptor potential vanilloid 4, and transient receptor potential ankyrin 1 expression patterns in ocular epithelial tissues. Transient receptor potential vanilloid 1 immunoreactivity was mainly present in all of the conjunctival epithelial layers in the cytoplasm irrespective of the presence or absence of pterygium, epithelial dysplasia, or carcinoma (a-d). Transient receptor potential vanilloid 4 was present in the nuclei throughout all the epithelial cell layers in a normal healthy subject, pterygium, epithelial dysplasia, and carcinoma (e-h). Transient receptor potential ankyrin 1 was present in the cytoplasm and nuclei of epithelial cells in all of the specimens regardless of the tissue diagnosis (i-l). Scale bar designates 100 μm

was limited. In this series of different cases, TRPV2 was mainly detected in the epithelial basal cells of the conjunctiva and pterygium. While during malignancy progression, the TRPV2 immunoreactivity in the basal cells was attenuated in epithelial dysplasia. Its expression became evident in the suprabasal cells in carcinoma *in situ* in association with prominent reduction of TRPV2 expression in basal cells. TRPV3 was weakly expressed in the cytoplasm of a healthy conjunctiva and pterygium with sporadic nuclear expression. On the other hand, in the neoplastic lesions, TRPV3 was markedly apparent throughout the layers in the epithelial nuclei of dysplastic or neoplastic tissues. These findings suggest that immunohistochemical analysis of TRPV2 and TRPV3 expression patterns might be a potential diagnostic marker to distinguish nonmalignant epithelial disorders from malignant/premalignant epithelial diseases.

It is also to be cleared if the expression patterns of TRPV2 and TRPV3 correlate with the cell behaviors of the neoplastic epithelial cells. TRPV3 is reportedly involved in cell proliferation of ocular surface epithelia or in inflammatory action in epidermal keratinocytes.^[10,19] It was suggested that the upregulation of both TRPV2 and TRPV3 might be related to the degree of epithelial tumor malignancy.^[20,21]

A study indicated a reduction of TRPV1, TRPV2, and TRPV4 expression levels and an increased level of TRPV3 expression in epithelium of a primary pterygium as compared with normal conjunctival.^[17] The findings in the pterygial epithelium were not identical to our data, although the exact reason, for example, racial

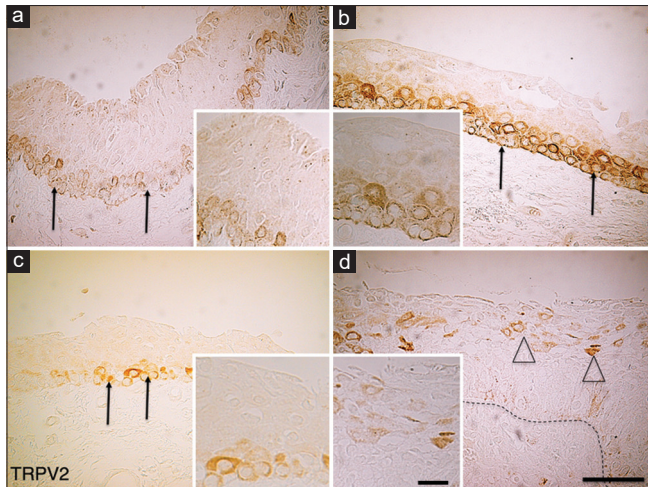


Figure 3: Immunohistochemical characterization of transient receptor potential vanilloid 2 expression patterns in healthy bulbar conjunctiva, pterygium, epithelial dysplasia, and carcinoma, respectively. Transient receptor potential vanilloid 2 was present in the epithelial basal layer in the cytoplasm of conjunctiva (a, arrows) and pterygium cells (b, arrows). (c) In an epithelial dysplasia tissue, some of the basal epithelial cells expressed transient receptor potential vanilloid 2 in the cytoplasm while others did not stain for it. (d) Transient receptor potential vanilloid 2 was present in some of the neoplastic suprabasal cells (open arrowheads) but not in the basal cells and superficial cells. Dotted line in Frame D designates localization of the basement membrane. Insert in each frame shows higher magnification picture. Scale bar designates 100 μm (a-d) or 25 μm (for inserts)

difference, is to be explored. These authors report that the expression of TRPV3 was more marked in the pterygial epithelium as compared with a healthy conjunctival epithelium that coincides with our data. The epithelium of pterygium tissues exhibited strong, mainly nuclear, TRPV4. Although the exact roles of nuclear TRPV4 are to be explored, nuclear TRPV4 was reportedly in other cell types, i.e., retinal pigment epithelial cells.^[22]

Another report by a different group reported that in rabbit and human eyes, TRPV1 protein expression was limited to the conjunctival basal layer.^[18] Our finding indicates that TRPV1 was instead present throughout all of the conjunctival epithelial layers. There is no explanation for this discrepant result and requires further investigation. One possibility is that the antibodies used had different binding characteristics.

The use of TRP expression patterns to provide signature diagnostic markers of different conditions was performed in the skin. TRPV1, TRPV2, TRPV3, TRPV4, and TRPA1 are present in the cells of healthy epidermis and epidermal tumors.^[7-9] TRPV4 expression was reportedly suppressed in skin cancer but not in ocular surface carcinoma.^[9] The epidermis is a stratified epithelium in the body, but unlike the conjunctival epithelium, it is keratinized. Therefore, it is possible that its TRP superfamily member expression pattern in epidermal keratinocytes differs from that in the conjunctival stratified epithelium. It remains to be determined if TRP member expression pattern

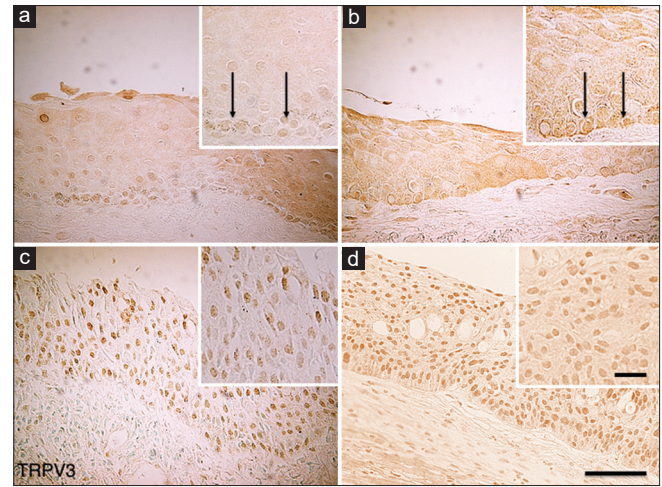


Figure 4: Immunohistochemical characterization of *in situ* transient receptor potential vanilloid 3 expression patterns in healthy bulbar conjunctiva, pterygium, epithelial dysplasia, and carcinoma, respectively. Transient receptor potential vanilloid 3 immunoreactivity was detected in the cytoplasm of the epithelial cells and also in the nuclei of some of the basal cells (arrows) and less frequently in the nuclei of the suprabasal cells in conjunctiva (a) and pterygium (b). In an epithelial dysplasia tissue (c) and carcinoma (d), transient receptor potential vanilloid 3 was markedly expressed throughout the epithelial layers in the cell nuclei. Insert in each frame shows higher magnification picture. Scale bar designates 100 μm (a-d) or 25 μm (for inserts)

alteration underlies how epithelial carcinogenesis develops.

Financial support and sponsorship

Nil.

Conflicts of interest

The authors declare that there are no conflicts of interests of this paper.

References

1. Saika S, Kawashima Y, Miyamoto T, Okada Y, Katoh T, Shirai K, *et al.* Immunolocalization of transcription factor AP1 in human ocular surface epithelia. *Curr Eye Res* 1999;18:477-89.
2. Alves LF, Fernandes BF, Burnier JV, Mansure JJ, Maloney S, Odashiro AN, *et al.* Expression of SIRT1 in ocular surface squamous neoplasia. *Cornea* 2012;31:817-9.
3. Zoroquiain P, Faingold D, Algahmdi S, Vila N, Logan P, Sanft DM, *et al.* Analysis of HSP90 expression is valuable in the differential diagnosis of ocular surface squamous lesions. *Am J Clin Pathol* 2016;145:385-92.
4. Li H. TRP channel classification. *Adv Exp Med Biol* 2017;976:1-8.
5. Baez D, Raddatz N, Ferreira G, Gonzalez C, Latorre R. Gating of thermally activated channels. *Curr Top Membr* 2014;74:51-87.
6. Feng J, Yang P, Mack MR, Dryn D, Luo J, Gong X, *et al.* Sensory TRP channels contribute differentially to skin inflammation and persistent itch. *Nat Commun* 2017;8:980.
7. Lehen'kyi V, Raphaël M, Prevarskaya N. The role of the TRPV6 channel in cancer. *J Physiol* 2012;590:1369-76.
8. Atoyan R, Shander D, Botchkareva NV. Non-neuronal expression of transient receptor potential type A1 (TRPA1) in human skin. *J Invest Dermatol* 2009;129:2312-5.
9. Fusi C, Materazzi S, Minocci D, Maio V, Oranges T, Massi D, *et al.* Transient receptor potential vanilloid 4 (TRPV4) is downregulated in keratinocytes in human non-melanoma skin cancer. *J Invest*

- Dermatol 2014;134:2408-17.
10. Yamada T, Ueda T, Ugawa S, Ishida Y, Imayasu M, Koyama S, *et al.* Functional expression of transient receptor potential vanilloid 3 (TRPV3) in corneal epithelial cells: Involvement in thermosensation and wound healing. *Exp Eye Res* 2010;90:121-9.
 11. Mergler S, Valtink M, Takayoshi S, Okada Y, Miyajima M, Saika S, *et al.* Temperature-sensitive transient receptor potential channels in corneal tissue layers and cells. *Ophthalmic Res* 2014;52:151-9.
 12. Okada Y, Reinach PS, Shirai K, Kitano A, Kao WW, Flanders KC, *et al.* TRPV1 involvement in inflammatory tissue fibrosis in mice. *Am J Pathol* 2011;178:2654-64.
 13. Okada Y, Shirai K, Reinach PS, Kitano-Izutani A, Miyajima M, Flanders KC, *et al.* TRPA1 is required for TGF- β signaling and its loss blocks inflammatory fibrosis in mouse corneal stroma. *Lab Invest* 2014;94:1030-41.
 14. Okada Y, Shirai K, Miyajima M, Reinach PS, Yamanaka O, Sumioka T, *et al.* Loss of TRPV4 function suppresses inflammatory fibrosis induced by alkali-burning mouse corneas. *PLoS One* 2016;11:e0167200.
 15. Sumioka T, Okada Y, Reinach PS, Shirai K, Miyajima M, Yamanaka O, *et al.* Impairment of corneal epithelial wound healing in a TRPV1-deficient mouse. *Invest Ophthalmol Vis Sci* 2014;55:3295-302.
 16. Nidegawa-Saitoh Y, Sumioka T, Okada Y, Reinach PS, Flanders KC, Liu CY, *et al.* Impaired healing of cornea incision injury in a TRPV1-deficient mouse. *Cell Tissue Res* 2018;374:329-38.
 17. Assimakopoulou M, Pagoulatos D, Nterma P, Pharmakakis N. Immunolocalization of cannabinoid receptor type 1 and CB2 cannabinoid receptors, and transient receptor potential vanilloid channels in pterygium. *Mol Med Rep* 2017;16:5285-93.
 18. Martínez-García MC, Martínez T, Pañeda C, Gallego P, Jimenez AI, Merayo J. Differential expression and localization of transient receptor potential vanilloid 1 in rabbit and human eyes. *Histol Histopathol* 2013;28:1507-16.
 19. Szöllősi AG, Vasas N, Angyal Á, Kistamás K, Nánási PP, Mihály J, *et al.* Activation of TRPV3 regulates inflammatory actions of human epidermal keratinocytes. *J Invest Dermatol* 2018;138:365-74.
 20. Li X, Zhang Q, Fan K, Li B, Li H, Qi H, *et al.* Overexpression of TRPV3 correlates with tumor progression in non-small cell lung cancer. *Int J Mol Sci* 2016;17:437.
 21. Kudou M, Shiozaki A, Yamazato Y, Katsurahara K, Kosuga T, Shoda K, *et al.* The expression and role of TRPV2 in esophageal squamous cell carcinoma. *Sci Rep* 2019;9:16055. doi: 10.1038/s41598-019-52227-0.
 22. Arredondo Zamarripa D, Noguez Imm R, Bautista Cortés AM, Vázquez Ruíz O, Bernardini M, Fiorio Pla A, *et al.* Dual contribution of TRPV4 antagonism in the regulatory effect of vasoconstrictors on blood-retinal barrier permeability: Diabetic milieu makes a difference. *Sci Rep* 2017;7:13094. doi: 10.1038/s41598-017-13621-8.