

---

## Successful percutaneous treatment of pulsatile tinnitus, a rare symptom of carotid artery stenosis

 Fatih Yılmaz\*,  Ahmet Karaduman\*,  İsmail Balaban\*,  
 Murat Veliöđlü\*\*,  Nuri Havan\*\*

Departments of \*Cardiology, and \*\*Radiology, Kartal Koşuyolu Training and Research Hospital; İstanbul-Turkey

### Introduction

Carotid artery stenosis is one of the primary reasons of cerebrovascular events. Additionally, carotid artery stenosis can lead to dizziness, imbalance, and sudden severe headaches. Furthermore, a rare and noteworthy symptom of carotid artery stenosis is pulsatile tinnitus (1, 2). The purpose of this case report is to

present the successful percutaneous treatment of the petrosal segment of the internal carotid artery (ICA) stenosis that caused pulsatile tinnitus.

## Case Report

A 60-year-old male patient had suffered a right-sided transient ischemic attack twice in the past three months. Additionally, for the past six months, the patient had pulsatile tinnitus, and the underlying cause could not be detected. The patient did not have any additional disease apart from hypertension. No murmurs were detected in the carotid arteries. The carotid Doppler ultrasonography (USG) showed no stenosis in the extracranial part of ICA. MR angiography revealed 90% stenosis of the petrosal segment of the left ICA; therefore, the patient was referred to us.

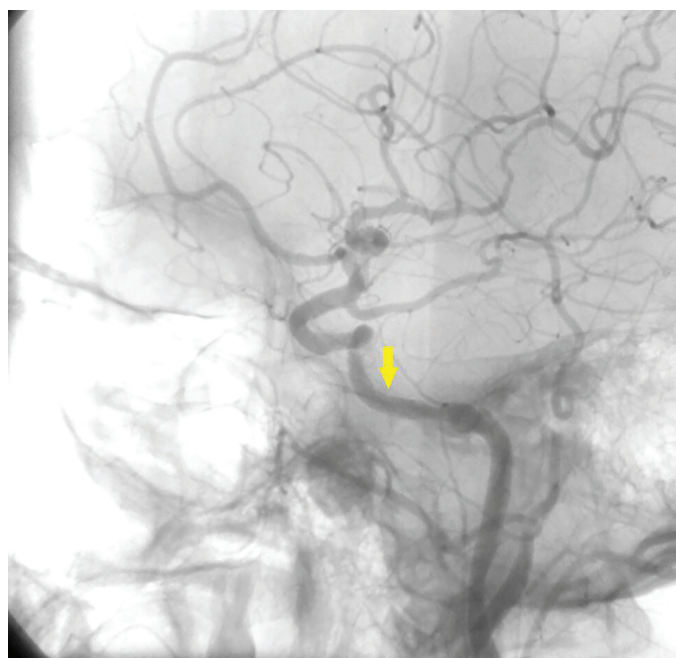
The patient was taken to the catheter laboratory for percutaneous intervention of the carotid artery. A 6F sheath was placed in the right femoral artery, whereas a 6F-Right guiding catheter was used to reach the left carotid artery. Digital subtraction angiogram (DSA) revealed 90% stenoses in the petrosal segment of the left ICA (Fig. 1a, Video 1). A total of 75 U/kg of unfractionated heparin was administered during the procedure. The lesion was passed with a 0.014-inch floppy guidewire. Thereafter, a 3.0x15 mm drug-eluting stent was implanted (Fig. 1b, Video 2). The patient reported that his tinnitus suddenly disappeared during the procedure. The procedure was terminated without complications. Upon discharge, the patient was prescribed 100 mg acetylsalicylic acid and 75 mg clopidogrel once a day.

The patient was followed up with dual antiaggregant therapy for six months and then followed up with clopidogrel 75 mg once a day.

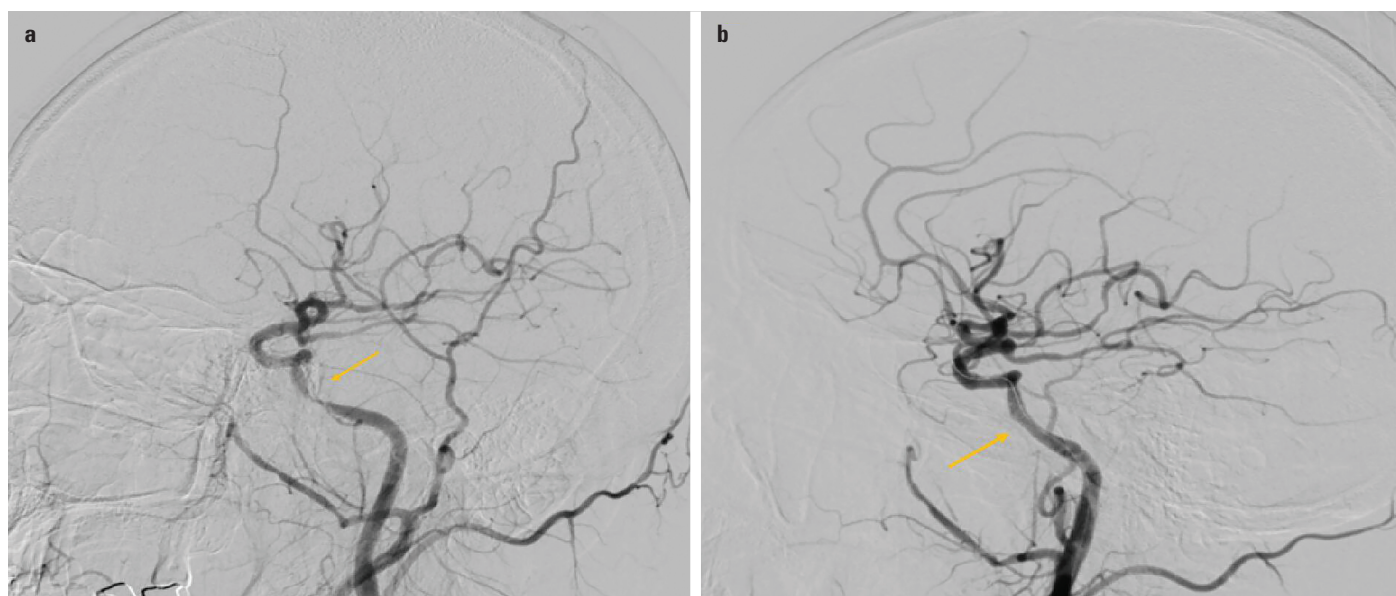
Three years later, carotid angiography for control purposes during coronary angiography was performed on the patient. DSA was also performed, which revealed an open carotid artery and stent (Fig. 2, Video 3).

## Discussion

Tinnitus is a symptom that causes insomnia and impaired quality of life in patients (3). Tinnitus is classified as pulsatile and



**Figure 2.** Three years later angiogram reveals the nearly – normal diameter of the vessel



**Figure 1.** (a) Digital subtraction angiogram shows atherosclerotic stenotic lesion of petrous segment of the left ICA (b) Postoperative angiogram shows correction of the diseased segment

non-pulsatile. Pulsatile tinnitus is mostly caused by vascular pathologies (4), such as diverticulum or aneurysm of the carotid artery and dural arteriovenous fistulas; it is also rarely caused by carotid artery stenosis. Carotid artery stenosis causes a turbulent flow near the inner ear because of which tinnitus occurs during each cardiac beat of the patient. Tinnitus is believed to be caused by the transmission of this turbulent flow sound through the bone to the cochlea. Tinnitus disappeared in our patient after opening the stenosis (5).

The most important step in the treatment of tinnitus is to eliminate the cause of tinnitus. Otorhinolaryngology examination should be performed first. Additionally, different tests should be performed to exclude vascular pathologies if no pathology can be found. First, these patients should be evaluated with non-invasive and easily applicable Doppler USG. However, Doppler USG is insufficient to observe the intracranial regions of the carotid artery. Therefore, CT and MR angiography play a crucial role in the evaluation of carotid artery stenosis (6). However, DSA, which is an invasive method, is still the gold standard method for evaluating carotid arteries.

The stenosis in our patient was located in the petrous ICA, which is not a surgically accessible region. We eliminated stenosis with endovascular treatment, a safer and less invasive method (7). A drug-eluting coronary stent was implanted into the patient, and the patient's tinnitus disappeared at that moment.

In the literature, several cases of tinnitus caused by vascular pathologies have been treated with intracranial stents (8, 9).

## Conclusion

In conclusion, it should be kept in mind that atherosclerotic carotid artery stenosis is one of the causes of pulsatile tinnitus. Additionally, endovascular therapy is an effective and safe method for eliminating pulsatile tinnitus in patients with severe carotid artery stenosis.

**Informed consent:** Written informed consent was obtained from the patient for publication of the case report and the accompanying videos and images.

**Video 1.** Digital subtraction angiogram shows atherosclerotic stenotic lesion of petrous segment of the left ICA

**Video 2.** Postoperative angiogram shows correction of the diseased segment

**Video 3.** Three years later angiogram reveals the nearly normal diameter of the vessel

## References

1. Sismanis A. Pulsatile tinnitus. A 15-year experience. *Am J Otol* 1998; 19: 472-7.
2. Hofmann E, Behr R, Neumann-Haefelin T, Schwager K. Pulsatile tinnitus: imaging and differential diagnosis. *Dtsch Arztebl Int* 2013; 110: 451-8.
3. Langguth B, Hund V, Busch V, Jürgens TP, Lainez JM, Landgrebe M, et al. Tinnitus and Headache. *Biomed Res Int* 2015; 2015: 797416.
4. Marsot-Dupuch K. Pulsatile and nonpulsatile tinnitus: a systemic approach. *Semin Ultrasound CT MR* 2001; 22: 250-70.
5. Liyanage SH, Singh A, Savundra P, Kalan A. Pulsatile tinnitus. *J Laryngol Otol* 2006; 120: 93-7.
6. Weissman JL, Hirsh BE. Imaging of tinnitus: a review. *Radiology* 2000; 216: 342-9.
7. Hartung O, Alimi YS, Juhan C. Tinnitus resulting from tandem lesions of the internal carotid artery: combined extracranial endarterectomy and intrapetrous primary stenting. *J Vasc Surg* 2004; 39: 679-81.
8. Iln YK, Jung WS, Kim BS. Disappeared pulsatile tinnitus related to petrous segment stenosis of the ICA after relief of the stenosis by stenting. *Interv Neuroradiol* 2013; 19: 97-101.
9. Cuellar H, Maiti T, Patra DP, Savardekar A, Sun H, Nanda A. Endovascular Treatment of Pulsatile Tinnitus by Sigmoid Sinus Aneurysm: Technical Note and Review of the Literature. *World Neurosurg* 2018; 113: 238-43.

**Address for Correspondence:** Dr. Ahmet Karaduman,  
Kartal Koşuyolu Eğitim ve Araştırma Hastanesi,  
Kardiyoloji Bölümü,  
Denizer Sok. No: 2  
Cevizli/Kartal 34865  
İstanbul- Türkiye  
Phone: +90 216 500 15 00

E-mail: ahmetkaraduman91@gmail.com

©Copyright 2020 by Turkish Society of Cardiology - Available online at [www.anatoljcardiol.com](http://www.anatoljcardiol.com)

DOI:10.14744/AnatolJCardiol.2020.76366

