

The Association of Intra-Tumoral and Stromal Vitamin D Receptor (VDR) Expressions with Molecular Subtypes and Clinicopathological Factors in Breast Carcinoma

Sukma Diani Putri^{1,2}, Siti Rahma Yunianda Nanza¹, Irianiwati Widodo³, Dewajani Purnomosari^{4*}

Abstract

Objective: This study aimed to investigate the association between intra-tumoral and stromal VDR expressions with molecular subtypes and clinicopathological factors. **Methods:** A total of 75 formalin-fixed paraffin embedded tissue samples were stained using immunohistochemical methods. The VDR expressions were measured by counting brown-stained nuclei in intra-tumoral and stromal areas. The association of VDR expression with molecular subtypes and clinicopathological factors was examined. Statistical analysis was performed by chi square tests. **Results:** High intra-tumoral VDR expression was found in carcinomas with luminal molecular subtypes ($p=0.039$) and low histological degrees ($p=0.035$). High VDR expression in the stroma was found in breast carcinomas with large tumor sizes. **Conclusions:** High intra-tumoral VDR expression is found in breast carcinomas with luminal subtypes and low histological grade (I/II). Both factors are known to have a good prognosis. These findings further strengthen the function of VDR as anti-tumorigenesis.

Keywords: Breast carcinoma- tumor microenvironment- vitamin D receptor- clinicopathological factors

Asian Pac J Cancer Prev, 23 (4), 1169-1175

Introduction

The complexity and development of breast carcinoma is inseparable from the role of surrounding cellular and non-cellular components called the tumor microenvironment (TME) (Chen et al., 2015). The constituent components of TME include endotheliocytes, adipocytes, immune or inflammatory cells, stroma, and the neoplasm itself (Place et al., 2011; Denton et al., 2018; Valkenburg et al., 2018). TME actively participates in tumorigenesis both as a modulator and an inhibitor of carcinoma (Yuan et al., 2016).

Vitamin D receptor (VDR) is a protein that is widely expressed by both tumor cells and stromal cells in TME (Thakkar et al., 2016). The bond between VDR and its ligand (calcitriol) induces the series of anti-tumorigenesis effects in breast cancer (Campbell and Trump., 2017). The VDR was found in several tissues, specifically intestine, bone, kidney, and parathyroid glands, and involved in the regulation of calcium and phosphate homeostasis (Pike et al., 2017). In breast carcinoma, VDR can be found in carcinoma cells, Cancer Associated Fibroblast (CAF), immune cells and adipocytes (Narvaez et al., 2014). The

increased VDR expression in breast carcinoma may have a better survival and is also associated with a better prognosis (Huss et al., 2019). VDR expression in breast carcinoma has been recently studied (Al-Azhri et al., 2017), but it was inseparable from stromal and intra-tumoral tissues. The results of previous studies indicated an association between VDR expression with molecular subtypes and clinicopathological factors in breast carcinoma.

This study aimed to investigate the association of intra-tumoral and stromal VDR expressions with molecular subtypes and clinicopathological factors in breast carcinoma.

Materials and Methods

Patients

This research was a cross-sectional study and was approved by the Medical and Health Research Ethics Committee of the Faculty of Medicine (KE/FK/0720EC/2019), Universitas Gadjah Mada. Formalin-fixed Paraffin Embedded (FFPE) tissue samples of 75 patients with invasive ductal breast carcinoma were obtained from the Dr. Sardjito General Hospital,

¹Postgraduate Program of Biomedical Sciences, Faculty of Medicine, Public Health and Nursing, Universitas Gadjah Mada, Indonesia. ²Indramayu State Polytechnic. ³Department of Anatomic Pathology, Faculty of Medicine, Public Health and Nursing Universitas Gadjah Mada, Indonesia. ⁴Department of Histology and Cell Biology, Faculty of Medicine, Public Health and Nursing, Universitas Gadjah Mada, Indonesia. *For Correspondence: d.purnomosari@ugm.ac.id

Yogyakarta, Indonesia between 2012 to 2015. All information regarding clinicopathological characteristics were collected from medical records, and molecular subtypes' information was retrieved from a previous study (Rahmawati et al., 2017). Sample selection used the consecutive sampling method. The tissue samples without tumor cells were excluded from the present study.

To check the serum level of vitamin D in the subjects, the Enzyme-linked immunoassay (ELISA) method was performed in the Integrated Laboratory, Faculty of Medicine, Public Health and Science, Universitas Gadjah Masa.

Immunohistochemistry

Samples were stained immunohistochemically using Rabbit/Polyclonal from Abcam (ab137371) using 1:200 dilution and incubated for one hour. Immunohistochemical kit was purchased from Biogear One Step Neopoly Detection Kit (BGNK-0025) with diaminobenzidine as chromogen. For negative control, the primary antibody was substituted with antibody diluent. Normal breast tissue within sections was used as the internal positive control.

The slides were examined blindly by two independent observers using Image Raster. For each sample, the

observers picked 10 field areas for intra-tumoral and stromal VDR expressions. VDR expressions were evaluated by counting total number of cells in each field, then the average score could be obtained. Cells were considered as positive if the nuclei were stained brown. Cut-off was determined by the normality test to decide higher and lower VDR expressions.

Statistical Analysis

Chi-squared tests were used to test the association between intra-tumoral and stromal VDR expressions with molecular subtypes and clinicopathological factors. The tests were conducted with 5% types I error.

Results

Immunohistochemistry Results

The molecular subtypes and clinicopathological features of patients according to intra-tumoral and stromal VDR expressions are shown in Table 1. From 75 samples, 34 samples (45.3%) had high VDR expression, and the rest (54.7%) had low intra-tumoral VDR expression. Whereas in the stromal there were 36 samples (48%) that showed high VDR expression, and 39 samples (52%) had low

Table 1. The Association of Intra-Tumoral VDR Expression with Molecular Subtypes and Clinicopathological Factors in Breast Carcinoma

Clinicopathological Factors	Total N=75 (100%)	Low VDR Expression N=36 (48%)	High VDR Expression N=39 (52%)	P (value)
Subtype				0.039
Luminal	41 (54.6%)	14 (34.1%)	27 (65.9%)	
Non Luminal	34 (45.4%)	20 (58.8%)	14 (41.2%)	
Age				1:00
≤50	43 (57.3%)	20 (46.5%)	23 (53.5%)	
>50	32 (42.7%)	14 (43.8%)	18 (56.3%)	
Tumor Size				0.428
≤5	52 (69.3%)	25 (48.1%)	27 (51.9%)	
>5	23 (30.7%)	9 (39.1%)	14 (60.9%)	
Histologic Grade				0.035
I/II	30 (40%)	9 (30%)	21 (70%)	
III	45 (60%)	25 (55.6%)	20 (44.4%)	
Nodal Involvement				0.247
Negative	39 (52%)	20 (51.3%)	19 (48.7%)	
Positive	36 (48%)	14 (38.9%)	22 (61.1%)	
ER				0.074
Negative	36 (48%)	20 (55.6%)	16 (44.4%)	
Positive	39 (52%)	14 (35.9%)	25 (64.1%)	
PR				0.067
Negative	47 (62.67%)	25 (53.2%)	22 (46.8%)	
Positive	28 (37.33%)	9 (32.1%)	19 (67.9%)	
HER-2				0.140
Negative	53 (71.67%)	27 (50.9%)	26 (49.1%)	
Positive	22 (29.33%)	7 (31.8%)	15 (68.2%)	
KI-67				0.160
Low	48 (64%)	19 (39.6%)	29 (60.4%)	
High	27 (36%)	15 (55.6%)	12 (44.4%)	

Table 2. Sub-Analysis of Intra-Tumoral VDR Expression Association with Molecular Subtypes in Breast Carcinoma

Molecular Subtype	Total N=75	Low VDR Expression N=36 (48%)	High VDR Expression N=39 (52%)	P (Value)
Luminal	41			0.499
Luminal A	30	11 (36.7%)	19 (66.3)	
Luminal B	11	3 (27.3%)	8 (72.7%)	
Non Luminal	34			0.013
HER-2	15	5 (33.3%)	10(66.7%)	
TNBC	19	15 (78.9%)	4 (21.1%)	

VDR expression.

In the current study, there was a significant association between intra-tumoral VDR expressions with the molecular subtypes (p = 0.039). Higher VDR expression was found in the luminal subtype compared to the non-luminal subtype. Intra-tumoral VDR expression was also associated with histological grade, where the higher expression was found in carcinomas with low histological grade (I / II) (Table 1). The results of the intra-tumoral VDR expression sub-analysis with molecular subtypes found an association between VDR expression and non-luminal subtypes (p = 0.013). Within the non-luminal

subtype, higher VDR expression was found in the HER-2 subtype than the TNBC subtype (Table 2).

VDR expression in the stroma was associated with tumor size (p = 0.014) (Table 3). Higher VDR expression was found in larger tumor sizes (> 5 cm) (Table 3). However, there was no significant associations between stromal VDR expression with clinicopathological factors, including age, histological grade, lymph node involvement, ER, PR, HER-2 and Ki-67.

Enzyme-linked immunoassay (ELISA) results

The results of the VDR expression data obtained were

Table 3. The Association of Stromal VDR Expression with Molecular Subtypes and Clinicopathological Factors in Breast Carcinoma

Clinicopathological Factors	Total N=75 (100%)	Low VDR Expression N=36 (48%)	High VDR Expression N=39 (52%)	P (value)
Molecular Subtype				0.074
Luminal	41 (54.6%)	16 (39%)	25 (61%)	
Non Luminal	34 (45.4%)	20 (58.8%)	14 (41.2%)	
Age				0.568
≤50	43 (57.3%)	20 (46.5%)	23 (53.5%)	
>50	32 (42.7%)	16 (50%)	16 (50%)	
Tumor Size				0.014
≤5	52 (69.3%)	30 (57.7%)	22 (42.3%)	
>5	23 (30.7%)	6 (26.1%)	17 (73.9%)	
Histological Grade				0.443
I/II	30 (40%)	13 (43.3%)	17 (56.7%)	
III	45 (60%)	23 (51.1%)	22 (48.9%)	
Nodal Involvement				0.449
Negative	39 (52%)	20 (51.3%)	19 (48.7%)	
Positive	36 (48%)	16 (44.4%)	20 (55.6%)	
ER				0.174
Negative	36 (48%)	20 (55.6%)	16 (44.4%)	
Positive	39 (52%)	16 (41%)	23 (59%)	
PR				1:00
Negative	47(62.67%)	23 (48.9%)	24 (51.1%)	
Positive	28(37.33%)	13 (46.4%)	15 (53.6%)	
HER-2				0.149
Negative	53(70.67%)	28 (52.8%)	25 (47.2%)	
Positive	22(29.33%)	8 (36.4%)	14 (63.6%)	
KI-67				0.109
Low	48 (64%)	20 (41.7%)	28 (58.3%)	
High	27 (36%)	16 (59.3%)	11 (40.7%)	

Table 4. The Association of Vitamin D level with VDR Expression and Clinicopathological Factors in Breast Carcinoma

Clinicopathological Factors	Total N=35 (100%)	Vitamin D Level		P (value)
		≤25 ng/ml	>25 ng/ml	
		N=25 (71,4%)	N=10(28,6%)	
Stromal VDR Expression				1
Low	12	9 (75%)	3 (25%)	
High	23	16 (69.6%)	7 (30.4%)	
Intra-tumoral VDR Expression				0.489
Low	14 (40%)	11 (78.6%)	3 (21.4%)	
High	21 (60%)	14 (66.7%)	7 (33.3%)	
Subtype				0.292
Luminal	25 (71.4%)	19 (76%)	6 (24%)	
Non Luminal	10 (28.6%)	6 (60%)	4 (40%)	
Age				0.027
≤50	17 (48.6%)	9 (52.9%)	8 (47.1%)	
>50	18 (51.4%)	16 (88.9%)	2 (11.1%)	
Tumor Size				0.292
≤5	25 (71.4%)	19 (76%)	6 (24%)	
>5	10 (28.6%)	6 (60%)	4 (40%)	
Histological Grade				0.105
I/II	14 (40%)	8 (57.1%)	6 (42.9%)	
III	21 (60%)	17 (81%)	4 (19%)	
Nodal Involvement				1
Negative	14 (40%)	10 (71.4%)	4 (28.6%)	
Positive	21 (60%)	15 (71.4%)	8 (28.6%)	
ER				0.158
Negative	11 (31.4%)	6 (54.5%)	5 (45.5%)	
Positive	24 (68.6%)	19 (79.2%)	5 (20.8%)	
PR				0.502
Negative	19 (54.3%)	13 (68.4%)	6 (31.6%)	
Positive	16 (45.7%)	12 (75%)	4 (25%)	
HER-2				1
Negative	28 (80%)	20 (71.4%)	8 (28.6%)	
Positive	7 (20%)	5 (71.4%)	2 (28.6%)	
KI-67				1
Negative	24 (68.6%)	17 (70.8%)	7 (29.2%)	
Positive	11 (31.4%)	8 (72.7%)	3 (27.3%)	

associated with 35 data of serum vitamin D levels from 75 patients. In this study the serum vitamin D levels <25 nmol/L were categorized as a low category and ≥25 nmol/L was categorized as high. In the results, we found that the majority of patients with breast cancer had low vitamin D levels (<25 ng/ml) (71.4%). VDR expressions both in the stroma and intra-tumoral showed no significant associations with serum vitamin D levels. There was no association found with molecular subtypes, as well as other clinicopathological factors. However, vitamin D levels was associated with the age of patients (p=0.027) (Table 4), where higher vitamin D levels (>25ng/ml) are found in younger patients (< 50).

Discussion

The previous study showed that neoplasm cells communicate well with surrounding stromal cells, inflammatory cells and immune cells directly or indirectly, but their surrounding does not always support them. TME can also inhibit the growth of carcinomas under certain conditions (Yuan et al., 2016). VDR is known by its impact to lead anti-tumorigenesis activities in TME and is associated with better prognosis. In the current study, VDR expression was found to be associated with luminal subtype, low grade and large tumor size.

Association of VDR expression with molecular subtypes in breast carcinoma

The current study results show there is an association

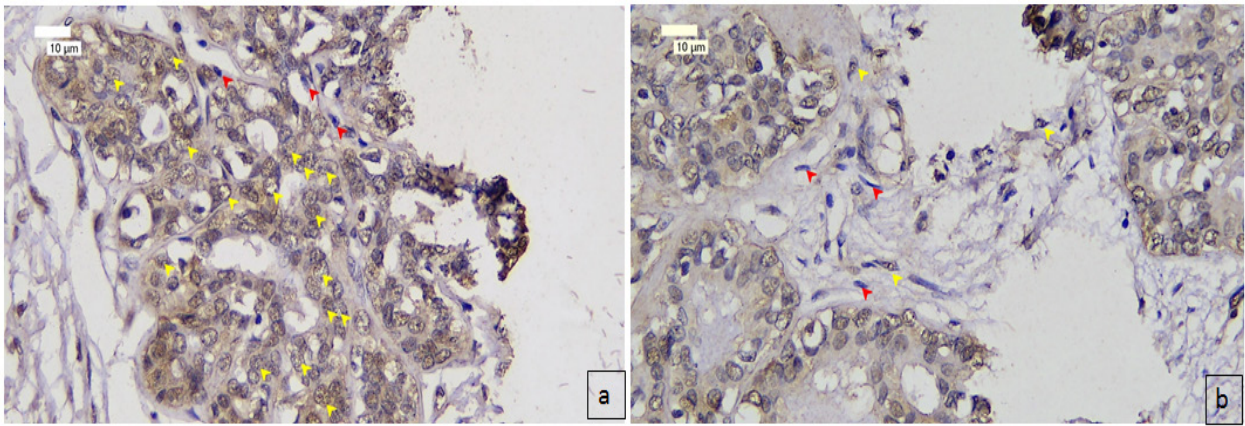


Figure 1. Immunohistochemistry Display of VDR Expression in Breast Cancer (400x). Cells with VDR expression can be found both at (a) intra-tumoral and (b) stroma. Positively identified cells with VDR expression are shown by yellow arrows, while the negatively identified cells are shown by red arrows.

between intra-tumoral VDR expression with molecular subtype of breast carcinoma. Higher intra-tumoral VDR expression was found in the luminal compared to non-luminal subtype. The results of the study are also the same as the results of previous studies (Al-Azhri et al., 2017; Huss et al., 2019). Stromal VDR expression was not associated with molecular subtypes ($p = 0.107$). High VDR expression is more common in the luminal subtype although it is not statistically significant. Luminal subtypes in breast carcinoma have less aggressive characteristics and are associated with a better prognosis compared to other subtypes (Al-Saeed et al., 2013). VDR-calcitriol complex has the potential to reducing the risk of progression a variety type of cancers (Fathi et al., 2018). In addition, VDR triggers anti-proliferative properties through inhibition of cell cycle through inhibition of Cdk expression and induces cell cycle inhibitors namely P21 and P27 (Shany et al., 2016). VDR also causes inhibition of epithelial to mesenchymal transition (EMT) and induces apoptosis (Thakkar et al., 2016; Ferrer-mayorga et al., 2017).

Both intra-tumoral and stromal VDR expressions in non-luminal subtypes were lower than in luminal subtypes. The absence of VDR can increase hypoxia inducible factor-1 (HIF-1), angiopoietin-1, vascular endothelial growth factor (VEGF) and platelet derived growth factor (PDGF) which can induce tumor vascularization (Santos-Martinez et al., 2014). Breast carcinoma with non-luminal subtypes has more aggressive characteristics and has a worse prognosis compared to the luminal subtype (Rahmawati et al., 2017., Widodo et al., 2017). VDR expression is associated with a better prognosis and is more prevalent in the luminal subtype (Al-Azhri et al., 2017; Huss et al., 2019).

Statistical analysis results using chi squared tests showed that the higher VDR expression was found in the HER-2 subtype compared with TNBC, both in intra-tumoral and in non-luminal subtypes. This result is different from previous studies which found that VDR expression is more common in the TNBC subtype compared to the HER-2 subtype although the result was not statistically significant (Al-Azhri et al., 2017).

Association of VDR expression with clinicopathological factors in breast carcinoma.

In this present study stromal VDR expression was associated with tumor size ($p=0.014$). Higher VDR expression was found in large tumors ($> 5\text{cm}$), so the results obtained were not same with previous studies (Al-Azhri et al., 2017; Huss et al., 2019). Tumor size and vascularization are ones of tumor growth parameter (Eckrich et al., 2020) In large tumors, more vascularization was found (Petrova et al., 2018) which was not observed in this study. Another possibility exists that this difference can be caused by the expression of fewer VDRs which will reduce the Wnt/ β catenin signaling pathway, causing tumor cells to undergo slower cell growth and increased apoptosis (Zheng et al., 2017; Trivedi et al., 2017).

Association of serum vitamin D levels with VDR expression, molecular subtypes and clinicopathological factors in breast carcinoma

The majority (71.4%) of patients with breast cancer in this study had low serum vitamin D levels ($<25\text{ ng/ml}$). These results are the same as previous studies that reported most breast cancer patients had low levels of vitamin D (Hemida et al., 2019; Shaukat et al., 2017).

Low levels of vitamin D in breast cancer patients were associated with advanced stage, positive-nodal involvement, and larger tumors (Thanasitthichai et al., 2015) that make it related to poor prognostic factors and mortality (Mohr et al., 2014). Furthermore, some research suggested that breast cancer patients with non-luminal subtype and higher grade tend to have lower levels of vitamin D than their opposing groups (Karthikayan et al., 2018). Meanwhile, the higher levels of vitamin D were associated with lower risk factor of breast cancer (Shaukat et al., 2017). However, in our study, both stromal and intra-tumoral VDR expressions did not show any statistically significant association with serum levels of vitamin D.

The current study showed that serum levels of vitamin D were associated with age of patients ($p=0.027$). We found that younger patients with breast cancer (< 50 years) had higher vitamin D levels ($>25\text{ng/ml}$). The results of this research same with previous report shown that

postmenopausal women may have a relatively low 25-OH vitamin D concentration (Aggarwal and Nityanand, 2013).

Multiple studies have stated the serum levels of vitamin D were negatively and significantly correlated with VDR expressions in breast cancer patients (Hemida et al., 2019). In this study, the results showed no significant correlation of vitamin D levels with VDR expressions.

There was an association between intra-tumoral VDR expression and molecular subtypes, where higher VDR expression was found in luminal subtypes. Intra-tumoral VDR expression was also associated with histological grade, with higher VDR expressions found at lower (I/II) histological grades. The absence of data regarding tumor stage and sample size in some samples became one of our limitations in this study. Further research is needed using a variety of variables such as vascular examination in tumors, tumor staging and survival outcome.

Acknowledgements

The authors would like to thank Dian Caturini, M.Sc; Agustin, laboratory staff in Anatomical Patology Department, Dr. Sardjito General hospital and Dewi Sulistyawati, laboratory staff in Histology and Cell Biology Department, UGM, Yogyakarta for their technical assistance.

Funding Statement

This study was supported by grants from the Ministry of Research, Technology and Higher Education of the Republic of Indonesia (KEMENRISTEKDIKTI) (No.0299/E3/2016).

References

- Al-Saeed EF, Al-Ghabban ARJ, Tunio MA (2013). The prognostic significance of the luminal A, luminal B, basal and Her 2 neu subtypes of breast cancer in Saudi women. *Open Breast Cancer J*, **5**, 16-22.
- Aggarwal S, Nityanand (2013). Calcium and vitamin D in postmenopausal women. *Indian J Endocrinol Metab*, **17**, 618–21.
- Al-Azhri J, Zhang Y, Bshara W, et al (2017). Tumor expression of vitamin D receptor and breast cancer histopathological characteristics and prognosis. *Clin Cancer Res*, **23**, 97–104.
- Campbell MJ, Trump DL (2017). Vitamin D receptor signaling and cancer. *Endocrinol Metab Clin NA*, **46**, 1009–38. A
- Chen F, Zhuang X, Lin L, et al (2015). New horizons in tumor microenvironment biology: challenges and opportunities. *BMC Med*, **13**, 1–13.
- Denton AE, Roberts EW, Fearon DT (2018). Stromal cells in the tumor microenvironment. Springer, pp 99–114.
- Eckrich J, Kugler P, Buhr CR, et al (2020). Monitoring of tumor growth and vascularization with repetitive ultrasonography in the chicken chorioallantoic-membrane-assay. *Sci Rep*, **10**, 1-14.
- Fathi N, Ahmadian E, Shaho S, et al (2019). Role of vitamin D and vitamin D receptor (VDR) in oral cancer. *Biomed Pharm*, **109**, 391-401.
- Ferrer-mayorga G, Gómez-lópez G, Barbáchano A, et al (2017). Vitamin D receptor expression and associated gene signature in tumour stromal fibroblasts predict clinical outcome in colorectal cancer. *Endocrinol Metab Clin North Am*, **46**, 1449–62.
- Hemida MA, Abdelmoneim NA., Hewala, TI, et al (2019). Vitamin D receptor in breast cancer tissues and its relation to Estrogen Receptor Alpha (ER-a) gene expression and serum 25-hydroxyvitamin D levels in Egyptian breast cancer patients: A Case-control Study. *Clin Breast Cancer*, **19**, 407–14.
- Huss L, Butt ST, Borgquist S, et al (2019). Vitamin D receptor expression in invasive breast tumors and breast cancer survival. *Breast Cancer Res*, **21**, 1–13.
- Karthikayan A, Sureshkumar S, Kadambari D, et al (2018). Low serum 25-hydroxy vitamin D levels are associated with aggressive breast cancer variants and poor prognostic factors in patients with breast carcinoma. *Arch Endocrinol Metabolism*, **62**, 452–9.
- Kim Y, Franke AA, Shvetsov YB, et al (2014). Plasma 25-hydroxyvitamin D3 is associated with decreased risk of postmenopausal breast cancer in whites: a nested case-control study in the multiethnic cohort study. *BMC Cancer*, **14**, 1–7.
- Mohr SB, Gorham ED, Kim J, et al (2014). Meta-analysis of Vitamin D sufficiency for improving survival of patients with breast cancer. *Anticancer Res*, **34**, 1163-6.
- Narvaez CJ, Matthews D, Laporta E, et al (2014). The impact of vitamin D in breast cancer: genomics, pathways, metabolism. *Front Physiol*, **5**, 1-10.
- Petrova V, Annicchiarico-petruzzelli M, Melino G, et al (2018). The hypoxic tumour microenvironment. *Oncogenesis*, **7**, 1-13.
- Pike JW, Meyer MB, Lee SM, et al (2017). Genomic determinants of vitamin D-regulated gene expression. *J Clin Invest*, **127**, 1146-54.
- Place AE, Huh SJ, Polyak K, (2011). The microenvironment in breast cancer progression: biology and implications for treatment. *Breast Cancer Res*, **13**, 1-15.
- Rahmawati Y, Setyawati Y, Widodo I, et al (2017). Association between molecular subtypes of breast cancer with histological grade and lymph node metastases in Indonesian woman. *Asian Pac J Cancer Prev*, **19**, 161–6.
- Santos-martinez N, Díaz L, Ordaz-rosado D, et al (2014). Calcitriol restores antiestrogen responsiveness in estrogen receptor negative breast cancer cells: a potential new therapeutic approach. *BMC Cancer*, **14**, 1-10.
- Shany S, Sigal-batikoff INA, Lamprecht S, (2016). Vitamin D and myofibroblasts in fibrosis and cancer: at cross-purposes with TGF-β/SMAD signaling. *Anticancer Res*, **6234**, 6225–34.
- Shaukat N, Jaleel F, Moosa F A, et al (2017). Association between Vitamin D deficiency and breast cancer. *Pak J Med Sci*, **33**, 645–9.
- Thakkar A, Buchwald BWMPP, Ince TA (2016). Vitamin D and androgen receptor-targeted therapy for triple-negative breast cancer. *Breast Cancer Res Treat*, **157**, 77–90.
- Thanasitthichai S, Chaiwerawattana A, Prasitthipayong A (2015). Association of vitamin D level with clinicopathological features in breast cancer. *Asian Pac J Cancer Prev*, **16**, 4881–3.
- Trivedi T, Zheng Y, Fournier PGJ, et al (2017). The vitamin D receptor is involved in the regulation of human breast cancer cell growth via a ligand-independent function in cytoplasm. *Oncotarget*, **8**, 26687–701.
- Valkenburg KC, Groot AE De, Pienta KC, et al (2018). Targeting the tumour stroma to improve cancer therapy. *Nat Rev Clin Oncol*, **15**, 366–81.
- Widodo I, Dwianingsih EK, Anwar SL, et al (2017). Prognostic value of clinicopathological factors for Indonesian breast carcinomas of different molecular subtypes. *Asian Pac J Cancer Prev*, **18**, 1251–6.
- Yuan Y, Jiang Y, Sun C, et al (2016). Role of the tumor microenvironment in tumor progression and the clinical

applications. *Oncol Rep*, **35**, 2499–2515.
Zheng Y, Trivedi T, Lin RCY, et al (2017). Loss of the vitamin D receptor in human breast and prostate cancers strongly induces cell apoptosis through downregulation of Wnt/ β -catenin signaling. *Bone Res*, **5**, 1–12.



This work is licensed under a Creative Commons Attribution-Non Commercial 4.0 International License.