

Abdominal cocoon with early postoperative small bowel obstruction

A case report and review of literature in China

Jie Xia, MD, WeiJia Xie, MD, Li Chen, PhD*, Daren Liu, PhD*

Abstract

Rationale: Abdominal cocoon is a condition in which intestinal obstruction results from the encasement of part or whole of the small bowel by a thick fibrous membrane, giving the appearance of a cocoon. The preoperative diagnosis is difficult to be made and the treatment is still controversial.

Patient concerns: Here we describe the case of a 62-year-old male presented with a 24-h history of continual colicky abdominal pain, which was accompanied with nausea and vomiting.

Diagnosis: Accurate diagnosis of abdominal cocoon was made intraoperatively.

Interventions: Membrane excision and adhesiolysis were performed and the patient experienced early postoperative small bowel obstruction. Nasointestinal obstruction tube was then installed and bowel function was gradually recovered by the 20th postoperative day.

Outcomes: The patient recovered well and was discharged from the hospital on the 30th postoperative day

Lessons: Abdominal cocoon can occur at any age. The possibility of abdominal cocoon should also be considered in infertile patients. Imaging studies may be helpful to make the correct diagnosis, and surgery should be performed for patients with recurrent acute or chronic intestinal obstruction.

Abbreviations: AC = abdominal cocoon, BMI = body mass index, CT = computed tomography, EPSBO = early postoperative small bowel obstruction, MRI = magnetic resonance imaging, NIT = nasointestinal obstruction tube, PE = peritoneal encapsulation, SEP = sclerosing encapsulating peritonitis, SSEP = secondary sclerosing encapsulating peritonitis.

Keywords: abdominal cocoon, bowel obstruction, sclerosing encapsulating peritonitis, treatment

1. Introduction

Abdominal cocoon (AC), also known as “sclerosing encapsulating peritonitis” (SEP), is a relatively rare celiac disease in surgical emergency.^[1] When it was first systematically described and named by Foo et al in 1978,^[2] “the AC” has been accepted and used ever since. Although there have been sporadic case reports, there have been few overall evaluations in which a large number of patients was included. On the gross specimen, the appearance was very smooth and the thickness of the fibrous membrane is approximately 1 to 6 mm.^[3] On microscopic examination, the membranes are

composed of thick collagenous fibrous tissue infiltrated with few inflammatory cells. The causes of AC still remain unknown. In addition, preoperative diagnosis of AC is difficult because of its nonspecific clinical features. Diagnosis is usually made by exploratory laparotomy. Nonetheless, recent technological advances in imaging examination, particularly computed tomography (CT), have made preoperative diagnosis of AC possible. Till now, contrast-enhanced CT is the most helpful radiological tool for confirming the diagnosis. Pursuing a correct preoperative diagnosis is the most critical thing, because it may be helpful for clinicians to make a proper treatment plan of these patients. The ideal treatment is surgery, with freeing of the adhesions and excision of the constricting fibrous membrane from the small intestine. However, extensive adhesiolysis may contribute to the occurrence of early postoperative small bowel obstruction (EPSBO).^[4] Nasointestinal obstruction tube (NIT) placement is recommended during the surgery. It is believed that NIT is an effective way in treating EPSBO^[5] and reducing the incidence of postoperative adhesive intestinal obstruction in AC patients. In this study, 1 case of AC treated by the authors was reported, and 81 AC cases reported in Chinese literature were reviewed.

2. Case report

A 62-year-old male was admitted into our hospital with a 24-h history of continual colicky abdominal pain, which was accompanied with nausea and vomiting. On physical examination, abdominal distension, mild tenderness, and a firm palpable lump in central abdomen were found. There was also hyperactive bowel sound on auscultation. He admitted a history of

Editor: N/A.

This study was approved by the Ethics Committee of Second Affiliated Hospital of Zhejiang University. Written informed consent was obtained from the patient and patients' guardians.

Jie Xia and WeiJia Xie have contributed equally to this work.

The authors have no conflicts of interest to disclose.

Second Affiliated Hospital of Zhejiang University school of medicine, Hangzhou, China.

* Correspondence: Li Chen and Daren Liu, Zhejiang University, Hangzhou, Zhejiang 310009, China (e-mails: chenli@mail.hz.zj.cn, darenliu@zju.edu.cn).

Copyright © 2018 the Author(s). Published by Wolters Kluwer Health, Inc. This is an open access article distributed under the terms of the Creative Commons Attribution-Non Commercial License 4.0 (CCBY-NC), where it is permissible to download, share, remix, transform, and buildup the work provided it is properly cited. The work cannot be used commercially without permission from the journal.

Medicine (2018) 97:25(e11102)

Received: 8 March 2018 / Accepted: 23 May 2018

<http://dx.doi.org/10.1097/MD.00000000000011102>

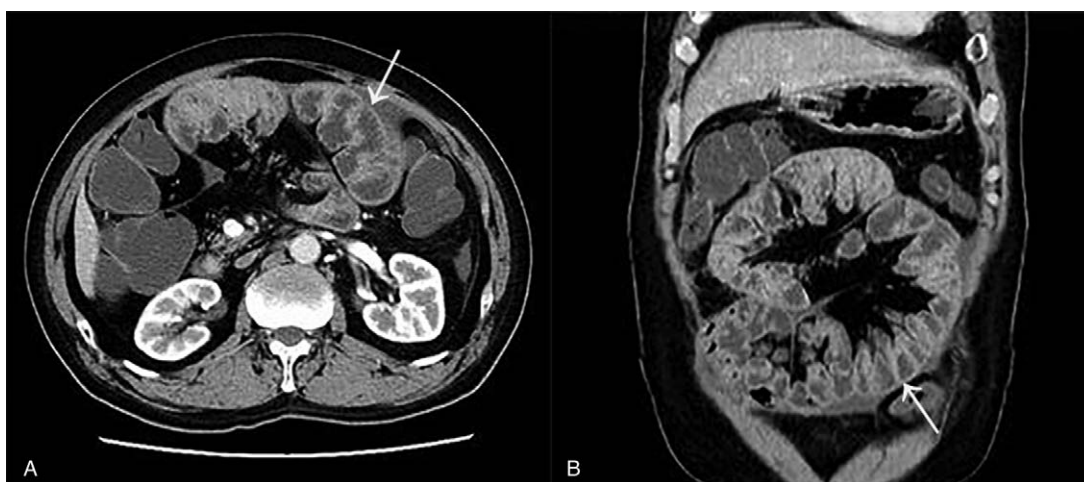


Figure 1. Computed tomography images showed the small intestine was restricted to the central part of the abdomen in a typical cocoon pattern (arrow), producing a “cauliflower” appearance. (A) Axial slice; (B) multiplanar coronal reconstruction.

constipation, anorexia but no weight loss in the recent 3 months. He had no medical history related to his current condition, no history of chronic diseases, chronic use of medication, infectious diseases like tuberculosis, or abdominal surgery. He had experienced several similar episodes over the previous 3 months, which required hospitalization and were relieved by conservative therapy. During examination, he was in distress, but laboratory findings were normal. Multiple air-fluid levels were seen in plain abdominal X-rays and small intestinal CT revealed congregated small intestine loops were confined to a single area and encased in a thick membrane suggestive of AC or internal hernia (Fig. 1). The most likely primary diagnosis was AC, and a decision was then taken to carry out an exploratory laparotomy this time. During laparotomy, a thick white membrane (Fig. 2) was found encasing the entire small intestine in the abdomen. The greater omentum was not observed. The large intestine, stomach, liver, and spleen were not affected. The whole of cocoon membrane was excised with care to avoid injury to small intestine. Appendectomy was also done before the closure of the abdomen. The pathology of the resected membrane showed fibrocollage-

nous tissue associated with mucoid and vitreous degeneration and an infiltration of few lymphocytes. Unfortunately, the patient experienced crampy abdominal pain, distention, and vomiting on day 6 after the surgery. A provisional clinical diagnosis of EPSBO was made for this patient. On the 10th day, an NIT of 300-cm long was installed through the nose with the tip pushed to the upper jejunum assisted by gastroscopy. The patient underwent intra-small-intestinal suction therapy for reducing and relieving the obstruction. Meanwhile, the patient was treated with appropriate enteral nutritional support, which was administered via NIT. Bowel function was gradually recovered on the 20th postoperative day and the patient started oral intake on the 25th day. He was discharged from the hospital on the 30th postoperative day. A 6-month follow-up was carried out and no recurrence was detected.

3. Literature review

The Chinese Biology and Medicine Database (<http://sinomed.unicam.ac.cn/zh>), the Chinese Periodical Database of Science

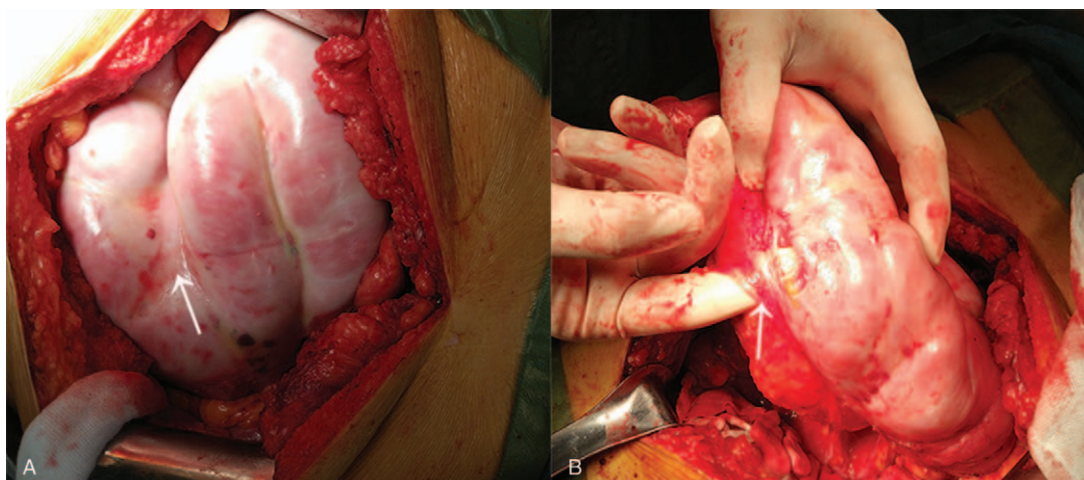


Figure 2. Intraoperative photograph showed a cocoon-like fashion. (A) A clustering of small bowel loops encased by membrane sac (arrow). (B) Displaying part of the adhesions (arrow).

Table 1
Characteristics of abdominal cocoon reported in China during the past 10 years.

Clinical data	Frequency, % (no. of positive cases/total cases)
Gender	
Male	63.4 (52/82)
Female	36.6 (30/82)
Age	
>17 years old	93.9 (77/82)
≤17 years old	6.1 (5/82)
Abdominal mass	
Yes	51.2 (42/82)
No	48.8 (40/82)
Chief complaints	
Intestinal obstruction	54.9 (45/82)
Sterility	18.3 (15/82)
Appendicitis	17.1 (14/82)
Others	9.7 (8/82)
Findings during surgery	
Lack greater omentum	36.6 (30/82)
Greater omentum dysplasia	22.0 (18/82)
Intestinal perforation or necrosis	11.0 (9/82)
Appendectomy	
Yes	37.8 (31/82)
No	62.2 (51/82)
Complications	
Postoperative intestinal obstruction	23.2 (19/82)
Intestinal fistula	7.3 (6/82)

and Technology (<http://lib.cqvip.com>), and the China Hospital Knowledge Database (<http://www.chkd.cnke.net>) were reviewed for cases of AC between January 2007 and December 2017. Patients with the history of abdominal trauma or surgery, or long time of oral medication intake, peritoneal dialysis, or intraperitoneal chemotherapy were not included in the study. Duplicate reports were reviewed and excluded from further analysis to avoid overrepresentation. A total of 82 patients with AC, including 1 case from the present study and 81 cases that were reported in Chinese literature from January 2007 to December 2017, were reviewed and analyzed (Table 1).

The average age of the 82 cases at presentation was 35.6 years (range, 6–78 years) and the male-to-female ratio was 1.73:1. There were 5 (6.1%) pediatric and 77 (93.9%) adult cases. All patients were diagnosed as AC, of which 42 cases (51.2%) were combined with abdominal mass. Of the 82 cases, 45 (54.9%) were manifested as symptoms of intestinal obstruction, 15 (18.3%) with sterility, and 14 (17.1%) with appendicitis. All of these 82 cases were examined with abdominal X-ray and computer tomography scanning. However, only 6 cases were considered as AC via preoperative examinations. Diagnosis of AC was established based on the intraoperative findings in most cases. In all the cases, we found that partial or the entire small bowel was encapsulated in a gray-white, fibrous, cocoon-like membrane. Greater omentum was absent in 30 cases (36.6%) and greater omentum dysplasia has been found in 18 cases (22%), and intestinal perforation or necrosis were present in 11 cases (11%).

In our study, all cases with AC underwent encapsulated membrane excision and adhesiolysis, and 31 cases (37.8%) also underwent appendectomy at the same time. All membrane tissues were sent for histological examination, which demonstrated proliferation of fibroconnective tissue with nonspecific chronic inflammatory reaction. Nineteen cases (23.2%) were presented

with postoperative bowel obstruction and were cured by conservative treatment. After the surgery, out of the 6 cases complicated with intestinal fistula, 3 of them died.

4. Discussion

AC is a rare cause of intestinal obstruction. However, there are still other inaccurate definitions to describe this rare disease, like peritoneal encapsulation (PE), SEP, idiopathic SEP, secondary SEP (SSEP) in previously published articles. Akbulut^[6] has helped us distinguish these definitions and made a detailed classification of all these concepts. SEP was divided into primary and secondary forms according to the underlying etiological causes. Primary SEP has also been termed as idiopathic SEP or AC or AC syndrome. The accurate definition of primary SEP is that no factors can explain this disease after various examinations (history taking, blood tests, radiological imaging, and histopathological tests). Patients with SSEP always have definitive history of long-term peritoneal dialysis, abdominal tuberculosis, history of abdominal trauma or surgery, or long-term beta-blocker treatment.^[7] In addition, PE needs to be better understood. PE may be a rare developmental abnormality, first described by Cleland in 1868.^[8] PE was surrounded by normal peritoneum, which was believed to be derived from the yolk sac peritoneum during early development.^[9] The accessory membrane present in front of the small bowel was considered to be easily removed. PE was typically asymptomatic and unrelated to any inflammatory process, while SEP is usually related with a local or systemic inflammatory process.

It has been reported that AC can be categorized into 3 types^[10] according to the extent of the encasing membrane: type 1—the intestine partially encapsulated by membrane; type 2—the whole intestine was encapsulated by the membrane; and type 3—the whole intestine and other intraperitoneal organs such as the stomach, liver, appendix, cecum, colon, and ovaries were encapsulated by the membrane.

Although a number of hypotheses have been proposed, the etiology and pathogenesis have not been clearly elucidated. Some authors have argued that AC has mainly been described in young adolescent girls from tropical and subtropical countries.^[11] These hypotheses involve retrograde menstruation with a superimposed viral infection, retrograde peritonitis via the fallopian tubes, and cell-mediated immunological tissue damage secondary to gynecological infection.^[12] Therefore, population district and gender may seem to be an important etiological agent of AC. In recent years, some new cases reported seem to be in contradiction with the previous theories. Adults, premenopausal women, children, as well as patients from temperate regions have also been found to be equally affected.^[13] Congenital dysplasia regarding the etiology of AC has been proposed.^[14] During the development of the embryo, abnormal membrane had formed and derived from some unknown extraembryonic tissues. Forty-eight patients having AC in our data presented with concomitant developmental abnormalities: absence of greater omentum or greater omentum dysplasia. Congenital dysplasia may signify an alternative etiology. To elucidate the precise etiology of AC, further studies are necessary.

AC may have existed in the patients for a long time before it is diagnosed by incident surgery. In 1 large case series, only 3% of admitted patients were diagnosed before the surgery.^[15] Commonly, it is usually presented as recurrent episodes of complete or partial small bowel obstruction in some individuals combined with relevant imaging findings.^[16] Other nonspecific

symptoms consist of nausea, vomiting, abdominal pain, anorexia, weight loss, malnutrition, and constipation. In addition, abdominal ascites and distention are detectable in some patients with severe disease.^[13] AC is usually misdiagnosed as adhesive intestinal obstruction, abdominal tumor, or chronic appendicitis. As a result, the preoperative diagnosis of AC is usually difficult. Patients were diagnosed as AC based on surgical findings in a majority of the reports.

The examination of barium-contrast X-ray, ultrasonography, CT, and occasionally contrast-enhanced magnetic resonance imaging (MRI) might be helpful for the definitive preoperative diagnosis of AC to some extent. Plain X-ray findings are not specific to the diagnosis of AC, which shows diffuse air-fluid levels and dilated small intestinal loops in the abdomen. Rather, these signs are common in many patients with other abdominal conditions. Barium-contrast X-ray studies are better, manifesting the accumulated, and conglomerated intestinal loops at the center of the abdomen. However, barium studies may not be possible in patients with prominent signs of intestinal obstruction. Multi-detector computer tomography technology has greater accuracy because it allows for multiplanar (axial, sagittal, and coronal) reconstruction.^[17] This characteristic appearance was that the capreolary intestine was centralized in a capsule, termed as the “cauliflower sign” or “accordion pattern.”^[18] A prolonged transit time may also aid in the diagnosis. To the best of our knowledge, there was a case described the use of contrast-enhanced MRI in a patient with AC. The authors concluded that there was almost similar outcome between using contrast-enhanced MRI and CT imaging, but the encasing membrane was more obvious in the MRI examination.^[19] Currently, it is accepted that abdominal CT scans can provide more accurate information in the diagnosis of AC and sometimes tell us the degree of obstruction with AC. Histologic examination of the membrane tissues showed proliferation of fibrocytes and enrichment of collagen fiber, with nonspecific inflammatory reaction and vascular proliferation in some cases.

We can summarize the diagnostic methods of AC as follows^[3,20]: The disease is more common in young and middle-age patients, children should not be ignored, and patients' gender is not a main reference. Patients with history of abdominal trauma or surgery, or long-time oral medication intake, peritoneal dialysis, or intraperitoneal chemotherapy should be excluded. Positive abdominal imaging-abdominal plain X-ray is suggestive for intestinal obstruction, and CT shows the “cauliflower sign” and the small bowel can be found encased in a thickened membrane. Surgical exploration found that part or all of the small intestine is surrounded by a fibrous membrane and the membrane is continuous and complete. The pathological examination of the membrane reveals the simple fibrous tissue, which can lead to final diagnosis.

Because of the recurrent nature of intestinal obstruction with AC, some patients are malnourished. If possible, such patients in our department generally are given further adjustment for body mass index (BMI). Preoperative nutritional supports including enteral or parenteral nutrition are essential to attain a BMI over 18.5 kg/m².

Surgery is considered to be the first choice for patients with recurrent acute or chronic intestinal obstruction.^[21] During surgery, we can find entire or partial intestine encapsulated in a thick, white, fibrous “cocoon-like” membrane. Membrane excision and adhesiolysis should be applied to all encased intestinal segments. Furthermore, more attention should be paid to the following tips: Some authors believed the risk of recurrence is quite

low if the membrane on the intestinal surface can be totally excised. so they try to remove the whole cocoon membrane, then release the small intestine, attention should be paid to operate lightly and softly to avoid damage to serosal surface and causing iatrogenic bowel perforation.^[22] Exploring whether there is a segmental necrotic bowel. Bowel resection is done only when the bowel is nonviable, because it may increase the complications of postoperative anastomotic leakage and in some patients, short bowel syndrome can be resulted.^[23] For reducing the incidence of postoperative adhesive intestinal obstruction in AC patients, it is recommended that NIT should be installed in preoperative or operative period.^[24] Additional appendectomy is worth recommending because the surgery would be difficult if appendicitis were to occur after the surgery.^[25] Prophylactic application of an antiadhesive substance such as sodium hyaluronate between the intestinal loops before closing the abdomen may be useful in preventing the development of EPSBO.

The most common postoperative complication is EPSBO. It is a temporary form of intestinal obstruction, which may be caused by interbowel conglutination, injury of the intestinal serosa, intestinal edema, and prolonged operation times. As we know, the intestinal wall serosa was slick after the membrane was removed. It may lead to form intestinal folding, angulation, volvulus, and crispation after the surgery which we believe to be related to the occurrence of EPSBO. NIT is the key procedure to deal with EPSBO in our center.^[26] The nasointestinal decompression intubation serves some functions for patients with AC: The tube's tip can expand the narrow, distorted, or angled obstruction from being formed with the help of flexible water balloon after the surgery.^[27] Giving patients continuous intras-small-intestinal suction therapy superior to that of nasogastric tube before the return of intestinal function. When the patients experienced EPSBO, we can pinpoint the location of the obstruction and make the diagnosis in the X-ray monitoring through injecting contrast agent from NIT.^[28] When we find the right location of the obstruction, we can adjust the NIT directly into the obstruction point which can give the patient the decompression treatment to reduce or alleviate the symptoms of intestinal obstruction.^[29] It can be used as a support tube to administer enteral nutrition for the patient.

In addition, postoperative complications including intra-abdominal infection, intestinal fistula, short bowel syndrome, and bowel perforation are quite rare in patients with AC.^[23] Early postsurgical activity was encouraged. Acupuncture, physical therapy can be used to promote enterokinesia. Hormone therapy, such as dexamethasone and administration of somatostatin, was also recommended. In a word, the prognosis of AC after surgery seems excellent and no recurrence has been described.^[30]

In conclusion, the aim of this study is to raise awareness of this rare type of intestinal obstruction. The combination of careful history, physical examination and radiological signs, along with being sufficient awareness of clinicians may be helpful in making a definitive diagnosis. Surgery is currently considered to be important in the management of this disease. Adhesiolysis with excision of membrane is necessary, but there is a high rate of occurrence of EPSBO. NIT installed preoperatively or operatively is recommended. It can be considered as a safe and effective treatment for EPSBO. Long-term prognosis is good and recurrence is rare.

Acknowledgment

The authors are very grateful to the patient for his consent.

Author contributions

Conceptualization: Daren Liu, Jie Xia, Li Chen, Weijia Xie.

Data curation: Daren Liu, Jie Xia, Li Chen, Weijia Xie.

Formal analysis: Daren Liu, Jie Xia, Li Chen.

Funding acquisition: Daren Liu.

Investigation: Jie Xia, Weijia Xie.

References

- [1] Mohanty D, Jain BK, Agrawal J, et al. Abdominal cocoon: clinical presentation, diagnosis, and management. *J Gastrointest Surg* 2009;13:1160–2.
- [2] Foo KT, Ng KC, Rauff A, et al. Unusual small intestinal obstruction in adolescent girls: the abdominal cocoon. *Br J Surg* 1978;65:427–30.
- [3] Wei B, Wei HB, Guo WP, et al. Diagnosis and treatment of abdominal cocoon: a report of 24 cases. *Am J Surg* 2009;198:348–53.
- [4] Zheng YB, Zhang PF, Ma S, et al. Abdominal cocoon complicated with early postoperative small bowel obstruction. *Ann Saudi Med* 2008;28:294–6.
- [5] Li D, Li R, Wu P, et al. Clinical and diagnostic significance of enteroclysis through nasointestinal decompression intubation. *Cell Biochem Biophys* 2014;70:349–53.
- [6] Akbulut S. Accurate definition and management of idiopathic sclerosing encapsulating peritonitis. *World J Gastroenterol* 2015;21:675–87.
- [7] Seng LK, Mahadaven M, Musa A. Abdominal cocoon: a report of two cases. *Br J Surg* 1993;80:1149.
- [8] Cleland On an abnormal arrangement of the peritoneum, with remarks on the development of the mesocolon. *J Anat Physiol* 1868;2:201–6.
- [9] Sieck JO, Cowgill R, Larkworthy W. Peritoneal encapsulation and abdominal cocoon. *Gastroenterology* 1983;84:1597–601.
- [10] Sharma V, Mandavdhare HS, Rana SS, et al. Role of conservative management in tubercular abdominal cocoon: a case series. *Infection* 2017;45:601–6.
- [11] Ibrahim NA, Oludara MA. Abdominal cocoon in an adolescent male patient. *Trop Doct* 2009;39:254–6.
- [12] Jagdale A, Prasla S, Mittal S. Abdominal cocoon: a rare etiology of intestinal obstruction. *J Family Med Prim Care* 2017;6:674–6.
- [13] Saied GA, Hassan AZ, Ossip M, et al. Idiopathic sclerosing encapsulating peritonitis. Case report and review of literature. *Eur Surg* 2010;42:103–6.
- [14] Sahoo SP, Gangopadhyay AN, Gupta DK, et al. Abdominal cocoon in children: a report of four cases. *J Pediatr Surg* 1996;31:987–8.
- [15] Tu JF, Huang XF, Zhu GB, et al. Comprehensive analysis of 203 cases with abdominal cocoon. *Chinese J Gastrointest Surg* 2006;9:133–5.
- [16] Shah MYS, Gedam BS, Sonarkar R, et al. Abdominal cocoon: an unusual cause of subacute intestinal obstruction. *Indian J Surg* 2013;75:S391–3.
- [17] Gupta S, Shirahatti RG, Anand J. CT findings of an abdominal cocoon. *AJR Am J Roentgenol* 2004;183:1658–60.
- [18] Ibrarullah M, Mishra T. Abdominal cocoon: “cauliflower sign” on CT scan. *Indian J Surg* 2016;78:243–4.
- [19] Jovani M, Baticci F, Bonifacio C, et al. Abdominal cocoon or idiopathic encapsulating peritoneal sclerosis: magnetic resonance imaging. *Dig Liver Dis* 2014;46:192–3.
- [20] Li N, Zhu W, Li Y, et al. Surgical treatment and perioperative management of idiopathic abdominal cocoon: single-center review of 65 cases. *World J Surg* 2014;38:1860–7.
- [21] Kumar A, Ramakrishnan TS, Sahu S, et al. Idiopathic sclerosing encapsulating peritonitis—is a preoperative diagnosis possible? Report of three cases. *Surg Today* 2009;39:610–4.
- [22] Naniwadekar RG, Kulkarni SR, Bane P, et al. Abdominal cocoon: an unusual presentation of small bowel obstruction. *J Clin Diagn Res* 2014;8:173–4.
- [23] Xu P, Chen LH, Li YM. Idiopathic sclerosing encapsulating peritonitis (or abdominal cocoon): a report of 5 cases. *World J Gastroenterol* 2007;13:3649–51.
- [24] Luz MMPD, Barral SM, Barral CM, et al. Idiopathic encapsulating peritonitis: report of two cases. *Surg Today* 2011;41:1644–8.
- [25] Li S, Wang JJ, Hu WX, et al. Diagnosis and treatment of 26 cases of abdominal cocoon. *World J Surg* 2017;41:1287–94.
- [26] Li R-H, Li D-C, Lv X-P, et al. Radiographically controlled nasointestinal intubation to treat recurrent postoperative adhesive ileus. *Cell Biochem Biophys* 2015;72:509–14.
- [27] Cui X, Jing H, Zhao J, et al. Clinical analysis of long nasointestinal tube (LT) with gastrografin in the treatment of postoperative adhesive small bowel obstruction. *J Dalian Med Univ* 2017.
- [28] Cui H, Jiang X, Li H. Adhesive small-bowel obstruction treatment using internal intestinal splinting with a nasointestinal ileus tube. *Minerva Chir* 2015;70:327–30.
- [29] Li RH, Li DC, Tian QZ, et al. Diagnosis of small bowel obstruction using targeted enterography during nasointestinal decompression. *Cell Biochem Biophys* 2015;72:833–7.
- [30] Devay AO, Gomceli I, Korukluoglu B, et al. An unusual and difficult diagnosis of intestinal obstruction: the abdominal cocoon. Case report and review of the literature. *World J Emerg Surg* 2006;1:8–18.