



Received: 2016.05.17

Accepted: 2016.05.25

Published: 2017.02.10

Authors' Contribution:

- A** Study Design
- B** Data Collection
- C** Statistical Analysis
- D** Data Interpretation
- E** Manuscript Preparation
- F** Literature Search
- G** Funds Collection

Magnetic Resonance Imaging in Differentiatial Diagnosis of Pyogenic Spondylodiscitis and Tuberculous Spondylodiscitis

Małgorzata Frel^{1ABCDE}, Jerzy Białecki^{2ABE}, Janusz Wieczorek^{1BCDE}, Łukasz Paluch^{1BF}, Agnieszka Dąbrowska-Thing^{1BF}, Jerzy Walecki^{1ADE}

¹ Department of Diagnostic Imaging, GrUCA Teaching Hospital, Medical Center of Postgraduate Education, Otwock, Poland

² Adults Orthopaedic Ward, II Orthopaedic Department, GrUCA Teaching Hospital, Medical Center of Postgraduate Education, Otwock, Poland

Author's address: Małgorzata Frel, Department of Diagnostic Imaging, GrUCA Teaching Hospital, Medical Center of Postgraduate Education, Otwock, Poland, e-mail: frelowa@wp.pl

Background:

Infectious spondylodiscitis is characterized by the involvement of two adjacent vertebrae and the intervening disc. Incidence rate of the disease is estimated at 0.4–2 cases per 100000 per year. *Staphylococcus aureus* is the most common infectious agent causing pyogenic spondylodiscitis. Non-pyogenic infections of the spine are most frequently caused by *Mycobacterium tuberculosis*, and fungi. Clinical symptoms are nonspecific. Early diagnosis and appropriate treatment can prevent unfavorable irreversible sequela for the patient.

Material/Methods:

Significant developments in techniques of imaging of pathological tissues raised expectations among the clinicians regarding possibility to distinguish between tuberculous spondylodiscitis and pyogenic spondylodiscitis on MR images. The aim of this study was to identify and differentiate between features of tuberculous and pyogenic spondylodiscitis on MR images.

We performed retrospective analysis of MR images obtained from 34 patients with confirmed spondylodiscitis (18 with pyogenic spondylodiscitis, and 16 with tuberculous spondylodiscitis). Data acquisition was performed using 1.5 T MRI scanners where images were obtained using similar protocols. T2 TIRM and T1-weighted images with and without contrast enhancement were subject to assessment in coronal, axial and sagittal planes.

Results:

Characteristic features of pyogenic spondylodiscitis include: involvement of the lumbar spine, ill-defined paraspinal abnormal contrast enhancement, diffuse/homogeneous contrast enhancement of vertebral bodies, low-grade destruction of vertebral bodies, hyperintense/homogeneous signal from the vertebral bodies on T2 TIRM images. Prevailing features of tuberculous spondylodiscitis included: involvement of the thoracic spine, involvement of 2 or more adjacent vertebral bodies, severe destruction of the vertebral body, focal/heterogeneous contrast enhancement of vertebral bodies, heterogeneous signal from the vertebral bodies on T2 TIRM images, well-defined paraspinal abnormal contrast enhancement, paraspinal and epidural abscesses, meningeal enhancement at the affected spine level.

Conclusions:

Comparison of MR images of patients diagnosed with pyogenic spondylodiscitis and tuberculous spondylodiscitis allowed identification of individual characteristics for preliminary differentiation between TB and infectious spondylodiscitis and thereby enabling proper treatment.

MeSH Keywords:

Bone Diseases, Infectious • Discitis • Magnetic Resonance Imaging • Spine • Tuberculosis, Spinal

PDF file:

<http://www.polradiol.com/abstract/index/idArt/899606>

Background

Differential diagnosis of vertebral inflammatory lesions has always been a challenge to orthopedic surgeons and radiologists due to equivocal clinical course and unclear results of imaging studies, x-ray in particular being characterized by low specificity and relatively low sensitivity, especially at early stages of the disease.

Purulent/nonspecific/spondylitis is the most common inflammatory condition of the vertebra. It is rare in healthy individuals without clinical signs of immunosuppression, and most often develops as a result of penetrating trauma or surgical intervention/as a surgical complication/.

In other cases of purulent spondylitis we should always suspect immunosuppression and presence of a primary inflammatory focus.

Prevalence of spondylitis is estimated at 0.4–2 cases per 100 000/year [1]. However, latest reports point to increasing incidence all over the world, particularly in the Southern Africa, where spondylitis is diagnosed in 11% of all patients reporting to the doctor due to back pain [2].

Two age peaks may be observed in the incidence of the disease – before the 20th year of life and between 50 and 70 years of age, with slight preponderance of men (M:K 1.5–2:1) [1].

Staphylococcus aureus is the most common cause of nonspecific spondylitis (20–84% of cases), followed by *Enterobacteriaceae*, *Klebsiella*, *Staphylococcus epidermidis*, *Streptococcus viridans*, *Escherichia coli* [3].

Pseudomonas aeruginosa and increasingly more common hospital strains of methicillin-resistant *Staphylococcus aureus* were identified among patients with infections due to intravenous injections (especially in the course of long-term hospital treatment) [4]. Treatment is particularly difficult in such cases, as those bacterial species are highly resistant to most antibiotics.

Atypical clinical course of spondylitis, where routine cultures yield negative results, may be indicative of tuberculosis, brucellosis, fungal, or parasitic infections [5–9].

Fungal infections are incredibly rare, being encountered almost exclusively among patients with profound immunosuppression (e.g. AIDS, leukemia, solid-organ transplantation, chemotherapy for neoplastic disease).

Spinal tuberculosis/Pott's disease/constitutes about 50% cases of osteoarticular tuberculosis and 1–3% of all cases of tuberculosis; in the developing countries this proportion reaching as much as 10–15% [10].

Acquired immunosuppression due to, e.g. HIV infection, is an important factor increasing the incidence of tuberculosis. HIV-positive patients are at 20–37-fold higher risk of developing tuberculosis than individuals without the infection. *Mycobacterium tuberculosis* is the causative agent in Pott's disease.

From a clinical point of view, the following factors indicate the nonspecific background of the inflammatory process: acute onset of the disease with hectic fever, surgical procedure on the abdomen immediately before the infection, significantly elevated inflammatory markers – CRP, ESR.

On the other hand, medical history often supports the tuberculous etiology of the disease: exposure to TB, insidious onset without significantly elevated temperature, lower CRP and ESR values, and positive tuberculin skin test.

X-ray is the first-line imaging study; it may demonstrate narrowing of intervertebral spaces and irregularity of vertebral marginal endplates [4]. These changes are visible only after several weeks of the pathological process.

Sclerosis of vertebral bodies, formation of bone blocks, destruction and collapse of vertebral bodies resulting in "gibbus deformity" (a deformation only observed in TB infections) may later develop.

Beside the above-mentioned features, CT examination reveals soft tissue edema and/or abscesses [11].

CT is more sensitive than x-ray in the diagnosis of moderately advanced lesions, but neither x-ray nor CT enable identification of early inflammatory process, or unequivocal differentiation between tuberculous and nonspecific etiology at later stages of the disease.

Before laboratory confirmation and final diagnosis is made based on the whole clinical picture, inflammatory process (particularly in case of specific lesions) may be so advanced, that treatment becomes difficult and prognosis unfavorable. Therefore, early diagnosis allows for implementation of proper treatment and protects the patient from irreversible sequelae: neurological disorders, vertebral deformation and resultant disability [12–21].

Significant progress in the imaging of tissue pathologies using MRI raised expectations among the clinicians with regard to the possibility to differentiate between nonspecific/purulent inflammation and spinal tuberculosis. In many cases, this imaging study was decisive for administration prolonged anti-mycobacterial treatment. Knowledge of the imaging features of nonspecific and specific spondylitis is of great clinical significance due to scarce or completely absent symptoms of tuberculosis.

Despite publishing of several dozen important clinical reports devoted to spondylitis over the past 20 years, only some of these publications contain comparative analysis of typical MRI characteristics of specific vs. nonspecific inflammation [12,22–25].

We attempted to identify distinguishing features for nonspecific/purulent and specific/tuberculous spondylitis in MR imaging.

Aim

The goal of this work was to identify the features distinguishing between nonspecific and specific spondylitis in MR imaging.

Material and Methods

Retrospective analysis of MR studies performed over the years 2011–2015 in 34 patients diagnosed with spondylitis (including 18 patients with nonspecific spondylitis – K:M=3:15, and 16 patients with TB spondylitis – K:M=7:9).

Age range of patients with purulent spondylitis was 47–74 years (median age 61.5 years); with TB spondylitis: 33–79 years (median age 52 years).

Among patients with nonspecific inflammation time from the onset of symptoms to MR imaging lasted from 3 months to one year, and from 5 months to one year among patients with TB infection.

Preliminary diagnosis of spondylitis was confirmed using microbiological studies, microscopy, and in some cases, based on positive response to implemented treatment.

MR studies, always preceded by x-ray imaging, were performed with 1.5T apparatuses using similar protocols.

T1-weighted, T2 TIRM, T1-weighted with contrast sequences in sagittal, transverse, and frontal planes were subject to assessment.

MRI studies were consulted independently by two radiologists with years of experience in the diagnostics of musculoskeletal system.

The following features were evaluated:

1. Level of lesions;
2. Number of involved vertebrae;
3. Vertebral body signal in T1-weighted imaging;
 - two vertebral bodies adjacent to the inflamed disc were assessed and compared to the signal from the remaining vertebral bodies;
 - signal was described as hypointense, hyperintense, isointense, heterogeneous (hypo- and hyperintense areas) with respect to the non-inflamed vertebrae;
4. Scope of signal in T1-weighted images;
 - two vertebrae adjacent to the inflamed disc were assessed;
 - scope of signal was described as 25%, 50%, 75%, or 100% of that from the unaffected vertebrae;
5. Vertebral signal in T2 TIRM images;
 - two vertebral bodies adjacent to the inflamed disc were assessed and compared to the signal from the remaining vertebrae;
 - signal strength was described as hypointense, hyperintense, isointense, fluid, heterogeneous (hypo-, hyperintense, fluid areas) in relation to the unaffected vertebrae;
6. Scope of signal in T2 TIRM images;

- two vertebral bodies adjacent to the inflamed disc were assessed;
 - scope of signal was described as 25%, 50%, 75%, or 100% of that from the vertebral body;
7. Type of signal enhancement in T1-weighted images following administration of contrast and the scope of contrast enhancement;
 - two vertebral bodies adjacent to the affected disc were assessed;
 - it was described as diffuse/homogeneous, focal/heterogeneous, marginal, lack of signal enhancement;
 - scope of signal was described as 25%, 50%, 75%, or 100%;
 8. Extent of vertebral destruction;
 - the most severely affected vertebra adjacent to the inflamed disc was assessed and compared to the unchanged vertebral bodies above and below the lesion;
 - degree of height reduction was described as follows: 0 – no height reduction, 1 – <25% reduction, 2 – 25–50% reduction, 3– 50–75% reduction, 4 – >75% reduction;
 9. Condition of the marginal endplate;
 - marginal endplate of the most severely affected vertebral body adjacent to the infected disc was assessed in T1-weighted images;
 - endplate was described as: unchanged, with erosions, complete destruction (endplate not visible);
 10. Signal from the intervertebral disc;
 - inflamed discs were compared to the unaffected ones;
 - in T1-weighted images signal was described as isointense, hypointense, hyperintense, heterogeneous (hyper/hypo);
 - in T2 TIRM images it was described as isointense, hypointense, hyperintense, fluid, heterogeneous (hyper/hypo/fluid);
 11. Contrast enhancement of the intervertebral disc in T1-weighted images;
 - described as diffuse, focal, marginal, lack of enhancement;
 12. Extent of intervertebral disc destruction;
 - none – intervertebral disc height and signal are unchanged;
 - mild – height of the disc is unaffected, signal is changed, height is increased secondary to widening of intervertebral space;
 - moderate – disc height decreased by <50%, height of the disc is partly maintained and signal with minute fluid-filled area;
 - severe – height of the disc decreased by >50%;
 - complete destruction – disc abscess (fluid signal in T2 TIRM images without contrast enhancement), disc structures indistinguishable;
 13. Areas of contrast enhancement in paravertebral soft tissues;
 - described as well-demarcated vs. poorly-demarcated regions of contrast enhancement
 14. Moreover, we assessed for the presence of abscesses in paravertebral tissues, and meningeal enhancement at the affected vertebral segment (segment defined as two affected vertebral bodies and the intervertebral disc in between).

Table 1. Level of the lesion.

Vertebrae – Level of the lesion – spinal level	Variable	Diagnosis		Total
		Purulent infection	Tuberculosis	
Th	Absolute number	6	12	18
	% in a column	33.3%	75.0%	52.9%
	Standardized residuals	-2.4	2.4	
L	Absolute number	12	3	15
	% in a column	66.7%	18.8%	44.1%
	Standardized residuals	2.8	-2.8	
Th12/L1	Absolute number	0	1	1
	% in a column	0.0%	6.3%	2.9%
	Standardized residuals	-1.1	1.1	
Total	Absolute number	18	16	34
	% in a column	100.0%	100.0%	100.0%
Result of statistical analysis		Value	Level of significance (p-value)	
Statistical test: Crammer's V		.494	.016	

Table 2. Number of affected vertebral bodies.

Vertebrae – Number of affected vertebral bodies	Variable	Diagnosis		Total
		Purulent infection	Tuberculosis	
2	Absolute number	18	12	30
	% in a column	100.0%	75.0%	88.2%
	Standardized residuals	2.3	-2.3	
> 2	Absolute number	0	4	4
	% in a column	0.0%	25.0%	11.8%
	Standardized residuals	-2.3	2.3	
Total	Absolute number	18	16	34
	% in a column	100.0%	100.0%	100.0%
Result of statistical analysis		Value	Level of significance (p-value)	
Statistical test: Crammer's V		.387	.024	

Results

The above-mentioned features/distractors/enabling differentiation between specific vs. nonspecific inflammatory disease were subject to statistical analysis. Tables 1–20 present these results. There is a clear relationship between the affected vertebral level and type of infection. The thoracic (Th) region is more characteristic for tuberculosis, while the lumbar (L) region is more specific for purulent spondylitis (Table 1).

Table 2 shows that the number of vertebral bodies not exceeding 2 suggests nonspecific inflammation, while larger number of affected vertebrae are indicative of tuberculosis.

Table 3 demonstrates lack of statistical dependence between the types of signal from the vertebral bodies in T1-weighted images and spondylitis etiology.

There was no statistical relationship between the scope of changed vertebral signal in T1-weighted images and type of inflammatory condition (Table 4).

Table 3. Signal intensity from vertebral bodies on T1-weighted images.

Variable		Diagnosis		Total
Vertebrae – Signal intensity on T-weighted images		Purulent infection	Tuberculosis	
Hypointense	Absolute number	18	14	32
	% in a column	100.0%	87.5%	94.1%
	Standardized residuals	1.5	-1.5	
Heterogeneous	Absolute number	0	2	2
	% in a column	0.0%	12.5%	5.9%
	Standardized residuals	-1.5	1.5	
Total	Absolute number	18	16	34
	% in a column	100.0%	100.0%	100.0%
Result of statistical analysis		Value	Level of significance (p-value)	
Statistical test: Crammer's V		.265	.122	

Table 4. Scope of altered signal from vertebral bodies in T1-weighted images.

Variable		Diagnosis		Total
Vertebrae – Scope of T1-weighted signal		Purulent infection	Tuberculosis	
25%	Absolute number	2	0	2
	% in a column	11.1%	0.0%	5.9%
50%	Absolute number	3	3	6
	% in a column	16.7%	18.8%	17.6%
75%	Absolute number	11	11	22
	% in a column	61.1%	68.8%	64.7%
100%	Absolute number	10	11	21
	% in a column	55.6%	68.8%	61.7%
Total	Absolute number	18	16	34
	% in a column	-	-	-
Result of statistical analysis		Value	Level of significance (p-value)	
Statistical test: chi-square (degrees of freedom=4)		2.755	0.600	

Table 5. Signal intensity from vertebral bodies in T2-weighted TIRM images.

Variable		Diagnosis		Total
Vertebrae – Signal intensity in T2 TIRM images		Purulent infection	Tuberculosis	
Hyperintense	Absolute number	16	5	21
	% in a column	88.9%	31.3%	61.8%
	Standardized residuals	3.5	-3.5	
Heterogeneous	Absolute number	2	11	13
	% in a column	11.1%	68.8%	38.2%
	Standardized residuals	-3.5	3.5	
Total	Absolute number	18	16	34
	% in a column	100.0%	100.0%	100.0%
Result of statistical analysis		Value	Level of significance (p-value)	
Statistical test: Crammer's V		.592	0.001	

Table 6. Scope of altered signal from vertebral bodies in T2 TIRM images.

Variable		Diagnosis		Total
Vertebrae – Scope of T2 TIRM signal		Purulent infection	Tuberculosis	
25%	Absolute number	1	0	1
	% in a column	5.6%	0.0%	2.9%
50%	Absolute number	3	1	4
	% in a column	16.7%	6.3%	11.8%
75%	Absolute number	9	3	12
	% in a column	50.0%	18.8%	35.3%
100%	Absolute number	14	15	29
	% in a column	77.8%	93.8%	85.3%
Total	Absolute number	18	16	34
	% in a column	–	–	–
Result of statistical analysis		Value	Level of significance (p-value)	
Statistical test: chi-square (degrees of freedom=4)		7.146	0.128	

Table 7. Type of vertebral contrast enhancement.

Variable		Diagnosis		Total
Vertebrae – Contrast enhancement		Purulent infection	Tuberculosis	
Homogeneous	Absolute number	16	6	22
	% in a column	88.9%	37.5%	64.7%
	Standardized residuals	3.1	–3.1	
Heterogeneous	Absolute number	2	10	12
	% in a column	11.1%	62.5%	35.3%
	Standardized residuals	–3.1	3.1	
Total	Absolute number	18	16	34
	% in a column	100.0%	100.0%	100.0%
Result of statistical analysis		Value	Level of significance (p-value)	
Statistical test: Crammer's V		.537	0.002	

Table 8. Scope of vertebral contrast enhancement.

Variable		Diagnosis		Total
Vertebrae – Scope of contrast enhancement		Purulent infection	Tuberculosis	
25%	Absolute number	2	0	2
	% in a column	11.1%	0.0%	5.9%
50%	Absolute number	3	2	5
	% in a column	16.7%	12.5%	14.7%
75%	Absolute number	10	9	19
	% in a column	55.6%	56.3%	55.9%
100%	Absolute number	13	12	25
	% in a column	72.2%	75.0%	73.5%
Total	Absolute number	18	16	34
	% in a column	–	–	–
Result of statistical analysis		Value	Level of significance (p-value)	
Statistical test: chi-square (degrees of freedom=4)		2.041	0.728	

Table 9. Intervertebral disc signal intensity in T1-weighted images.

Variable		Diagnosis		Total
Disc – Signal in T1-weighted images		Purulent infection	Tuberculosis	
Isointense	Absolute number	15	16	31
	% in a column	83.3%	100.0%	91.2%
	Standardized residuals	-1.7	1.7	
Hypointense	Absolute number	3	0	3
	% in a column	16.7%	0.0%	8.8%
	Standardized residuals	1.7	-1.7	
Total	Absolute number	18	16	34
	% in a column	100.0%	100.0%	100.0%
Result of statistical analysis		Value	Level of significance (p-value)	
Statistical test: Crammer's V		.293	0.087	

Table 10. Intervertebral disc signal intensity in T2 TIRM images.

Variable		Diagnosis		Total
Discs – Signal intensity in T2 TIRM images		Purulent infection	Tuberculosis	
Isointense	Absolute number	0	3	3
	% in a column	0.0%	18.8%	8.8%
	Standardized residuals	-1.9	1.9	
Hyperintense	Absolute number	7	3	10
	% in a column	38.9%	18.8%	29.4%
	Standardized residuals	1.3	-1.3	
Fluid	Absolute number	7	6	13
	% in a column	38.9%	37.5%	38.2%
	Standardized residuals	.1	-.1	
Heterogeneous	Absolute number	4	4	8
	% in a column	22.2%	25.0%	23.5%
	Standardized residuals	-2	.2	
Total	Absolute number	18	16	34
	% in a column	100.0%	100.0%	100.0%
Result of statistical analysis		Value	Level of significance (p-value)	
Statistical test: Crammer's V		.367	0.206	

There is a relationship between type of signal from vertebral bodies in T2 TIRM images and the type of infection. Hyperintense signal is typical for purulent infection, while heterogeneous signal is typical for tuberculosis (Table 5).

Scope of altered signal from vertebral bodies in T2-weighted images is not associated with a specific type of infection (Table 6).

We demonstrated a relationship between type of contrast enhancement of vertebral bodies and type of infection.

Homogeneous enhancement suggests purulent infection, while heterogeneous enhancement indicates tuberculous spondylitis (Table 7).

There is no statistically significant dependence between the scope of contrast enhancement of vertebral bodies and the type of inflammation (Table 8).

Table 9 shows that vertebral signal in T1-weighted images does not correlate with the type of inflammation. In Table 10 we demonstrated lack of statistically significant

Table 11. Type of intervertebral disc contrast enhancement.

Variable		Diagnosis		Total
Discs – Contrast enhancement		Purulent infection	Tuberculosis	
Diffuse	Absolute number	3	0	3
	% in a column	16.7%	0.0%	8.8%
	Standardized residuals	1.7	-1.7	
Focal	Absolute number	2	2	4
	% in a column	11.1%	12.5%	11.8%
	Standardized residuals	-.1	.1	
Marginal	Absolute number	11	8	19
	% in a column	61.1%	50.0%	55.9%
	Standardized residuals	.7	-.7	
None	Absolute number	2	6	8
	% in a column	11.1%	37.5%	23.5%
	Standardized residuals	-1.8	1.8	
Total	Absolute number	18	16	34
	% in a column	100.0%	100.0%	100.0%
Result of statistical analysis		Value	Level of significance (p-value)	
Statistical test: Crammer's V		.398	0.146	

Table 12. Severity of vertebral destruction.

Variable		Diagnosis		Total
Vertebrae – Severity of destruction		Purulent infection	Tuberculosis	
None	Absolute number	3	1	4
	% in a column	16.7%	6.3%	11.8%
	Standardized residuals	.9	-.9	
<25%	Absolute number	2	1	3
	% in a column	11.1%	6.3%	8.8%
	Standardized residuals	.5	-.5	
26–50%	Absolute number	10	2	12
	% in a column	55.6%	12.5%	35.3%
	Standardized residuals	2.6	-2.6	
51–75%	Absolute number	2	6	8
	% in a column	11.1%	37.5%	23.5%
	Standardized residuals	-1.8	1.8	
> 75%	Absolute number	1	6	7
	% in a column	5.6%	37.5%	20.6%
	Standardized residuals	-2.3	2.3	
Total	Absolute number	18	16	34
	% in a column	100.0%	100.0%	100.0%
Result of statistical analysis		Value	Level of significance (p-value)	
Statistical test: Crammer's V		.598	0.016	

Table 13. Condition of marginal endplates.

	Variable	Diagnosis		Total
		Endplates	Purulent infection	
Erosions	Absolute number	8	3	11
	% in a column	44.4%	18.8%	32.4%
	Standardized residuals	1.6	-1.6	
Destruction	Absolute number	10	13	23
	% in a column	55.6%	81.3%	67.6%
	Standardized residuals	-1.6	1.6	
Total	Absolute number	18	16	34
	% in a column	100.0%	100.0%	100.0%
Result of statistical analysis		Value	Level of significance (p-value)	
Statistical test: Crammer's V		.274	0.110	

Table 14. Severity of destruction of intervertebral discs.

	Variable	Diagnosis		Total
		Discs – severity of destruction	Purulent infection	
Mild	Absolute number	4	1	5
	% in a column	22.2%	6.3%	14.7%
	Standardized residuals	1.3	-1.3	
Moderate	Absolute number	5	6	11
	% in a column	27.8%	37.5%	32.4%
	Standardized residuals	-6	.6	
Severe	Absolute number	2	3	5
	% in a column	11.1%	18.8%	14.7%
	Standardized residuals	-6	.6	
Complete	Absolute number	7	6	13
	% in a column	38.9%	37.5%	38.2%
	Standardized residuals	.1	-.1	
Total	Absolute number	18	16	34
	% in a column	4	1	5
Result of statistical analysis		Value	Level of significance (p-value)	
Statistical test: Crammer's V		.246	0.561	

dependence between type of signal from intervertebral discs in T2 TIRM images and the type of inflammation.

Table 11 shows lack of statistically significant relationship between type of contrast enhancement of the intervertebral discs and a type of inflammation.

Table 12 shows that degree of vertebral destruction below 50% is more characteristic for purulent infection, while

destruction exceeding 50% is more tightly associated with TB infection.

Table 13 demonstrates that the degree of destruction of marginal endplates does not determine the type of inflammation. The extent of intervertebral disc destruction also does not correlate with type of spondylitis (Table 14).

Table 15. Enhancement of paravertebral tissues.

Variable		Diagnosis		Total
		Purulent infection	Tuberculosis	
Additional features – enhancement of paraspinal tissues				
0	Absolute number	1	0	1
	% in a column	5.6%	0.0%	2.9%
	Standardized residuals	1.0	-1.0	
1	Absolute number	17	16	33
	% in a column	94.4%	100.0%	97.1%
	Standardized residuals	-1.0	1.0	
Total	Absolute number	18	16	34
	% in a column	100.0%	100.0%	100.0%
Result of statistical analysis		Value	Level of significance (p-value)	
Statistical test: Crammer's V		.164	0.339	

Table 16. Types of enhancement of paraspinal tissues.

Variable		Diagnosis		Total
		Purulent infection	Tuberculosis	
Additional features – type of enhancement of paraspinal tissues				
Well- demarcated	Absolute number	4	15	19
	% in a column	23.5%	93.8%	57.6%
	Standardized residuals	-4.1	4.1	
Poorly demarcated	Absolute number	13	1	14
	% in a column	76.5%	6.3%	42.4%
	Standardized residuals	4.1	-4.1	
Total	Absolute number	17	16	33
	% in a column	100.0%	100.0%	100.0%
Result of statistical analysis		Value	Level of significance (p-value)	
Statistical test: Crammer's V		.710	0.000	

Table 17. Paraspinal abscess.

Variable		Diagnosis		Total
		Purulent infection	Tuberculosis	
Additional features – paraspinal abscess				
0	Absolute number	11	4	15
	% in a column	61.1%	25.0%	44.1%
	Standardized residuals	2.1	-2.1	
1	Absolute number	7	12	19
	% in a column	38.9%	75.0%	55.9%
	Standardized residuals	-2.1	2.1	
Total	Absolute number	18	16	34
	% in a column	100.0%	100.0%	100.0%
Result of statistical analysis		Value	Level of significance (p-value)	
Statistical test: Crammer's V		.363	0.034	

Table 18. Meningeal enhancement.

	Variable	Diagnosis		Total
		Purulent infection	Tuberculosis	
0	Absolute number	13	4	17
	% in a column	72.2%	25.0%	50.0%
	Standardized residuals	2.7	-2.7	
1	Absolute number	5	12	17
	% in a column	27.8%	75.0%	50.0%
	Standardized residuals	-2.7	2.7	
Total	Absolute number	18	16	34
	% in a column	100.0%	100.0%	100.0%
Result of statistical analysis		Value	Level of significance (p-value)	
Statistical test: Crammer's V		.471	0.006	

Table 19. Epidural abscess.

	Variable	Diagnosis		Total
		Purulent infection	Tuberculosis	
0	Absolute number	16	7	23
	% in a column	88.9%	43.8%	67.6%
	Standardized residuals	2.8	-2.8	
1	Absolute number	2	9	11
	% in a column	11.1%	56.3%	32.4%
	Standardized residuals	-2.8	2.8	
Total	Absolute number	18	16	34
	% in a column	100.0%	100.0%	100.0%
Result of statistical analysis		Value	Level of significance (p-value)	
Statistical test: Crammer's V		.482	0.005	

In Table 15 it is shown that contrast enhancement of paravertebral structures does not differentiate between types of inflammation.

In Table 16 we present a relationship between type of enhancement of paravertebral structures and a type of inflammation. Well-demarcated enhancement is typical for TB, while poorly demarcated enhancement is suggestive of purulent infection.

Table 17 shows that presence of a paravertebral abscess is significantly more often indicative of tuberculous infection.

Meningeal enhancement is strongly associated with tuberculous spondylitis (Table 18). Presence of an epidural abscess is considerably more often indicative of tuberculous infection (Table 19).

Intervertebral disc abscess formation is not associated with any particular type of inflammation (Table 20). Table 21 presents a compilation of features differentiating between specific types of spondylitis.

Discussion

In the analyzed material patients we found increased prevalence of the following characteristics among patients with nonspecific/purulent spondylitis compared to tuberculous spondylitis: lumbar spine involvement (67% vs. 19%), presence of poorly demarcated enhancement of paravertebral tissues (76% vs. 6%), diffuse/homogeneous contrast enhancement of vertebral bodies (89% vs. 38%), less vertebral destruction, hyperintense/homogeneous vertebral signal in T2 TIRM images (89% vs. 31%), (Figures 1A-1C, 2A, 2B, 3A-3C, 4).

Table 20. Intervertebral disc abscess.

Variable	Diagnosis		Total
	Purulent infection	Tuberculosis	
Additional features – intervertebral disc abscess			
0	Absolute number	12	13
	% in a column	66.7%	81.3%
	Standardized residuals	-1.0	1.0
1	Absolute number	6	3
	% in a column	33.3%	18.8%
	Standardized residuals	1.0	-1.0
Total	Absolute number	18	16
	% in a column	100.0%	100.0%
Result of statistical analysis		Value	Level of significance (p-value)
Statistical test: Crammer's V		.165	0.336

Table 21. Compilation of differentiating characteristics. Discrimination of tuberculous spondylitis from pyogenic spondylitis. Differentiating features.

	Nonspecific infection	Tuberculous infection
Involved spinal level	L	TH
Number of affected vertebrae	<2	>2
Severity of destruction of vertebral bodies	<50%	>50%
Areas of paraspinal enhancement	Well-demarcated	Poorly demarcated
Vertebral signal in T2 TIRM images	Hyperintense/homogeneous	Heterogeneous
Vertebral enhancement	Diffuse/homogeneous	Focal/heterogeneous
Paraspinal abscess	39% of cases	75% of cases
Epidural abscess	11% of cases	56% of cases
Meningeal enhancement at the affected vertebral level	28% of cases	75% of cases

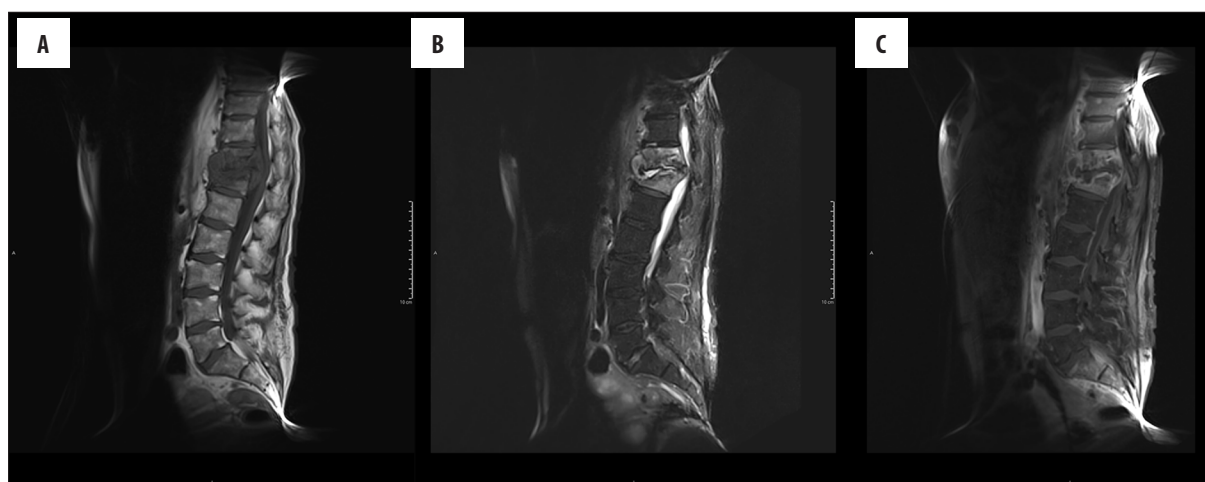


Figure 1. 68-year-old patient diagnosed with Pyogenic Spondylodiscitis(PS). Images (A) T1sag., (B) T2 TIRM sag.,(C) T1 sag. with contrast enhancement. Inflammatory process of the Th11 and Th12 vertebral body, abscess in the intervertebral disc Th11–Th12.

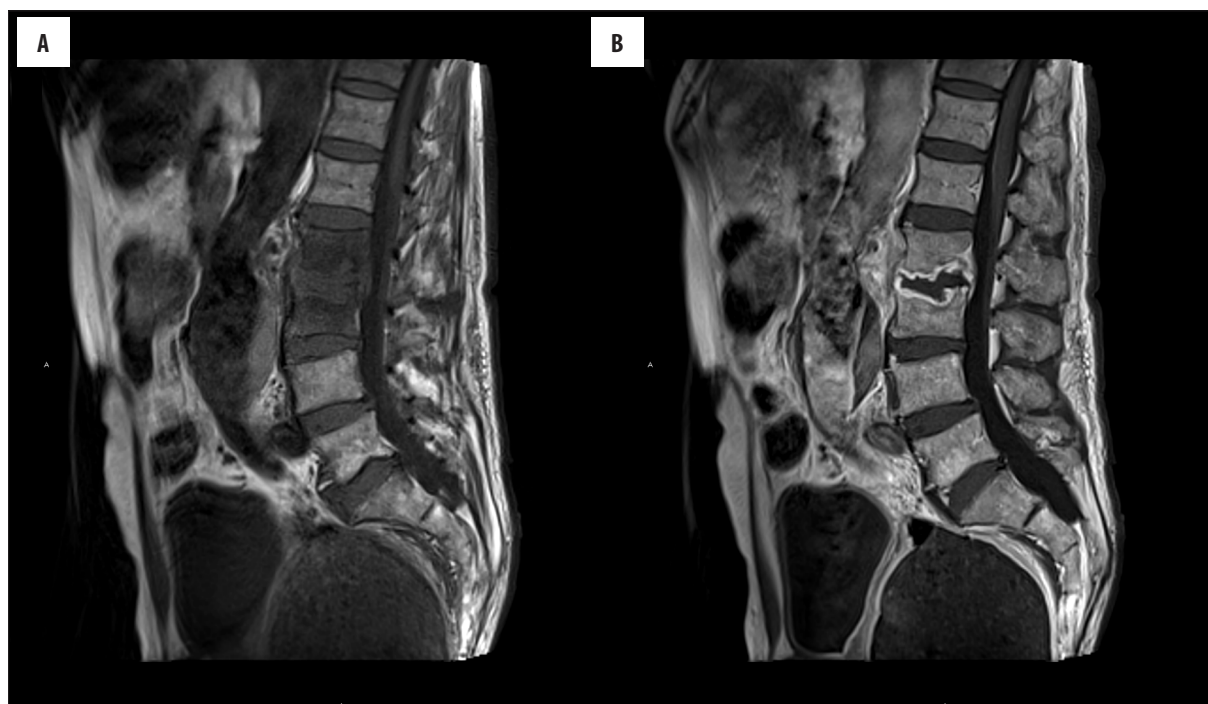


Figure 2. 66-year-old patient diagnosed with PS. Images (A) T1 sag., (B) T1 sag. with contrast enhancement. Inflammatory process on the L2–L3 level. T1 image shows hypointensity of the L2 and L3 vertebral body. Contrast enhancement of the L2 and L3 vertebral body. Rim contrast enhancement in the intervertebral disc.

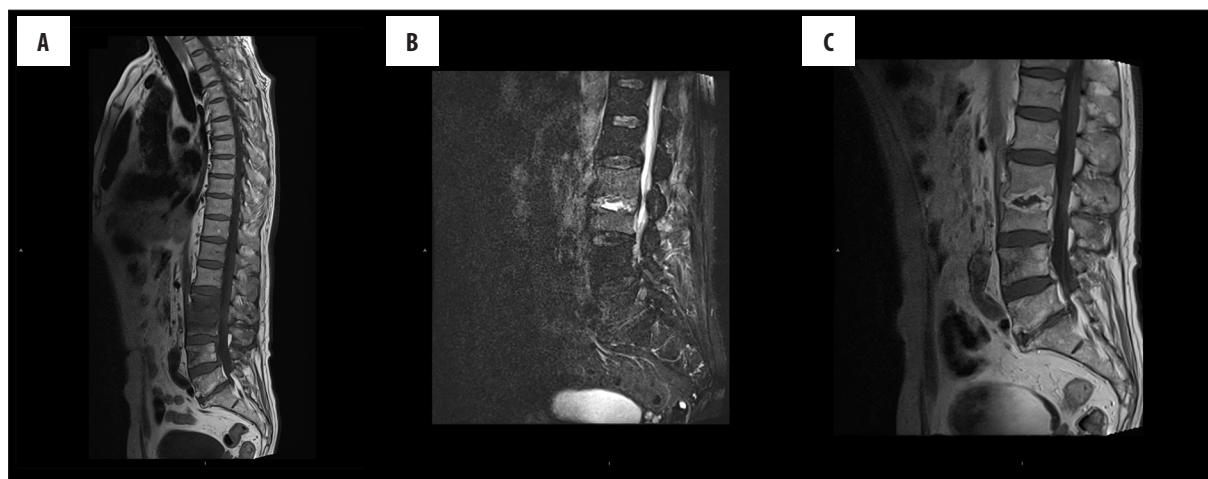


Figure 3. 62-year-old patient diagnosed with PS. Images (A) T1 sag., (B) T2 TIRM, (C) T1 sag. with contrast enhancement. Inflammatory process and contrast enhancement of the L2 and L3 vertebral body. The presence of intervertebral abscess.

The following features were more common in tuberculous infections: thoracic spine involvement (75% vs. 22%), involvement of >2 vertebral bodies (25% vs. 0%), more severe vertebral destruction, focal/heterogeneous contrast enhancement of vertebral bodies (63% vs. 11%), heterogeneous signal from vertebral bodies in T2 TIRM sequences (69% vs. 11%), well-demarcated contrast enhancement of paravertebral tissues (94% vs. 24%), presence of a paravertebral abscess 75% vs. 39%), meningeal enhancement at a level of the affected spinal segment (75% vs. 28%), epidural abscess (56% vs. 11%), (Figures 5A–5C, 6A–6D, 7A, 7B).

The majority of publications devoted to MR imaging of nonspecific and specific spondylitis describe similar symptomatology [10,20,21,22,23].

MR imaging did not show significant differences between nonspecific and specific inflammatory conditions with regard to the vertebral signal in T1-weighted images, or with respect to the extent of changes affecting vertebral bodies in T1-weighted and T2 TIRM images.

We also failed to observe significant difference with respect to the scope of vertebral contrast enhancement. Isointense signal from the intervertebral discs in T1-weighted images predominated in both types of inflammation.

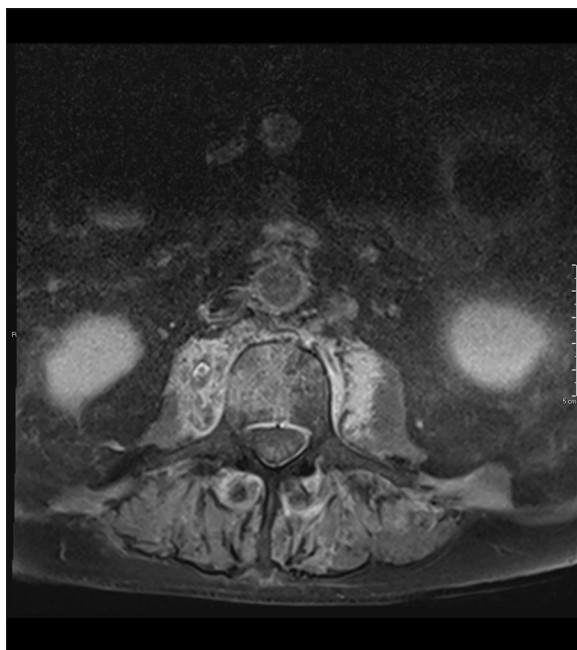


Figure 4. 74-year-old patient diagnosed with PS. Images T1 ax. with contrast enhancement. Ill-defined paraspinal abnormal signal.

T2 TIRM images demonstrated greater variability of signal from the intervertebral discs in cases of tuberculous infections (both isointense, as well as hyperintense, hypointense, and heterogeneous) among all examined patients irrespective of the phase of the disease.

We did not detect significant differences with respect to the pattern of contrast enhancement of the intervertebral discs or the degree of disc destruction. We showed similar prevalence of intervertebral disc abscesses in both types of inflammatory process. We did not observe a statistical relationship between the severity of marginal endplate destruction and a type of infection.

Several publications appeared in the recent years attempting to differentiate between nonspecific and tuberculous

spondylitis based on MR imaging [12,22–25], as well as some review papers on these two disease entities [3,26–29].

Na-Young Jung et al. indicated the following features as the most differentiating between those two types of inflammation: presence of well-demarcated contrast enhancement areas in paravertebral soft tissues in tuberculosis, greater prevalence of abscesses in tuberculosis, involvement of several vertebral bodies in tuberculosis, thoracic spine involvement in tuberculosis [12].

Ming-Chau Chang et al. observed greater extent of vertebral destruction in tuberculous infection, heterogeneous signal from vertebral bodies following contrast administration in tuberculosis, and homogeneous contrast enhancement in purulent inflammation [22]. Likewise, Souza et al. emphasized the significance of vertebral enhancement pattern as a differentiating feature [22,23].

Moreover, in our work we demonstrated greater predilection of nonspecific inflammations to the lumbar spine region, which was previously described in numerous scientific reports concerning spondylitis – both review papers [3,26], as well as clinical studies [22]. However, Jung et al. failed to observe that predilection of nonspecific inflammations to the lumbar region of the vertebra [12].

Based on the results of clinical studies (Harada Y. et al. [25], Chang et al. [22]) Kyu Yeol Lee [3] published a review paper describing more frequent occurrence of epidural abscesses and meningeal spreading of inflammatory infiltration in TB infection. Sharif considered meningeal spreading rare in nonspecific inflammation [26].

We also observed greater frequency of occurrence of epidural abscesses and meningeal enhancement in spondylitis of tuberculous etiology.

Na-Young Jung et al., Souza et al., Griffith et al. [12,23,30] demonstrated involvement of several vertebral bodies as more characteristic for tuberculosis. Lee presented the same observation in his review article [3]. In our material

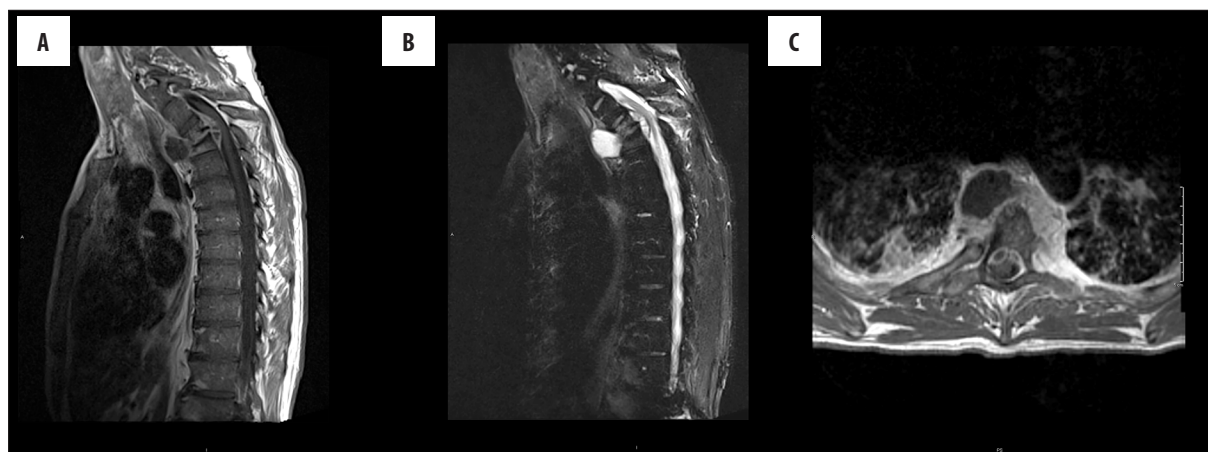


Figure 5. 41-year-old patient diagnosed with TS. Images (A) T1 sag. with contrast enhancement, (B) T2 TIRMsag., (C) T1ax. with contrast enhancement. Inflammatory process on the Th3–Th4 level. Paraspinal abscess, epidural abscess. Partial destruction of the vertebral bodies.

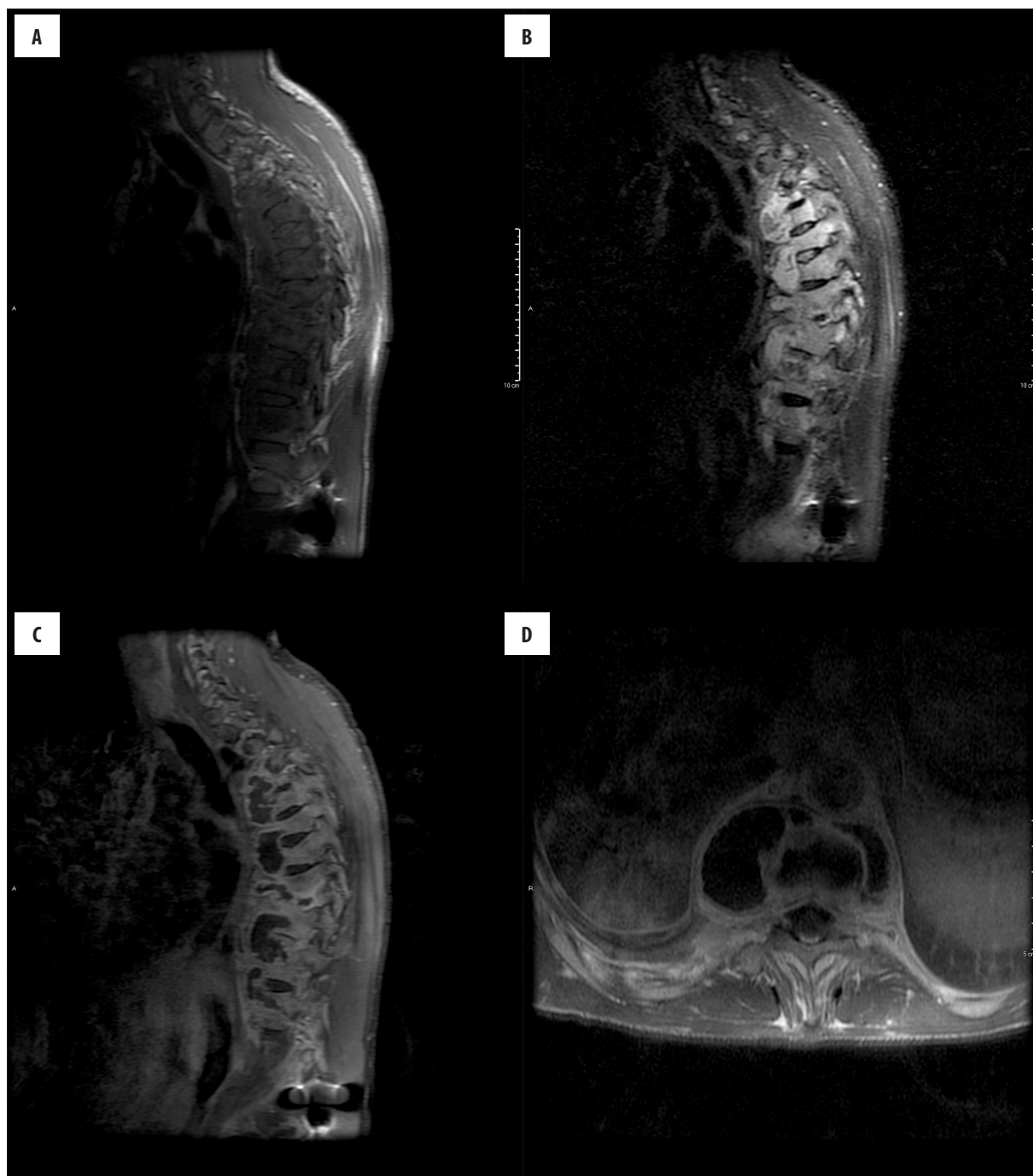


Figure 6. 32-year-old patient diagnosed with Tuberculous Spondylodiscitis (TS). Images (A) T1sag, (B) T2 TIRM, (C) T1 with contrast enhancement, (D) T1 ax. with contrast enhancement. Multilevel inflammatory process in the thoracic region of the spine. Multiple paraspinal abscesses with rim contrast enhancement. Relative disc preservation.

we also observed more frequent involvement of several vertebrae in tuberculous spondylitis.

Many reports published to date indicate sparing of intervertebral discs in tuberculous spondylitis [23,24,31,32], which was linked to the fact that mycobacteria do not produce proteolytic enzymes. In our study intervertebral disc destruction was similar in both types of inflammation, which might be due to longer disease duration before MR imaging. A study by Jung et al. also did not

demonstrate the differences in disc involvement by the inflammatory process [12].

Unlike Chang et al., who underscored the increased incidence of intervertebral disc abscesses in nonspecific inflammation, in our study the incidence of abscess was similar in both types of inflammation [22].

Moreover, we also observed differences in the signal from vertebral bodies in T2 TIRM images. In both types of

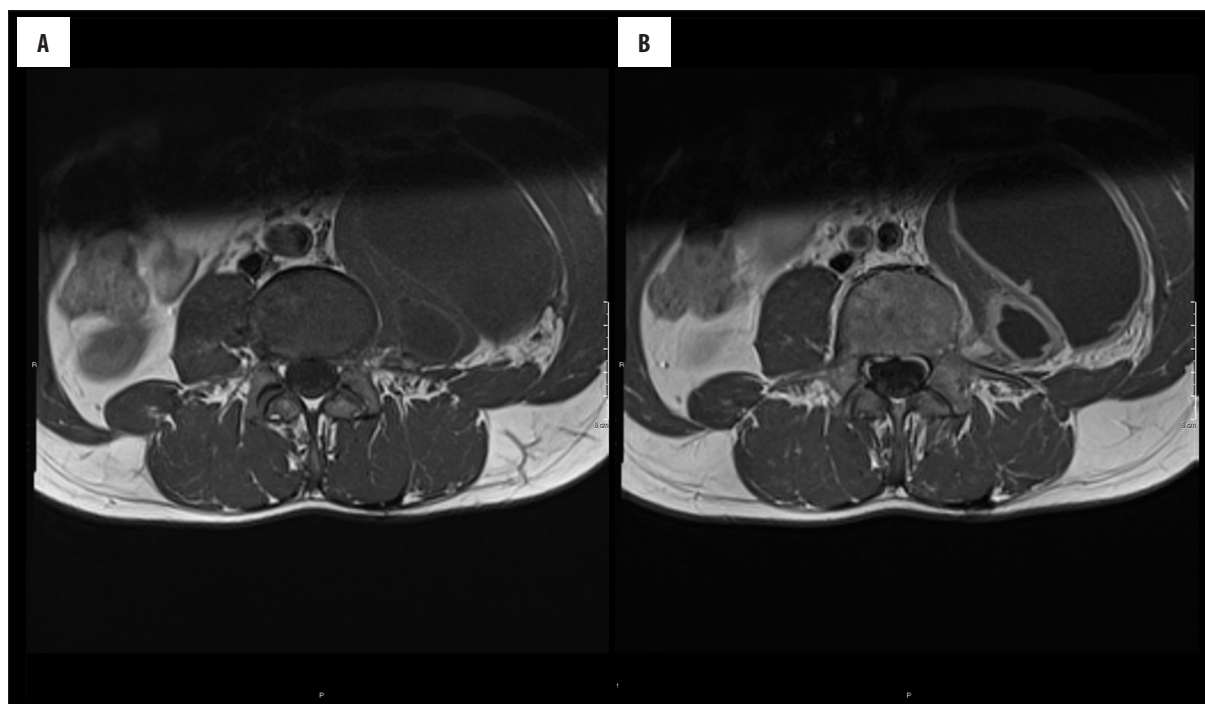


Figure 7. 29-year-old patient diagnosed with TS. Images (A) T1 ax., (B) T1ax with contrast enhancement. The abscesses with rim enhancement in the left iliopsoas.

inflammation – hyperintense/homogeneous in nonspecific, and heterogeneous in tuberculous infection.

Cited clinical studies did not indicate such characteristic as important for differentiation between types of inflammation. Jung et al., described only higher incidence of high signal from the inflamed vertebrae in T2-weighted images in tuberculous spondylitis; however, he did not observe signal heterogeneity in those vertebral bodies [12].

Conclusions

Comparison of MR images in patients diagnosed with spinal tuberculosis and nonspecific spondylitis allowed to identify individual characteristics for preliminary differentiation between these two disease entities and establishing direction for further management.

References:

1. Dziurzyńska-Białek E, Kruk-Bachonko J, Guz W et al: Diagnostic difficulties resulting from morphological image variation in spondylodiscitis MR imaging. *Pol J Radiol*, 2012; 77(3): 25–34
2. Vinas FC, Goldstein JA et al: Spinal Inflammations, <http://emedicine.medscape.com/article/1266702-overview> (accessed 24.05.2016)
3. Lee KY: Comparison of pyogenic spondylitis and tuberculous spondylitis. *Asian Spine J*, 2014; 8(2): 216–23
4. Hatzembuehler J, Pulling TJ: Diagnosis and management of osteomyelitis. *Am Fam Physician*, 2011; 84(9): 10
5. Colmenero JD, Jimenez-Mejias ME, Sanchez-Lora FJ: Pyogenic, tuberculous, and brucellar vertebral osteomyelitis: A descriptive and comparative study of 219 cases. *Ann Rheum Dis*, 1997; 56(12): 709–15
6. Miller DJ, Mejicano GC: Vertebral osteomyelitis due to *Candida species*: Case report and literature review. *Clin Infect Dis*, 2001; 33(4): 523–30
7. Nussbaum ES, Rockswold GL, Bergman TA: Spinal tuberculosis: A diagnostic and management challenge. *J Neurosurg*, 1995; 83(2): 243–47
8. Vinas FC, King PK, Diaz FG: Spinal aspergillus osteomyelitis. *Clin Infect Dis*, 1999; 28(6): 1223–29
9. Wang YC, Lee ST: *Candida* vertebral osteomyelitis: A case report and review of the literature. *Chang Gung Med J*, 2001; 24(12): 810–15
10. Całka K, Plucińska I, Jaźwiec P et al: Tuberculosis of the spine – radiological imaging. Case report. *Pol J Radiol*, 2006; 71(4): 81–85
11. Di Muzio B, Gaillard AF et al: Spondylodiscitis. <http://radiopaedia.org/articles/spondylodiscitis> (accessed 24.05.2016)
12. Jung NY, Jee WH, Ha KY et al: Discrimination of tuberculous spondylitis from pyogenic spondylitis on MRI. *Am J Roentgenol*, 2004; 182(6): 1405–10
13. Moore SL, Raffii M: Imaging of musculoskeletal and spinal tuberculosis. *Radiol Clin North Am*, 2001; 39(2): 329–42

14. Alothman A, Memish ZA, Awada A et al: Tuberculous spondylitis: Analysis of 69 cases from Saudi Arabia. *Spine (Phila Pa 1976)*, 2001; 26(24): E565-70
15. Schimmer RC, Jeanneret C, Nunley PD: Osteomyelitis of the cervical spine: A potentially dramatic disease. *J Spinal Disord Tech*, 2002; 15(2): 110-17
16. Ziai WC, Lewin JJ III: Update in the diagnosis and management of central nervous system infections. *Neurol Clin*, 2008; 26(2): 427-68
17. Kourbeti IS, Tsiodras S, Boumpas DT: Spinal infections: evolving concepts. *Curr Opin Rheumatol*, 2008; 20(4): 471-79
18. An HS, Seldomridge JA: Spinal infections: diagnostic tests and imaging studies. *Clin Orthop Relat Res*, 2006; 444: 27-33
19. Mylona E, Samarkos M, Kakalou E et al: Pyogenic vertebral osteomyelitis: A systematic review of clinical characteristics. *Semin Arthritis Rheum*, 2009; 39(1): 10-17
20. Jaramillo-de la Torre JJ, Bohinski RJ, Kuntz C IV: Vertebral osteomyelitis. *Neurosurg Clin N Am*, 2006; 17(3): 339-51
21. Hegde V, Meredith DS, Kepler CK, Huang RC: Management of postoperative spinal infections. *World J Orthop*, 2012; 3(11): 182-89
22. Chang MC, Wu HT, Lee CH et al: Tuberculous spondylitis and pyogenic spondylitis: Comparative magnetic resonance imaging features. *Spine (Phila Pa 1976)*, 2006; 31(7): 782-88
23. de Souza CG, Gasparett EL, Marchiori E et al: Pyogenic and tuberculous discitis: Magnetic resonance imaging findings for differential diagnosis. *Radiol Bras [online]*, 2013; 46(3): 173-77
24. Arizono T, Oga M, Shiota E et al: Differentiation of vertebral osteomyelitis and tuberculous spondylitis by magnetic resonance imaging. *Int Orthop*, 1995; 19: 319-22
25. Harada Y, Tokuda O, Matsunaga N: Magnetic resonance imaging characteristics of tuberculous spondylitis vs. pyogenic spondylitis. *Clin Imaging*, 2008; 32(4): 303-9
26. Sharif HS: Role of MR imaging in the management of spinal infections. *Am J Roentgenol*, 1992; 158(6): 1333-45
27. Moorthy S, Prabhu NK: Spectrum of MR imaging findings in spinal tuberculosis. *Am J Roentgenol*, 2002; 179(4): 979-83
28. Shanley DJ: Tuberculosis of the spine: Imaging features. *Am J Roentgenol*, 1995; 164: 659-64
29. Garg RK, Somvanshi DS: Spinal tuberculosis: A review. *J Spinal Cord Med*, 2011; 34(5): 440-54
30. Griffith JF, Kumta SM, Leung PC et al: Imaging of musculoskeletal tuberculosis: A new look at an old disease. *Clin Orthop*, 2002; 398: 32-39
31. DJ Kotze, LJ Erasmus. MRI findings in proven *Mycobacterium tuberculosis* (TB) spondylitis. *South African Journal of Radiology*, 2006; 10(2): 6-12
32. Smith AS, Weinstein MA, Mizushima A et al: MR imaging characteristics of tuberculous spondylitis vs. vertebral osteomyelitis. *Am J Roentgenol*, 1989; 153(2): 399-405