

Molecular Characterization of *Trypanosoma cruzi* Reactivation and Follow-up in a Case Series of People With HIV

Marisa Liliana Fernandez,^{1,2,®} Constanza Lopez Albizu,¹ Diego Nicita,² Susana Besuschio,³ Cinthia Giomi,² María Laura Biondi,² María Susana Leguizamón,^{4,5} Julian Garcia,² Marcelo Corti,² Alejandro Schijman,^{3,5} and Juan Miguel Burgos^{4,5}

¹Instituto Nacional de Parasitología Dr M. Fatała Chabén, Administración Nacional de Laboratorios e Institutos de Salud Dr C. Malbrán, Ministerio de Salud, Buenos Aires, Argentina,

²Departamento de Enfermedades Infecciosas, Hospital de Infecciosas Francisco Javier Muñiz, Buenos Aires, Argentina, ³Instituto de Investigaciones en Ingeniería Genética y Biología Molecular "Dr Hector Torres," Consejo Nacional de Investigaciones Científicas y Técnicas, Buenos Aires, Argentina, ⁴IBIO, Universidad Nacional de San Martín, Buenos Aires, Argentina, and ⁵Consejo Nacional de Investigaciones Científicas y Técnicas, CONICET, Buenos Aires, Argentina

We characterize *Trypanosoma cruzi* infections from blood and cerebrospinal fluid samples in a case series of people with human immunodeficiency virus and Chagas disease. We identify different infecting *T. cruzi* populations, highlighting the usefulness of real-time polymerase chain reaction for Chagas disease reactivation diagnosis and evaluation of treatment response.

Keywords. Chagas disease reactivation; people with HIV; qPCR; *Trypanosoma cruzi*.

Chagas disease reactivation (CDR) is observed in immunosuppressed patients, such as people with human immunodeficiency virus (PWH) with CD4 counts <100 cells/mL. In these patients, CDR usually presents central nervous system (CNS) involvement and, less frequently, cardiac compromise with 100% mortality if treatment is delayed [1, 2]. In the CNS compromise scenario, parasite detection in cerebrospinal fluid (CSF) confirms the diagnosis, although lumbar puncture could be contraindicated due to CNS chagoma mass effect. During CDR, trypomastigotes can also be detected in peripheral blood (PB) by means of the Strout method or molecular tools, such as qualitative polymerase chain reaction (PCR) [3]. Because of its

high sensitivity, the latter facilitates DNA parasite detection but does not differentiate chronic from acute infection or reactivation. Conversely, the use of real-time PCR (qPCR) allows parasite quantification to support CDR diagnosis. Additionally, molecular strategies allow *Trypanosoma cruzi* characterization among the 6 discrete typing units (DTUs; ie, TcI–TcVI) differentially observed in disease manifestations [4].

Herein, we describe a case series of PWH with suspected CDR. We evaluated their clinical progress, parasite burdens, and parasite populations in blood and CSF samples before and during trypomastigote treatment.

MATERIALS AND METHODS

We present a case series study of PWH suspected of having CDR because of CNS involvement, *T. cruzi* reactive serology, and low CD4 counts. Patients were admitted at Hospital Muñiz in Argentina from 2015 to 2022. PB and CSF residual samples were collected at Hospital Muñiz and Instituto Nacional de Parasitología.

At admission, *T. cruzi* infection status was assessed by 2 serological tests among enzyme-linked immunosorbent assay, indirect hemagglutination, indirect immunofluorescence, and ChemiLuminescent Immuno Assay. Parasite presence was evaluated by Strout method from PB and microscopically from a pellet obtained from a fresh CSF drop after centrifugation (10 minutes, 3000 rpm) [5]. In addition, DNA was isolated from PB and CSF samples and stored at –20°C for molecular studies performed later. In brief, PB was mixed with 1 volume of guanidine–ethylenediaminetetraacetic acid lysis buffer and DNA isolation was carried out by means of High Pure DNA Isolation Kit (Roche Diagnostics GmbH, Mannheim, Germany). Quantification of parasite burden was carried out by means of qPCR against *T. cruzi* satellite DNA as described by Cura et al [6]. Identification of parasite DTUs was carried out based on 7 nested PCRs designed by Bontempi et al [7]. Finally, PCR–restriction fragment length polymorphism (RFLP) minicircle signatures were carried out to compare parasite populations, following the protocol of Burgos et al [8].

This study was approved by the Institutional Ethics in Research Committee of the Hospital Muñiz, Argentina.

RESULTS

The study included 8 PWH suspected of having CDR due to *T. cruzi* reactive serology and presence of neurological disorders (Table 1). Patients were from Argentina and Paraguay (5 men and 3 women), whose ages ranged from 39 to 69 years. All patients presented with CD4⁺ lymphocyte counts <41

Received 23 May 2023; editorial decision 04 July 2023; accepted 06 July 2023; published online 10 July 2023

Presented in part: 52nd Congress of the Brazil Society of Tropical Medicine, Maceio, Brazil, August 2016.

Correspondence: Marisa L. Fernandez, MD, Hospital de Infecciosas Francisco Javier Muñiz, GCBA, Uspallata 2272, Ciudad de Buenos Aires, Argentina (marisa.fernandez@gmail.com).

Open Forum Infectious Diseases®

© The Author(s) 2023. Published by Oxford University Press on behalf of Infectious Diseases Society of America. This is an Open Access article distributed under the terms of the Creative Commons Attribution-NonCommercial-NoDerivs licence (<https://creativecommons.org/licenses/by-nc-nd/4.0/>), which permits non-commercial reproduction and distribution of the work, in any medium, provided the original work is not altered or transformed in any way, and that the work is properly cited. For commercial re-use, please contact journals.permissions@oup.com

<https://doi.org/10.1093/ofid/ofad357>

Table 1. Clinical and Molecular Characterization of *Trypanosoma cruzi* Reactivation Diagnosis and Treatment Follow-up in Human Immunodeficiency Virus–Coinfected Patients

Patient ID	Age (YO)	Gender	Origin ^a	CD4, Cells/ mL	Clinical Symptoms	Clinical Evolution	Sample	Days of Trypanocidal Treatment						DTU		
								0	1–4	5–8	9–14	15–21	22–28		≥29	
1	42	M	P	7	Seizures	Died after 40 d of BNZ due to status epilepticus probably caused by sequelae brain lesions	CSF	(+) 21 716	ND	...	TcVI	
2	65	M	A	10	Altered state of consciousness	Died after 15 d of BNZ. Had 3 concomitant CNS infections: <i>Cryptococcus</i> spp, CMV, <i>Mtb</i>	PB	...	107	ND	ND	...	ND	...	TcVI	
3	65	W	A	16	Right-sided hemiparesis	Completed 60 d of with BNZ. Alive after 2 y post-CDR	CSF	(+) 258 000	ND	TcV	
4	59	M	A	41	Altered state of consciousness	Extended to 90 d of BNZ. Recovered without neurological sequelae. Started ART. Alive 1 y post-CDR	PB	(-) 63	35	DNQ	ND	...	TcV	
5	69	M	A	19	Altered state of consciousness	Died after 15 d of BNZ and 25 d on mechanic ventilation	CSF	...	(+) 643	(-) DNQ	...	63	47	...	ND	TcV
6	39	W	A	9	Right-sided hemiparesis	Completed 30 d of BNZ and 30 d of nifurtimox. Alive after 6 y post-CDR	PB	...	(-) 1415	605	13	...	TcV + TcVI	
7	40	W	P	12	Seizures	Completed 60 d of BNZ. Alive after 6 y post-CDR	PB	(+) 677	8	13	...	TcV + TcVI	
8	50	M	P	25	Left-sided hemiparesis	Died after 21 d of BNZ (empiric) due to acute abdominal complication before brain biopsy	CSF	(-) ND	...	(-) ND	TcV + TcVI	
							PB	(-) 2	...	ND	ND	ND	TcV + TcVI	

Abbreviations: (+), positive microscopy; (-), negative microscopy; ART, antiretroviral therapy; BNZ, benznidazole; CDR, Chagas disease reactivation; CMV, cytomegalovirus; CNS, central nervous system; CSF, cerebrospinal fluid; DNQ, detectable nonquantifiable by real-time polymerase chain reaction (<1.53 parasite equivalents/mL); DTU, discrete typing unit; M, man; *Mtb*, *Mycobacterium tuberculosis*; ND, not detectable by real-time polymerase chain reaction; NE, not evaluated; PB, peripheral blood; W, woman.

^aOrigin: A, Argentina; P, Paraguay.

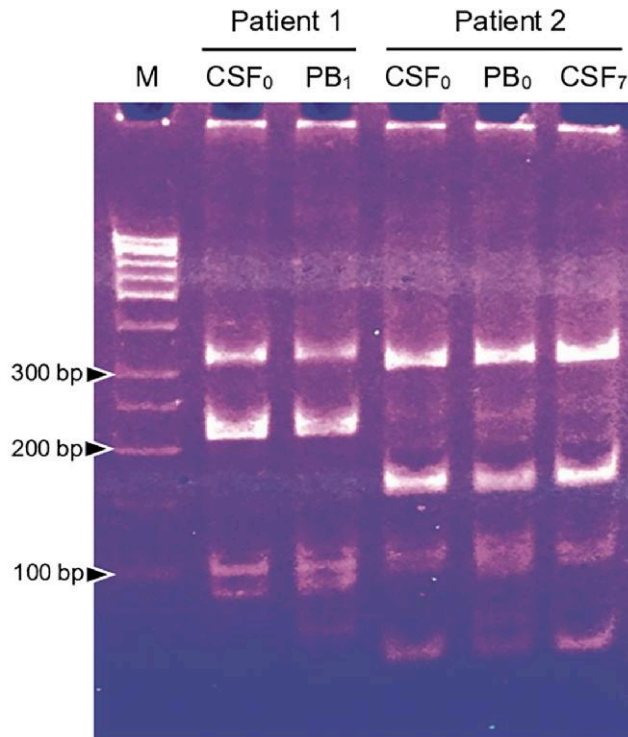


Figure 1. Minicircle signatures (vkDNA polymerase chain reaction–restriction fragment length polymorphism) of *Trypanosoma cruzi* populations detected in peripheral blood (PB) and cerebrospinal fluid (CSF) of patients 1 and 2. Subscript numbers indicate days of treatment. Each patient’s parasite population presented its own minicircle signature, with high identity between CSF and PB samples, suggesting infections by similar parasite populations in both tissues. Abbreviations: CSF, cerebrospinal fluid; M, 50-bp molecular marker; PB, peripheral blood.

cells/mL (Table 1). They were not receiving antiretroviral treatment, except patient 3 who had started it 2 weeks before admission. All patients showed brain lesions on computed tomography and magnetic resonance imaging.

Peripheral blood samples of 6 patients were drawn before initiation of benznidazole (BNZ) treatment. Two of them (33%) presented positive Strout results (patients 6 and 7), whereas all showed detectable *T. cruzi* qPCR findings (100%), ranging from 2 to 3522 par. eq./mL (parasite equivalents/mL). At the same time, lumbar punctures were carried out in 6 patients. Trypomastigote forms were observed in CSF samples in 4 of them (67%; patients 1–4) and their parasite loads were quantified by means of qPCR, ranging between 3511 and 258 000 par. eq./mL. Finally, patients 7 and 8 presented negative findings in CSF by both techniques (Table 1).

All patients were treated with BNZ (5 mg/kg/day) for 60 days, 90 days, or until their death. Treatment was well tolerated, except for patient 6 who was switched to nifurtimox after 30 days due to leukopenia. During follow-up, PB parasitic loads of all patients decreased, even to undetectable values, by qPCR evaluation. Regarding CSF loads, most patients responded with a decrease, reaching values <1.5 par. eq./mL up to the third week (patients 4 and 5) or becoming undetectable on the fourth week (patients 1 and 3). On the other hand, patient 2 showed an

increase in CSF parasite load from 3511 to 13 556 par. eq./mL after 7 days of treatment. Remarkably, this patient presented undetectable PB findings in 3 samples after 3 days of BNZ initiation.

Molecular characterization of infecting *T. cruzi* populations was carried out from all qPCR-positive samples. Infections of 5 patients were characterized from PB and CSF samples. Two presented TcV parasites (patients 3 and 4), 1 presented TcVI (patient 1), and 2 showed a mixed infection with TcV + TcVI in both samples (patients 2 and 6). Three infections were characterized from PB solely. Among them, patient 5 presented TcV parasites and patients 7 and 8 showed a mixed TcV + TcVI infection (Table 1). Last, because treatment response was uneven between PB and CSF samples of patient 2, variable region of kinetoplastid DNA (vkDNA) PCR-RFLP was carried out to analyze parasite populations’ heterogeneity. Observation of very similar profiles between samples suggested the presence of the same parasite populations without selection during CSF colonization from PB (Figure 1).

DISCUSSION

Here we present 8 PWH with chronic *T. cruzi* infection and suspected CDR. Microscopy and qPCR analysis of CSF samples

showed an excellent concordance (κ coefficient = 1) with 4 positive samples (loads >3511 par. eq./mL, patients 1–4) and 1 negative sample (patient 7) by means of both determinations. Among PB samples, concordant findings were obtained from patients 6 and 7 (parasitic loads of 677 and 3522 par. eq./mL, respectively), whereas samples from patients 2, 3, and 4 presented negative Strout results but positive qPCR determinations (parasitic loads between 63 and 805 par. eq./mL). Based on positive microscopic examination of CSF and/or Strout test, CDR was confirmed in 7 patients (patients 1–7). Finally, CDR of patient 8 could not be assigned because negative findings in 2 CSF samples, 3 Strout tests, and a very low DNA parasitic load at admission (2 par. eq./mL), which is commonly found during chronic *T. cruzi* infection in the absence of CDR [3, 9].

During follow-up, all patients showed good treatment response observed by PB qPCR parasitic load decrease, becoming undetectable in most of them, between 1 and 8 weeks after BNZ treatment initiation. Concerning CSF samples, all except patient 2 displayed the same pattern, showing the antiparasitic efficacy of BNZ in CSF during CDR. Patient 2 was the only who presented an increment of CSF parasite load after treatment initiation, dying 15 days afterward. The lack of response would not be due to a CSF-resistant *T. cruzi* population since it showed the same vkDNA PCR-RFLP profile as PB did, which responded positively becoming negative 1 week after treatment initiation. Instead, it could be related to the presence of 3 concomitant CNS opportunistic infections and their treatments (Table 1). Although *T. cruzi* clonal histotropism has been reported in immunocompromised patients, our comparison of vkDNA PCR-RFLP profiles suggests the absence of parasite selection during CSF invasion from the bloodstream [10]. Nevertheless, the results from patient 2 showed that positive PB response may not be directly correlated with CSF clearance. Finally, treatment response was similar with different parasite DTUs. Molecular characterization showed parasites TcV and TcVI, or mixed infections, detected in PB and CSF samples, with both populations frequently found in patients from Argentina and Paraguay [4]. Among other patients who died, patient 1 presented a good parasitological treatment response, and his death was due to status epilepticus. Patient 5 presented a moderate response to treatment showing high parasitic load 2 weeks after starting it. Interestingly, this was the only patient who had undetectable blood BNZ dosage during treatment, likely because he was on mechanical ventilation and received BNZ through nasogastric tube [11]. Four patients are alive 1–6 years after their hospitalization due to CDR. Three of them (patients 3, 6, and 7) completed 60 days of trypanocidal treatment with neurological improvement over the course of the first 2 weeks after initiation, whereas treatment for patient 4 was prolonged to 90 days due to his partial neurological recovery.

Prompt diagnosis and parasitological treatment evaluation in CDR are critical in PWH to improve survival. Benznidazole should be administered after confirmation or strong suspicion of CDR due to its adverse events and possible presence of other opportunistic infections in deeply immunocompromised people. As expected, microscopy assays bring positive findings only in very high parasitic load samples with a low sensitivity for CDR diagnosis in clinical practice. Conversely, qualitative PCR presents high sensitivity for DNA parasite detection, also in chronic-phase patients, precluding CDR definition. In this field, the qPCR advantage for parasitic load discrimination allows proposing it as a tool for CDR diagnosis. Altogether, our findings highlight the usefulness of molecular diagnosis to evaluate parasitemia follow-up and allow us to propose PB load monitoring as a marker for parasitological response during CDR treatment. Finally, incorporation of more studies like ours will allow setting up qPCR burdens to define and evaluate CDR and patients' management protocols.

Notes

Acknowledgments. We thank personnel from the Hospital de Infecciosas Francisco Javier Muñiz Clinical Analysis Division, wards, and Infectious Diseases Residency, especially Florencia Villafañe and Germán Astudillo. We also thank Alejandro Palma for reviewing the manuscript.

Patient consent. The Institutional Ethics in Research Committee of the Hospital Muñiz, Argentina (DI-2020-158-GCABA-HIFJM), approved this study. Informed consent was waived due to local regulation and owing to retrospective data collection.

Financial support. This work was supported by Administración Nacional de Laboratorios e Institutos de Salud (Dr Carlos G. Malbrán, Ministerio de Salud de la Nación, Argentina) and Agencia Nacional de Promoción de la Investigación, el Desarrollo Tecnológico y la Innovación (PICT-2018-01891 to J. M. B.).

Potential conflicts of interest. All authors report no potential conflicts of interest.

References

1. Cordova E, Boschi A, Ambrosioni J, Cudos C, Corti M. Reactivation of Chagas disease with central nervous system involvement in HIV-infected patients in Argentina, 1992–2007. *Int J Infect Dis* 2008; 12:587–92.
2. Shikanai-Yasuda MA, Mediano MFF, Novaes CTG, et al. Clinical profile and mortality in patients with *T. cruzi*/HIV co-infection from the multicenter data base of the “network for healthcare and study of *Trypanosoma cruzi*/HIV co-infection and other immunosuppression conditions.” *PLoS Negl Trop Dis* 2021; 15:e0009809.
3. Panel on Guidelines for the Prevention and Treatment of Opportunistic Infections in Adults and Adolescents with HIV. Guidelines for the prevention and treatment of opportunistic infections in adults and adolescents with HIV. Available at: <https://clinicalinfo.hiv.gov/en/guidelines/hiv-clinical-guidelines-adult-and-adolescent-opportunistic-infections/chagas-disease>. Accessed 21 July 2023.
4. Messenger LA, Miles MA, Bern C. Between a bug and a hard place: *Trypanosoma cruzi* genetic diversity and the clinical outcomes of Chagas disease. *Expert Rev Anti Infect Ther* 2015; 13:995–1029.
5. Flores MA, Trejo A, Paredes AR, et al. El método de concentración de Strout en el diagnóstico de la fase aguda de la enfermedad de Chagas. *Bol Chil Parasit* 1966; 21:2.
6. Cura CI, Ramírez JC, Rodríguez M, et al. Comparative study and analytical verification of PCR methods for the diagnosis of congenital Chagas disease. *J Mol Diagnostics* 2017; 19:673–81.

7. Bontempi IA, Bizai ML, Ortiz S, et al. Simple methodology to directly genotype *Trypanosoma cruzi* discrete typing units in single and mixed infections from human blood samples. *Infect Genet Evol* **2016**; 43:123–9.
8. Burgos JM, Altchek J, Bisio M, et al. Direct molecular profiling of minicircle signatures and lineages of *Trypanosoma cruzi* bloodstream populations causing congenital *Chagas* disease. *Int J Parasitol* **2007**; 37:1319–27.
9. Rodrigues-Dos-Santos Í, Melo MF, de Castro L, et al. Exploring the parasite load and molecular diversity of *Trypanosoma cruzi* in patients with chronic Chagas disease from different regions of Brazil. *PLoS Negl Trop Dis* **2018**; 12:e0006939.
10. Burgos JM, Begher S, Silva HVM, et al. Case report: molecular identification of *Trypanosoma cruzi* I tropism for central nervous system in chagas reactivation due to AIDS. *Am J Trop Med Hyg* **2008**; 78:294–7.
11. Fernández ML, Marson ME, Mastrantonio GE, et al. Benznidazole in cerebrospinal fluid: a case series of Chagas disease meningoencephalitis in HIV-positive patients. *Antimicrob Agents Chemother* **2021**; 65:1–7.