

Clinical and radiographic predictors of the need for facial CT in pediatric blunt trauma: a multi-institutional study

Brittany N Nguyen,¹ Mary J Edwards ,² Shachi Srivatsa,³ Derek Wakeman,⁴ Thais Calderon,⁴ Abdularouf Lamoshi,⁵ Kim Wallenstein,⁶ Tiffany Fabiano,⁷ Brittany Cantor,⁷ Kathryn Bass,⁸ Ananth Narayan,⁹ Ralph Zohn,¹⁰ Mitchell Chess,¹¹ Richard D Thomas¹²

For numbered affiliations see end of article.

Correspondence to

Dr Mary J Edwards;
edwardm2@amc.edu

This article was presented at the Pediatric Trauma Society's annual meeting and approved through the publications committee of the society.

Received 2 February 2022
Accepted 7 April 2022

ABSTRACT

Background Facial injuries are common in children with blunt trauma. Most are soft tissue lacerations and dental injuries readily apparent on clinical examination. Fractures requiring operative intervention are rare. Guidelines for utilization of maxillofacial CT in children are lacking. We hypothesized that head CT is a useful screening tool to identify children requiring dedicated facial CT.

Methods We conducted a multicenter retrospective review of children aged 18 years and under with blunt facial injury who underwent both CT of the face and head from 2014 through 2018 at five pediatric trauma centers. Penetrating injuries and animal bites were excluded. Imaging and physical examination findings as well as interventions for facial fracture were reviewed. Clinically significant fractures were those requiring an intervention during hospital stay or within 30 days of injury.

Results 322 children with facial fractures were identified. Head CT was able to identify a facial fracture in 89% (287 of 322) of children with facial fractures seen on dedicated facial CT. Minimally displaced nasal fractures, mandibular fractures, and dental injuries were the most common facial fractures not identified on head CT. Only 2% of the cohort (7 of 322) had facial injuries missed on head CT and required an intervention. All seven had mandibular or alveolar plate injuries with findings on physical examination suggestive of injury.

Discussion In pediatric blunt trauma, head CT is an excellent screening tool for facial fracture. In the absence of clinical evidence of a mandibular or dental injury, a normal head CT will usually exclude a clinically significant facial fracture.

Level of evidence III.

INTRODUCTION

Facial injuries are common in children sustaining blunt force trauma. The majority are soft tissue lacerations, abrasions, or dental injuries that are readily apparent on physical examination. Facial fractures requiring intervention are rare in children,^{1,2} but soft tissue swelling can make identification by physical examination difficult. In most cases, CT scans are necessary to confirm the diagnosis of facial fracture.^{1,2} Although dedicated facial CT has a high diagnostic value for detecting injury, it comes

Key messages

What is already known on this topic

- ▶ Facial CT is the gold standard for characterization of facial fractures in blunt trauma; however, there is evidence to suggest that head CT will identify many significant injuries and can be useful as a screening tool.

What this study adds

- ▶ A guideline for when facial CT should be considered in pediatric blunt trauma is proposed.

How this study might affect research, practice and/or policy

- ▶ It is proposed to screen children with blunt trauma for facial injury with head CT and physical examination, reserving dedicated facial CT for select patients.

at the cost of ionizing radiation exposure and its inherent risk to the developing child.³ Although there is no question that dedicated facial CT is far superior to other imaging modalities in characterizing bony injury to the face,^{1,4,5} given the exceedingly low rates of injuries requiring intervention, liberal utilization of this modality likely exposes a significant number of children to unnecessary radiation to benefit very few. As many injured children also undergo CT scanning to the head and cervical spine, one must also consider the cumulative effects of repeat exposure to radiosensitive organs in the head and neck. Specifically, with the thyroid gland, repeated radiation exposures with extensive CT scanning for trauma can result in reaching a critical threshold for malignancy risk in some children.⁵

Unfortunately, robust clinical guidelines for cross-sectional imaging of the face to screen for facial fractures in children are lacking. However, several studies from the USA and South Korea demonstrate that head CT can adequately evaluate most facial trauma in children, potentially limiting the need for dedicated facial CT in many cases.^{6–8} We performed a descriptive study to assess the ability of head CT to screen for facial injuries in children requiring intervention in five trauma centers in New York State. We similarly sought to describe clinical predictors that could be combined with head CT to improve

© Author(s) (or their employer(s)) 2022. Re-use permitted under CC BY-NC. No commercial re-use. See rights and permissions. Published by BMJ.

To cite: Nguyen BN, Edwards MJ, Srivatsa S, et al. *Trauma Surg Acute Care Open* 2022;**7**:e000899.

detection of the subset of patients who would benefit from CT scan of the face.⁹

METHODS

Consent for participation was not obtained as this was a retrospective chart review and database analysis with only de-identified data and no protected health information shared between institutions. Each institution queried their trauma registry inclusive of the years 2014 to 2018 for patients aged 18 years and under who underwent both head and maxillofacial CT scans for blunt trauma during their admission. Patients suffering from penetrating trauma and animal bites were excluded from the analysis. Records were then reviewed in detail and patients with facial fractures confirmed by facial CT were included in the analysis. We considered facial CT results to be the confirmatory or gold standard.

Head CT reports were then reviewed and assessed for concordance with facial CT. For each patient with a facial fracture seen on facial CT, if the head CT failed to identify *any* facial fracture, it was considered discordant. Identification of additional facial fractures or superior characterization of facial fractures on facial CT was not considered a discordance if the head CT determined that *any* facial fracture was present. Records were then reviewed to determine the clinical significance of the injuries. Injuries were deemed clinically significant if an intervention was required prior to discharge or within 30 days of discharge at the same institution. The proportion of clinically significant injuries in the discordant cases was assessed and reported. Laceration repairs and nasal packing for hemostasis were excluded from the analysis of interventions. Demographic data were collected to include year of admission, age, mechanism of injury, length of stay, and Injury Severity Score (ISS). If available, the clinical indication for facial imaging was recorded. In cases where the head and facial CT scans were done simultaneously and the results provided in the same report, or if the head CT report referred to the facial CT report for description of facial injury, the head CT scans were reviewed retrospectively in a blinded manner by a radiologist at each institution to determine if a facial fracture was seen. In cases where a significant injury was found, if the indication for imaging was not provided or limited to mechanism alone, the record was further reviewed for physical examination findings in the head, face, and neck.

To characterize various scanning techniques across institutions, 10 head CT scans from each center were randomly selected and reviewed for specific landmarks by a radiologist at each institution. The results of this survey were forwarded to the lead radiologist of the study (RDT). Head CT scans done at outside hospitals prior to transfer into the trauma centers were included in this analysis. The review recorded inclusion of specific landmarks. Evaluated landmarks were the orbital roof, nasion, zygomaticofrontal suture, orbital floor, nasal tip, foramen magnum, basion, opisthion, and posterior arch of C1. Using these data, the plane of reconstruction and anatomic coverage were surmised. This was a descriptive study and required no comparative statistical analysis. All demographics and assessments were reported as mean with SD and frequencies with percentages as appropriate.

RESULTS

A total of 322 patients with facial fractures were identified among the five institutions. The average age was 10.8 (SD: 4.9) years, with 206 boys (64%) and 116 girls (36%). The average ISS was 11.2 (SD: 10.7). The mechanisms of injury included motor vehicle crash (23%), falls (17%), and pedestrian accidents (14%)

Table 1 Characteristics of the study sample

	n	%
Patients	322	100
Sex		
Male	206	64
Female	116	36
Mean age (SD) (years)	10.8	4.9
Mean ISS (SD)	11.2	10.7
Mechanism of injury		
MVC	75	23.2
Fall	55	17
Pedestrian struck	46	14.2
Bicycle crash	44	13.6
Assault	13	4
ATV	10	3.1
Sports	8	3.1
Non-accidental trauma	4	1.2
Other	67	21.1
CT scan results	322	
Concordance	287	89.1
Discordance	35	10.9

ATV, All terrain vehicle; ISS, Injury Severity Score; MVC, motor vehicle crash.

(table 1). Of the 322 children with fractures seen on facial CT, 35 (10.9%) had discordant head CT findings. In cases of discordance, the most common missed finding was nasal bone fractures (n=21, 60%), followed by mandibular fractures (n=9, 26%). Of these 35 patients with discordant findings, only 7 patients (20%) required intervention for their fractures (figure 1). The ages of these patients ranged from 2 to 18 years. Six of these seven patients underwent repair of mandible fractures with open reduction and internal fixation. One patient had significant injuries missed on head CT and required surgery due to a fracture of the alveolar plate and associated dental trauma. However, she had obvious dental trauma and intraoral injury on physical examination after being struck by a bicycle handlebar through the roof of the mouth (table 2).

The overall operative intervention rate for facial fractures in the entire cohort was 17% (56 of 322).

In total 50 (15%) of the 322 head CT scans were randomly reviewed for technique. Analysis revealed that four out of five centers used a steep reconstruction plane roughly parallel to the orbital roof. Three of the five centers had near-identical anatomic coverage ending above the C1 arch; the fourth center extended its coverage more inferiorly usually including the C1 arch. Interestingly, all mandibular injuries were detected on head CT at this institution. The fifth center routinely scanned the head and face in the trauma setting and used a reconstruction plane closer to the more horizontal orbitomeatal plane. No facial injuries were missed by head CT at this institution. Interinstitutional disparity in rates of discordance across the institutions is presented in table 3.

In all cases of patients requiring intervention for a facial fracture, the records revealed significant clinical findings on physical examination to suggest a mandibular or dental injury. These included evidence of open fracture, severe mandibular pain and swelling, or an obvious dental injury. One patient with significant mental status changes had a large amount of blood in the oral cavity.

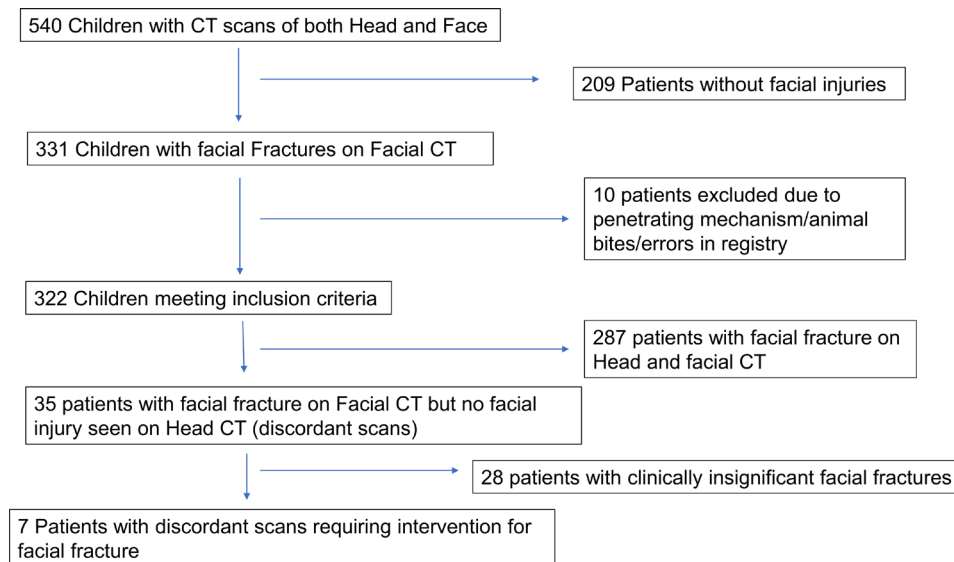


Figure 1 Flow diagram of the cohort.

DISCUSSION

This retrospective review of five trauma centers in New York State finds that head CT is an excellent screening tool for clinically significant facial fractures in pediatric blunt trauma. Even when accounting for variations in CT technique, if no facial fracture is seen on head CT and there is no evidence on examination of a mandibular or dental injury, a facial CT can be avoided safely. If a facial fracture is seen on head CT, facial CT should be strongly considered to better characterize these injuries. This approach will miss recognition of minor nasal fractures. However, these are rarely clinically significant and usually very apparent on examination. In addition, as head CT frequently does not adequately evaluate the mandible and oral cavity, and injuries to the mandible frequently require intervention, clinical evidence of significant dental trauma, malocclusion, mandibular deformity, oral bleeding, or tenderness should prompt additional facial imaging as well.

Many pediatric patients with suspected facial trauma undergo both a head and a facial CT during their emergency department assessment for blunt trauma.⁶⁻⁸ As providers have little in the way of clinical guidelines to help determine which children require dedicated facial imaging, the threshold to obtain facial CT is subject to significant variability between institutions and providers. Given the low incidence of surgically significant facial fractures in pediatric patients,¹ it is important to realize that many identified injuries require no intervention and therefore detection is not critical in all fractures. In our cohort, 83% of patients with facial fractures required no intervention. Of the 35 patients who did not have a facial injury seen on head CT but were identified on dedicated facial CT, 20% required an intervention. This was 2% of the total cohort (7 of 323). Among

these children, all had examination findings in the mandible or oral cavity readily apparent on examination. As a result, we propose a clinical algorithm for facial fracture detection that begins with physical examination of the patient and, if indicated, head CT to screen for significant injury (figure 2). We concede that some facial fractures managed conservatively may require follow-up by a facial surgeon, so in cases where soft tissue injury is significant and the mechanism severe a facial surgeon should be consulted and additional imaging left to their discretion.¹⁰⁻¹⁴

In addition to the previously discussed stochastic effects of radiation to organs such as the thyroid and cervical spine bone marrow leading to potential for malignancy,³ repeated exposures to CT of the head and face in pediatric patients have been associated with increased risk of cataract development.¹⁵ This further underscores the necessity of an evidence-based guideline to determine which children require both a head CT and a facial CT for screening pediatric facial trauma. We have shown through this multi-institutional review that clinical and radiographic predictors can eliminate the need for dedicated facial CT in most cases. Our results are similar to previously published articles on this topic.

In 2018, Ryu *et al*⁷ did an analysis of 156 children under the age of 8 who obtained both head and facial CT scans and found head CT to have 100% specificity and sensitivity in determining the presence of a facial fracture. However, this study was limited by the fact that only 11 (7%) of the cohort actually had a facial fracture. In 2006, Marinaro *et al* conducted a comparable study of 91 children in New Mexico and found that CT of the head was 90% sensitive and 90% specific in identifying non-nasal midface fractures in children.⁶ Similarly, this analysis was limited by the fact that only 55 of these patients had a facial fracture. Finally, the largest pediatric study to date was published in 2017 by Lee *et al*⁸ and was a single-center review of 400 patients under 18 who suffered from trauma and had both head and facial CT scans. Eighty-five of these children had fractures and head CT, with an accuracy of 99% in determining the presence of a facial injury (sensitivity 94.1%–96.5% and specificity 99.7%–100%). In the adult trauma literature, the results are not as compelling. A large study from South Korea of 868 adults with facial fractures found head CT had an accuracy of 94% and a specificity of 99%; however, sensitivity was only 83%.¹⁶ It is important to

Table 2 Description of discordant CTs (n=35)

	n (%), n=35	Operative intervention, n (%)
Injury location		
Orbital	3 (8.6)	0 (0)
Nasal	21 (60)	0 (0)
Maxillary	2 (5.7)	1 (50)
Mandibular	9 (25.7)	6 (66.7)

Table 3 Description of discordant scans and imaging techniques by institution

Center	Total scans	Discordant scans, n (%)	Discordant scans requiring intervention, n (%)	Imaging technique
1	59	15 (25)	5 (8.4)	Steep reconstruction plane roughly parallel to the orbital roof, ending above the C1 arch.
2	53	10 (19)	2 (3.8)	Steep reconstruction plane roughly parallel to the orbital roof, ending above the C1 arch.
3	40	5 (12.5)	0 (0)	Steep reconstruction plane roughly parallel to the orbital roof, ending above the C1 arch.
4	69	5 (7.3)	0 (0)	Steep reconstruction plane roughly parallel to the orbital roof, including the C1 arch.
5	101	0 (0)	0 (0)	The fifth center routinely scanned head and face in the trauma setting and used a reconstruction plane closer to the more horizontal orbitomeatal plane.

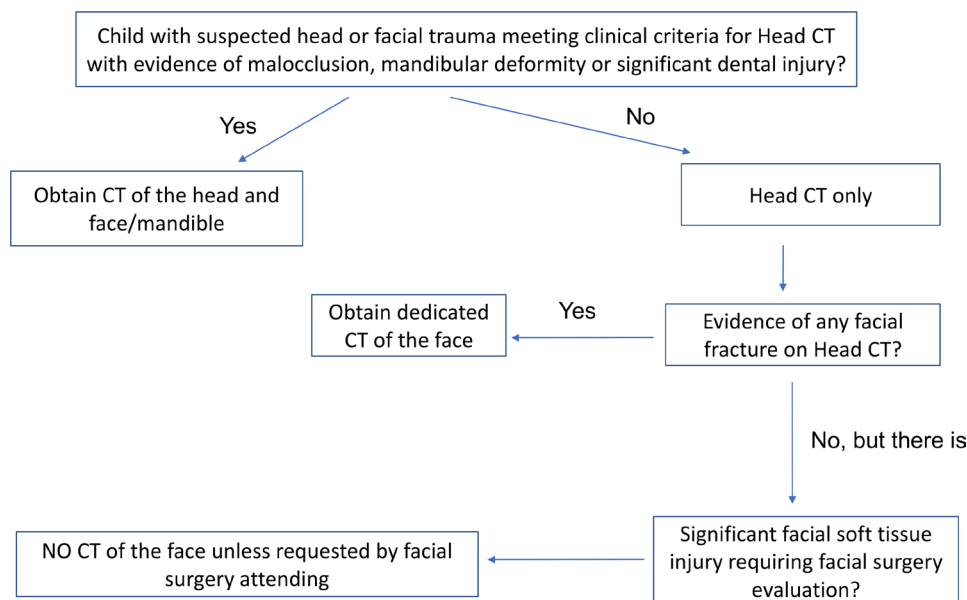
understand that these studies sought to determine the equivalence of head CT to facial CT in recognizing facial injury and were not designed to assess head CT as a screening modality for facial injury. Subsequent studies have clearly shown the superiority of dedicated facial CT in characterizing facial fractures and guiding treatment.^{4,5}

This is the largest study to date assessing the sensitivity of head CT as a screening modality for facial fractures in pediatric blunt trauma; however, unlike other studies, we also did not assess the ability of head CT to adequately characterize all facial fractures, but to act purely as a screening modality to prompt further imaging of the face. We found that head CT identified 89% of children with facial fractures and most of the missed fractures (80%) did not require any intervention. Of the entire cohort, 2% had a clinically significant facial fracture and a head CT that failed to identify significant facial trauma. In all these cases, there were obvious findings on physical examination to prompt evaluation of the mandible or alveolar plate.

These results demonstrate that although head CT is reliable in assessing midface injuries, mouth and mandible injuries can clearly be missed in scanning techniques designed to minimize exposure to the orbits and neck.¹⁵ This is reflected in our cohort, as institutions 1 to 3 employ such a scanning technique. Institution 5, which scanned on a horizontal plane, had superior ability to detect facial fracture on CT of the brain. Similarly, institution

4, which uses a steep reconstruction plane parallel to the orbital roof, but extends the scan lower, was able to detect the mandibular injuries which were missed by other institutions. Although the sensitivity of these approaches in detecting facial injuries is superior, it comes at the expense of increased radiation exposure to the lens of the eye, the thyroid, and bone marrow. Conversely, although the benefit of limiting exposure to radiosensitive organs in children undergoing head CT is clear,^{2,9,15} it comes at the cost of decreasing the ability to detect adjacent facial injuries. In the case of facial fractures, we argue that many of these injuries are either clinically insignificant or readily apparent on clinical examination. In some institutions, depending on the plane of imaging, reconstructions of cervical spine CT scans may also capture the mandible. If this is the case, consideration should be given to reconstruct and review these images as well prior to additional scanning.

Although the strength of this study is in the relatively large number of children with facial injuries and the inclusion of multiple institutions, there are limitations which temper the impact of our findings. First, this is an uncontrolled retrospective review, with the limitations of selection and reporting bias inherent in that methodology. Indications for intervention were not standardized across institutions and therefore subject to disparity. Although American College of Surgeons (ACS)-accredited trauma centers have robust data registries

**Figure 2** Proposed algorithm to direct facial imaging.

with internal and external quality controls, all are subject to reporting error. The trauma registries do not have the ability to capture interventions done after discharge at other facilities or follow-up obtained at other facilities. The cohort of patients studied all had both facial and head CTs performed and therefore we cannot comment on clinical predictors of facial injury in patients who do not undergo head CT as part of their evaluation. We did not include penetrating trauma and animal bites or mauling and therefore cannot make recommendations regarding these injuries either. Finally, the relatively low number of children requiring intervention for injury (17%) also tempers the strength of our conclusions. However, our findings reinforce several other, smaller studies in the USA and in South Korea.

In conclusion, in children with blunt injuries, head CT in combination with clinical examination is an excellent screening tool for clinically significant facial injuries in children. If there is no apparent facial fracture on head CT and no clinical evidence of trauma to the mandible or significant dental injury, further imaging with facial CT can likely be avoided. Although this guideline warrants further controlled prospective study, retrospective evidence to date suggests it is safe and likely to significantly reduce unnecessary radiation exposure to injured children.

Author affiliations

- ¹Department of Surgery, Albany Medical Center, Albany, New York, USA
²Surgery, Albany Medical College, Albany, New York, USA
³Department of Surgery, Ohio State University Foundation, Columbus, Ohio, USA
⁴Department of Surgery, University of Rochester, Rochester, New York, USA
⁵Department of Surgery, Long Island Jewish Medical Center Northwell Health Cancer Institute, New Hyde Park, New York, USA
⁶Department of Surgery, Upstate Golisano Children's Hospital, Syracuse, New York, USA
⁷Trauma Surgery Division, John R Oishei Children's Hospital, Buffalo, New York, USA
⁸Department of Surgery, University at Buffalo, Buffalo, New York, USA
⁹Department of Radiology, Albany Medical Center, Albany, New York, USA
¹⁰Department of Radiology, Long Island Jewish Medical Center Northwell Health Cancer Institute, New Hyde Park, New York, USA
¹¹Department of Radiology, University of Rochester, Rochester, New York, USA
¹²Department of Radiology, University at Buffalo, Buffalo, New York, USA

Acknowledgements Thank you Dr Ashar Ata for assistance in the review of the article.

Contributors Literature search: MJE, BNN, SS, BC. Study design: MJE, DW. Data collection: MJE, BNN, SS, TF, DW, TC, AL, KW. Data analysis: MJE, BNN, SS, TF, DW, TC, AL, KW, RDT, RZ, MC, AN. Data interpretation: MJE, BNN, RDT. Writing: MJE, BNN, SS, BC. Critical review: all authors. Guarantor: MJE

Funding The authors have not declared a specific grant for this research from any funding agency in the public, commercial or not-for-profit sectors.

Competing interests None declared.

Patient consent for publication Not required.

Ethics approval The institutional review boards at all five contributing sites determined this to be an exempt study, permitting sharing of de-identified data at all institutions with the primary research site (Albany Medical Center, Department of Clinical Investigations Study #5580).

Provenance and peer review Not commissioned; externally peer reviewed.

Data availability statement Data are available upon reasonable request. Data were obtained by retrospective chart review and a query of prospectively collected trauma databases from five centers in upstate New York. Data are available by request and can be shared after institutional authorization is obtained.

Open access This is an open access article distributed in accordance with the Creative Commons Attribution Non Commercial (CC BY-NC 4.0) license, which permits others to distribute, remix, adapt, build upon this work non-commercially, and license their derivative works on different terms, provided the original work is properly cited, appropriate credit is given, any changes made indicated, and the use is non-commercial. See: <http://creativecommons.org/licenses/by-nc/4.0/>.

ORCID iD

Mary J Edwards <http://orcid.org/0000-0003-1431-4898>

REFERENCES

- Alcalá-Galiano A, Arribas-García JJ, Martín-Pérez MA, Romance A, Montalvo-Moreno JJ, Juncos JMM. Pediatric facial fractures: children are not just small adults. *Radiographics* 2008;28:441–61.
- Haug RH, Foss J. Maxillofacial injuries in the pediatric patient. *Oral Surgery, Oral Medicine, Oral Pathology, Oral Radiology, and Endodontology* 2000;90:126–34.
- Brenner DJ, Hall EJ. Computed tomography--an increasing source of radiation exposure. *N Engl J Med* 2007;357:2277–84.
- Talwar AA, Heiman AJ, Kotamarti VS, Bommareddy K, Harris ES, Sandberg ML, Patel A, Ricci JA. High-Resolution maxillofacial computed tomography is superior to head computed tomography in determining the operative management of facial fractures. *J Surg Res* 2020;256:381–9.
- Ricci JA, Tran BNN, Ruan QZ, Lin SJ, Singhal D, Lee BT. Comparing head and facial computed tomographic imaging in identifying operative facial fractures. *Ann Plast Surg* 2018;80:S219–22.
- Marinero J, Crandall CS, Doezema D. Computed tomography of the head as a screening examination for facial fractures. *Am J Emerg Med* 2007;25:616–9.
- Ryu J, Yun SJ, Lee SH, Choi YH. Screening of pediatric facial fractures by brain computed tomography: diagnostic performance comparison with facial computed tomography. *Pediatr Emerg Care* 2020;36:125–9.
- Lee SH, Yun SJ, Ryu S, Choi SW, Kim HJ, Kang TK, Oh SC, Cho SJ. Brain computed tomography compared with facial 3-dimensional computed tomography for diagnosis of facial fractures. *J Pediatr* 2017;184:32–7.
- Mueller DL, Hatab M, Al-Senan R, Cohn SM, Corneille MG, Dent DL, Michalek JE, Myers JG, Wolf SE, Stewart RM. Pediatric radiation exposure during the initial evaluation for blunt trauma. *J Trauma* 2011;70:724–31.
- Haug RH, Foss J. Maxillofacial injuries in the pediatric patient. *Oral Surg Oral Med Oral Pathol Oral Radiol Endod* 2000;90:126–34.
- Gelesko S, Markiewicz MR, Bell RB. Responsible and prudent imaging in the diagnosis and management of facial fractures. *Oral Maxillofac Surg Clin North Am* 2013;25:545–60.
- Mukherjee CG, Mukherjee U. Maxillofacial trauma in children. *Int J Clin Pediatr Dent* 2012;5:231–6.
- Imahara SD, Hopper RA, Wang J, Rivara FP, Klein MB. Patterns and outcomes of pediatric facial fractures in the United States: a survey of the National trauma data bank. *J Am Coll Surg* 2008;207:710–6.
- Ryan ML, Thorson CM, Otero CA, Ogilvie MP, Cheung MC, Saigal GM, Thaller SR. Pediatric facial trauma: a review of guidelines for assessment, evaluation, and management in the emergency department. *J Craniofac Surg* 2011;22:1183–9.
- Harbron RW, Ainsbury EA, Barnard SGR, Lee C, McHugh K, Berrington de González A, Edyvean S, Pearce MS. Radiation dose to the lens from CT of the head in young people. *Clin Radiol* 2019;74:816.e9–816.e17.
- Kim DH, Choi YH, Yun SJ, Lee SH. Diagnostic performance of brain computed tomography to detect facial bone fractures. *Clin Exp Emerg Med* 2018;5:107–12.