



Since January 2020 Elsevier has created a COVID-19 resource centre with free information in English and Mandarin on the novel coronavirus COVID-19. The COVID-19 resource centre is hosted on Elsevier Connect, the company's public news and information website.

Elsevier hereby grants permission to make all its COVID-19-related research that is available on the COVID-19 resource centre - including this research content - immediately available in PubMed Central and other publicly funded repositories, such as the WHO COVID database with rights for unrestricted research re-use and analyses in any form or by any means with acknowledgement of the original source. These permissions are granted for free by Elsevier for as long as the COVID-19 resource centre remains active.

Factors associated with positive thrombus findings at ultrasonography in COVID-19 ward patients who underwent imaging for suspected deep vein thrombosis under prophylactic anticoagulation

Abdulkerim Özhan, MD,^a and Murat Bastopcu, MD,^b *Kütahya and Bitlis, Turkey*

ABSTRACT

Objective: The incidence of deep vein thrombosis (DVT) is increased in patients with coronavirus disease 2019 (COVID-19) and its presence is associated with worse outcomes. Ultrasound examination of patients with COVID-19 with a suspected DVT is challenging owing to concerns with disease transmission; the timely initiation of therapeutic anticoagulation is essential. This study aimed to identify patient factors associated with positive thrombus findings at ultrasound examination in patients with COVID-19 who underwent imaging for suspected DVT.

Methods: Patients who did not require intensive care unit treatment and who underwent ultrasound imaging for suspected DVT between March and December 2020 were included retrospectively. Patient demographics, comorbidities, modified Well's score, and D-dimer results on the day of ultrasound examination were recorded. Parameters for a higher likelihood of a positive DVT result were determined by comparing patients with confirmed DVT on ultrasound examination and patients with negative ultrasound findings. To determine a cut-off for D-dimer levels, a receiver operating characteristic curve was constructed. The sensitivity and specificity of the determined high-risk factors in the prediction of positive ultrasound results were calculated.

Results: A positive history for DVT (25% vs 4%; $P < .001$), thrombophilia (9% vs 2%; $P = .048$), immobilization (53% vs 23%; $P = .001$), and a Well's score ≥ 2 (50% vs 21%; $P = .001$) were more frequent in patients with DVT. The mean D-dimer levels were higher in patients with DVT (3871 ± 1805 vs 2075 ± 1543 ; $P < .001$). The presence of either thrombophilia or a D-dimer level of >2020 had a sensitivity of 93% and a specificity of 64%. The presence of either thrombophilia, a D-dimer level of >2020 , or a Well's score of ≥ 2 had a sensitivity of 100% and a specificity of 51%.

Conclusions: Patients with COVID-19 with a D-dimer of >2020 , a positive history for thrombophilia, and a Well's score of ≥ 2 should undergo a timely ultrasound examination. The high risk of DVT should be remembered for all hospitalized patients with COVID-19. (*J Vasc Surg Venous Lymphat Disord* 2022;10:811-7.)

Keywords: COVID-19; Deep vein thrombosis; Doppler ultrasound

The novel coronavirus disease 2019 (COVID-19) can cause severe respiratory disease and is associated with significant morbidity in cases that require hospitalization. It is well-established that the incidence of venous thromboembolism (VTE) is increased in patients with COVID-19. Early in the pandemic, prophylactic anticoagulation was recommended for all patients with COVID-19 without increased risk of bleeding. Despite prophylactic treatment, deep vein thrombosis (DVT) is encountered frequently and impacts the course of the disease.¹ In severe disease, VTE is markedly increased, with an incidence exceeding 20% in intensive care unit (ICU) patients.^{2,3} Reports from patients from general wards

have also shown frequent VTE. Among non-ICU patients, incidences between 12% and 26% were reported in screening studies, with most cases being asymptomatic.⁴⁻⁶ Prophylactic anticoagulation does not completely preclude VTE events in ward patients.⁷ With this high incidence among COVID-19 cases, clinical suspicion of VTE should be kept in mind for all hospitalized patients.

The initial workup for suspected DVT includes a detailed anamnesis, careful evaluation of the extremities, and D-dimer testing.⁸ The value of classical scoring methods may be less helpful in the setting of COVID-19 wards. Normal D-dimer levels help to exclude DVT; however, its levels are increased in the early stages of the

From the Department of Cardiovascular Surgery, Kütahya Health Sciences University, Evliya Celebi Training and Research Hospital, Kütahya^a; and the Department of Cardiovascular Surgery, Tatvan State Hospital, Bitlis.^b

Author conflict of interest: none.

Correspondence: Abdulkerim Özhan, MD, Kutahya Health Sciences University, Evliya Celebi Training and Research Hospital, 43270, Kutahya, Turkey (e-mail: draozhan@gmail.com).

The editors and reviewers of this article have no relevant financial relationships to disclose per the Journal policy that requires reviewers to decline review of any manuscript for which they may have a conflict of interest.

2213-333X

Copyright © 2022 by the Society for Vascular Surgery. Published by Elsevier Inc.

<https://doi.org/10.1016/j.jvsv.2022.02.012>

COVID-19 infection. Higher D-dimer levels indicate a more severe infection and are also prognostic for patients with COVID-19.⁹ Because of the hyperinflammatory environment resulting in high D-dimer levels, higher cut-offs may guide the physician for the diagnosis of VTE.

Owing to concerns with transmission and equipment cleanliness, clinicians may hesitate to rapidly perform an ultrasound examination when DVT is suspected. The proper use of ultrasound devices and personnel can ensure the optimal treatment of patients with COVID-19 while minimizing the risk for medical personnel. There is no current guideline on the timing of ultrasound imaging for patients with COVID-19 with suspected DVT and institutional protocols may vary. With an awareness of the substantial risk in patients with COVID-19, clinicians are vigilant for the signs of DVT. Imaging studies are ordered for all suspected cases because there are no globally accepted guidelines on the timing of ultrasound for DVT in COVID-19. This factor may cause increased transmission of the virus, and the prudent use of imaging facilities may be necessary in centers that treat patients with and without COVID-19.

The aim of this study was to identify the parameters associated with positive findings of venous thrombus in COVID-19 ward patients who underwent ultrasound imaging for suspected DVT.

METHODS

This study was performed in a single referral center that treated patients with COVID-19. Patients who did not require ICU treatment and who underwent ultrasound imaging for suspected DVT between March and December 2020 were included retrospectively. Approval was obtained from the institutional ethics board for this study and the study was conducted in accordance with the Declaration of Helsinki. Individual patient consent was waived owing to the retrospective nature of the study.

The national guidelines set forth by the Ministry of Health for the diagnosis and treatment of COVID-19 were followed. The diagnosis of COVID-19 was made with symptoms of fever, cough, dyspnea, musculoskeletal pain, or other flu-like symptoms together with a positive reverse-transcriptase polymerase chain reaction test or radiological findings of COVID-19 pneumonia. The national guideline categorizes patients according to their severity. Mild cases with symptoms of fever, cough, throat ache, and musculoskeletal pain, but without dyspnea (respiratory rate of $<24/\text{min}$, SpO_2 of $>93\%$) or radiological findings of COVID-19 pneumonia are recommended for home treatment with isolation and close follow-up. A moderate COVID-19 infection is diagnosed with dyspnea (respiratory rate of $<30/\text{min}$, SpO_2 of $>90\%$) and radiological findings of COVID-19 pneumonia. Cases with moderate infection are hospitalized per the national guideline. The diagnosis of severe pneumonia is made

ARTICLE HIGHLIGHTS

- **Type of Research:** Single-center retrospective cohort study
- **Key Findings:** Selection of patients with D-dimer of >2020 , a positive history for thrombophilia, and a Well's score of ≥ 2 for urgent ultrasound examination was associated with a sensitivity of 100% and a specificity of 51% among 168 patients with coronavirus disease 2019 with suspected deep vein thrombosis.
- **Take Home Message:** Selecting high-risk patients with coronavirus disease 2019 with suspected deep vein thrombosis for urgent ultrasound examination is associated with high sensitivity while minimizing health worker exposure.

when tachypnea (respiratory rate of >30) or hypoxia (SpO_2 of $\leq 90\%$) existed together with radiological findings of COVID-19 pneumonia and warrants ICU admission. Patients with accompanying hypotension, acute kidney injury, acute liver dysfunction, confusion, immunosuppression, or other acute organ dysfunctions are also admitted to the ICU.¹⁰

The standard treatment for COVID-19 infection included favipiravir and intravenous methylprednisolone for hospitalized patients. Our institutional protocol was to administer DVT prophylaxis to all hospitalized patients with COVID-19, including leg elevation and a single dose of low-molecular-weight heparin, unless active bleeding was demonstrated. Sequential compression, TED hose, or other compression stockings were not used for prophylaxis. Patients with improving symptoms and elevated D-dimer levels at the time of discharge were continued on prophylactic anticoagulation with single dose daily enoxaparin for 1 month if no contraindications were present. Patients with VTE were continued their anticoagulation for 6 months. At admission, D-dimer was measured for all patients. In case of suspected VTE, D-dimer measurements were repeated before ordering an ultrasound study. An ultrasound study was ordered when patients had at least one of the following: calf or whole leg swelling compared with the contralateral leg, new-onset tenderness, or pain in the lower extremity. Patient demographics, comorbidities, the modified Well's score, and D-dimer results on the day of ultrasound examination were recorded.

Parameters for a higher likelihood of a positive DVT result were determined by comparing patients with confirmed DVT at ultrasound examination and patients with negative ultrasound findings. A history of a previous DVT was declared by the patient or confirmed with hospital records, when available. Thrombophilia was defined as a known coagulation abnormality (antithrombin III, protein C or S deficiency, factor V Leiden mutation, or other known diseases with abnormal clotting) declared

Table I. Comparison of patients with and without deep vein thrombosis (DVT) on ultrasound examination

	No DVT (n = 132)	DVT (n = 32)	P value
Age	62 ± 16	63 ± 22	.253
Female gender	60 (44%)	11 (34%)	.315
DM	73 (54%)	9 (28%)	.009
Hypertension	87 (64%)	17 (53%)	.256
Chronic pulmonary disease	58 (43%)	10 (31%)	.237
Coronary artery disease	36 (27%)	4 (13%)	.095
Chronic heart failure	24 (18%)	4 (13%)	.482
Chronic renal disease	30 (22%)	2 (6%)	.040
History of DVT	5 (4%)	8 (25%)	<.001
Venous insufficiency	10 (7%)	2 (6%)	.827
Thrombophilia	2 (2%)	3 (9%)	.048
Immobilization	32 (24%)	17 (53%)	.001
Active malignancy	21 (15%)	8 (25%)	.198
Recent surgery	24 (18%)	4 (13%)	.482
Pregnancy	6 (4%)	0 (0%)	.596
Well's score ≥ 2	28 (21%)	16 (50%)	.001
D-Dimer	2075 ± 1543	3871 ± 1805	<.001

DM, Diabetes mellitus.
Boldface entries indicate statistical significance.

by the patient or present in the hospital records. Immobilization was defined as being bedridden for >3 days owing to current COVID-19 disease or previous trauma, neurological disorder, surgery, or other diseases. Recent surgery was defined as any surgery with regional or general anesthesia within the previous 3 months.

Statistical analysis. Statistical analysis was carried out using IBM SPSS Statistics 22 software (Armonk, NY). Nominal variables are presented as numbers and percentages while continuous variables are presented as mean and standard deviation. For group comparison, the χ^2 test or Fisher's exact test was applied for nominal variables, the Student *t* test for continuous variables with normal distribution, and the Mann-Whitney *U* test for continuous variables without a normal distribution. Different multivariate models were created with factors

significantly associated with positive ultrasound findings at univariate analysis. A receiver operating characteristic curve was constructed for the diagnostic ability of D-dimer in predicting DVT. Youden's index was used to determine the cut-off for D-dimer in discriminating positive findings at ultrasound examination. Significance was set at a *P* value of <.05.

RESULTS

During the study period, 945 patients were treated outside of the ICU setting; 168 (18%) were suspected of DVT and were included in the study. The mean age of the study patients was 63 ± 18 years and 71 (42%) were female. Of these patients who were ordered an ultrasound examination, 32 (19%) were diagnosed with DVT, with an overall incidence of 3% among general ward patients.

Table II. Multivariate analysis of patient factors with prior deep vein thrombosis (DVT) and immobilization included in the model

	P value	OR (95% CI)
DM	.073	0.36 (0.12-1.10)
Chronic renal disease	.056	0.19 (0.03-1.04)
Prior DVT	.081	5.82 (0.80-42.09)
Thrombophilia	.007	30.78 (2.58-366.65)
Immobilization	.071	2.72 (0.92-8.06)
D-Dimer (each 10-unit increase)	<.001	1.01 (1.01-1.01)

CI, Confidence interval; DM, diabetes mellitus; OR, odds ratio.
Boldface entries indicate statistical significance.

Table III. Multivariate analysis of patient factors with Well's score included in the model

	<i>P</i> value	OR (95% CI)
DM	.029	0.28 (0.09-0.88)
Chronic renal disease	.073	0.21 (0.04-1.16)
Thrombophilia	.008	28.41 (2.36-342.62)
Well's Score ≥ 2	.014	4.01 (1.33-12.14)
D-Dimer (each 10-unit increase)	<.001	1.01 (1.01-1.01)

CI, Confidence interval; *DM*, diabetes mellitus; *OR*, odds ratio.
Boldface entries indicate statistical significance.

Patients with DVT were compared against patients without DVT for demographic properties, clinical findings, and D-dimer results (Table I). Patients with DVT less frequently had diabetes mellitus (DM) (28% vs 54%; $P = .009$) or chronic renal disease (6% vs 2%; $P = .040$). A positive history for DVT (25% vs 4%; $P < .001$), thrombophilia (9% vs 2%; $P = .048$), immobilization (53% vs 24%; $P = .001$), and a Well's score of ≥ 2 (50% vs 21%; $P = .001$) were more frequent in patients with DVT. The mean D-dimer levels were higher in patients with DVT (3871 ± 1805 vs 2075 ± 1543 ; $P < .001$).

A positive history for DVT, thrombophilia, immobilization, a Well's score of ≥ 2 , and elevated D-dimer were carried onto multivariate analysis. Because immobilization is a criterion in the Well's scoring system, two multivariate models were constructed separately with immobilization and Well's score of ≥ 2 . In the first model, multifactorial analysis revealed thrombophilia and high D-dimer to be independently associated with positive DVT at ultrasound examination. The odds ratio was 31

for thrombophilia, and 1 for each 10-unit increase in D-dimer (Table II). In the second model, thrombophilia, a high Well's score, and a high D-dimer were associated with DVT; DM was negatively associated with DVT. The odds ratio was 28 for thrombophilia, 1 for each 10-unit increase in D-dimer, and 4 for a Well's score of ≥ 2 (Table III).

To determine a cut-off for the D-dimer levels, a receiver operating characteristic curve was constructed. Using the Youden's index, a D-dimer of 2020 had a sensitivity of 89% and 66% specificity with an area under curve of 0.789 (Fig). The diagnostic ability of high-risk factors in selecting patients for an early ultrasound examination was investigated. The presence of either thrombophilia or a D-dimer of >2020 had a sensitivity of 93% and a specificity of 64% (Table IV). The presence of either thrombophilia, a D-dimer of >2020 , or a Well's score of ≥ 2 had a sensitivity of 100% and a specificity of 51% (Table V).

DISCUSSION

In patients with a D-dimer of >2020 , thrombophilia, or a Well's score of ≥ 2 , there is a high likelihood of positive results with Doppler when DVT is suspected. The selection of patients for a timely ultrasound examination using these factors may ensure an accurate diagnosis and minimization of disease transmission.

Ultrasound imaging has additional challenges in patients with COVID-19 whose transfer to the imaging units may cause additional transmission and additional risks to the hypoxic patient. Point-of-care ultrasound examination may be necessary, with additional risks for the physician. The patient-to-patient and patient-to-clinician transmission risk may defer a timely ultrasound examination. Our findings do not preclude an imaging study for the definitive diagnosis of DVT in any patients with COVID-19, but can serve as a guide to which patients should be assessed urgently with imaging studies. Although all patients with suspected DVT will have an ultrasound examination ordered, our results may be used to plan institutional protocols in prioritizing ultrasound studies. Patients who are less likely to be positive may be assessed, allowing time for precautions against disease transmission.

Prospective studies with established protocols for DVT imaging are warranted to assess the benefits of patient

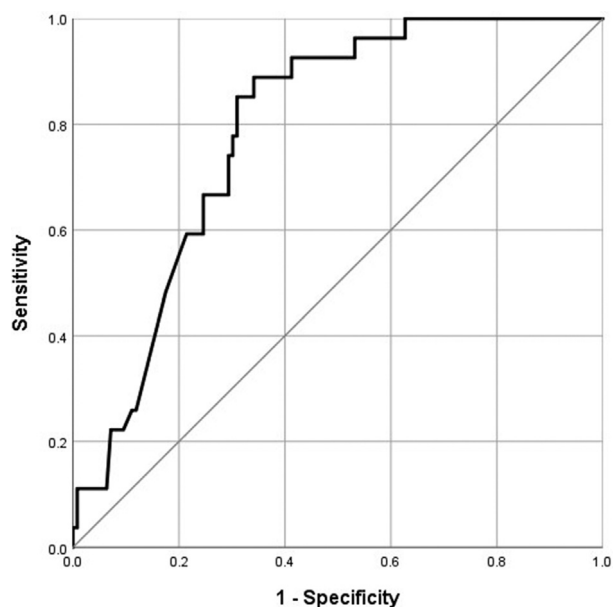
**Fig.** Receiver operating characteristic curve for D-dimer and positive ultrasound results.

Table IV. Diagnostic ability of either thrombophilia or high D-dimer

	No DVT	DVT	P value
Low risk	81 (64)	2 (7)	<.001
High risk	45 (36)	25 (93)	

Boldface entries indicate statistical significance. Values are number (%).

selection and the risk of forgoing imaging in low risk patients. A single-center study evaluated the effectiveness of an algorithm that includes a D-dimer of >4000, swelling, and/or pain in the extremity, with three other parameters for pulmonary embolism (persistent unexplained fever, new-onset hypoxia, late dead space fraction).¹¹ Their algorithm resulted in a 72% decrease in the number of ultrasound examinations ordered, with therapeutic anticoagulation started on patients whose ultrasound examinations were deferred. In their cohort, a serum D-dimer level of >4000 ng/mL had a sensitivity and specificity of 80% and 70% for DVT, respectively.

COVID-19 is characterized by an inflammatory activation that activates the coagulation cascades in the patient.^{12,13} Being an acute phase reactant, D-dimer levels are elevated both by the acquired thrombotic state and the proinflammatory environment. The elevation in D-dimer is associated with severity of COVID-19 disease, mortality, and VTE.¹⁴ For patients not requiring ICU-level care, higher D-dimer levels were demonstrated in patients with DVT.¹⁵ In parallel, more patients with DVT required transfer to the ICU.^{15,16}

Our clinical protocol per our national guideline is to start all hospitalized patients without contraindications on prophylactic anticoagulation. The prothrombotic pathways in COVID-19 disease are being evidenced and there is a remarkable risk of VTE in these patients compared with other viral infections. These patients can severely deteriorate owing to a sudden VTE event. Therefore, the risks of additional anticoagulation are outweighed by the benefits of avoiding limb and pulmonary complications.^{13,17} The detection and due treatment of DVT is important to decrease mortality and complications. In these patients, if ultrasound examination is delayed, switching to full-dose treatment from prophylactic doses can be considered weighing the individual

Table V. Diagnostic ability of either thrombophilia, high D-dimer, and a Well's score of ≥ 2

	No DVT	DVT	P value
Low risk	64 (51)	0 (0)	<.001
High risk	62 (49)	27 (100)	

DVT, Deep vein thrombosis. Boldface entries indicate statistical significance. Values are number (%).

risk for bleeding. Patients with high-risk factors defined by institutional protocols can be given higher prophylactic doses until imaging or full-dose anticoagulation if imaging is not feasible.¹⁸

Well's criteria were developed to identify outpatients at risk of VTE prior to a ultrasound examination. The Well's score has low discriminatory accuracy for inpatients¹⁹ and its applicability to patients with COVID-19 has not been robustly studied. In our cohort of patients with COVID-19, 20% of patients with a high Well's scores did not have DVT on ultrasound examination and these patients contributed to disease transmission risk. The modified Well's score categorizes patients into two groups.²⁰ It is reasonable to consider any hospitalized COVID-19 patient with associated symptoms as high risk owing to their immobility and bed confinement.²¹ We had a low threshold for DVT suspicion and performed an ultrasound examination when the Well's score was ≥ 1 . A Wells score of ≥ 2 was associated with a greater likelihood of positive ultrasound results. In previous reports that included ICU patients, Well's score was not a predictor of DVT, possibly owing to the prevalent high Wells scores on many ICU patients regardless of DVT symptoms.²²

The D-dimer level is used in DVT diagnosis, but higher cut-offs are more relevant in COVID-19-associated DVT. The D-dimer levels have been used to guide thromboprophylaxis in COVID-19.²³ In one study that screened all non-ICU patients with COVID-19 with a D-dimer of >1000 ng/mL using Doppler ultrasound examination, a D-dimer of >1570 was associated with the best discriminative capacity.²⁴ In another study, a D-dimer of >3000 had a positive predictive value of 67%.¹⁵ In other studies that included both ICU and non-ICU patients, cut-offs at 2000 mg/dL and 6494 mg/dL had the best discriminatory ability.^{22,25} IL-6 levels may be better correlated with the inflammatory response and have better discriminatory properties.²⁶ It is not, however, part of the routine workup and may not be possible to measure outside of clinical studies, so its effectiveness at the bedside setting may be limited.

In their study on all ICU and non-ICU patients screened with ultrasound examination, Zhang et al²⁷ reached the recommendation to perform an ultrasound examination on patients with a CURB-65 score of ≥ 3 , a Padua prediction score of ≥ 4 , and a D-dimer of >1000 ng/mL. The combination of these three findings had a sensitivity of 89% and a specificity of 61% for DVT in hospitalized patients.²⁷ The Padua prediction score was not collected for our patients, but includes known thrombophilic conditions as a criterion, and several other criteria overlap with the Well's score. The CURB-65 score may signify the severity of immune response with the increased severity of pneumonia, which may be more relevant in cohorts that include ICU patients.

Patients with DVT in our study had less DM and chronic renal disease than what has previously been reported.

Comorbidities of advancing age, hypertension, DM, chronic kidney disease, and malignancy increase the risk of DVT during COVID-19 treatment.^{9,15} This finding is likely due to our exclusion of ICU patients. Patients with these comorbidities are more prone to require treatment in the ICU. In the study by Cho et al,²² patients with DM less frequently had DVT, but both our and their study was single-center in design and selection bias cannot be excluded.

Our study is limited by its retrospective, single-center design and its inherent limitations. Another limitation is that the level of DVT in our patients was not recorded. Other inflammatory markers such as C-reactive protein or IL-6 were not available for our patients. All patients received anticoagulation, which may make comparisons with other cohorts where the selective use of anticoagulation is implemented difficult. All patients are questioned for known thrombophilia, but patients were not tested for the levels of coagulation parameters and some patients may be unaware of their condition. Our study was not designed to screen for all DVTs in COVID-19 ward patients and some patients may have had silent asymptomatic venous thrombi that became clinically evident after discharge from the hospital. Our study included patients with moderate infection treated in the ward setting and cannot be applied directly to other patients populations, such as those with severe infection treated in the ICU. Because of these limitations and the different comorbidities that may be present in patients hospitalized in different institutions, our results need to be externally validated by studies in other centers.

CONCLUSIONS

All patients hospitalized with COVID-19 carry a substantial DVT risk. Patients with COVID-19 with a D-dimer of >2020, a positive history for thrombophilia, and a Well's score of ≥ 2 should undergo a timely ultrasound examination. The high risk of DVT should be remembered for all hospitalized patients with COVID-19.

AUTHOR CONTRIBUTIONS

Conception and design: AO, MB
 Analysis and interpretation: AO, MB
 Data collection: AO
 Writing the article: AO, MB
 Critical revision of the article: AO, MB
 Final approval of the article: AO, MB
 Statistical analysis: MB
 Obtained funding: Not applicable
 Overall responsibility: AO

REFERENCES

- Middeldorp S, Coppens M, van Haaps TF, Foppen M, Vlaar AP, Müller MCA, et al. Incidence of venous thromboembolism in hospitalized patients with COVID-19. *J Thromb Haemost* 2020;18:1995-2002.

- Suh YJ, Hong H, Ohana M, Bompard F, Revel M-P, Valle C, et al. Pulmonary embolism and deep vein thrombosis in COVID-19: a systematic review and meta-analysis. *Radiology* 2021;298:E70-80.
- Di Minno A, Ambrosino P, Calcaterra I, Di Minno MND. COVID-19 and venous thromboembolism: a meta-analysis of literature studies. *Semin Thromb Hemost* 2020;46:763-71.
- Santoliquido A, Porfida A, Nesci A, De Matteis G, Marrone G, Porceddu E, et al. Incidence of deep vein thrombosis among non-ICU patients hospitalized for COVID-19 despite pharmacological thromboprophylaxis. *J Thromb Haemost* 2020;18:2358-63.
- Ierardi AM, Gaibazzi N, Tuttolomondo D, Fusco S, La Mura V, Peyvandi F, et al. Deep vein thrombosis in COVID-19 patients in general wards: prevalence and association with clinical and laboratory variables. *Radiol Med* 2021;126:722-8.
- Trimaille A, Curtiaud A, Marchandot B, Matsushita K, Sato C, Leonard-Lorant I, et al. Venous thromboembolism in non-critically ill patients with COVID-19 infection. *Thromb Res* 2020;193:166-9.
- Jimenez-Guiu X, Huici-Sánchez M, Rmiera-Villegas A, Izquierdo-Miranda A, Sancho-Cerro A, Vila-Coll R. Deep vein thrombosis in noncritically ill patients with coronavirus disease 2019 pneumonia: deep vein thrombosis in nonintensive care unit patients. *J Vasc Surg Venous Lymphat Disord* 2021;9:592-6.
- Kakkos SK, Gohel M, Baekgaard N, Bauersachs R, Bellmunt-Montoya S, Black SA, et al. Editor's choice - European Society for Vascular Surgery (ESVS) 2021 Clinical Practice Guidelines on the Management of Venous Thrombosis. *Eur J Vasc Endovasc Surg* 2021;61:9-82.
- Eljilany I, Elzouki A-N. D-Dimer, fibrinogen, and IL-6 in COVID-19 patients with suspected venous thromboembolism: a narrative review. *Vasc Health Risk Manag* 2020;16:455-62.
- The National Scientific Advisory Board of the Ministry of Health. Covid-19 (SARS-CoV-2 infection) treatment of adult patients (in Turkish). Ankara, Turkey; 2021. 1-22 p. Available at: <https://covid19.saglik.gov.tr/Eklenti/42578/0/covid-19rehberieriskinhastayonetimivet edavi-12022022pdf.pdf>. Accessed March 4, 2022.
- Dua A, Thondapu V, Rosovsky R, Hunt D, Latz C, Waller HD, et al. Deep vein thrombosis protocol optimization to minimize healthcare worker exposure in coronavirus disease-2019. *J Vasc Surg Venous Lymphat Disord* 2021;9:299-306.
- Ranucci M, Ballotta A, Di Dedda U, Baryshnikova E, Dei Poli M, Resta M, et al. The procoagulant pattern of patients with COVID-19 acute respiratory distress syndrome. *J Thromb Haemost* 2020;18:1747-51.
- Schulman S, Hu Y, Konstantinides S. Venous thromboembolism in COVID-19. *Thromb Haemost* 2020;120:1642-53.
- Naymagon L, Zubizarreta N, Feld J, van Gerwen M, Alsen M, Thibaud S, et al. Admission D-dimer levels, D-dimer trends, and outcomes in COVID-19. *Thromb Res* 2020;196:99-105.
- Artifoni M, Danic G, Gautier C, Gicquel P, Boutoille D, Raffi F, et al. Systematic assessment of venous thromboembolism in COVID-19 patients receiving thromboprophylaxis: incidence and role of D-dimer as predictive factors. *J Thromb Thrombolysis* 2020;50:211-6.
- Cai C, Guo Y, You Y, Hu K, Cai F, Xie M, et al. Deep venous thrombosis in COVID-19 patients: a cohort analysis. *Clin Appl Thromb* 2020;26:107602962098266.
- Dobesh PP, Trujillo TC. Coagulopathy, venous thromboembolism, and anticoagulation in patients with COVID-19. *Pharmacother J Hum Pharmacol Drug Ther* 2020;40:1130-51.
- Aryal MR, Gosain R, Donato A, Pathak R, Bhatt VR, Katel A, et al. Venous thromboembolism in COVID-19: towards an ideal approach to thromboprophylaxis, screening, and treatment. *Curr Cardiol Rep* 2020;22:52.
- Chopard R, Albertsen IE, Piazza G. Diagnosis and treatment of lower extremity venous thromboembolism. *JAMA* 2020;324:1765.
- Wells PS, Anderson DR, Rodger M, Forgie M, Kearon C, Dreyer J, et al. Evaluation of D-dimer in the diagnosis of suspected deep-vein thrombosis. *N Engl J Med* 2003;349:1227-35.
- Sebuhyan M, Mirailles R, Crichi B, Frere C, Bonnin P, Bergeron-Lafaurie A, et al. How to screen and diagnose deep venous thrombosis (DVT) in patients hospitalized for or suspected of COVID-19 infection, outside the intensive care units. *J Méd Vasc* 2020;45:334-43.
- Cho ES, McClelland PH, Cheng O, Kim Y, Hu J, Zenilman ME, et al. Utility of d-dimer for diagnosis of deep vein thrombosis in

- coronavirus disease-19 infection. *J Vasc Surg Venous Lymphat Disord* 2021;9:47-53.
23. Stawiarski K, Loutoo A, Velardi L, Zarich S. D-dimer driven deep vein thrombosis prophylaxis strategy for hospitalized patients with COVID-19. *Thromb Res* 2021;201:151-3.
 24. Demelo-Rodríguez P, Cervilla-Muñoz E, Ordieres-Ortega L, Parra-Virto A, Toledano-Macías M, Toledo-Samaniego N, et al. Incidence of asymptomatic deep vein thrombosis in patients with COVID-19 pneumonia and elevated D-dimer levels. *Thromb Res* 2020;192: 23-6.
 25. Pieralli F, Pomerio F, Giampieri M, Marcucci R, Prisco D, Luise F, et al. Incidence of deep vein thrombosis through an ultrasound surveillance protocol in patients with COVID-19 pneumonia in non-ICU setting: a multicenter prospective study. *PLoS One* 2021;16: e0251966.
 26. Ierardi AM, Coppola A, Fusco S, Stellato E, Aliberti S, Andrisani MC, et al. Early detection of deep vein thrombosis in patients with coronavirus disease 2019: who to screen and who not to with Doppler ultrasound? *J Ultrasound* 2021;24:165-73.
 27. Zhang L, Feng X, Zhang D, Jiang C, Mei H, Wang J, et al. Deep vein thrombosis in hospitalized patients with COVID-19 in Wuhan, China: prevalence, risk factors, and outcome. *Circulation* 2020;142:114-28.

Submitted Sep 3, 2021; accepted Feb 14, 2022.