



## Case Report

## Reverse shoulder megaprosthesis replacement for aggressive aneurysm bone cyst of proximal humerus: Case report and literature review

Manh Nguyen Huu<sup>a,b</sup>, Dung Trung Tran<sup>a,b,\*</sup>, Viet Vu Duc<sup>a,b</sup>, Quyet Tran<sup>a,b</sup>,  
Quang Minh Dang<sup>a,b</sup>, Thanh Duc Tran<sup>a,b</sup>, Sang Quang Tran Nguyen<sup>a,b</sup>, Cong Van Tran<sup>b</sup>

<sup>a</sup> Department of Orthopaedic Surgery, College of Health Science, VinUniversity, Hanoi, Viet Nam

<sup>b</sup> Orthopaedic and Sports Medicine Center, Vinmec Healthcare System, Hanoi, Viet Nam

## ARTICLE INFO

## Keywords:

Reverse shoulder  
Megaprosthesis  
Aneurysm bone cyst  
Case report  
Proximal humerus

## ABSTRACT

**Introduction:** and importance: Wide resection in the surgical treatment of aneurysms bone cysts is often performed in cases where the tumor is large, recurrent, growing, and intensely invasive. Reshaping the defect after tumor removal is a necessary issue to restore shape and maintain function for the patient.

**Case presentation:** A 26-year-old male patient, diagnosed with an aneurysm bone cyst in the proximal humerus, underwent surgery for curettage and bone grafting twice. After surgery, there was still pain in the shoulder area, the tumor progressed aggressively with limited shoulder movement. Based on the imaging re-evaluation, it was shown that the tumor increased rapidly in size, invaded the soft tissue, and completely changed the normal structure of the shoulder joint, and the proximal humerus. We used a reverse shoulder joint with an additional module to restore the bone defect of the tumor and the function of the shoulder joint. Follow-up showed that patient no longer pain in shoulder area, shoulder joint function recovery is progressing well, Musculoskeletal Tumor Society (MSTS) score is 25 & 28, shoulder joint function score according to ASES scale: 80 & 93.33 respectively at 3 months and 6 months after surgery.

**Clinical discussion:** Aggressive aneurysm bone cyst of proximal humerus is not common and still a challenge to the treatment. Due to the bone and joint destruction, the indication of tumor resection and reconstruct the joint and bone loss is required. Among several solution, reverse shoulder megaprosthesis is a newest one can favor the purpose of our treatment. Up to now, this solution is mainly used to preserving for malignant bone tumor.

**Conclusions:** Tumor wide resection with modular reverse shoulder replacement with the modular segment is a reasonable intervention option in cases of large aneurysm bone cysts, with rapid recurrence, aggressive progression, and soft tissue invasion.

## 1. Introduction

Aneurysmal bone cyst is a rare, non-malignant vascular lesion that accounts for about 1% of all primary osseous tumors [1]. This lesion was first described in 1942 as characterized by local destruction of bone structure with blood-filled septa in the bone [2,3]. Occasionally, this lesion can be aggressive and rapidly transform like a malignant bone lesion but has no metastases and, therefore, is not considered a true cancer [4]. This lesion is common among young patients, frequently found in the long bones, particularly the proximal humerus, the distal

femur, and the superior tibia, which could lead to deformity during bone growth, causing loss of limb function [5–8]. Current treatments include Ethhiboc sclerotherapy, arterial embolization, tumor curettage/resection with or without bone graft, wide resection of the tumor, and proximal humerus reconstruction. Indications for tumor curettage are often applied to small tumors, as with large tumors, it can increase the risk of postoperative fracture with the recurrence rate of up to 30–40% [9,10].

For large aneurysm bone cysts in the proximal humerus, treatment options following wide resection of the tumor-bearing bone include

\* Corresponding author., Center of Orthopaedic and Sport Medicine, Vinmec Hospital, 458 Minh Khai, Khu đô thị; Times City, Hai Bà Trưng, Hà Nội, Viet Nam  
E-mail addresses: [v.manhnh8@vinmec.com](mailto:v.manhnh8@vinmec.com) (M. Nguyen Huu), [dungbacsy@vinmec.com](mailto:dungbacsy@vinmec.com), [dung.tt@vinuni.edu.vn](mailto:dung.tt@vinuni.edu.vn) (D. Trung Tran), [v.vietvd@vinmec.com](mailto:v.vietvd@vinmec.com) (V. Vu Duc), [v.quyet@vinmec.com](mailto:v.quyet@vinmec.com) (Q. Tran), [v.quangdm2@vinmec.com](mailto:v.quangdm2@vinmec.com) (Q.M. Dang), [v.thanhtd26@vinmec.com](mailto:v.thanhtd26@vinmec.com) (T.D. Tran), [v.sangntq@vinmec.com](mailto:v.sangntq@vinmec.com) (S.Q. Tran Nguyen), [v.congtv3@vinmec.com](mailto:v.congtv3@vinmec.com) (C. Van Tran).

URL: <http://www.dungbacsy.com> (D. Trung Tran).

<https://doi.org/10.1016/j.amsu.2022.103263>

Received 12 December 2021; Received in revised form 6 January 2022; Accepted 13 January 2022

Available online 20 January 2022

2049-0801/© 2022 The Authors. Published by Elsevier Ltd on behalf of IJS Publishing Group Ltd. This is an open access article under the CC BY-NC-ND license

(<http://creativecommons.org/licenses/by-nc-nd/4.0/>).

allogeneic, autologous, partial, or total shoulder replacement [11]. This surgery remains a challenge due to high level of difficulty in rehabilitation of the shoulder, elbow and hand, since it can affect the rotator cuff tendons [12].

We would like to introduce a clinical case, with a large aneurysm bone cyst on the humerus, where this patient has failed with the method of bone grafting, as the tumor would continue to grow and transform rapidly after the intervention. The patient was chosen for wide resection surgical intervention, reconstructing the structure with reverse shoulder replacement. This case report has been reported is compliant with the SCARE Guidelines 2020 [39].

## 2. Case presentation

A 26-year-old male patient, right-handed, with a healthy personal history and no abnormal findings in the family. Two years ago, the patient suddenly had severe pain and lost movement in his right hand while riding a bicycle. When he went to the doctor, he discovered that he had a fracture in the upper right humerus/bone aneurysm, then the patient was arranged to undergo surgical curettage and autologous pelvic reconstruction. After 07 months of surgery, the patient's pain recurred; he went to another hospital and was diagnosed: Recurrent aneurysm bone cyst, where the patient continued to be treated with curettage and 2nd artificial bone graft. The patient still felt pain back in the shoulder area, with swelling of the head on the arm and limited movement. The patient went to a specialized oncology hospital for a pathological biopsy of the tumor, then was consulted to be transferred to our center for further treatments. Through clinical examinations, we found that the patient had much pain in the right shoulder area, accompanied by swelling, limited movement, and a noticeable deformation of the right shoulder. Using X-ray film and CT scan to re-evaluate the lesion, we found an image of proximal humerus bone defect, with multi-arc, rough margins, periosteal thickening, thinning of the bone wall spreading to all sides, and no periosteal reaction (Fig. 1, Fig. 2). Continuing to evaluate the lesion on MRI, we observed cortical disruption of the cyst, invasion of surrounding soft tissue of the superomedial proximal humerus. In addition, the MRI showed a complete loss of normal structure of the rotator cuff tendon and of the insertions site on

the proximal humerus (Fig. 3). Based on this imaging diagnosis, together with the results of histopathology led us to the diagnosis of a large aneurysm bone cyst in the proxiaml humerus, grade 3.

We continued to follow the surgical option for treatment, however, there was an adjustment regarding the surgical method selection, that is wide resection surgical intervention to completely solve the invasive nature of the tumor and replace the joint using a reverse shoulder joint, which is a bold plan that has never been performed in Vietnam before. MRI and CT show that the tumor is about 11cm long, the inferior border is 4cm from the deltoid insertion site, the resected bone containing the tumor is expected to be 14cm long whilst preserving the maximum area of the deltoid insertion site in order to maintain the function for the reverse shoulder joint. In addition, we also measured the diameter of the remaining bone marrow canal, the size of the glenoid fossa, the artificial ball based on the socket, and the size of the contralateral socket, so that the expected template of the joint set was suitable for the patient.

The patient was given a primary skin incision from the coracoid process along the deltopectoral groove towards the deltoid tubercle. Exposing the cephalic vein, relying on this vein to dissect the pectoralis major inward, deltoid muscle outward. Expose, cut, and mark the insertion sites of pectoralis major, subscapularis, teres minor, teres major, latissimus dorsi muscle, and long head of biceps brachii, accordingly.

During the dissection, we paid close attention to detecting and preserving the route of the axillary nerve, through the identification of the inferior border of the subscapular muscle, and at the same time exposing and dissecting to protect the radial nerve gradually goes behind the humerus, exposing the inward brachial nerve vessel. The Deltoid muscle was dissected and exposed, ensuring the intended resecting area with minimal impact on the muscle insertion site whilst ensuring thorough removal of the aneurysm bone cyst. The remaining insertion site of the Deltoid muscle tendon after resection of the cyst-bearing bone is 2/3 of the original insertion site. An incision of the anterior glenohumeral joint capsule was made, dislocating the proximal humerus from the shoulder joint structure. The rotator cuff muscle and posterior joint capsule were resected to a safe limit (Fig. 4).

To facilitate the wide local resection, we used a vibrating saw to cut the humerus at a position 14cm from the superior surface of the humeral

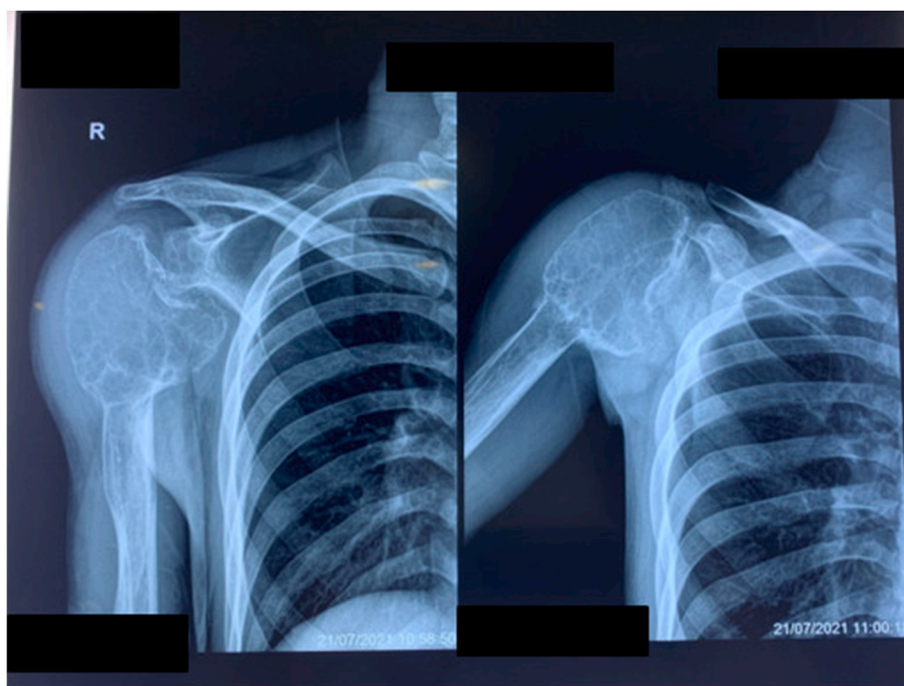


Fig. 1. X-ray image shows a cortical thickening lesion, bone wall erosion, multiple bone defects.

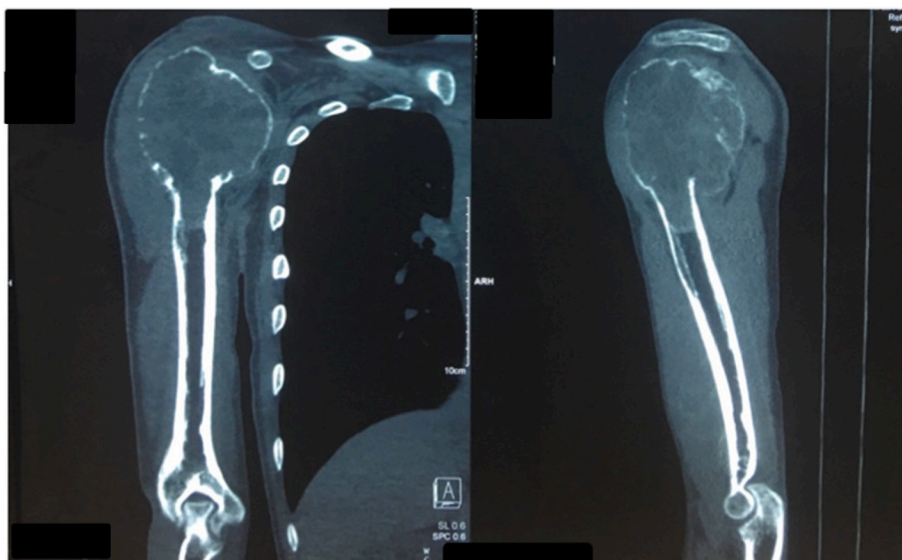


Fig. 2. The CT scan provides an overview of the bone lesions, allowing us to accurately measure for the replacement joint.

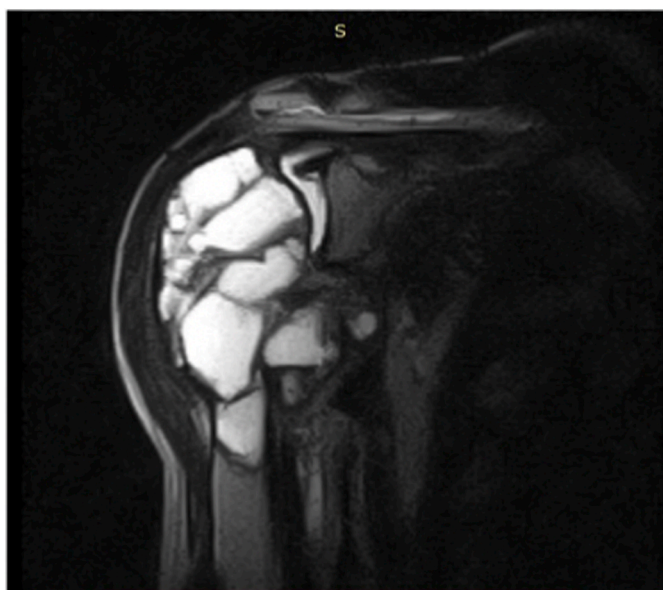

Fig. 3. The tumor invading parts of the rotator cuff tendon, the inferior margin of the tumor has not invaded the deltoid tuberosity on MRI.

according to preoperative calculations, then used a bone holder to lift the inferior end of the tumor-bearing bone up and perform inferioposterior resection from bottom to top. After removing the tumor, we proceeded to shape the humerus socket and install the glenoid sphere according to the size calculated before surgery. The prosthesis stem of the humerus which we selected, is a size 12 according to the preoperative template; this is a long stem with cement. Consequently, we tested the connecting module with a length of 12 cm, confirmed during surgery that the shoulder joint was stable, the range of motion was good, and there was no sign of dislocation (Fig. 5).

After surgery, the operated shoulder was immobilized using a Desault shirt, the incision progressed well, and the sutures were removed after 14 days. The postoperative histopathological result of the bone resection also confirmed the diagnosis of aneurysm bone cyst (Fig. 6). We use CT scanning to evaluate the postoperative result in 3D reconstructed images (Fig. 7).

The patient had trained in passive rehabilitation and combined with

physical therapy to avoid Deltoid muscle atrophy. The Desault bandage was removed after 6 weeks whilst increasing the passive exercises, and the patient can start doing active exercises that gradually increase the strength of the Deltoid muscle. Examination and evaluation at 3 months follow-up have confirmed the shoulder joint function was relatively good with abduction, external rotation, and extending movement. The Musculoskeletal Tumor Society (MSTS) score ASES score was 24, while the shoulder joint function score on the ASES scale was 80. Post-operative follow-up at 6 months after surgery has collected the Musculoskeletal Tumor Society (MSTS) score of 28, while the shoulder joint function score according to ASES scale was 93.33. The patient has returned to a normal life.

### 3. Discussion

Aneurysm bone cyst is a rare benign tumor, accounting for 1% of all primary osseous tumors, the tumor forms blood-filled cavities, the septum contains osteoblastic and osteoclast cells, inside there are macrophages, lymphocytes, fibroblasts, so far the etiology is unclear, the disease onset is under 20 years of age, and the ratio between men and women is similar [6,8,13,14]. This tumor can be primary or secondary to other benign tumors and accounts for about 19–39% such as giant cell tumors, chondrosarcomas, and osteosarcomas. Several types of malignancies may have a histopathological appearance that resembles aneurysmal bone cysts [6,13]. Aneurysm bone cysts can occur at any location but are common in the medulla of long bones, usually not affecting the cartilage growth, however, about 23% of patients have limb deformity due to the tumor affecting cartilage growth [8,13]. Henry J. Mankin et al. reported 150 patients with aneurysm bone cysts, showing that there were 7 cases of aneurysm bone cyst in the proximal humerus, accounting for 4.67% [14].

Several non-surgical interventions have also been recorded with beneficial results but have many technical difficulties as well as complications such as phenol injection, Ethibloc sclerotherapy, embolization, and radiation therapy. The method of injection Ethibloc has recorded 30% of local reactions and other systemic complications such as infection, fistula, pulmonary embolism. Radiation therapy with a dose of 30–40 Gy also often encounters complications such as bone necrosis, cancer [13]. Using Calcitonin and methylprednisolone injected intracystically has been evaluated by some authors as a safe and effective method with a low recurrence rate, helping to promote the healing of primary ABC lesions [15,16]. Recently, the use of doxycycline is also a

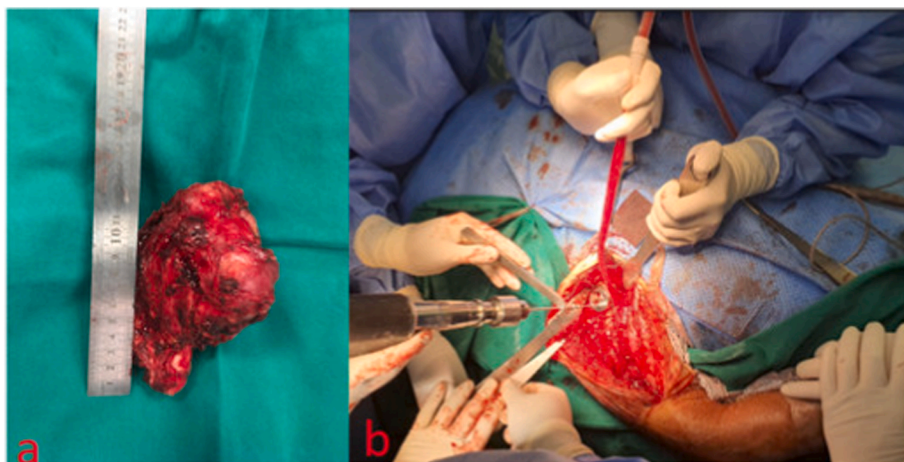


Fig. 4. (a) Resected proximal humerus tumor, (b) Reverse humeral head installation at the socket.

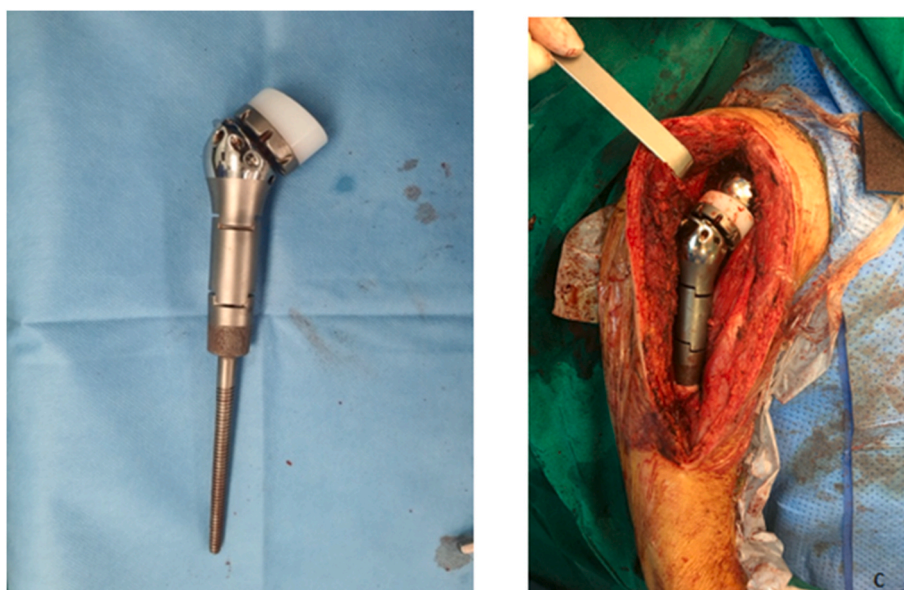


Fig. 5. Humeral component with modular.

new option because of its anti-cancer properties, including inhibition of matrix metalloproteinase and angiogenesis, which are two factors that play a role in the development of ABC size in bone [17]. Shiels et al. reported improvements in all 16 ABC cases treated with transdermal doxycycline with a 6% recurrence rate after a median follow-up of 18 months, which is currently not yet widely used. Non-interventional treatment with Denosumab is also a possible, safe and promising method. It has been shown that using Denosumab reduces tumor size, pain, and postoperative tumor recurrence rate [18–20]. This non-invasive treatment is often used in cases of primary aneurysm bone cysts that have not broken the cortical and invaded the surrounding area.

Regarding surgical intervention of aneurysm bone cyst, there are several different methods described in the literature such as curettage with or without bone graft, cryosurgery, resection of tumor-bearing bone, and reconstructing the humeral structure with cement, vascularized fibular graft, an acrylic prosthetic humerus based on 3D printing technology [10,12,13]. In addition, shoulder joint replacement, such as partial, total, reverse shoulder megaprosthesis, has displayed beneficial results but is more expensive and is not always available [21,22].

The most common treatment option for small but yet affect cortical

bone is curettage, with or without bone grafting. However, the recurrence rate of this method is as high as 30–40% [10]. Ozaki et al. reported a recurrence rate of 17% with curettage and cement grafting [23]. Recently some authors have also implemented a percutaneous Curepsy technique with the advantages of limited invasiveness and good local control, with a small incision of about 5–10mm using a curette or Rongeur to remove the internal organization of the tumor [24]. Author, it suggests that this method can destroy a sufficient amount of the internal structure of the tumor to repair the damage. The author also reported that the recurrence rate of this technique is 19%, and the effectiveness of this technique is also partly related to the selection of patients for the intervention (selecting patients with small tumor lesions and imaging diagnosis suggest a primary ABC lesion) [24].

In our patient, the lesion of the proximal humerus is broad, grade 3 according to Capanna's classification, and on MRI, there is a partial invasion of the rotator cuff tendon, the inferior border of the tumor is 4cm from the deltoid tubercles. In fact, our patient's clinical case shows a relatively short time of recurrence (07 months after the first surgery and 11 months after the second surgery, and has a strong progression, invasive to the surrounding soft tissue). During the operation, to ensure the principle of wide local resection of the tumor, we also removed the

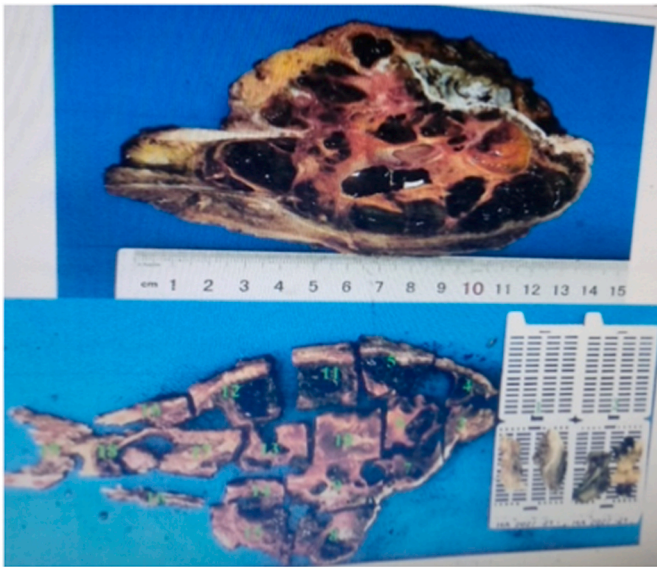

Fig. 6. Pathological results of the sectional section of the patient after surgery.

insertion site of the rotator cuff tendon. To compensate for the function of the rotator cuff tendon, the option of reverse shoulder joint is considered the most applicable. However, due to the fact that the structure of the reverse shoulder joint uses the function of the Deltoid muscle to replace the function of the rotator cuff tendons, preserving the maximum the area of Deltoid muscle insertion site and the axillary nerve is imperative, which is a key issue for functional recovery after surgery.

In cases of cystic aneurysms grade V according to Capanna's classification or grade 3 according to Enneking's classification, these are progressive aneurysm cystic lesions that destroy the bone wall of the proximal humerus, total resection of the proximal humerus is necessary to avoid recurrence [5,8,11,13]. There are multiple substitutions that can be implemented for the resected bone such as fibular graft, vascularized or not, allogeneous humeral graft, bone fusion using intramedullary nailing with pins or kirchner wires. The advantages of these methods are ease of sourcing, but the disadvantages are poor healing, bone loss, graft rejection, and infection. Particularly, the vascularized fibular graft has a higher healing rate, yet it also requires specialized medical center, takes a long time, and the replaced fibular graft is not enough to replace the humerus, resulting to difficulty in restoring function after surgery [8,25–28]. Author Haluk Ozcanli et al. also reported 7 clinical cases where the resected tumor-bearing bone was replaced by an autologous fibular graft, while retaining the cortical

bone. The results showed that there was a recurrence in 2 patients, the remaining patients had relative bone healing and almost normal shoulder function in all patients [23].

Artificial shoulder replacement surgery with partial or total replacement is proposed to avoid recurrence and healing failure. However, with this option, it will be difficult to restore function to the shoulder, elbow and hand joints, especially in cases where the tumor has invaded the rotator cuff tendons extensively. The reverse shoulder joint megaprosthesis is used as the best surgical solution for broad bone loss of proximal humerus, with rotator cuff injury, and without damage to the deltoid muscle and axillary nerve. Because its kinetic mechanism is based on the preservation of the delta muscle, it provides better functional outcomes after surgery than options of partial joint replacement, or allograft [11]. This design not only improves the strength, stability and range of motion of the joint, but also increases the risk of dislocation and loose joints.

The healing process of rotator cuff insertion site in cases of conventional artificial joints is not always straightforward, leading to joint instability, increased risk of dislocation and loss of function of the shoulder joint after surgery. In these cases, reverse total shoulder replacement is also an effective solution in cases of failure after partial replacement. Author V. Singh Chauhan et al. also introduced a clinical case of a 28-year-old male patient, diagnosed with cancer of the proximal humerus 10 years ago. The patient has undergone tumor resection, partial shoulder replacement megaprosthesis since this solution can ensure wide resection, but due to the loss of function of the rotator cuff tendon, which causes dislocation of the proximal humerus upward leading to pain and severe arm movement limitation. The patient was replaced with an inverted shoulder joint in 2017, which improved the function of the shoulder joint [29].

Another study by author Timothy W. Grosel BS et al., in 2018 also compared the results of reverse shoulder replacement surgery (10 patients) and partial shoulder replacement surgery (37 patients) for the treatment of proximal humerus tumor. The author showed that the complication rate was the most common in the group that received partial shoulder replacement with 13 patients (34%), while the reversed shoulder replacement group had only 1 patient (10%). Among the complications recorded in the group of patients with partial shoulder replacement, there were 6 cases of dislocation and 2 sub-dislocations, no dislocation was recorded in the group of patients with reverse shoulder replacement, additionally, there was a case of partial shoulder replacement had to undergo a reverse shoulder replacement surgery to improve the patient's motor function [38].

In our patient, the lesion of the proximal humerus was extensive, and the MRI image showed partial invasion of the rotator cuff tendon. This is a Grade V lesion according to Capanna's classification, if classified according to the Enneking classification, the lesion is considered as grade

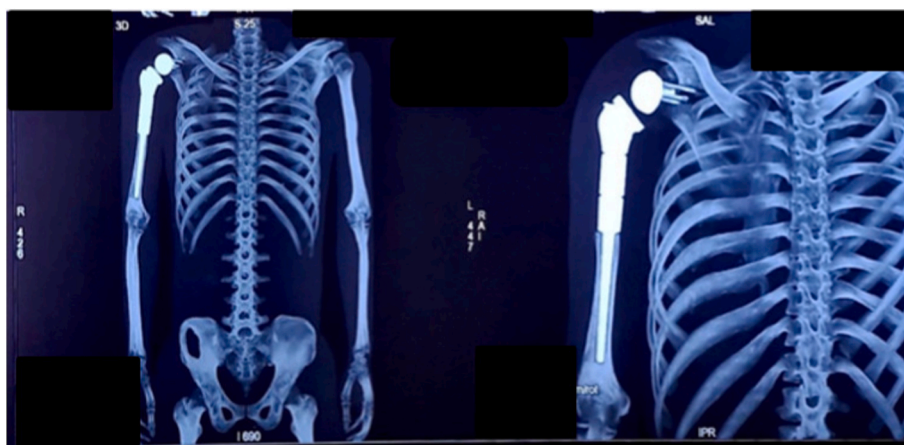


Fig. 7. Postoperative VRT (Volume Rendering Technique) 3D rendered film.

3 (aggressive). The inferior margin of the tumor is 4 cm from the deltoid tubercle. In fact, our patient's clinical case shows a relatively short time recurrence rate (07 months after the first surgery and 11 months after the second surgery, and has a strong progression, invasive to the soft tissue). During the operation, to ensure the principle of wide local resection, we also removed the insertion site of the rotator cuff tendon. To compensate for the function of the rotator cuff tendon, the option of reverse shoulder joint is considered the most applicable. However, due to the fact that the structure of the reverse shoulder joint uses the function of the Deltoid muscle to replace the function of the rotator cuff tendons, preserving the maximum the area of Deltoid muscle insertion site and the axillary nerve is imperative, which is a key issue for functional recovery after surgery.

Several authors, such as De Wilde et al. have also reported very early results of reverse shoulder replacement surgery (between 1997 and 2001) in 4 patients with proximal humerus tumors (two recurrent giant cell tumors, one chondrosarcoma, and one osteosarcoma), the median follow-up time was 38 months. The results for shoulder function are promising, with abduction range up to 175°, shoulder flexion up to 169°, only 1 patient has weak shoulder rotation, MSTS score of 90–96.7% and no complications had been found [30].

In a review article, author Antonio D' Arienzo et al., also provided the mean MSTS score in patients undergoing reverse shoulder replacements between 18 and 25.7, the average result being higher, in terms of the shoulder range of motion, shoulder extension, and adduction, than with other replacement options [21]. In addition, the author also listed a number of complications of reverse shoulder replacement, which were recorded with rates ranging from 0% to 40% [21]. Of these complications, the most common were scapular notching (0–30%) [31–34], articular instability and dislocation (0–30%) [32–36], aseptic loosening (0–13.3%) [31,35], infection was reported at a low rate<sup>21</sup>. However, the author also showed that this complication rate was lower than other methods.

Reviewing a number of documents has revealed that the report of reverse shoulder replacement surgery in patients with aneurysm bone cyst is very rare, the author AKS Kaa in mentioned 1 case of aneurysm bone cyst on the proximal humerus with the size of 6cm in a total of 14 patients with proximal humerus tumors, who underwent reverse shoulder replacement [37]. This uncommon could be explained by the rarity and non-malignant nature of the cysts, so it is rarely that wide local resection could be indicated as the treatment of bone cancer. In addition to that is the effectiveness of current non-invasive or minimally invasive treatments, or bone curettage, with or without bone graft.

#### 4. Conclusion

Megaprosthesis reverse shoulder replacement is a good solution to restore function and range of motion of the joint for a large aneurysm bone cyst in the proximal humerus that rapidly recurs, causing bone degeneration, invasiveness, and loss of shoulder function. Calculation of preoperative tumor resection and for the expected template through the contralateral shoulder is absolutely necessary to predict the use of this modular joint replacement. Preservation of the Deltoid muscle and axillary nerve during tumor resection is a key issue to restore the function of the shoulder joint after surgery. Further follow-up time is needed to evaluate the long-term effectiveness of this surgery.

#### Sources of funding

The authors declare that sponsors had no such involvement.

#### Consent

Written informed consent was obtained from the patient for publication of this case report and accompanying images. A copy of the written consent is available for review by the Editor-in-Chief of this

journal on request. The patient received an explanation of the procedures and possible risks of the surgery, and gave written informed consent.

#### Author contribution

DTT: the main doctor conceived the original idea and operated the patients, revised manuscript. MNH, VDV, QT: followed up, operated the patients, revised manuscript. TDT, SNTQ: followed up, summed up, revised manuscript. QDM, CVT: operated the patients, revised manuscript.

#### Guarantor

DTT is the guarantor of this manuscript.

#### Provenance and peer review

Not commissioned, externally peer-reviewed.

#### Ethical approval

The procedures used in this study inhere to the tenets of the Declarations of Helsinki.

#### Sources of funding

We declare no funding for this study.

#### Declaration of competing interest

The authors declare that there is no conflict of interests regarding the publication of this paper.

#### Appendix A. Supplementary data

Supplementary data to this article can be found online at <https://doi.org/10.1016/j.amsu.2022.103263>.

#### References

- [1] J.M. Mirra, Aneurysmal Bone Cyst. Bone Tumors, Published online, 1989, <https://c.i.nii.ac.jp/naid/10015781473/>.
- [2] J. Cottalorda, R. Kohler, J. Sales de Gauzy, et al., Epidemiology of aneurysmal bone cyst in children: a multicenter study and literature review, *J. Pediatr. Orthop. Part B* 13 (6) (2004) 389–394, <https://doi.org/10.1097/01202412-200411000-00008>.
- [3] M.J. Kransdorf, D.E. Sweet, Aneurysmal bone cyst: concept, controversy, clinical presentation, and imaging, *AJR Am. J. Roentgenol.* 164 (3) (1995) 573–580, <https://doi.org/10.2214/ajr.164.3.7863874>.
- [4] K. Jamshidi, M. Jabalameli, D. Jafari, F. Najd Mazhar, H. Gharati, Endoscopic treatment of aneurysmal bone cyst of proximal of hummers, *J. Res. Orthop. Sci.* 1 (3) (2014), 0-0.
- [5] Z.M. Mohaidat, S.R. Al-gbaraibeh, O.N. Aljararhih, M.T. Nusairat, A.A. Al-omari, Challenges in the diagnosis and treatment of aneurysmal bone cyst in patients with unusual features, *Adv. Orthop.* (2019), e2905671, <https://doi.org/10.1155/2019/2905671>, 2019.
- [6] R.L. Randall, S.E. Nork, P.J. James, Aggressive aneurysmal bone cyst of the proximal humerus. A case report, *Clin. Orthop.* 370 (2000) 212–218, <https://doi.org/10.1097/00003086-200001000-00021>.
- [7] Mn A, C A, S E, S A, M D. Giant aggressive aneurysmal bone cyst of the proximal humerus unresponsive to Denosumab. *J Bone Biol Osteoporos.* Published online 636989184000000000:153-158. doi:10.18314/jbo.v5i1.1800.
- [8] M. Güven, M. Demirel, T. Özler, I.C. Başsorgun, S. Ipek, S. Kara, An aggressive aneurysmal bone cyst of the proximal humerus and related complications in a pediatric patient, *Strateg. Trauma. Limb. Reconstr.* 7 (1) (2012) 51–56, <https://doi.org/10.1007/s11751-012-0132-9>.
- [9] T. Amouyel, F. Deroussen, M.-C. Plancq, L.-M. Collet, R. Gouron, Successful treatment of humeral giant aneurysmal bone cyst: value of the induced membrane reconstruction technique, *J. Shoulder Elbow Surg.* 23 (9) (2014) e212–e216, <https://doi.org/10.1016/j.jse.2014.05.028>.
- [10] K. Jamshidi, M. Jabalameli, D. Jafari, F. Najd Mazhar, H. Gharati, Endoscopic treatment of aneurysmal bone cyst of proximal of hummers, *J. Res. Orthop. Sci.* 1 (3) (2014), 0-0.
- [11] T.W. Grosel, D.R. Plummer, J.L. Mayerson, T.J. Scharschmidt, J.D. Barlow, Oncologic reconstruction of the proximal humerus with a reverse total shoulder

- arthroplasty megaprosthesis, *J. Surg. Oncol.* 118 (6) (2018) 867–872, <https://doi.org/10.1002/jso.25061>.
- [12] K.A. Singh, V. Shankar, S.P. Mohanty, Reconstruction of proximal humerus using custom made acrylic prosthesis in malignant bone tumors, *J. Orthop. Case Rep.* 6 (5) (2016) 65–68, <https://doi.org/10.13107/jocr.2250-0685.636>.
- [13] A. Aydın, H. Özcanlı, A. Yeter, F. Akıydız, E. Güler, A new technique for aneurysmal bone cysts of the proximal humerus: cortical collapsing, *Acta. Orthop. Traumatol. Turcica* 42 (2008) 161–165, <https://doi.org/10.3944/AOTT.2008.161>.
- [14] H.J. Mankin, F.J. Hornicek, E. Ortiz-Cruz, J. Villafuerte, M.C. Gebhardt, Aneurysmal bone cyst: a review of 150 patients, *J. Clin. Oncol. Off. J. Am. Soc. Clin. Oncol.* 23 (27) (2005) 6756–6762, <https://doi.org/10.1200/JCO.2005.15.255>.
- [15] L. Bavan, A. Wijendra, A. Kothari, Efficacy of treatment interventions for primary aneurysmal bone cysts: a systematic review, *Bone. Jt. Open* 2 (2) (2021) 125–133, <https://doi.org/10.1302/2633-1462.22.BJO-2020-0168>.
- [16] M.B.D.R. Oliveira, W. Meoahas, R.R. Silva, G.S. de Carvalho, F.C. de Q. Mello, M.E. M. Paschoal, Percutaneous treatment OF aneurysmal bone cyst with calcitonin and methylprednisolone, *Acta. Ortopédica. Bras.* 26 (5) (2018) 314–319, <https://doi.org/10.1590/1413-785220182605201423>.
- [17] H.Y. Park, S.K. Yang, W.L. Sheppard, et al., Current management of aneurysmal bone cysts, *Curr. Rev. Musculoskelet. Med.* 9 (4) (2016) 435–444, <https://doi.org/10.1007/s12178-016-9371-6>.
- [18] T. Lange, C. Stehling, B. Fröhlich, et al., Denosumab: a potential new and innovative treatment option for aneurysmal bone cysts, *Eur. Spine. J. Off. Publ. Eur. Spine. Soc. Eur. Spinal. Deform. Soc. Eur. Sect. Cerv. Spine. Res. Soc.* 22 (6) (2013) 1417–1422, <https://doi.org/10.1007/s00586-013-2715-7>.
- [19] K.M. Skubitz, J.C. Peltola, E.R. Santos, E.Y. Cheng, Response of aneurysmal bone cyst to Denosumab, *Spine* 40 (22) (2015) E1201–E1204, <https://doi.org/10.1097/BRS.0000000000001027>.
- [20] A. Dubory, G. Missenard, J. Domont, C. Court, Interest of Denosumab for the treatment of giant-cells tumors and aneurysmal bone cysts of the spine. About nine cases, *Spine* 41 (11) (2016) E654–E660, <https://doi.org/10.1097/BRS.0000000000001350>.
- [21] A. D'Arienzo, E. Ipponi, A.D. Ruinato, et al., Proximal humerus reconstruction after tumor resection: an overview of surgical management, *Adv Orthop* (2021) 5559377, <https://doi.org/10.1155/2021/5559377>, 2021.
- [22] K.A. Singh, V. Shankar, S.P. Mohanty, Reconstruction of proximal humerus using custom made acrylic prosthesis in malignant bone tumors, *J. Orthop. Case Rep.* 6 (5) (2016) 65–68, <https://doi.org/10.13107/jocr.2250-0685.636>.
- [23] T. Ozaki, A. Hillmann, N. Lindner, W. Winkelmann, Cementation of primary aneurysmal bone cysts, *Clin. Orthop.* 337 (1997) 240–248, <https://doi.org/10.1097/00003086-199704000-00026>.
- [24] K.I.A. Reddy, F. Sinnaeve, C.L. Gaston, R.J. Grimer, S.R. Carter, Aneurysmal bone cysts: do simple treatments work? *Clin. Orthop.* 472 (6) (2014) 1901–1910, <https://doi.org/10.1007/s11999-014-3513-1>.
- [25] C.G. Finkemeier, Bone-grafting and bone-graft substitutes, *J. Bone. Joint. Surg. Am.* 84 (3) (2002) 454–464, <https://doi.org/10.2106/00004623-200203000-00020>.
- [26] M. Ghert, N. Colterjohn, M. Manfrini, The use of free vascularized fibular grafts in skeletal reconstruction for bone tumors in children, *J. Am. Acad. Orthop. Surg.* 15 (10) (2007) 577–587, <https://doi.org/10.5435/00124635-200710000-00001>.
- [27] K. Arai, S. Toh, K. Tsubo, S. Nishikawa, S. Narita, H. Miura, Complications of vascularized fibula graft for reconstruction of long bones, *Plast. Reconstr. Surg.* 109 (7) (2002) 2301–2306, <https://doi.org/10.1097/00006534-200206000-00021>.
- [28] A. Minami, T. Kasashima, N. Iwasaki, H. Kato, K. Kaneda, Vascularised fibular grafts. An experience of 102 patients, *J. Bone Joint. Surg. Br.* 82 (7) (2000) 1022–1025, <https://doi.org/10.1302/0301-620x.82b7.10332>.
- [29] V.S. Chauhan, A. Vaish, R. Vaishya, Reverse shoulder arthroplasty after failed megaprosthesis for osteosarcoma of the proximal humerus: a case report and review of literature, *J. Clin. Orthop. Trauma.* 10 (3) (2019) 526–530, <https://doi.org/10.1016/j.jcot.2019.03.015>.
- [30] L.F. De Wilde, F.S. Plasschaert, E.A. Audenaert, R.C. Verdonk, Functional recovery after a reverse prosthesis for reconstruction of the proximal humerus in tumor surgery, *Clin. Orthop.* 430 (2005) 156–162, <https://doi.org/10.1097/01.blo.0000146741.83183.18>.
- [31] S. Maclean, S.S. Malik, S. Evans, J. Gregory, L. Jeys, Reverse shoulder endoprosthesis for pathologic lesions of the proximal humerus: a minimum 3-year follow-up, *J. Shoulder Elbow Surg.* 26 (11) (2017) 1990–1994, <https://doi.org/10.1016/j.jse.2017.04.005>.
- [32] L. De Wilde, P. Boileau, H. Van der Bracht, Does reverse shoulder arthroplasty for tumors of the proximal humerus reduce impairment? *Clin. Orthop.* 469 (9) (2011) 2489–2495, <https://doi.org/10.1007/s11999-010-1758-x>.
- [33] N. Bonneville, P. Mansat, J. Lebon, J.-M. Laffosse, P. Bonneville, Reverse shoulder arthroplasty for malignant tumors of proximal humerus, *J. Shoulder Elbow Surg.* 24 (1) (2015) 36–44, <https://doi.org/10.1016/j.jse.2014.04.006>.
- [34] M.F. Guven, L. Aslan, H. Botanlioglu, G. Kaynak, H. Kesmezacar, M. Babacan, Functional outcome of reverse shoulder tumor prosthesis in the treatment of proximal humerus tumors, *J. Shoulder Elbow Surg.* 25 (1) (2016) e1–6, <https://doi.org/10.1016/j.jse.2015.06.012>.
- [35] A.K.S. Kaa, P.H. Jørgensen, J.O. Søjbjerg, H.V. Johannsen, Reverse shoulder replacement after resection of the proximal humerus for bone tumours, *Bone. Jt. J.* 95-B (11) (2013) 1551–1555, <https://doi.org/10.1302/0301-620X.95B11.31545>.
- [36] D. Griffiths, P.D. Gikas, C. Jowett, et al., Proximal humeral replacement using a fixed-fulcrum endoprosthesis, *J. Bone Joint. Surg. Br.* 93 (3) (2011) 399–403, <https://doi.org/10.1302/0301-620X.93B3.24421>.
- [37] A.K.S. Kaa, P.H. Jørgensen, J.O. Søjbjerg, H.V. Johannsen, Reverse shoulder replacement after resection of the proximal humerus for bone tumours, *Bone. Jt. J.* 95-B (11) (2013) 1551–1555, <https://doi.org/10.1302/0301-620X.95B11.31545>.
- [38] G. Tw, P. Dr, E. Js, et al., Reverse total shoulder arthroplasty provides stability and better function than hemiarthroplasty following resection of proximal humerus tumors, *J. Shoulder Elbow Surg.* 28 (11) (2019), <https://doi.org/10.1016/j.jse.2019.02.032>.
- [39] R.A. Agha, T. Franchi, C. Sohrabi, G. Mathew, The SCARE 2020 guideline: updating consensus surgical CAse REport (SCARE) Guidelines, *Int. J. Surg.* 84 (2020) 226–230, for the SCARE Group.