

Access this article online
Quick Response Code:

Website: <a href="http://journals.lww.com/TJOP">http://journals.lww.com/TJOP</a>
DOI: 10.4103/tjo.TJO-D-23-00133

# Review for special issue: Corneal lamellar surgery: Present outcomes and future perspectives

Loïc Hamon<sup>1,2\*</sup>, Isabel Weinstein<sup>1,2</sup>, Adrien Quintin<sup>1</sup>, Tarek Safi<sup>1</sup>, Max Bofferding<sup>1,2</sup>, Loay Daas<sup>1,2</sup>, Berthold Seitz<sup>1,2</sup>

## Abstract:

Since the establishment of the first eye bank in the 1940s, their role has evolved to face new challenges. With the recent development of lamellar keratoplasties, eye banks play an even bigger role in the selection and preparation of donor tissues. The increasing number of keratoplasty techniques and the high demand for “ready-to-use” tissues are challenging eye banks to improve and develop new preparation techniques. Besides necessary examinations, new approaches of tissue analysis in eye banks allow a better/optimized selection of corneal tissues. These new challenges in tissue preservation, preparation, and selection are propelling eye banks into a new era of modern eye banking.

## Keywords:

Cold storage, cornea, donor tomography, eye bank, organ culture, prestripped tissues, quality management

## Introduction

Since the first penetrating keratoplasty (PKP) was performed by Eduard Zirm in 1905, the number of keratoplasties has inexorably increased worldwide.<sup>[1]</sup> Corneal blindness represents a major cause of blindness worldwide, affecting around 8 million individuals. Many of these patients may be visually rehabilitated by corneal transplantation.<sup>[2]</sup> Despite this increase in keratoplasties, more than half the world’s population still did not have access to keratoplasty in 2012.<sup>[3]</sup> Paradoxically, requirements for graft quality have continued to rise in countries where transplantation is more accessible. Alongside technical advances in PKP,<sup>[4]</sup> new lamellar techniques have also emerged.<sup>[5]</sup> These techniques, which focus on transplanting precise layers of the cornea, offer undeniable advantages for patients.<sup>[6]</sup> To ensure a

high level of quality, eye banks are more than ever involved in the selection and preparation process for these lamellar surgeries. In the past, on the contrary, the role of eye banks was limited solely to collection, storage, and evaluation of the tissues before transplantation.

## Methodology

This review covers various aspects of eye banking practices, with a focus on storage options, selection, and type of tissues. A literature search was conducted in MEDLINE and Scopus between May and October 2023. Numerous terms associated with eye banking were connected using the Boolean operators “and,” “or,” “and/or”, including “eye banking,” “preservation,” “culture medium,” “dextran,” “hypothermic storage,” “cold culture,” “organ culture,” “procurement,” “microbiology,” “donor screening,” “donor tomography,” “cornea guttata,” “specular microscopy,”

This is an open access journal, and articles are distributed under the terms of the Creative Commons Attribution-NonCommercial-ShareAlike 4.0 License, which allows others to remix, tweak, and build upon the work non-commercially, as long as appropriate credit is given and the new creations are licensed under the identical terms.

For reprints contact: WKHLRPMedknow\_reprints@wolterskluwer.com

**How to cite this article:** Hamon L, Weinstein I, Quintin A, Safi T, Bofferding M, Daas L, *et al.* Review for special issue: Corneal lamellar surgery: Present outcomes and future perspectives. Taiwan J Ophthalmol 2024;14:3-14.

<sup>1</sup>Department of Ophthalmology, Saarland University Medical Center (UKS), <sup>2</sup>Klaus Faber Center for Corneal Diseases, Including LIONS Eye Bank Saar-Lor-Lux, Trier/Westpfalz, Saarland University Medical Center, Homburg/Saar, Germany

### \*Address for correspondence:

Dr. Loïc Hamon,  
Department of Ophthalmology, Saarland University Medical Center, Kirrberger Straße 100, Bld. 22, 66421 Homburg, Germany.  
E-mail: loic.hamon@uks.eu

Submission: 30-08-2023  
Accepted: 05-12-2023  
Published: 12-02-2024

“endothelium,” “quality management,” “guidelines,” “penetrating keratoplasty,” “Descemet’s membrane endothelial keratoplasty (DMEK),” “Descemet’s stripping automated endothelial keratoplasty (DSAEK),” “ultra-thin DSAEK,” “deep anterior lamellar keratoplasty (DALK),” “pre-stripped,” “pre-cut,” “pre-loaded,” “modern,” and “advanced.” The terms were searched as “mesh terms” and “all fields” terms with no limitations on the keyword searches. Only articles published in peer-reviewed journals were selected in this review. The authors screened the search results and selected the most recent and noteworthy publications concerning the field of eye banking. This methodology is subject to selection bias, due to the finite number of keywords and the (assumed) subjective selection of the most recent and/or relevant articles. Furthermore, only articles written in English, French or German were taken into consideration.

### Recovery of corneal tissues

Corneal transplantation safety is widely dependent on clinical donor selection. The risk of donor-to-host disease transmission through corneas, such as retinoblastoma,<sup>[7]</sup> the cases of Creutzfeldt–Jakob, and rabies transmissions in the 1970s<sup>[8]</sup> or acquired immune deficiency syndrome in the 1990s,<sup>[9]</sup> with lethal consequences for the recipients, has been a major concern since the beginning of keratoplasty.<sup>[10]</sup> To minimize this risk, careful donor selection is necessary. Regulatory agencies such as the European Eye Bank Association, the Eye Bank Association of America, or the Association of Eye Banks of Asia are continuously working to minimize this risk with regularly updated and broadly accepted regulations in the field. In this context, the use of nucleic acid testing has shown high sensitivity and specificity in the analysis of potentially transmissible infectious diseases,<sup>[11]</sup> but standard clinical protocols require postmortem validation (if no premortem blood is available).<sup>[12]</sup>

If the donor presents no contraindications, the eye bank staff can proceed with the collection of the donor corneas,<sup>[13]</sup> using one of the following methods:

#### *Whole globe collection*

Whole globe collection is a simple and quick method of collecting donor tissue and can be performed in the morgue, in a refrigerated room, or at the donor’s bed depending on the possible collection process. The globe is lifted out of the orbita with an instrument, and the optic nerve and extraocular muscles are cut with scissors, similar to an enucleation procedure. Whole globes need to be prepared in the eye bank before surgery.<sup>[14]</sup> Advantages of this method are the short time of tissue collection and the possibility to prepare scleral tissue, allowing tissue preparation for other surgeries such as sclerocorneoplasty or scleral patches.

#### *Corneoscleral explantation*

Corneoscleral explantation (15 mm disc) is a more expensive alternative regarding time and resources. It is performed in the same way as an ophthalmic surgical procedure, under sterile conditions [Figure 1].<sup>[15]</sup> This method has a much higher acceptance rate by the donors’ relatives as only the corneoscleral disc is explanted.<sup>[16]</sup> The corneoscleral disc is also already cut, avoiding further manipulations in the eye bank before preservation.

After collection, the whole globes or corneas are taken to the eye bank, where they are preserved, examined, and prepared for surgical purposes.

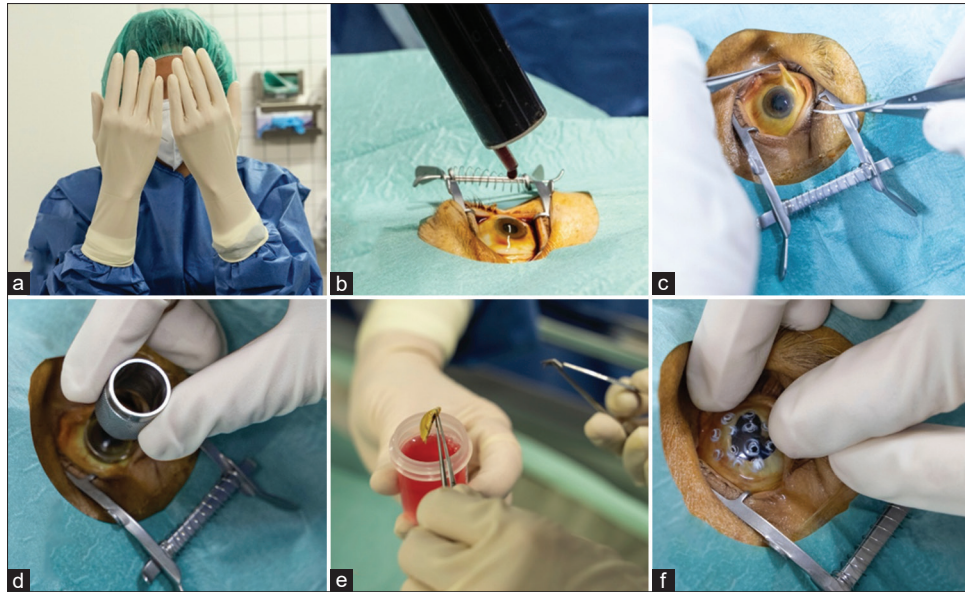
### Organization and quality management system in the eye bank

An eye bank is bound by the laws, technical norms, guidelines, and legislative frameworks of its country, which regulate corneal donation, handling, transport, and transplantation of donor tissues.<sup>[1]</sup> A quality management system (QMS) is an essential component of a highly functioning eye bank to ensure a maximum level of quality and safety of human tissues.<sup>[17]</sup> The International Organization for Standardization 9001:2015 standard can be adopted for the entire process in eye banks from donation to transplantation.<sup>[18]</sup> This standard follows a process-oriented approach with the goal of continuous improvement. The QMS is based on the principle of good practice and provides defined instructions and standard of operating procedures for every step of the donation-transplantation process [Figure 2].<sup>[18]</sup>

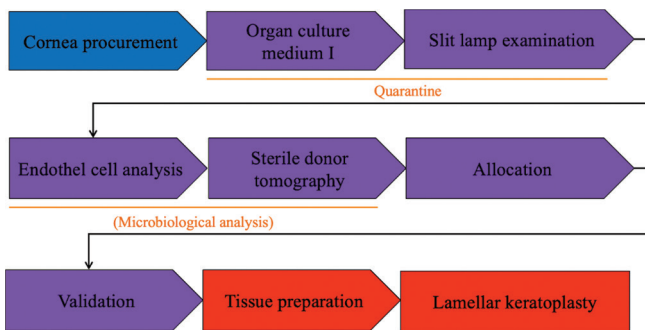
The eye bank must be located in a suitable and properly equipped facility. Human tissues should be processed under sterile conditions, ideally with a clean room concept [Figure 3]. The staff must successfully complete initial basic training and necessary refresher courses and demonstrate essential knowledge to carry out the expected tasks. Before recovering human corneas, personnel must be sufficiently trained and be familiar with the necessary documentation regarding the consent of the donor family, donor selection criteria, contraindications as well as the proper techniques for recovering the cornea and reconstruction of the eye. In this way, tissue quality can constantly be increased, and the number of discarded tissues due to contamination concerns can be diminished.<sup>[19]</sup> Traceability of the donor and the recipient must be ensured and documented throughout the entire process. Internal and external audits need to be held regularly to monitor, maintain, and improve the QMS and obtain national and international accreditations.

### Preservation of corneal tissues

Introduced in 1935, the conservation of whole globes in moist chambers directly after enucleation was the only



**Figure 1:** Cornea procurement – corneoscleral technique. (a) The material for corneal removal is prepared in a sterile manner, eye bank staff need to wash and sterilize themselves like for intraocular surgery. (b) Povidone-iodine 1.25% is applied slowly 5 min before trephination, to minimize potential contamination.<sup>[15]</sup> (c) Bulbar conjunctiva is dissected around the limbus before trephination. (d) Trephination is performed using a 15 mm diameter round trephine. To ensure optimal processing of the graft, trephination should be exact and concentric. (e) Following trephination, the corneoscleral disc is placed in organ culture medium II (also known as transport medium). (f) After corneal collection, a plastic shell is applied for esthetic reconstruction, and the eyelids are sutured or glued together so that there is no evidence of the procedure for the relatives



**Figure 2:** Path of a donor cornea before lamellar keratoplasty from procurement in the mortuary (blue) to the operating room (red). Between the beginning and the end of its journey, the donor cornea is processed in the eye bank (purple) in an isotonic organ culture medium (so-called medium I or preservation medium), where it undergoes a series of analyses (including microbiological analysis of culture medium, slit-lamp examination, endothelial cell analysis, and sterile donor tomography) before being allocated (patient-cornea matching) and approved (= validation) for surgery. Before penetrating or anterior lamellar keratoplasty, donor corneas need to be transferred into another hypertonic organ culture medium (so-called medium II or transport medium) to deswell to normal corneal thickness. Corneas allocated for Descemet's membrane endothelial keratoplasty can remain in medium I before surgery. The tissue preparation (prestripping and/or stripping) for lamellar keratoplasties can be processed in the eye bank or – most often – in the operating room before surgery

known preservation technique until the 1960s.<sup>[20]</sup> The insufficient sterility and the restricted storage period did not leave enough time for quality control in the eye banks and led to the replacement of this method with new, more effective techniques.

The first protocols for cryopreservation were developed in the 1960s.<sup>[21]</sup> Nevertheless, cryopreservation protocols for human corneas were not able to provide tissues with sufficient endothelial quality.<sup>[22]</sup> To date, donor corneas

cannot reliably be frozen. The worldwide COVID-19 pandemic in 2019 and the resulting organizational challenges for eye banks<sup>[23]</sup> led to a renewed interest in cryopreservation techniques and new protocols may emerge in the near future.<sup>[24]</sup>

Currently, there are two major preservation techniques: hypothermic storage, widely used worldwide, especially in North America and Asia and organ culture, mostly used in Europe [Figure 4].

### Hypothermic storage

This storage technique at 2°C–8°C was developed by McCarey and Kaufman in 1974. The original McCarey–Kaufman (M-K) medium consisted of tissue culture medium TC-199, dextran (an osmotic agent preventing corneal swelling), bicarbonate, and antibiotics (penicillin/streptomycin) and allowed a storage period of up to 10 days.<sup>[25]</sup> New solutions, such as the modified M-K medium, K-sol, or the popular Optisol (GS), enable storage periods of 14–16 days.<sup>[26]</sup>

Donor corneoscleral discs are stored in flat cylindrical containers, allowing morphological inspection with the slit lamp and endothelium inspection by specular microscopy, both under sterile conditions if using special fixation devices. Low temperature slows cell metabolism, reducing pathogen proliferation but also interfering with corneal wound healing.<sup>[10]</sup>

The technique of hypothermic storage is simple and does not require expensive equipment. Donor corneas





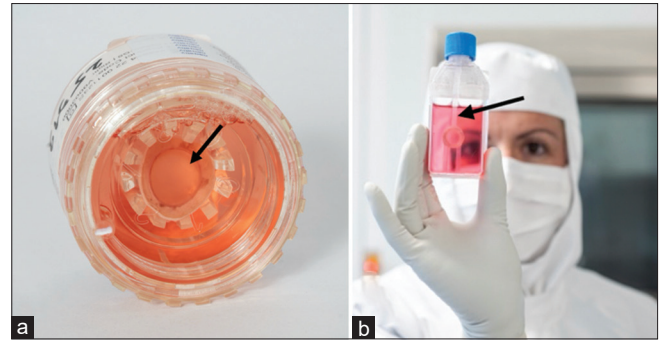
**Figure 3:** Cleanroom in the Klaus Faber Center for Corneal Diseases, incl. LIONS Eye Bank Saar-Lor-Lux, Trier/Westpfalz (Homburg/Saar, Germany). (a) During procurement, the corneas are transferred from organ culture medium II (transport medium - containing dextran) to organ culture medium I (preservation medium - without dextran). Corneas are mounted on holders and transferred in sterile conditions under laminar flow. (b) A staff member in sterile clothing renewing the organ culture medium of organ-cultured corneas under a laminar flow bench in maximal sterile conditions (EU GMP grade A) in clean room EU GMP Grade B (so-called "A in B"). (c) Transfer chamber between the different clean rooms for corneas and instruments. The chambers are equipped with unilateral flow pressure systems (from the most to the least sterile cleanroom) to ensure the sterility of the areas. (d) Organ-cultured corneas are stored at +34°C in an incubator for up to 28 days

are also directly available for corneal surgery. Compared to organ culture, storage time appears shorter, but more recent storage solutions nonetheless allow for scheduled surgery.

### Organ culture preservation

Introduced for eye banks by Doughman *et al.* in the 1970s and then widely popularized in Europe,<sup>[27]</sup> organ culture aims for the long-term preservation of the human cornea under simulated physiological conditions. This technique was also (re)introduced in North America as "Minnesota system corneal preservation" but has not supplanted hypothermic storage.<sup>[28]</sup>

In the eye bank, corneas are suspended in a cell culture container filled with an organ culture medium (modified Minimal Essential Medium) and supplemented with fetal or newborn calf serum (2%–10%), antibiotics, and antimycotics (*organ culture medium I*, so-called *preservation medium*). Cell culture containers are stored at 30°C–37°C for a maximum recommended period of 28 days, with medium renewal after 7–14 days, depending on the exact medium composition. With *medium I* being isotonic, the organ-cultured cornea swells to twice its normal thickness during storage. Before PKP or DALK can be performed, the organ-cultured cornea



**Figure 4:** Storage options. (a) Hypothermic storage. The donor corneoscleral disc (arrow) is stored in flat cylindrical containers, allowing morphological inspection with the slit lamp and endothelium inspection by specular microscopy, both under sterile conditions if using special fixation devices. (b) Organ culture preservation. In cell culture flask, corneoscleral discs are maintained vertically on a plastic holder (arrow)

has to be transferred into a hypertonic medium for stromal deswelling, containing a macromolecule—mostly dextran T500 4%–8%.<sup>[26]</sup> Dextran cannot, due to technical limitations, be added to the isotonic *medium I*. The proven toxicity of dextran on endothelial cells<sup>[29]</sup> imposes a deswelling time as short as possible.<sup>[30]</sup> This process of deswelling is not necessary before DMEK (but remains necessary before DSAEK!).

Organ culture is a more complicated and expensive procedure than the hypothermic storage but offers advantages such as a longer storage time<sup>[26]</sup> allowing more time for examination and the control of pathogen contamination during the storage time. This technique requires well-equipped facilities. Concerning endothelial vitality and graft survival, both preservation techniques seem to have comparable outcomes.<sup>[26]</sup>

Several advances in culture media are under consideration, promising improvements in terms of preservation, notably with calf serum-free culture media.<sup>[31]</sup> Regarding deswelling agents, there is currently no practical alternative to dextran, although some research is exploring the possibility of deswelling with poloxamines.<sup>[32]</sup> Moreover, new organ culture options are currently developed such as the active storage machine, a device where corneas are preserved in almost physiological conditions of electrolytic medium and pressure in banks of "storage plates"<sup>[33]</sup> but are currently not commercially available.

### Tissue selection and suitability for transplantation

Before cultured corneas can be transplanted, they have to fulfill certain quality criteria in accordance with current international and/or national standards. These standards vary according to the type (PKP, anterior, or posterior lamellar keratoplasty) and the elective or urgent nature of the surgery. Besides necessary examinations, new approaches of tissue analysis have been developed over the past few years, allowing to

increase in the quality of transplanted corneas from modern eye banks.<sup>[34]</sup>

### *Microbiological testing*

In the case of hypothermic storage, microbiological testing of samples of the storage solution is generally not performed, as the storage time is too short to receive the results before keratoplasty.<sup>[26]</sup> Moreover, the number of contaminating germs should be low and not grow at this temperature after proper decontamination during recovery<sup>[15]</sup> and before storage.

In the case of organ culture, microbiological testing of the medium sample is performed during the quarantine period at the beginning of the cultivation process. Contaminated tissues are discarded before keratoplasty.

### *Morphological examination: slit-lamp biomicroscopy*

Slit-lamp biomicroscopy has been a fundamental method of tissue evaluation and remains the gold standard for determining surgical suitability, using different magnifications and illumination techniques, including direct illumination, retroillumination, specular reflection, and sclerotic scatter, to evaluate all layers of the cornea from both anterior and posterior perspectives.<sup>[35]</sup>

The examination is performed through a cell culture container under sterile conditions. In the case of hypothermic storage, the cylindrical storage plates are put on a fixation device mounted onto the slit lamp. In the case of organ culture, the cell culture flasks are placed vertically on a support positioned in place of the chin rest. A cornea with a scar or other morphological abnormalities can still be used for posterior lamellar keratoplasty (depending on scar location) or for an emergency tectonic PKP.

### *Endothelial evaluation and detection of cornea guttata in the eye bank*

The evaluation of the endothelial cell layer is of utmost importance to ensure tissue viability and is part of the eye bank evaluation protocol since the early 2000s.<sup>[1]</sup>

Specular microscopy is the first-choice technique in hypothermic storage. This technique does not require osmotic stimulation of the endothelial cells, avoiding tissue manipulations and associated endothelial cell loss.<sup>[36]</sup> However, specular microscopy is usually restricted to the center of the cornea, and visualized areas are limited because of a microscope-related fixed magnification.

Inverted light microscopy is the first-choice technique for organ-cultured corneas [Figure 5]. The endothelial cells are visualized by swelling the intracellular space using a hypotonic solution, allowing endothelial layer inspection regardless of the corneal hydration.<sup>[37]</sup> Application of

vital stains, such as trypan blue, may help to discriminate dead or necrotic cells.<sup>[37]</sup>

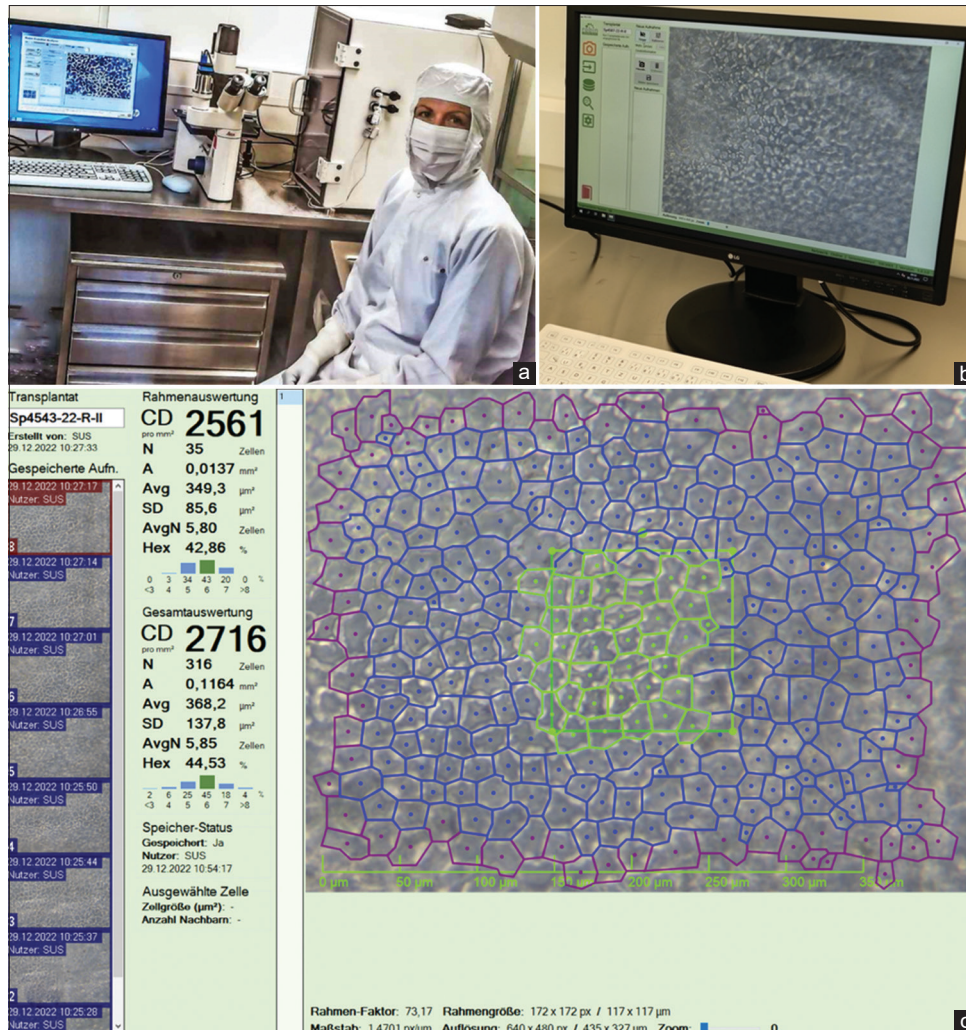
According to international standards, a minimum endothelial cell density (ECD) of 2000 cells/mm<sup>2</sup> is needed for penetrating or posterior lamellar keratoplasty to ensure long-term graft survival.<sup>[1]</sup> A minimum ECD between 1000 and 2000 cells/mm<sup>2</sup> is advised (but not required) for anterior lamellar keratoplasty or tectonic surgery. Corneas with ECD lower than 2000 cells/mm<sup>2</sup>, endothelial cell loss of more than 25% during cultivation, cell necrosis, pronounced polymegathism or pleomorphism, pronounced granulation/vacuolization, or cornea guttata (CG) have to be discarded for elective penetrating or posterior lamellar surgery.<sup>[1]</sup>

CG detection is neither simple nor standardized using inverted light microscopy as it is very difficult to detect with a slit lamp because of corneal swelling and the presence of organ culture medium. Therefore, a relatively high prevalence of CG on transplanted corneas has been reported after PKP<sup>[38]</sup> and DMEK.<sup>[39]</sup> Safi *et al.* recently investigated morphological criteria regarding inverted light microscopy that correlated with the presence of CG on transplanted tissues: The presence of <50% of the cells in an endothelial picture having a hexagonal or a circular shape, the presence of cell membrane defects and interruptions, and presence of a small thickening of the cell membrane “blebs.”<sup>[40]</sup> Using these findings, artificial intelligence can be used for automated endothelial cell count (ECC) as well as the detection of abnormalities in specular microscopy images, including areas of necrosis and the presence of CG [Figure 6].

### *Sterile donor tomography*

Given the considerably increased number of keratorefractive procedures performed in the past three decades, eye banks will soon have to more intensively face the problem of identifying donor corneas with abnormal refraction, which cannot always be reliably recognized by slit-lamp examination alone.<sup>[41]</sup> Therefore, many surgeons have highlighted the need for improved screening techniques of donor corneas to avoid refractive surprises after keratoplasty.<sup>[42]</sup> A quick and efficient method to achieve this is donor tomography. A more recent concept, known as “sterile donor tomography,” sterilely measures the organ-cultured cornea stored in a cell culture flask using the swept-source anterior segment-optical coherence tomography (AS-OCT) [Figure 7].<sup>[43,44]</sup> A raster scan is generated from the back surface of the donor cornea, creating a 3D volume dataset with a depth resolution of 5.621 μm/voxel in aqueous medium and a lateral resolution of 6 μm/voxel.<sup>[45]</sup> Thereafter, the measured raw data are loaded into MATLAB (MathWorks Inc., Natick, Massachusetts, USA) and pretreated to remove artifacts induced by the culture flask wall and the tissue





**Figure 5:** Evaluation of corneal endothelium. The evaluation is performed with an inverted light microscope under sterile conditions in the eye bank. (a) A member of the eye bank staff performing endothelial cell count (ECC). (b) The examination is displayed on a monitor. The examiner takes a picture of the endothelial cell layer for further analysis. To evaluate donor corneal endothelium, inverted light microscopy should be performed in the center, in the 4 paracentral/midperipheral quadrants, and in the periphery of the donor cornea. (c) ECC using Robin REAXLR (robin GmbH, Haan, Germany). The ECC is performed automatically in the selected area and can be adapted manually by moving or deleting the points in the center of each cell. The cell density is estimated based on the ECC in the green area. Cells that only partially fit in the area are counted if they cross the lower or left borders of the area and are not counted if they cross the upper or right borders to avoid over- or underestimation

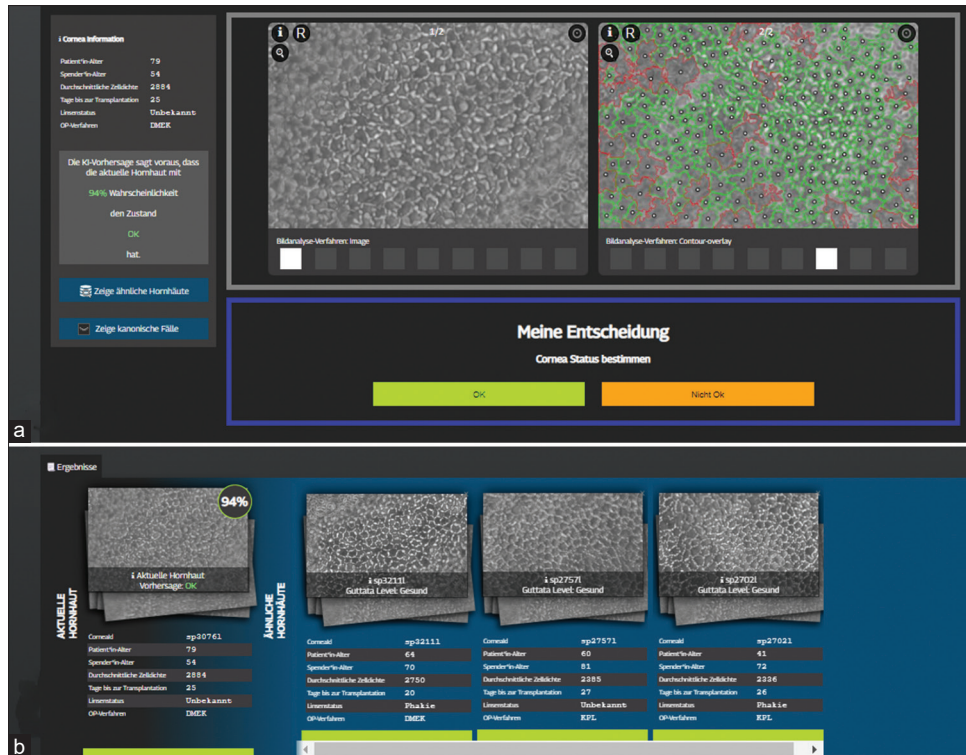
holder, extract background noise, adjust the contrast size, minimize the brightness of the central reflection, and identify the edge of the front and back surfaces of the donor cornea.<sup>[45,46]</sup> The MATLAB software analyzes corneal thickness as well as anterior and posterior radii of curvature at the steep and flat corneal meridian, from which the refractive power is derived.<sup>[45,46]</sup>

Donor tissues presenting curvature anomalies are suspect for previous refractive surgery or corneal ectasia and should be discarded for elective PKP. Nevertheless, they may still be suited for posterior lamellar keratoplasty, such as DMEK or DSAEK, or for tectonic keratoplasty.<sup>[47]</sup>

### Artificial intelligence

Artificial intelligence has shown great potential in medicine, and particularly in ophthalmology, helping, for

example, to detect keratoconus or subclinical glaucoma, or to classify diabetic retinopathy.<sup>[48]</sup> Its role in the field of eye banking is for now more limited but promising. The programmed machine learning algorithms are mostly based on complex neural networks, allowing feature extraction and transformation to improve the software at performing the programmed task. One such feature is the “*case-reasoning system*”, where artificial intelligence compares the information received with database(s) of similar information where a choice or diagnosis has already been made or validated. The *Kittool* [Figure 6] represents a hybrid decision support system based on deep learning and case reasoning algorithms used in eye banks for automated ECC as well as the detection of abnormalities in specular microscopy images, including areas of necrosis and the presence of GC.<sup>[49]</sup> Such support systems could also be developed



**Figure 6:** Automated detection of cornea guttata (CG) in the eye bank using artificial intelligence (AI). Kittool: decision support tool for the detection of CG integrating 2 components: (a) Graphical analytic tools, whereby endothelial cells are processed to generate several cell representations such as “honeycomb” representation for an enhanced visualization of the endothelial layer. (b) Machine learning classifiers including case-based reasoning for AI-based support enable automated CG detection in the eye bank by comparison with previous endothelial cell images with a known postoperative classification of the graft endothelium after keratoplasty

to detect other corneal anomalies, such as abnormal corneal refraction (e.g., post-LASIK) or morphological anomalies (e.g., scars).

### Types of tissue and preparation

In recent years, a marked trend toward lamellar keratoplasties has been observed. This shift toward lamellar surgery, particularly posterior lamellar surgery, can be seen on every continent. In Canada, DMEK currently accounts for 85% of all keratoplasty procedures.<sup>[50]</sup> The same trend is observed in Germany, where DMEK will represent 98.6% of posterior lamellar surgeries, associated with a decrease from 70.2% to 31.7% in PKP between 2011 and 2021.<sup>[5]</sup> In the USA, performed lamellar keratoplasties also dramatically increased, with DSAEK being the most performed lamellar surgery in 2014.<sup>[51]</sup> The proportion of lamellar keratoplasties also increased in China in the past decade, but PKP remains the predominant surgical technique, representing 56.9% at all keratoplasties.<sup>[52]</sup>

Anterior or posterior lamellar surgeries present undeniable advantages in terms of visual rehabilitation and lower immune response rate. However, PKP still remains the technique of choice for emergencies, complicated surgeries, or specific indications.<sup>[4]</sup> This multiplicity of techniques encourages eye banks to adapt

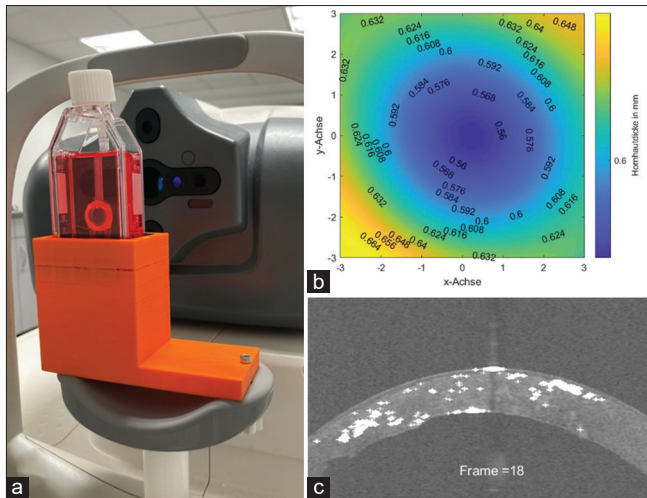
and vary their procedures for graft preparation and storage to meet this increasing demand.

### Penetrating keratoplasty

The PKP was the first and only technique until the end of the 1950s and consists of a plain corneal transplantation. Recipient trephination can be mechanical or nonmechanical. Conventional mechanical trephination is always associated with deformation of the recipient corneal tissue, including deformation of the incised edges, with irregular cut surfaces related to the axial and radial forces induced by the use of the trephine. Nonmechanical trephination includes femtosecond or excimer laser cutting techniques. Significant improvement in postoperative astigmatism can be achieved using the Homburg/Erlangen technique of nonmechanical excimer laser trephination.<sup>[4]</sup> The graft diameter should be individualized according to the specificities of the patient as a compromise between visual rehabilitation and the risk for an immunological reaction (as large as possible but as small as necessary).<sup>[4]</sup>

Mechanical or nonmechanical trephination of the graft is usually performed in the operating room by the surgeon. The role of eye banks before PKP is therefore limited to providing a corneoscleral disc with the best quality possible.





**Figure 7:** Sterile donor tomography in the eye bank. (a) Preoperative measurements of donor corneal tissue are sterilely performed using an anterior segment optical coherence tomography (anterior segment-optical coherence tomography [AS-OCT] – CASIA 2, Tomey, Nagoya, Japan) through their sealed cell culture flask, mounted on the chin rest of the AS-OCT in a holder previously constructed with a three-dimensional (3D) printer (Ultimaker 2 Go, Ultimaker B.V., Geldermalsen, The Netherlands). (b) Self-programmed MATLAB produces a thickness mapping of the donor cornea (thickness displayed in millimeters). Other parameters such as radii of curvature of the anterior and posterior corneal surface are also denoted (not shown). (c) Sterile donor tomography of a donor cornea presenting a granular dystrophy. The MATLAB software is able to generate images and videos with automated detection of the hyperdensities, displayed as white dots (arrow)

### Anterior lamellar keratoplasties

Stromal corneal pathologies and keratoconus, in particular, are typical indications for anterior lamellar keratoplasty. In these cases, DALK has become an increasingly popular alternative compared to PKP.<sup>[53]</sup> Major advantages of DALK are the absence of allograft endothelial immune reaction, as the donor endothelium is not transplanted, and a faster (but not higher!) visual rehabilitation compared to PKP.<sup>[54]</sup>

In this procedure, the recipient's corneal stroma is totally excised, leaving only the endothelium and the Descemet's membrane, with or without pre-Descemet's layer (Dua's layer). Several techniques were developed to dissociate the posterior stroma of the endothelium, including the very popular "big bubble technique" by Anwar *et al.*<sup>[55]</sup> After successful dissection, Descemet's membrane and endothelium of the previously trephined donor cornea are removed. The donor and recipient trephination are usually performed manually but can also be performed with an excimer laser, thus combining the advantages of a DALK<sup>[56]</sup> with the better graft regularity and lower astigmatism of an excimer-assisted procedure for the patient.<sup>[4]</sup> The donor's full-thickness stroma is then positioned against the recipient's Descemet's membrane and sutured using standard techniques for PKP.<sup>[54]</sup>

Tissues preserved in the eye bank but presenting insufficient endothelial cells for PKP or posterior lamellar

surgery may still be selected and prepared for DALK. This allows greater flexibility in tissue management and allocation for eye banks. The rest of the tissue selection process remains identical to PKP and the donor trephination and endothelial dissection is realized in the operating room by the surgeon shortly before or during surgery.

### Posterior lamellar keratoplasties

Posterior lamellar keratoplasty techniques have steadily improved over the past 20 years, allowing rapid visual recovery and fewer immune reactions than PKP.<sup>[56]</sup> Indications for posterior lamellar keratoplasty include diseases of the corneal endothelium with clear or unaffected stroma, with Fuchs' endothelial corneal dystrophy representing the most common indication.

### Descemet's membrane endothelial keratoplasty

DMEK is becoming increasingly popular internationally, especially in Europe, and can also be used in difficult conditions of the anterior segment of the eye.<sup>[5]</sup> In DMEK, only the Descemet's membrane and the corneal endothelium are transplanted.

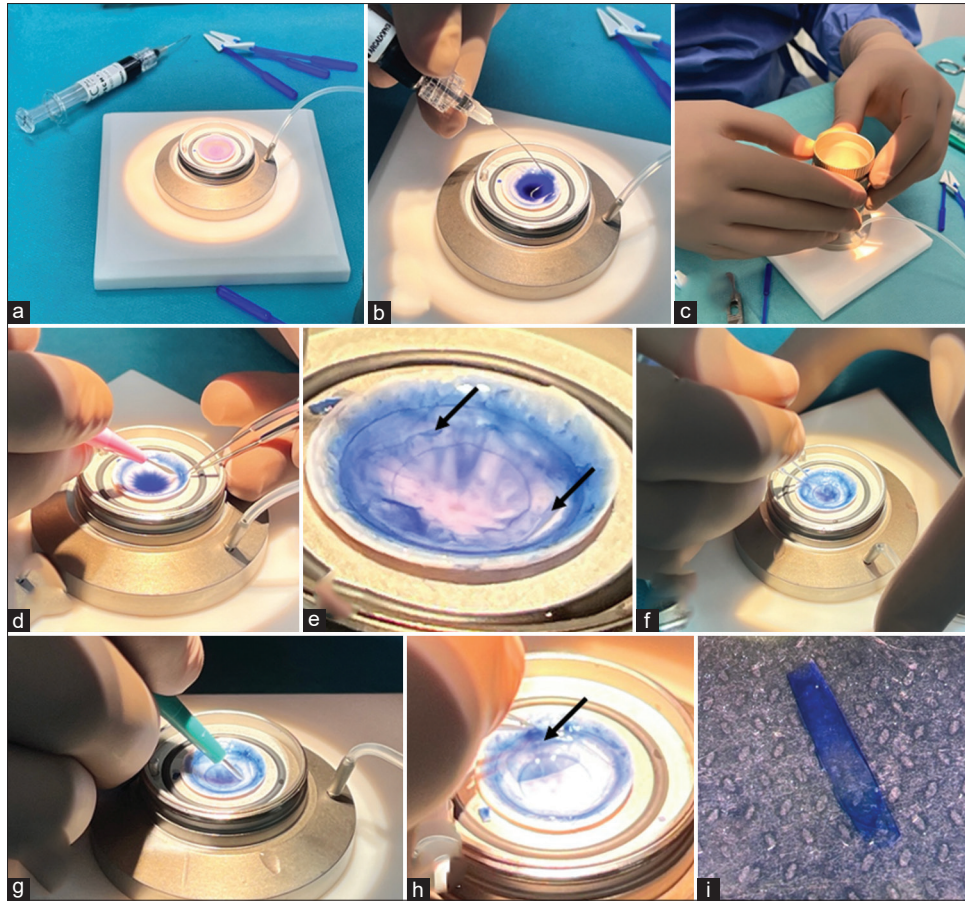
The transplant can/should be prepared before DMEK in the eye bank or in the operating room, with a low risk of membrane rupture that may cause graft loss.<sup>[57]</sup> Several techniques for DMEK donor preparation have been described, such as direct peeling with a microkeratome,<sup>[58]</sup> submerged corneas using the backgrounds away method, where the cornea is submerged in Optisol, balanced salt solution, or organ culture medium to reduce surface tension during the preparation<sup>[59]</sup> or pneumatic dissection. The use of artificial anterior chambers with aspiration or pressurization also proves to be useful to facilitate the dissection [Figure 8].<sup>[60]</sup> Following dissection, the Descemet's membrane with corneal endothelium is prepared to be injected into the anterior chamber by the surgeon in place of the previously removed recipient's affected endothelium (descemetorhexis).<sup>[60]</sup>

### Descemet's stripping automated endothelial keratoplasty

DSAEK is one of the most performed posterior lamellar keratoplasties in North America.<sup>[57]</sup> The technique consists of the removal of Descemet's membrane with endothelial tissue from the recipient and to implant a donor posterior lenticle (<200 μm) composed of posterior stroma, Descemet's membrane, and endothelium. The presence of a stroma-to-stroma interface in DSAEK probably contributes to poorer visual outcomes if compared to DMEK.<sup>[61]</sup>

The donor lenticle can be prepared mechanically using a microkeratome for intrastromal cutting in corneal





**Figure 8:** Preparation of Descemet's membrane endothelial keratoplasty tissue in Homburg/Saar (Germany). (a) The 15-mm corneoscleral slices are placed epithelium down on the suction block (Hanna trephination system; Moria SA, Antony, France), the same also commonly used to prepare DSAEK tissue, to prevent displacement during graft preparation. (b) To improve visualization, Blue Color Caps (BCC, Croma GmbH, Leobendorf, Austria) is instilled into the concave corneoscleral disc, with adequate staining taking approximately 60 s. (c) The future graft size marker is placed under visual control by sliding the trephine down inside the trephine guide cylinder until it touches the surface of the endothelium. Caution: do not perforate! (d and e) To reach the edge of the Descemet's membrane (DM), peripheral lamellar incisions approximately 1.5 mm long (arrows) outside the 7.5 or 8.0 mm mark are made using a razor blade in a hexagonal, heptagonal, or octagonal fashion. (f) Typically, the DM is not only cut with the scalpel but also tears in a curved manner (analogous to the capsulorhexis of the lens). Using a small toothless Tweezer, the DM is grasped radially with very little stretching, and the peripheral edge of the DM (preferably the ruptured area first) is lifted circularly analogous to opening an envelope. (g) Three semicircular marks on the edge of the graft are made with a 1 mm skin trephine, 2 close to each other and 1 at a greater distance. The third mark is located clockwise at a greater distance from the first two marks. This ensures the anterior/posterior orientation of the graft during surgery. (h) The graft (arrow) is delicately entirely removed from the donor stroma. (i) The graft is then placed into a glass container (12 cm × 1 cm) half-filled with organ culture medium without dextran, where it spontaneously coils with varying intensity depending on multiple factors influencing the graft's elasticity. For overnight preservation, the DM is transferred to the original organ culture flask and returned to the cornea bank incubator until surgery.<sup>[60]</sup>

preparation, achieving a lenticle thickness under 200  $\mu\text{m}$ . Cutting techniques with femtosecond laser have been explored to improve the uniformity of the lenticles, which unfortunately resulted in rougher stromal beds and increased irregularity, and therefore, did not achieve the desired visual results.<sup>[62]</sup> Nowadays, ultra-thin lenticles (<130  $\mu\text{m}$ ) are preferred and used for so-called ultra-thin DSAEK. To achieve this thinness, donor corneas undergo two cuts with, first, one thick, followed by one thin microkeratome.<sup>[57]</sup> Before precutting, donor tissue thickness can be assessed using ultrasound pachymetry or, more recently AS OCT to predict microkeratome cut depth and assist in choosing the appropriate microkeratome blade thickness.<sup>[57]</sup> Ultra-thin tissue can also be prepared using a low-pulse energy, high-frequency femtosecond laser.<sup>[63]</sup>

### *Prestripped, precut, and preloaded tissues in eye banks*

Advances in the field of eye banking have resulted in the preparation and validation of "ready-to-use" tissues suitable for elective procedures: precut and preloaded tissues for (UT-)DSAEK and prestripped and preloaded tissues for DMEK.

The use of prestripped or precut tissues offers many advantages for surgeons, such as immediate tissue availability (also in institutions without an eye bank), gain of time, and a reduced surgical complexity of the DMEK or DSAEK surgery. Recent studies showed controversial results comparing eye bank prestripped and surgeon-prepared DMEK grafts. While Regnier *et al.* showed similar outcomes and complication rates between eye bank prestripped and surgeon-prepared grafts,<sup>[64]</sup> Safi

*et al.* described severe endothelial cell loss after prestripping compared to surgeon-prepared DMEK-tissues, with endothelial cell loss reaching up to 23% for prestripped corneas versus 4% for surgeon-prepared corneas after 5 days of storage.<sup>[65]</sup> Prestripped tissues have also shown decreased adhesion forces and elastic modulus, which may contribute to increased rebubbling rates, in comparison to nonprestripped tissues.<sup>[66]</sup>

Preloaded DMEK tissues are generally prestripped and then preloaded in a transport cartridge to be injected by the surgeon,<sup>[67]</sup> comparable to a preloaded intraocular lens (IOL) in cataract surgery [Figure 9]. In recent years, several nontouch DMEK preloading techniques have been developed. These techniques induce less endothelial cell loss than previous preloading techniques, with comparable cell loss as prestripped tissues, and demonstrate the practical aspects of preparing injectable endothelial tissues.<sup>[68]</sup> Preparation (stripping and nontouch loading) immediately before surgery by an experienced surgeon probably ensures the optimum viability of the tissue, but the use of prestripped tissues prepared in eye banks represents a reasonable compromise between tissue quality and organizational constraints.<sup>[60]</sup>

Concerning (UT-)DSAEK, laboratory data on the biomechanics of DSAEK grafts suggest that surgeon-cut DSAEK grafts present higher elastic modulus and adhesion force than eye bank-prepared DSAEK grafts.<sup>[69]</sup> Nonetheless, this finding presents no practical implications for DSAEK, given that precut tissues provided similar visual and refractive outcomes, rebubbling rates, and endothelial cell loss after 12 months as non-precut tissues.<sup>[70]</sup>

## Conclusions

To cope with the increasing demand for corneal tissues and new challenges in terms of tissue selection, the

activities of eye banks have been refocused on larger structures with more resources, allowing optimal preservation conditions as well as a better selection and preparation of tissues. These large structures are in charge to prepare tissues for external institutions by developing “ready-to-use” tissues. This trend is expected to grow in future due to its economic and logistical advantages. Nevertheless, these practices tend to change eye banks into “market places” for surgeons, a development that presents risks of unequal access to “good quality” tissue for all institutions and could fragilize the relationship between patients, surgeons, and eye banks.


In terms of preservation, hypothermic storage and longer storage currently remain the two major storage methods in eye banks. The development of new screening techniques, such as the sterile donor tomography or the rise of artificial intelligence and convolutional neural networks, for example, for the detection of CG, should enable the automation and better efficiency of tissue selection processes in eye banks. These recent advances promise even more developments in the field of eye banking in the near future.

## Data availability statement

The datasets generated during and/or analyzed during the current study are not publicly available, but are available from the corresponding author on reasonable request.

## Declaration of patient consent

The authors certify that they have obtained appropriate consent forms from the legal guardians of the patient. In the form, the guardians have given the consent for the images and other clinical information of the patient to be reported in the journal. The guardians understand that the names and initials of the patient will not be published



**Figure 9:** Prestripped and preloaded tissue for Descemet’s membrane endothelial keratoplasty (DMEK). (a) Culture flask with a trypan blue-stained and preloaded DMEK lamella (arrow) within a transport cartridge before shipping. (b) Discolored tissue (arrow) after 48 h storage and shipping. (c) The graft needs to be restained with trypan blue (arrow) within the transport cartridge before surgery<sup>[65]</sup>

and due efforts will be made to conceal the identity, but anonymity cannot be guaranteed.

### Acknowledgment

- The authors thank Dr. Annkathrin Rickman and Springer Nature for the permission to republish Figure 8
- The authors thank Ms. Christina Turner (director's assistant and in charge of the publication and education pool, Department of Ophthalmology, Saarland University Medical Center [UKS], Homburg/Saar, Germany) who reviewed the first draft of the manuscript and ensured correct English.

### Financial support and sponsorship

Nil.

### Conflicts of interest

The authors declare that there are no conflicts of interest in this paper.

## References

1. European Eye Bank Association (EEBA). Technical Guidelines for Ocular Tissue (TGOT). EEBA; 2020. Available from: [https://www.eeba.eu/files/pdf/EEBA\\_Technical\\_Guidelines\\_for\\_Ocular\\_Tissue\\_Revision11.pdf](https://www.eeba.eu/files/pdf/EEBA_Technical_Guidelines_for_Ocular_Tissue_Revision11.pdf). [Last accessed on 2023 Aug 09].
2. Anitha V, Tandon R, Shah SG, Radhakrishnan N, Singh S, Murugesan V, *et al*. Corneal blindness and eye banking: Current strategies and best practices. *Indian J Ophthalmol* 2023;71:3142-8.
3. Gain P, Jullienne R, He Z, Aldossary M, Acquart S, Cognasse F, *et al*. Global survey of corneal transplantation and eye banking. *JAMA Ophthalmol* 2016;134:167-73.
4. Seitz B, Daas L, Milioti G, Szentmàry N, Langenbucher A, Suffo S. Excimer laser-assisted penetrating keratoplasty: On 1 July 2019 excimer laser penetrating keratoplasty celebrates its 30<sup>th</sup> anniversary. Video article. *Ophthalmologie* 2019;116:1221-30.
5. Flockerzi E, Turner C, Seitz B, Collaborators GS, GeKeR Study Group. Descemet's membrane endothelial keratoplasty is the predominant keratoplasty procedure in Germany since 2016: A report of the DOG-section cornea and its keratoplasty registry. *Br J Ophthalmol* 2023;bjo-2022-323162 [online ahead of print].
6. Molter Y, Milioti G, Langenbucher A, Seitz B. Appearance, recurrence and prognosis of immunological graft rejection after penetrating keratoplasty. *Ophthalmologie* 2020;117:548-56.
7. Hata B. The development of glioma in the eye to which the cornea of a patient, who suffered from glioma, was transplanted. *Acta Soc Ophthalmol Jap* 1939;43:1763-7.
8. Armitage WJ, Tullo AB, Ironside JW. Risk of Creutzfeldt-Jakob disease transmission by ocular surgery and tissue transplantation. *Eye (Lond)* 2009;23:1926-30.
9. Caron MJ, Wilson R. Review of the risk of HIV infection through corneal transplantation in the United States. *J Am Optom Assoc* 1994;65:173-8.
10. Armitage WJ. Preservation of human cornea. *Transfus Med Hemother* 2011;38:143-7.
11. Heck E, Brown A, Cavanagh HD. Nucleic acid testing and tissue safety: An eye bank's five-year review of HIV and hepatitis testing for donor corneas. *Cornea* 2013;32:503-5.
12. Kalus U, Wilkemeyer I, Caspari G, Schroeter J, Pruss A. Validation of the serological testing for Anti-HIV-1/2, Anti-HCV, HBsAg, and Anti-HBc from post-mortem blood on the siemens-BEP-III automatic system. *Transfus Med Hemother* 2011;38:365-72.
13. Martin C, Tschernig T, Loic H, Daas L, Seitz B. Corneae from body donors in anatomy department: Valuable use for clinical transplantation and experimental research. *BMC Ophthalmol* 2020;20:284.
14. Filev F, Bigdon E, Steinhorst NA, Kammal A, Schröder C, Wulff B, *et al*. Donor cornea harvest techniques: Comparison between globe enucleation and *in situ* corneoscleral disc excision. *Cornea* 2018;37:957-63.
15. Li S, Bischoff M, Schirra F, Langenbucher A, Ong M, Halfmann A, *et al*. Correlation between microbial growth in conjunctival swabs of corneal donors and contamination of organ culture media. *Ophthalmologie* 2014;111:553-9.
16. Wykrota AA, Weinstein I, Hamon L, Daas L, Flockerzi E, Suffo S, *et al*. Approval rates for corneal donation and the origin of donor tissue for transplantation at a university-based tertiary referral center with corneal subspecialization hosting a LIONS eye bank. *BMC Ophthalmol* 2022;22:17.
17. Pels E, Rijnneveld WJ. Organ culture preservation for corneal tissue. Technical and quality aspects. *Dev Ophthalmol* 2009;43:31-46.
18. Toniolo M, Camposampiero D, Griffoni C, Jones GL. Quality management in European Eye Banks. *Dev Ophthalmol* 2009;43:70-86.
19. Laun D, Suffo S, Kramp K, Bischoff M, Huber M, Langenbucher A, *et al*. How implementing a quality management system at the LIONS eye bank Saar-Lor-Lux, trier/Western palatinate from 2006 to 2016 impacted the rate and reasons for discarding human organ-cultured corneas. *Klin Monbl Augenheilkd* 2022;239:717-23.
20. Filatov VP. Transplantation of the cornea. *Arch Ophthalmol* 1935;13:321-47.
21. O'Neill P, Mueller FO, Trevor-Roper PD. On the preservation of corneae at -196 degrees C. For full-thickness homografts in man and dog. *Br J Ophthalmol* 1967;51:13-30.
22. Rodríguez-Fernández S, Álvarez-Portela M, Rendal-Vázquez E, Piñero-Ramil M, Sanjurjo-Rodríguez C, Castro-Viñuelas R, *et al*. Analysis of cryopreservation protocols and their harmful effects on the endothelial integrity of human corneas. *Int J Mol Sci* 2021;22:12564.
23. Hamon L, Bayyoud T, Seitz B. Ocular findings in patients with COVID-19: Impact on eye banking [Letter]. *Clin Ophthalmol* 2021;15:2051-2.
24. Chaurasia S, Das S, Roy A. A review of long-term corneal preservation techniques: Relevance and renewed interests in the COVID-19 era. *Indian J Ophthalmol* 2020;68:1357-63.
25. McCarey BE, Kaufman HE. Improved corneal storage. *Invest Ophthalmol* 1974;13:165-73.
26. Pels E, Beele H, Claerhout I. Eye bank issues: II. Preservation techniques: Warm versus cold storage. *Int Ophthalmol* 2008;28:155-63.
27. Doughman DJ, Harris JE, Schmitt MK. Penetrating keratoplasty using 37 C organ cultured cornea. *Trans Sect Ophthalmol Am Acad Ophthalmol Otolaryngol* 1976;81:778-93.
28. Lindstrom RL, Doughman DJ, Skelnik DL, Mindrup EA. Minnesota system corneal preservation. *Br J Ophthalmol* 1986;70:47-54.
29. Abdin A, Daas L, Pattmüller M, Suffo S, Langenbucher A, Seitz B. Negative impact of dextran in organ culture media for pre-stripped tissue preservation on DMEK (Descemet membrane endothelial keratoplasty) outcome. *Graefes Arch Clin Exp Ophthalmol* 2018;256:2135-42.
30. Hamon L, Daas L, Mäurer S, Weinstein I, Quintin A, Schulz K, *et al*. Thickness and curvature changes of human corneal grafts in dextran-containing organ culture medium before keratoplasty. *Cornea* 2021;40:733-40.
31. Valtink M, Donath P, Engelmann K, Knels L. Effect of different culture media and deswelling agents on survival of human corneal endothelial and epithelial cells *in vitro*. *Graefes Arch Clin Exp*



- Ophthalmol 2016;254:285-95.
32. Zhao M, Campolmi N, Thuret G, Piselli S, Acquart S, Peoc'h M, *et al.* Poloxamines for deswelling of organ-cultured corneas. *Ophthalmic Res* 2012;48:124-33.
  33. Garcin T, Gauthier AS, Crouzet E, He Z, Herbepin P, Perrache C, *et al.* Three-month storage of human corneas in an active storage machine. *Transplantation* 2020;104:1159-65.
  34. Batista A, Breunig HG, König A, Schindele A, Hager T, Seitz B, *et al.* Assessment of human corneas prior to transplantation using high-resolution two-photon imaging. *Invest Ophthalmol Vis Sci* 2018;59:176-84.
  35. Clover J. Slit-lamp biomicroscopy. *Cornea* 2018;37 Suppl 1:S5-6.
  36. Schroeter J, Rieck P. Endothelial evaluation in the cornea bank. *Dev Ophthalmol* 2009;43:47-62.
  37. Sperling S. Evaluation of the endothelium of human donor corneas by induced dilation of intercellular spaces and trypan blue. *Graefes Arch Clin Exp Ophthalmol* 1986;224:428-34.
  38. Schönit S, Maamri A, Zemova E, Munteanu C, Safi T, Daas L, *et al.* Prevalence and impact of cornea guttata in the graft after penetrating keratoplasty in Germany. *Cornea* 2022;41:1495-502.
  39. Schmitz LM, Safi T, Munteanu C, Seitz B, Daas L. Prevalence and severity of cornea guttata in the graft following descemet membrane Endothelial Keratoplasty (DMEK). *Acta Ophthalmol* 2022;100:e1737-45.
  40. Safi T, Daas L, Kiefer GL, Sharma M, Ndiaye A, Deru M, *et al.* Semiquantitative criteria in the Eye bank that correlate with cornea guttata in donor corneas. *Klin Monbl Augenheilkd* 2021;238:680-7.
  41. Kang SJ, Schmack I, Edelhauser HF, Grossniklaus HE. Donor corneas misidentified with prior laser *in situ* keratomileusis. *Cornea* 2010;29:670-3.
  42. Quintin A, Hamon L, Langenbucher A, Seitz B. *In situ* donor keratometry in deceased patients as a novel screening technique for Eye banking. *Graefes Arch Clin Exp Ophthalmol* 2023;261:1619-25.
  43. Quintin A, Hamon L, Mäurer S, Langenbucher A, Seitz B. OCT application for sterile corneal graft screening in the eye bank. *Klin Monbl Augenheilkd* 2021;238:688-92.
  44. Hamon L, Quintin A, Mäurer S, Weinstein I, Langenbucher A, Seitz B, *et al.* Reliability and efficiency of corneal thickness measurements using sterile donor tomography in the eye bank. *Cell Tissue Bank* 2022;23:695-706.
  45. Mäurer S, Asi F, Rawer A, Damian A, Seitz B, Langenbucher A, *et al.* Concept for 3D measurement of corneal donor tissue using a clinical OCT. *Ophthalmologe* 2019;116:640-6.
  46. Damian A, Seitz B, Langenbucher A, Eppig T. Optical coherence tomography-based topography determination of corneal grafts in eye bank cultivation. *J Biomed Opt* 2017;22:16001.
  47. Seitz B, Asi F, Mäurer S, Hamon L, Quintin A, Langenbucher A. Anterior segment OCT: Application to improve graft selection for corneal transplantation. In: Alió JL, Alió del Barrio JL, editors. *Atlas of Anterior Segment Optical Coherence Tomography*. Cham: Springer; 2021. p. 223-36.
  48. Nuzzi R, Boscia G, Marolo P, Ricardi F. The impact of artificial intelligence and deep learning in eye diseases: A review. *Front Med (Lausanne)* 2021;8:710329.
  49. Kiefer GL, Safi T, Nadig M, Sharma M, Sakha MM, Ndiaye A, *et al.* An AI-based decision support system for quality control applied to the use case donor cornea. In: Degen H, Ntoa, S. editors, *Artificial Intelligence in HCI. HCII 2022: Lecture Notes in Computer Science*. Vol. 13336. Cham: Springer; 2022.
  50. Chan SW, Yucl Y, Gupta N. New trends in corneal transplants at the University of Toronto. *Can J Ophthalmol* 2018;53:580-7.
  51. Park CY, Lee JK, Gore PK, Lim CY, Chuck RS. Keratoplasty in the United States: A 10-year review from 2005 through 2014. *Ophthalmology* 2015;122:2432-42.
  52. Zhao S, Wan X, Yao W, Xu J, Le Q. Trends of corneal transplantation in adults from 2010 to 2019 in East China: A 10-year experience. *Ophthalmic Res* 2022;65:30-9.
  53. Muraine M, Toubeau D, Gueudry J, Brasseur G. Impact of new lamellar techniques of keratoplasty on eye bank activity. *Graefes Arch Clin Exp Ophthalmol* 2007;245:32-8.
  54. Krumeich JH, Knülle A, Krumeich BM. Deep anterior lamellar (DALK) versus. Penetrating keratoplasty (PKP): A clinical and statistical analysis. *Klin Monbl Augenheilkd* 2008;225:637-48.
  55. Anwar M, Teichmann KD. Big-bubble technique to bare Descemet's membrane in anterior lamellar keratoplasty. *J Cataract Refract Surg* 2002;28:398-403.
  56. Daas L, Hamon L, Ardjomand N, Safi T, Seitz B. Excimer laser-assisted DALK: A case report from the homburg keratoconus center (HKC). *Ophthalmologe* 2021;118:1245-8.
  57. Boynton GE, Woodward MA. Eye-bank preparation of endothelial tissue. *Curr Opin Ophthalmol* 2014;25:319-24.
  58. Yoeruek E, Bartz-Schmidt KU. Novel surgical instruments facilitating descemet membrane dissection. *Cornea* 2013;32:523-6.
  59. Price MO, Giebel AW, Fairchild KM, Price FW Jr. Descemet's membrane endothelial keratoplasty: Prospective multicenter study of visual and refractive outcomes and endothelial survival. *Ophthalmology* 2009;116:2361-8.
  60. Seitz B, Daas L, Flockerzi E, Suffo S. Descemet membrane endothelial keratoplasty DMEK – Donor and recipient step by step. *Ophthalmologe* 2020;117:811-28.
  61. Tourtas T, Laaser K, Bachmann BO, Cursiefen C, Kruse FE. Descemet membrane endothelial keratoplasty versus descemet stripping automated endothelial keratoplasty. *Am J Ophthalmol* 2012;153:1082-90.
  62. Vetter JM, Butsch C, Faust M, Schmidtmann I, Hoffmann EM, Sekundo W, *et al.* Irregularity of the posterior corneal surface after curved interface femtosecond laser-assisted versus microkeratome-assisted descemet stripping automated endothelial keratoplasty. *Cornea* 2013;32:118-24.
  63. Phillips PM, Phillips LJ, Saad HA, Terry MA, Stolz DB, Stoeger C, *et al.* "UlthraThin" DSAEK tissue prepared with a low-pulse energy, high-frequency femtosecond laser. *Cornea* 2013;32:81-6.
  64. Regnier M, Auxenfans C, Maucort-Boulch D, Marty AS, Damour O, Burillon C, *et al.* Eye bank prepared versus surgeon cut endothelial graft tissue for descemet membrane endothelial keratoplasty: An observational study. *Medicine (Baltimore)* 2017;96:e6885.
  65. Safi T, Seitz B, Berg K, Schulz K, Langenbucher A, Daas L. Reproducibility of non-invasive endothelial cell loss assessment of the pre-stripped DMEK roll after preparation and storage. *Am J Ophthalmol* 2021;221:17-26.
  66. Romano V, Kazaili A, Pagano L, Gadhvi KA, Titley M, Steger B, *et al.* Eye bank versus surgeon prepared DMEK tissues: Influence on adhesion and re-bubbling rate. *Br J Ophthalmol* 2022;106:177-83.
  67. Rickmann A, Wahl S, Hofmann N, Knakowski J, Haus A, Börgel M, *et al.* Comparison of preloaded grafts for descemet membrane endothelial keratoplasty (DMEK) in a novel preloaded transport cartridge compared to conventional precut grafts. *Cell Tissue Bank* 2020;21:205-13.
  68. Català P, Vermeulen W, Rademakers T, van den Bogaerdt A, Kruijt PJ, Nuijts RM, *et al.* Transport and preservation comparison of preloaded and prestripped-only DMEK grafts. *Cornea* 2020;39:1407-14.
  69. Romano V, Parekh M, Kazaili A, Steger B, Akhtar R, Ferrari S, *et al.* Eye bank versus surgeon prepared descemet stripping automated endothelial keratoplasty tissues: Influence on adhesion force in a pilot study. *Indian J Ophthalmol* 2022;70:523-8.
  70. Pagano L, Gadhvi KA, Coco G, Fenech M, Titley M, Levis HJ, *et al.* Re-bubbling rate in preloaded versus surgeon prepared DSAEK. *Eur J Ophthalmol* 2022;32:880-4.