

Guide sheath-assisted ureteroscope lithotripsy for upper ureteral calculi: An observational study on 81 cases

JIA-SHENG HU, GUO-HAI XIE, HE-SHENG YUAN, GUAN-LIN LIU,
XIAO-LONG JIA, ZHONG ZHENG and YUE CHENG

Department of Urology, Ningbo First Hospital, Ningbo, Zhejiang 315000, P.R. China

Received June 26, 2017; Accepted June 1, 2018

DOI: 10.3892/etm.2018.6620

Abstract. The present study assessed the clinical efficacy of guide sheath-assisted ureteroscope lithotripsy in the treatment of upper ureteral calculi. A total of 81 patients with upper ureteral calculi underwent ureteroscope lithotripsy assisted by a guide sheath between January 2012 and June 2014; of these, 63 patients were successfully treated with simple rigid ureteroscope lithotripsy assisted by a ureteral access sheath, and 18 patients were successfully treated with rigid and flexible ureteroscope lithotripsy assisted by a guide sheath. At 1 day after the surgery, ultrasound examination of kidneys, ureters and bladder, and urinary system computed tomography were used to re-check for residual stones, and 69 patients had stones with a diameter of <2 mm in the renal pelvis, while 12 had stones of 2-4 mm in diameter. The operation time was 30-115 min (average, 56.0±4.8 min); all patients underwent a successful surgical procedure. A total of 7 patients had an elevated temperature 37.4-39.1°C (mean temperature, 37.7±0.3°C) after the surgery, but no other major complications were noted. After 1 month, the residual stones were completely discharged, so that the stone clearance rate was 100%. All patients were followed up for 3-12 months and no associated complications occurred. Overall, ureteroscope lithotripsy assisted by a guide sheath for the treatment of upper ureteral calculi had the benefit of water injection and reflux functions, as well as enhanced vision, reduced pressure within the renal pelvis, good discharge of stones as well as an improved efficiency and success rate compared with simple ureteroscopic lithotripsy.

Introduction

Upper ureteral calculi are a common ailment encountered at urology departments, and they have a long embedding time and

easily induce secondary conditions, including oedema in the ureteric wall, chronic inflammatory diseases and inflammatory polyps (1). These diseases develop and involve the tissues around the ureter, resulting in serious ureteral obstruction (1).

Surgery is the most efficient treatment for upper ureteral calculi (2). However, in specific cases, the embedded stones have large volumes and adhere to the ureteric wall, thus increasing the difficulty of the operation for upper ureteral calculi and resulting in limitations (2). Furthermore, the therapeutic methods for upper ureteral calculi are complicated as the ureteroscope, soft lenses and percutaneous nephrolithotripsy (PCN) have advantages and disadvantages (2). Upper segment stones are easily washed into the pelvis during ureteroscopy, increasing the surgical difficulty of this procedure. The soft lens can be utilized to treat upper ureteral calculi; however, due to its fragile nature, it is easily damaged and therefore often associated with increased surgical costs. PCN exhibits high lithotripsy efficiency coupled with various risk factors. Rigid ureteroscopy exhibited poor outcomes for the treatment of upper ureteral calculi. Due to the stone obstructing the ureteral cavity, drainage of the fluids used for flushing is hindered and a larger pressure is required for the process, which has the potential of moving the stone into the wrong direction (3,4). PCN suggested better curative effects with 90.09% success rate of lithotripsy (5), but causes a larger surgical wound and bears risks of haemorrhage, haemopneumothorax, sepsis and peripheral tissue injury during or following surgery. Soft ureteroscopy treatment has improved safety and effects to the upper ureteral calculi, but requires highly trained surgeons to treat ureteral incarcerated stones. Complications, including bleeding, may occur during surgery by damaging the ureteral wall. A combination of hard and soft lens may combine advantages to reduce surgical complications and significantly improve the surgical efficiency.

In the present study, ureteroscope lithotripsy assisted by a guide sheath was used to treat upper ureteral calculi in order to improve the vision, to increase the efficiency of lithotripsy and to decrease the difficulty of the operation and the occurrence of complications.

Correspondence to: Dr Yue Cheng, Department of Urology, Ningbo First Hospital, 59 Liu Ting Street, Haishu, Ningbo, Zhejiang 315000, P.R. China
E-mail: chengyue_06@163.com

Key words: ureteroscopy, lithotripsy, guide sheath, upper ureteral calculi

Patients and methods

Patients. A total of 81 patients with upper ureteral calculi who were treated at Ningbo First Hospital (Ningbo, China) between

January 2012 and June 2014 were included in the present observational study. The data collected included patient age, sex and body mass index as well as medical history, including diabetes mellitus, vascular disease and pelvic radiation. Patients with pelvic radiation history were excluded. The cohort was comprised of 57 males and 24 females aged 25-71 years, with an average age of 43.4 ± 12.9 years.

The inclusion criteria were as follows: i) The embedding time in the same region was >2 months (6); ii) the calculi caused serious kidney hydronephrosis, which was confirmed according to the standard clinical criteria (7); and iii) extracorporeal shock wave lithotripsy (ESWL) therapy failed. The exclusion criteria were as follows: Patients who had undergone local radiotherapy or who had a history of retroperitoneal surgery, which may lead to ureterostenosis. Overall, 46 patients had left ureteral calculi, while 35 patients had right ureteral calculi, which is presented in Table I. The diameters of the stones were 7-25 mm. Stones from 57 patients were ≥ 1.5 cm in diameter, while 24 patients had stones <1.5 cm.

Treatments. All procedures were performed with the patient under general intravertebral anesthesia in a standard lithotomy position. A rigid ureteroscope (hard lens type, F8/8.9; Richard Wolf GmbH, Knittlingen, Germany) was inserted into the ureter by using a Zebra urological guide-wire (Zibo Qianyan Medical Instrument Co., Ltd., Zibo, China). The ureteroscope and the guide-wire were placed at the lower end of the stones. The rigid ureteroscope was placed outside and the guide sheath (type, F12/14; length, 35 cm) (Cook Medical, Bloomington, IN, USA) was placed along the guide-wire.

According to body surface measurement and judgment of the distance between the stones and the ureter, the guide sheath was placed to avoid one step. The length of the sheath placed into the ureter was adjusted according to the method described in a previous study (8). When the sheath was in direct proximity to the stones, the inner core was removed, and the small ureteroscope (Richard Wolf GmbH, Knittlingen, Germany) was placed (hard lens type, F/6.5/7; Fig. 1)

The placement of the guide sheath and the condition of the upper ureter were observed along the guide sheath. The guide sheath was placed close to the lower part of the stones. Subsequently, holmium laser lithotripsy was performed (Fig. 2).

During the holmium laser lithotripsy, the placements and methods were determined according to methods described in a previous study (9). Gradual lithotripsy was performed with high frequency and low power (20 W, 1.0 J x 20 Hz). The frequency and power were adjusted according to stone hardness. For larger stones refluxing to the renal pelvis, a soft ureteroscope was used with methods similar to those for the rigid ureteroscope. During lithotripsy, part of the stone was treated using an ureteroscopic basket. The soft ureteroscope was used with a distorted or thin ureter. The stones were directly fragmented by lithotripsy. Double J-tube stenting was performed subsequent to surgery. Ultrasound examination of kidneys, ureters and bladder (KUB) or urinary system computed tomography (CT) was re-performed after one month in order to confirm the absence of any residual stones and to withdraw the D-J tube. All patients were followed up for 3-12 months.

Statistical analysis. All data are expressed as the mean \pm standard deviation. Statistical analysis was performed with SPSS 20.0 software (IBM Corp., Armonk, NY, USA) and Student's t-test was used to compare the proportion of patients treated by simple rigid ureteroscope lithotripsy assisted with ureteral access sheath and those treated with rigid and flexible ureteroscope lithotripsy assisted with guide sheath.

Results

Surgery effects. A total of 63 patients were successfully treated with rigid ureteroscope lithotripsy assisted by a ureteral access sheath, while 18 patients were successfully treated with rigid and flexible ureteroscope lithotripsy assisted by a guide sheath (Table I).

A number of broken stones were washed out the ureteral dilated sheath (Fig. 3). The majority of patients 77.8% (63/81) with incarcerated calculi of the upper ureter were treated with hard lens accompanied with ureteral dilated sheath. If treatment by hard lens only was not advisable, it was combined with the soft lens to improve the surgical success rate. During surgery, changing the flushing pressure aided removing partial stones from the ureteral dilated sheath and furthered the overall decrease of stones.

At 1 day after surgery, KUB and urinary system CT scans were performed. The D-J tubes were well-placed in all cases. A total of 69 patients had residual calculi in the renal pelvis that were <2 mm, while the residual calculi were 2-4 mm in 12 patients. In all of the patients, the calculi were completely discharged after 1 month, with a stone clearance rate of 100% (Table I). Patients exhibited a better response to lithotripsy and shattered residual stones (<4 mm) were discharged following surgery.

Complications. The proportion of patients treated by simple rigid ureteroscope lithotripsy assisted with ureteral access sheath (63/81) was significantly higher than that of patients treated by rigid and flexible ureteroscope lithotripsy assisted with a guide sheath (18/81; $P < 0.01$). The operation time ranged between 30 and 115 min (average, 56 ± 4.8 min; Table I). A total of 7 patients had an elevated body temperature 37.4 - 39.1°C (mean temperature, $37.7 \pm 0.3^\circ\text{C}$) after surgery (Table I), which may indicate poor infection control prior to surgery, but no other complications were encountered. During or after surgery, no obvious bleeding occurred, conversion to percutaneous nephrolithotomy (PCNL) or open surgery was not required in any of the cases and no inter-operative complications, including urethral perforation or visceral injury, occurred. The 7 patients who developed an elevated temperature after the operation were treated by anti-infective therapy and they recovered without any other complications. All patients were followed up for 3-12 months and no associated complications, including ureterostenosis or atresia of the ureter, occurred (Table I).

Discussion

Due to the long course of embedding and the irritation by the upper ureteral calculi, a series of immune reactions in the body may easily lead to inflammatory polyps or stricture in

Table I. Clinical data for all patients (n=81) and safety and outcome measures.

Parameter	Value
Sex	
Male	57 (70.4%)
Female	24 (29.3%)
Age (years)	43.4±12.9 (25-71)
Body mass index mg/m ²	21.0±2.0
Diabetes	7 (8.6%)
Hypertension	9 (11.1%)
Pelvic radiation (Gy)	30±5
Left ureteral calculi	46
Right ureteral calculi	35
Diameter of calculi (mm)	7-25
Mode of surgery	
Simply rigid ureteroscope lithotripsy assisted with ureteral access sheath	63 ^a
Rigid and flexible ureteroscope lithotripsy assisted with guide sheath	18
Operation time (min)	56.0±4.8 (30-115)
Complications	
Post-operative fever 37.4-39.1°C (mean, 37.7±0.3°C)	7
Ureteral perforation	0
Conversion to PCNL or open surgery	0
Peripheral organ injury	0
Ureteral avulsion	0
Residual stone diameter in the renal pelvis after surgery	
<2 mm	69 ^b
2-4 mm	12
Stone-free rate at 1 month after surgery	81 (100%)

Values are expressed as n(%) or as the mean ± standard deviation (range) unless otherwise indicated. ^aP<0.01, simply rigid ureteroscope lithotripsy assisted with ureteral access sheath vs. rigid and flexible ureteroscope lithotripsy assisted with guide sheath; ^bP<0.01, residual stone in the renal pelvis sized <2 mm vs. 2-4 mm; PCNL, percutaneous nephrolithotomy.

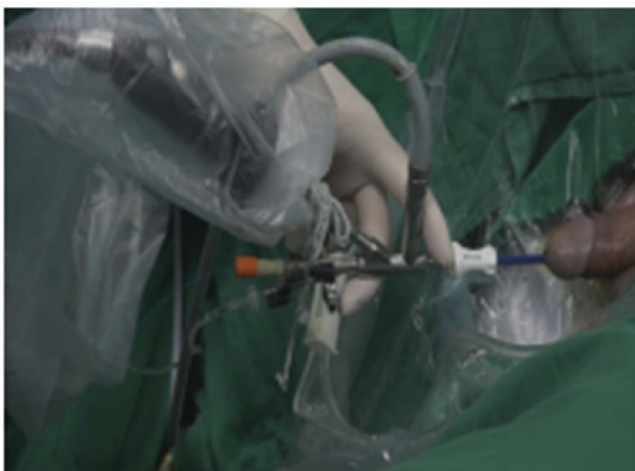


Figure 1. Placing of the ureteroscope sheath.

the ureter around the stones (10). Surgery is the major therapy for upper ureteral calculi, with techniques including rigid ureteroscope lithotripsy, open surgery under retroperitoneal laparoscopy and soft ureteroscope lithotripsy.

Rigid ureteroscope lithotripsy used on upper ureteral calculi may lead to complications, including stones blocking the ureter, non-smooth drainage of flushing liquid requiring enhanced power and stones moving up, and its application is limited (3,4). Multiple turnovers are required to withdraw stones, which is associated with a risk of serious complications, including mucous membrane injury and avulsion (11,12). Post-processing of the retained renal calculi is also challenging (13). Gdor *et al* (14) reported a success rate of endoscopic treatment of upper ureteral calculi of only 56%. The minimally invasive nephroscope treatment had a higher efficiency for upper ureteral calculi, with a success rate of 90.9% (5). However, injury to kidney tissue resulted in larger trauma and even serious injury, including bleeding, hemo-pneumothorax, hematosepsis and tissue injury. Lin *et al* (15) analyzed 528 patients who received PCNL treatment for upper ureteral calculi, of which 17 patients experienced bleeding during surgery, 2 patients had pleural effusion, 1 patient had colon perforation, 8 patients had an elevated temperature and 3 patients had seroperitoneum. The rate of complications was 5.8%. During open surgery with retroperitoneal laparoscopy, the stones were completely withdrawn, but retroperitoneal

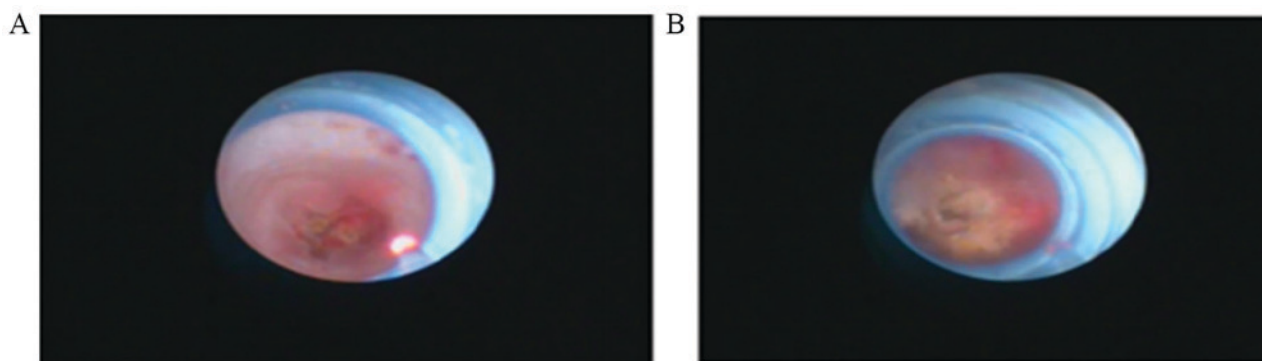


Figure 2. Lower part of the calculi. Ureteral fine lens F6/7.5; magnification, x20. Head end of ureteral dilated sheath was located in the lower part of the upper ureteral calculi and the ureteral fine lens reached the stone by dilated sheath. (A) Ureteral dilatation sheath put in place during surgery. (B) Lithotripsy using a holmium laser.

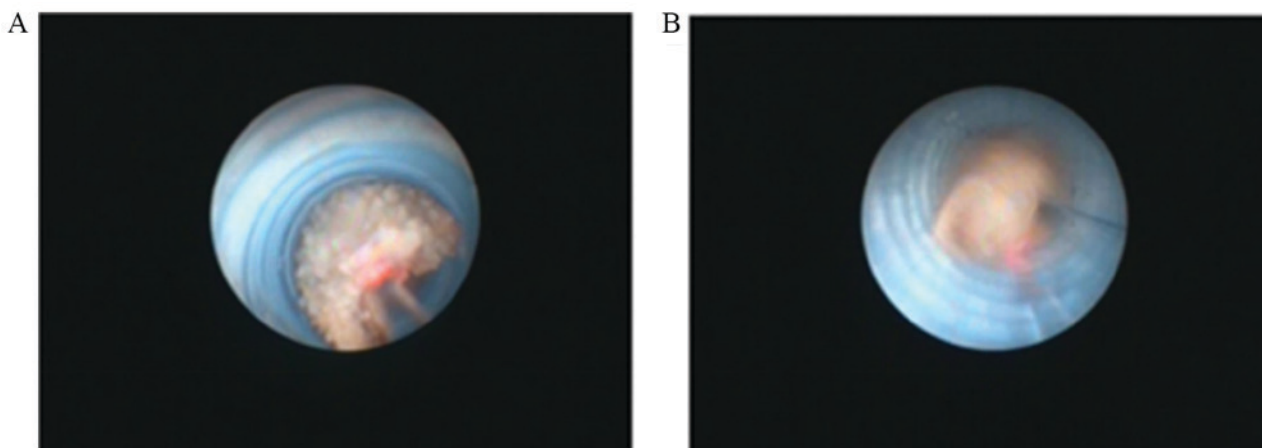


Figure 3. Guide sheath withdrawing calculi. Ureteral fine lens F6/7.5; magnification, x20. Utilizing the flushing pressure, shattered stones washed out through the Ureteral dilated sheath. (A) Stones in ureteral dilated sheath were broken down by holmium laser lithotripsy. (B) Shattered stones were washed off the ureteral dilated sheath.

laparoscopic surgery is performed in a narrow space and the incidence of complications, including urinous infiltration and ureterostenosis. Due to the surgical incision into the ureteral cavity, there was a risk of urine leakage.

Compared with the hard lens, the soft ureteroscope has a better safety and efficiency in treating upper ureteral calculi. As the calculi was located in the ureter and the soft lens allowed surgery in narrow space, a more advanced technique was required. The use of soft lenses usually causes inflammatory polyps and poses a limitation during the operation. It easily causes bleeding and ureteral wall injury, leading to fail of operation.

In the present study, ureteroscopy lithotripsy assisted by a guide sheath was used for treating upper ureteral calculi. During the surgery, injection and refluxing of liquid was facilitated due to improved vision. For the placement of the guide sheath, a larger space between the ureteroscope and the guide sheath was available, which was beneficial for the flow of the flushing liquid. Auge *et al* (16) reported that the guide sheath in the ureter was helpful for reducing the pressure in the renal pelvis by 57-75%, as well as decreasing stone refluxing. The assistance of the ureteric guide sheath had certain advantages leading to an improved success rate and efficiency of the operation. According to Breda *et al* (17), the ureteral access sheath is highly recommended for the treatment of

upper urinary tract disease by means of retrograde intrarenal surgery, during which the lower part of the calculus usually causes distortion or partial stricture, resulting in difficulty in using the rigid ureteroscope. In the present study, the placement of the guide sheath straightened the ureteral lumen to a certain extent, which was convenient during surgery, as the ureteral sheath tightly connected to ureteral wall and stretching of the sheath aided to straighten the ureteral cavity during surgery.

The increasing pressure of the flushing liquid facilitated the passing of the ureteroscope. It was possible to remove most of the stones by expanding the sheath from the PCN. This method increased the efficiency of lithotripsy and withdrawal of the stones. The ureteroscopic basket was also convenient, eliminating the requirement for open surgery and avoiding multiple turnovers, which reduced injury to the ureteral lumen and mucosa.

The guide sheath was safe and efficient, but problems still existed with the calculi or remnants refluxing to the renal pelvis (18). Particularly during or at the end of the lithotripsy, the lumen was gradually opened as the distal calculi broke. The flushing liquid caused a high pressure, and parts of the stones were easily refluxed to the renal pelvis, which required a change to the soft ureteroscope. Due to the low capacity of the calculi

to reflux to the renal pelvis, the use of a basket is suggested for withdrawing the stones. For removing the residual stones, it was attempted to fragment them into particles of <2 mm in size (9).

With the assistance of a guide sheath, a change to the soft ureteroscope was also required for patients with distorted or structured ureters and difficulty in passing. The soft ureteroscope had a thinner tube than the ureter and a more flexible head-end, which was helpful for passing through the distorted or restricted ureters. Lithotripsy with a soft ureteroscope was performed on calculi. Polyps occurred, usually in the narrow space. By applying a skilled technique, bleeding and injury of the ureteral lumen were avoided, after soft ureteroscopy, a change from the soft to the rigid ureteroscope was required. In addition, the soft ureteroscope expanded the lumen, which resulted in straightening of the restricted ureter by flushing liquid with increasing power after clearing the polyps and stones. Subsequently, the thin ureteroscope was successfully passed through the ureter. Rigid ureteroscopy lithotripsy was efficient in surgery assisted by a guide sheath.

In conclusion, ureteroscope lithotripsy was successful with a rigid or soft ureteroscope assisted by a guide sheath for upper ureteral calculi. The technique is helpful for the surgery due to factors including the abundant refluxing of liquid, enhancing the vision, decreasing pressure in the renal pelvis, increasing the efficiency of withdrawing stones and reducing refluxing of stones in the renal pelvis. Due to further advantages, including the protection of the ureteral lumen and decreased complications during or after surgery, particularly for larger stones in the upper ureter, it is suggested that guide sheath-assisted rigid ureteroscopy lithotripsy is an efficient treatment for upper ureteral calculi. However, further studies using larger samples are required to confirm these results.

Acknowledgements

Not applicable.

Funding

No funding received.

Availability of data and materials

The datasets used and/or analyzed during the current study are available from the corresponding author on reasonable request.

Authors' contributions

J-SH performed the surgical procedures. G-HX and H-SY collected the images. G-LL, X-LJ and ZZ collected and analyzed data. YC analyzed the data and supervised this study. All authors read and approved the final version of the manuscript.

Ethics approval and consent to participate

Written informed consent was obtained from all patients and the present study was approved by the Ethics Committee of Ningbo First Hospital.

Patient consent for publication

Written informed consent was obtained from all patients.

Competing interests

The authors declare that they have no competing interests.

References

- Mugiya S, Ito T, Maruyama S, Hadano S and Nagae H: Endoscopic features of impacted ureteral stones. *J Urol* 171: 89-91, 2004.
- Manohar T, Ganpule A and Desai M: Comparative evaluation of Swiss LithoClast 2 versus Holmium: YAG laser lithotripsy for impacted upper-ureteral stones. *J Endourol* 22: 443-446, 2008.
- Ma L, Yu DM, Zhang ZG, Li GH, Ding GQ, Chen YB, Xu LW, Wu HY and Cai XJ: Transperitoneal laparoscopic ureterolithotomy for upper ureteral calculi: A report of 1171 cases. *Zhonghua Yi Xue Za Zhi* 93: 1577-1579, 2013 (In Chinese).
- Martov AG, Teodorovich OV, Galliamov EA, Lutsevich OÉ, Zabrodina NB, Gordienko Alu and Parkhonin DI: Endoscopic ureterolithotomy in large concretions of the upper third of the ureter. *Urologiia* 5: 50-55, 2011 (In Russian).
- Cengiz K, Berkan R, Mirze B and Ünsal A: Efficacy of a percutaneous antegrade approach for the treatment of large upper ureteral stones: Single-center experience. *Turkish J Urol* 37: 210-216, 2011.
- Roberts WW, Cadeddu JA, Micali S, Kavoussi LR and Moore RG: Ureteral stricture formation after removal of impacted calculi. *J Urol* 159: 723-726, 1998.
- Morgentaler A, Bridge SS and Dretler SP: Management of the impacted ureteral calculus. *J Urol* 143: 263-266, 1990.
- Cheng Y and Liu GL: The flexible ureteroscope treatment of urinary tract calculi surgical skills to share. *Xiandaminiaowaikezazhi* 19: 281-284, 2014 (In Chinese).
- Cheng Y, Yan ZJ, Xie GH, Yuan HS and Liu G: Powdered gravel Application of flexible ureteroscope in the treatment of kidney stones. *Weichuangweikeminiaozazhi* 2: 210-212, 2013 (In Chinese).
- Zhong W, Zeng G, Wu W, Chen W and Wu K: Minimally invasive percutaneous nephrolithotomy with multiple mini tracts in a single session in treating staghorn calculi. *Urol Res* 39: 117-122, 2011.
- Alapont JM, Broseta E, Oliver F, Pontones JL, Boronat F and Jiménez-Cruz JF: Ureteral avulsion as a complication of ureteroscopy. *Int Braz J Urol* 29: 18-23, 2003.
- Jiang YM, Li JM, Xu HY, Liu JH, Yan YJ, Zhang JS, Chen J and Jia WJ: Ureteral avulsion long segment. *Zhonghuaminiaowaikezazhi* 29: 408-410, 2008.
- Dong ZQ, Li KJ, Xu XM, Zhang P, Zhang LS and Mao Z: Different ways to comparative efficacy of lithotripsy treatment of ureteral calculi incarcerated on segment. *Zhongguoneijingzazhi* 13: 163-165, 2007.
- Gdor Y, Gabr AH, Faerber GJ, Roberts WW and Wolf JS Jr: Success of endoureterotomy of ureteral strictures associated with ureteral stones is related to stone impaction. *J Endourol* 22: 2507-2511, 2008.
- Lin W, Li Y, Huang HP, Meng DL, Wang JG and He JQ: Comparison of two minimally invasive methods of treatment failure after treatment of upper ureteral calculi ESWL. *Shiyongyixuelinchuang* 10: 49-53, 2009 (In Chinese).
- Auge BK, Pietrow PK, Lallas CD, Raj GV, Santa-Cruz RW and Preminger GM: Ureteral access sheath provides protection against elevated renal pressures during routine flexible ureteroscopic stone manipulation. *J Endourol* 18: 33-36, 2004.
- Breda A, Territo A and Lópezmartínez JM: Benefits and risks of ureteral access sheaths for retrograde renal access. *Curr Opin Urol* 26: 70-75, 2016.
- Liu DY, He HC, Wang J, Tang Q, Zhou YF, Wang MW, Chu CL, Zhang CY, Zhu Y, Zhou WL and Shen ZJ: Ureteroscopic lithotripsy using holmium laser for 187 patients with proximal ureteral stones. *Chin Med J (Engl)* 125: 1542-1546, 2012.



This work is licensed under a Creative Commons Attribution-NonCommercial-NoDerivatives 4.0 International (CC BY-NC-ND 4.0) License.