

Prophylactic clip closure may reduce the risk of delayed bleeding after colorectal endoscopic submucosal dissection



Authors

Hideharu Ogiyama, Shusaku Tsutsui, Yoko Murayama, Shingo Maeda, Shin Satake, Ayaka Nasu, Daisuke Umeda, Yoshio Miura, Kouhei Tominaga, Masashi Horiki, Tamana Sanomura, Kazuho Imanaka, Hiroyasu Iishi

Institution

Departments of Gastroenterology and Hepatology, Itami City Hospital, Itami, Hyogo, Japan

submitted 5.10.2017

accepted after revision 18.1.2018

Bibliography

DOI <https://doi.org/10.1055/a-0581-8886> |

Endoscopy International Open 2018; 06: E582–E588

© Georg Thieme Verlag KG Stuttgart · New York

ISSN 2364-3722

Corresponding author

Hideharu Ogiyama, MD, PhD, Department of Gastroenterology and Hepatology, Itami City Hospital, 1-100, Koyaike, Itami, Hyogo 664-8540, Japan
Fax: +81-72-781-9888
hogiyama@hosp.itami.hyogo.jp

ABSTRACT

Background and study aims Endoscopic submucosal dissection (ESD) has a high en bloc resection rate and is widely performed for large superficial colorectal tumors, but delayed bleeding remains one of the most common complications of colorectal ESD. The aim of the present study was to evaluate the clinical efficacy of prophylactic clip closure of mucosal defects for the prevention of delayed bleeding after colorectal ESD.

Patients and methods We enrolled consecutive patients with colorectal lesions between January 2012 and May 2017 in this retrospective study. In the early part of this period, post-ESD mucosal defects were not closed (non-closure group); however, from January 2014, post-ESD mucosal defects were prophylactically closed with clips when possible (closure group). The main outcome measured was delayed bleeding. Variables were analyzed using the chi-squared test, Fisher's exact test, or Student's t-test.

Results Of 156 lesions analyzed, 61 were in the non-closure group and 95 in the closure group. Overall, delayed bleeding occurred in 5 cases (3.2%). The delayed bleeding rate was 0% (0/95) in the closure group and 8.2% (5/61) in the non-closure group ($P=0.008$). The mean procedure time for closure was 10.4 ± 4.6 min (range 3–26 min).

Conclusions We demonstrated that prophylactic clip closure of mucosal defects might reduce the risk of delayed bleeding after colorectal ESD.

Introduction

Endoscopic submucosal dissection (ESD) is a recently developed technique for gastrointestinal neoplasms with no risk of lymph node metastasis. ESD has a high en bloc resection rate and is minimally invasive. ESD is indicated for large superficial colorectal tumors and is now widely performed [1–3].

However, bleeding after colorectal ESD remains a major complication and needs to be prevented.

Shioji et al. reported that prophylactic clip closure of the mucosal defect caused by removal of a polyp (mean size 7.8 mm) does not decrease delayed bleeding after endoscopic mucosal resection (EMR) [4]. However, Liaquat et al. reported that pro-

phylactic clip closure after EMR of large (≥ 2 cm) colorectal lesions did reduce the risk of delayed bleeding [5].

In comparison with EMR, ESD creates larger mucosal defects, and the rate of delayed bleeding associated with ESD is higher than that with EMR.

Recently, Fujihara et al. [6] reported that prophylactic closure of large mucosal defects after colorectal ESD reduced peritoneal inflammatory reactions and abdominal symptoms, but there is no consensus about the effect of prophylactic clip closure for prevention of delayed bleeding after colorectal ESD.

Delayed bleeding requires emergency endoscopic procedures and/or blood transfusions and rarely requires surgery. This results in longer hospitalization.

The aim of this study was to determine whether prophylactic clip closure reduces the risk of delayed bleeding after colorectal ESD.

Patients and methods

Consecutive patients who underwent colorectal ESD at Itami City Hospital from January 2012 to May 2017 were analyzed retrospectively. All ESD procedures were performed by a single experienced endoscopist (H.O.) who had performed approximately 200 upper gastrointestinal ESDs and 30 colorectal ESDs.

Inclusion and exclusion criteria

The choice of ESD was determined by each colonoscopist based on the Japan Gastroenterological Endoscopy Society guidelines [2, 7, 8].

Lesions that could not be resected or required surgery because of an intraoperative perforation were excluded from this study. Lesions in the anal canal or ileocecal valve were excluded because it was difficult to achieve prophylactic clip closure. Lesions with a resected specimen diameter greater than 5 cm or with a mucosal defect that could not be closed with a clip were also excluded.

Premedication before colorectal ESD

Patients were given a low-fiber diet on the day before ESD and prescribed 24 mg of sennoside (Pursennid; Novartis Pharma, Tokyo, Japan) the night before ESD. On the morning of ESD, 68 g of magnesium citrate (Magcorol P; Horii Pharmaceutical, Osaka, Japan) dissolved in 1.8 L of water was used to cleanse the bowel. An intravenous injection was administered immediately before the procedure, consisting of 10 mg scopolamine butyl bromide (Buscopan; Nippon Boehringer Ingelheim, Tokyo, Japan) or 0.5 mg of glucagon (Glucagon G Novo; Eisai Ltd, Tokyo, Japan), 17.5 mg of pethidine hydrochloride (Takeda Pharma, Osaka, Japan), and 2–3 mg of midazolam (Dormicum; Astellas Pharma, Tokyo, Japan).

Colorectal ESD procedures

The colorectal ESD procedures were performed with a CO₂ inflation system using a standard colonoscope (PCF-Q260AZI, Q260AI, or HQ290I; Olympus, Tokyo, Japan) for lesions located in the cecum and ascending, transverse, and descending colons and a gastroscope (GIF-H260Z and GIF-Q260J; Olympus) for lesions located in the rectum and sigmoid colon. Before the procedure, a disposable attachment (F-050/040/020; Top Corp., Tokyo, Japan) was mounted onto the tip of the endoscope. The VIO 300 D (ERBE Elektromedizin, Tübingen Germany) was used as a high-frequency electrosurgical unit; 10% glycerin (Glyceol; Chugai Pharmaceutical Co., Tokyo, Japan) and hyaluronate solutions (MucoUp; Johnson & Johnson K.K., Tokyo, Japan) were used for injection. We principally used the FlushKnife, FlushKnife BT (Fujifilm Medical, Tokyo, Japan), or DualKnife J (Olympus). If necessary, we used other endo-knives such as the SB Knife Jr (Sumitomo Bakelite, Tokyo, Japan) and the ITknife nano (Olympus). The electric currents used for the circumferential incision and submucosal dissection were the endcut mode and coagulation

mode, respectively. After the lesion was resected, we performed preventive coagulation of visible vessels in the resection area with hemostatic forceps such as Coagrasper (Olympus) or Tigh-turn (Zeon Medical, Tokyo, Japan). However, when we closed a mucosal defect, we rarely performed preventive coagulation. The degree of submucosal fibrosis was classified into 3 types (F0–2), as described previously [9].

Clip closure technique

After the lesion was resected, a large mucosal defect remained. In patients enrolled in 2012–2013, the defects were not closed, but in patients enrolled from 2014, the defects were usually closed endoscopically. To close the mucosal defect, we used a normal clip closure technique, but if the mucosal defect was too large to be closed by normal clip closure, we used Otake's clip closure technique, as described previously [10].

Initially, a small incision was made around the mucosal defect with the FlushKnife, FlushKnife BT, or DualKnife J. The number of incisions depended on the size of the mucosal defect. The incision provided a better grip for the clip, which could be lifted easily across the defect without slipping. This makes it easier to reduce the size of the defect and place additional clips if necessary.

We use the EZ clip (HX-610-090L; Olympus) or ZEOCLIP (ZP-CH; Zeon Medical) for closure.

Schedule after ESD

Blood tests and X-ray examination were performed on the day after ESD; if delayed bleeding occurred, the blood test was repeated. Some patients (n = 15) underwent X-ray examination 3–7 d after ESD for other causes such as abdominal pain. After the colorectal ESD procedure, the fasting period was 2 d, and the hospitalization period was 8 d.

Measured outcomes

We mainly aimed to identify whether prophylactic clip closure reduced the rate of delayed bleeding following colorectal ESD. Delayed bleeding was defined as clinical evidence of bleeding that required endoscopic hemostasis or a decrease in the hemoglobin level of > 2 g/dL after ESD. Lesions in which the mucosal defect was not closed were included in the non-closure group, and lesions in which the mucosal defect was closed were included in the closure group.

Ethics

The study protocol was approved by the ethics committee of Itami City Hospital and was performed in accordance with the Declaration of Helsinki.

Statistical analysis

Continuous and categorical variables are shown as means ± standard deviations, ranges, and proportions. Background and clinical outcomes were compared using the chi-square test, Fisher's exact test, or Student's t-test, as appropriate. A value of $P < 0.05$ was considered statistically significant. Statistical analysis was performed using JMP software (version 11.2.0; SAS Institute Inc., Cary, NC).

Results

Between January 2012 and May 2017, a total of 195 lesions in 186 patients were treated with colorectal ESD. A total of 39 lesions were excluded from the analysis because they could not be resected, needed surgery because of intraoperative perforation, were located in the anal canal or ileocecal valve, were greater than 5 cm in diameter, or had a mucosal defect that could not be closed (► Fig. 1). Of 156 lesions, 61 that were not closed and 95 that were closed with clips were included. Background and clinical outcomes of all patients are divided into 2 periods at the beginning of prophylactic clip closure (► Table 1). Regarding the macroscopic features, the prevalence of nongranular-type laterally spreading tumor (LST-NG) was higher in the second period than in the first period. The sizes of the resected specimens and tumors were larger in the second period than in the first period. The prevalence of carcinoma was higher in the second period than in the first period.

► Table 2 shows the differences in background and clinical outcomes between the closure and non-closure groups. Age, sex, tumor location, use of antithrombotic drugs, macroscopic features, the resected specimen size, tumor size, fibrosis, and procedure time were not significantly different between the 2 groups. The rate of carcinoma was higher in the closure group than in the non-closure group. The usage rate of hemostatic forceps was lower in the closure group than in the non-closure group.

ESD for colorectal lesions from
January 2012 to May 2017 195 lesions

Excluded:

- could not be resected 5 lesions
- needed surgery because of intraoperative perforation 3 lesions
- located in the anal canal or ileocecal valve 11 lesions
- tumor size in resected specimen was larger than 5 cm 12 lesions
- mucosal defect could not be closed 8 lesions

Closure group
95 lesions

Non-closure group
61 lesions

► Fig. 1 Flow diagram.

The rate of delayed bleeding was 5/61 (8.2%) in the non-closure group; delayed bleeding did not occur in the closure group ($P=0.008$). Lesions that could not be closed had no delayed bleeding, and the result was the same when we included 8 lesions that could not be closed in the closure group. The median

► Table 1 Background and clinical outcomes of patients by period.

	1st period (n = 73)	2nd period (n = 122)	P value
Age (years)	69.6 ± 9.6	70.6 ± 9.5	0.48
Sex (male/female)	45/28	81/41	0.50
Use of antithrombotic drugs (anticoagulants/antiplatelet drugs)	7 (2/6)	23 (8/17)	0.08
Tumor location (colon/rectum)	49/24	95/27	0.13
Macroscopic features (LST-G/LST-NG/protruded)	34/24/15	54/62/6	0.001
Resected specimen size (mm)	30.5 ± 13.7	37.2 ± 15.2	0.003
Tumor size (mm)	23.3 ± 13.3	28.0 ± 13.9	0.02
Fibrosis (F0/F1/F2)*	50/21/2	70/45/7	0.26
2nd device (SB knife Jr/IT knife nano/other)	14/2/1	24/3/5	0.75
Histology (adenoma/carcinoma)	51/22	45/77	<0.001
Procedure time (min)	73.7 ± 6.1	82.2 ± 4.7	0.27
Adverse events			
▪ Delayed bleeding	5	3	0.13
▪ Perforation	1	6	0.20
En bloc resection rate, n (%)	69 (94.5)	120 (98.3)	0.20

LST-G: granular-type laterally spreading tumor; LST-NG: nongranular-type laterally spreading tumor. Data are presented as the mean ± standard deviation. The P values represent the results of analysis of variance with the chi-square test, Fisher's exact test, or Student's t-test. * The degree of submucosal fibrosis was classified into 3 types (F0–2), as described previously [9].

► **Table 2** Background and clinical outcomes in the closure group vs. non-closure group.

	Closure group (n = 95)	Non-closure group (n = 61)	P value
Age (years)	70.3 ± 9.4	70.1 ± 8.5	0.90
Sex (male/female)	62/33	42/19	0.73
Tumor location (colon/rectum)	78/17	44/17	0.23
Use of antithrombotic drugs (anticoagulants/antiplatelet drugs)	19 (16/5)	8 (6/3)	0.29
Macroscopic features (LST-G/LST-NG/protruded)	39/50/6	26/24/11	0.05
Resected specimen size (mm)	32.2 ± 8.1	30.1 ± 11.7	0.42
Tumor size (mm)	23.5 ± 7.0	22.2 ± 9.0	0.32
Fibrosis (F0/F1/F2)*	60/32/3	38/19/4	0.60
Histology (adenoma/carcinoma)	41/54	43/18	0.001
Procedure time (min)	64.3 ± 33.9	72.8 ± 46.7	0.19
Use of hemostatic forceps	64	59	<0.001
Closure time (min)	10.4 ± 4.6	–	
Delayed bleeding	0/95	5/56	0.008

LST-G: granular-type laterally spreading tumor; LST-NG: nongranular-type laterally spreading tumor. Data are presented as a mean ± standard deviation. The P values represent the results of analysis of variance with chi-square test, Fisher's exact test, or Student's t-test. * The degree of submucosal fibrosis was classified into 3 types (F0–2), as described previously [9].

► **Table 3** Clinical outcome of normal clip closure and clip closure using Otake's technique.

	Normal clip closure (n = 23)	Clip closure using Otake's technique (n = 72)	P value
Closure procedure time (min)	8.3 ± 5.8	11.1 ± 4.0	0.01
Number of clips (range)	4.73 ± 1.63 (3–8)	4.51 ± 1.52 (2–9)	0.54
Resected specimen size (mm)	29.0 ± 7.7	34.3 ± 10.2	0.03

Data are presented as a mean ± standard deviation. The P values represent the results of analysis of variance with Student's t-test

size of the resected tumors in 5 bleeding lesions was 35 mm (range 18–47 mm).

► **Table 3** shows the differences in clinical outcomes between the normal clip closure group (group N) and the clip closure group using Otake's technique (group O). The closure procedure time was longer in group O (11.1 min) than in group N (8.3 min). The number of clips was not different between the groups. The size of the resected specimen was larger in group O than in group N.

► **Table 4** shows the characteristics of patients who could not be closed with a clip. The sizes of the resected specimens and tumors were 51.4 ± 9.9 mm and 39.4 ± 5.5 mm, respectively, which were larger than those of the closure group.

► **Fig. 2a** shows the day that delayed bleeding occurred. Delayed bleeding occurred within 7 d and mostly occurred within 2 d. ► **Fig. 2b** shows the residual clip rate in patients who underwent X-ray examination in the closure group. Among 15 lesions, the residual clip rates on day 3, 5, and 6 were 100%, 80%, and 93%, respectively.

Adverse events associated with clipping, such as perforation, did not occur.

Discussion

In the present study, we have shown that prophylactic clip closure significantly decreases the risk of delayed bleeding after colorectal ESD. This is the first study to demonstrate the clinical efficacy of prophylactic clip closure for prevention of delayed bleeding after colorectal ESD.

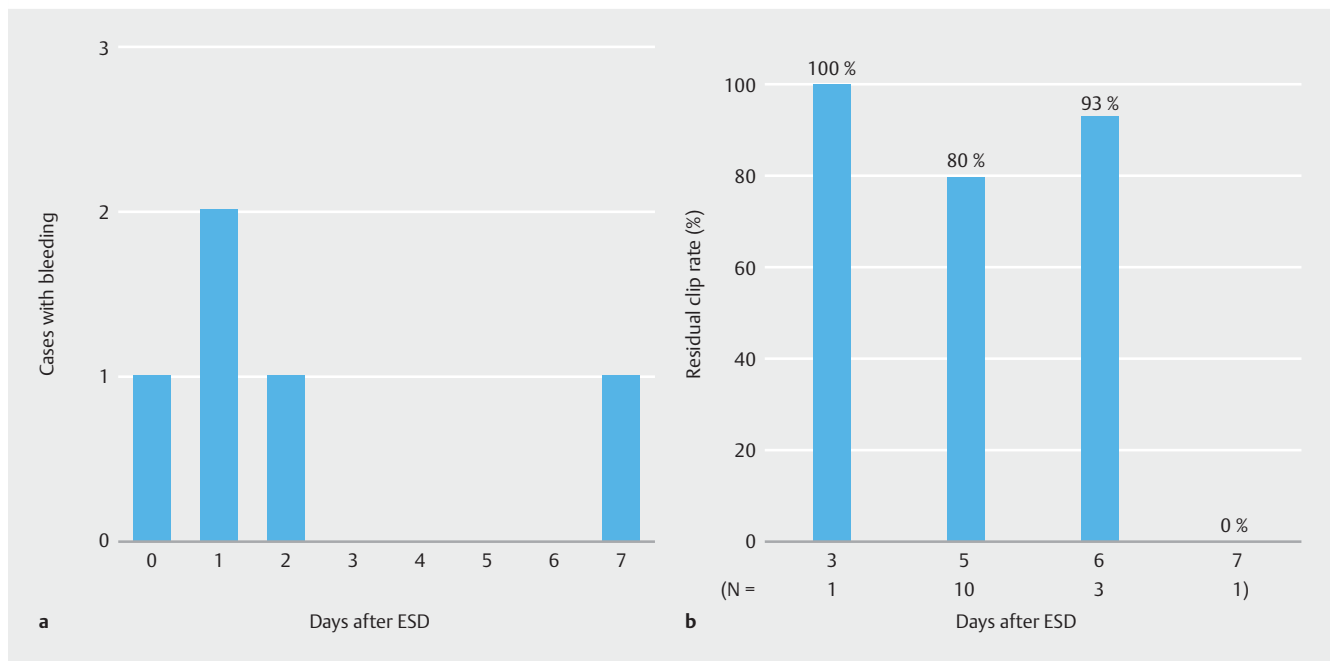
In reports with a large number of cases (>100), the rate of delayed bleeding in colorectal ESD ranges between 1.5% and 4.4% [1, 3, 11, 12]. High rates (7.9% and 11.9%) are found in reports of a small number of cases (<100) [13, 14]. As reported by Odagiri et al., the rate of delayed bleeding may be affected by the number of cases [12]. The delayed bleeding rate is higher than that of EMR for small colorectal lesions [4].

A meta-analysis showed that the delayed bleeding rate in gastric ESD was 4.53% [15], and it is still a major complication. In gastric ESD, post-ESD preventive coagulation therapy of visi-

► **Table 4** Characteristics of patients with lesions that could not be closed with a clip.

Patient number	Sex	Age (years)	Location	Macroscopic features	Resected specimen size (mm)	Tumor size (mm)	Procedure time (min)	Fibrosis (F0/F1/F2)*	Histology (adenoma/carcinoma)
1	M	78	Transverse colon	LST-NG	45	30	120	F1	Carcinoma
2	M	62	Transverse colon	LST-NG	52	45	270	F2	Carcinoma
3	M	75	Cecum	LST-NG	60	44	310	F1	Carcinoma
4	F	56	Rectum	LST-NG	40	38	98	F1	Carcinoma
5	F	74	Sigmoid colon	LST-G	48	36	88	F1	Carcinoma
6	M	75	Rectum	LST-G	45	35	69	F0	Adenoma
7	F	41	Sigmoid colon	LST-G	50	42	81	F0	Carcinoma
8	M	79	Transverse colon	LST-G	71	45	135	F0	Carcinoma

F: female; M: male; LST-G: granular-type laterally spreading tumor; LST-NG: nongranular-type laterally spreading tumor. * The degree of submucosal fibrosis was classified into 3 types (F0–2), as described previously [9].



► **Fig 2** **a** The timing of delayed bleeding. Delayed bleeding occurred within 7 d and mostly within 2 d. **b** Correlation between the residual clip rate and days after ESD in patients who underwent X-ray examination in the closure group. The residual clip rate on days 3–6 was high.

ble vessels in the ulcer with hemostatic forceps may reduce delayed bleeding [16].

However, in colorectal ESD, preventive coagulation may lead to excessive coagulation of the muscularis propria [17], which may increase the risk of delayed perforation, because the muscularis propria of the colon is much thinner than that of the stomach [18].

Recently, Liaquat et al. reported that prophylactic clip closure reduced the risk of delayed bleeding after EMR of large (≥ 2 cm) colorectal lesions [5].

On the basis of these reports, we thought that prophylactic clip closure would be more effective and securer than preventive coagulation to decrease the risk of delayed bleeding after colorectal ESD. In the present study, by achieving prophylactic clip closure of the mucosal defect, the need for hemostatic for-

ceps was reduced in the closure group, and the usage rate of hemostatic forceps was lower in the closure group than in the non-closure group.

Several methods have been reported on the closure of mucosal defect after colorectal ESD [6, 10, 19–23]. As it is simple and easy, we have chosen Otake's method to close large mucosal defects that would be difficult to close using conventional clipping.

Our results showed that the mean procedure time for closure was 10.4 min, which is similar to the procedure time described in previous studies [10]; we think the procedure time for closure is acceptable. From January 2014, we could not close 8 of 103 mucosal defects. Five bleeding mucosal defects in the non-closure group were within the range that might be closed if we had tried. Lesions that could not be closed with a clip had a larger resected specimen and tumor size and a longer procedure time. There were 12 lesions greater than 5 cm. Among the 8 lesions greater than 5 cm in the second period, there were only 2 for which we could close the mucosal defect; among the remaining 6, we could not close 2 and did not try to close the other 4. Additionally, delayed bleeding was found in 3 excluded lesions; 2 of them were in the second period. These 3 lesions were larger than 5 cm and located in the anal canal and ileocecal valve. To reduce delayed bleeding, we think it is desirable that all post-ESD mucosal defects be closed prophylactically if possible. If prophylactic clip closure fails or is predicted to fail in advance – for example, in cases with lesions larger than 5 cm – another clipping technique [22, 23] or a shielding method using polyglycolic acid sheets with fibrin glue [24, 25] might be an option to decrease delayed bleeding.

In the present study, delayed bleeding occurred mostly within 2 d, and most of the clips used for prophylactic clip closure remained for 3–6 d. This residual clip rate is similar to that in a previous report [26]. As it has been reported that healing of a large mucosal defect was accelerated by closure [26, 27], we believe that accelerated wound healing with prophylactic clip closure contributes to decreased risk of delayed bleeding.

In the present study, delayed perforation did not occur, and we did not evaluate the efficacy of prophylactic clip closure for protection from delayed perforation.

When closing a mucosal defect, the probability of local recurrence is a matter of concern. In lesions where an en bloc resection was performed using ESD, the recurrence rate is extremely low [28], and local recurrence should not be a concern because we achieved en bloc resection in all lesions in the closure group.

In the analysis of the treatment period, the rate of LST-NG was higher and size of the resected specimens and tumors larger in the second period than in the first period. We think these factors caused the rate of carcinoma to be higher in the second period than in the first period and different between the closure and non-closure groups. This indicates that ESD was performed for more difficult lesions in the second period than in the first period. However, these factors have not been reported as predictors of delayed bleeding [29].

Some limitations of the present study must be considered. First, this was a retrospective, single-institution study. Second,

the lesions that received prophylactic clip closure were treated recently, so the learning curve with colorectal ESD cannot be ignored. It has been reported that colorectal ESD can be safely performed by endoscopists who have an experience of ≥ 30 cases [30]. The endoscopist in this study had sufficient experience, having performed approximately 200 upper gastrointestinal ESDs and 30 colorectal ESDs. To exclude the effect of the learning curve, a prospective study is needed.

In conclusion, we demonstrated that prophylactic clip closure might reduce the risk of delayed bleeding after colorectal ESD. In the future, a multicenter prospective study will be needed to confirm the effectiveness of prophylactic clip closure.

Competing interests

None

References

- [1] Saito Y, Uraoka T, Yamaguchi Y et al. A prospective, multicenter study of 1111 colorectal endoscopic submucosal dissections (with video). *Gastrointest Endosc* 2010; 72: 1217–1225
- [2] Tanaka S, Terasaki M, Kanao H et al. Current status and future perspectives of endoscopic submucosal dissection for colorectal tumors. *Dig Endosc* 2012; 24 (Suppl. 01): 73–79
- [3] Tanaka S, Tamegai Y, Tsuda S et al. Multicenter questionnaire survey on the current situation of colorectal endoscopic submucosal dissection in Japan. *Dig Endosc* 2010; 22 (Suppl. 01): S2–S8
- [4] Shioji K, Suzuki Y, Kobayashi M et al. Prophylactic clip application does not decrease delayed bleeding after colonoscopic polypectomy. *Gastrointest Endosc* 2003; 57: 691–694
- [5] Liaquat H, Rohn E, Rex DK. Prophylactic clip closure reduced the risk of delayed postpolypectomy hemorrhage: experience in 277 clipped large sessile or flat colorectal lesions and 247 control lesions. *Gastrointest Endosc* 2013; 77: 401–407
- [6] Fujihara S, Mori H, Kobara H et al. The efficacy and safety of prophylactic closure for a large mucosal defect after colorectal endoscopic submucosal dissection. *Oncol Rep* 2013; 30: 85–90
- [7] Tanaka S, Oka S, Chayama K. Colorectal endoscopic submucosal dissection: present status and future perspective, including its differentiation from endoscopic mucosal resection. *J Gastroenterol* 2008; 43: 641–651
- [8] Tanaka S, Kashida H, Saito Y et al. JGES guidelines for colorectal endoscopic submucosal dissection/endoscopic mucosal resection. *Dig Endosc* 2015; 27: 417–434
- [9] Matsumoto A, Tanaka S, Oba S et al. Outcome of endoscopic submucosal dissection for colorectal tumors accompanied by fibrosis. *Scand J Gastroenterol* 2010; 45: 1329–1337
- [10] Otake Y, Saito Y, Sakamoto T et al. New closure technique for large mucosal defects after endoscopic submucosal dissection of colorectal tumors (with video). *Gastrointest Endosc* 2012; 75: 663–667
- [11] Takeuchi Y, Iishi H, Tanaka S et al. Factors associated with technical difficulties and adverse events of colorectal endoscopic submucosal dissection: retrospective exploratory factor analysis of a multicenter prospective cohort. *Int J Colorectal Dis* 2014; 29: 1275–1284
- [12] Odagiri H, Yasunaga H, Matsui H et al. Hospital volume and the occurrence of bleeding and perforation after colorectal endoscopic submucosal dissection: analysis of a national administrative database in Japan. *Dis Colon Rectum* 2015; 58: 597–603

- [13] Hurlstone DP, Atkinson R, Sanders DS et al. Achieving R0 resection in the colorectum using endoscopic submucosal dissection. *Br J Surg* 2007; 94: 1536–1542
- [14] Probst A, Golger D, Anthuber M et al. Endoscopic submucosal dissection in large sessile lesions of the rectosigmoid: learning curve in a European center. *Endoscopy* 2012; 44: 660–667
- [15] Park YM, Cho E, Kang HY et al. The effectiveness and safety of endoscopic submucosal dissection compared with endoscopic mucosal resection for early gastric cancer: a systematic review and meta-analysis. *Surg Endosc* 2011; 25: 2666–2677
- [16] Takizawa K, Oda I, Gotoda T et al. Routine coagulation of visible vessels may prevent delayed bleeding after endoscopic submucosal dissection – an analysis of risk factors. *Endoscopy* 2008; 40: 179–183
- [17] Yoshida N, Yagi N, Naito Y et al. Safe procedure in endoscopic submucosal dissection for colorectal tumors focused on preventing complications. *World J Gastroenterol* 2010; 16: 1688–1695
- [18] Toyonaga T, Man IM, Ivanov D et al. The results and limitations of endoscopic submucosal dissection for colorectal tumors. *Acta Chir Iugosl* 2008; 55: 17–23
- [19] Matsuda T, Fujii T, Emura F et al. Complete closure of a large defect after EMR of a lateral spreading colorectal tumor when using a two-channel colonoscope. *Gastrointest Endosc* 2004; 60: 836–838
- [20] Fujii T, Ono A, Fu KI. A novel endoscopic suturing technique using a specially designed so-called “8-ring” in combination with resolution clips (with videos). *Gastrointest Endosc* 2007; 66: 1215–1220
- [21] Sakamoto N, Beppu K, Matsumoto K et al. “Loop Clip”, a new closure device for large mucosal defects after EMR and ESD. *Endoscopy* 2008; 40 (Suppl. 02): E97–E98
- [22] Kato M, Takeuchi Y, Yamasaki Y. Line-assisted complete closure of a large colorectal mucosal defect after endoscopic submucosal dissection. *Dig Endosc* 2016; 28: 686
- [23] Yahagi N, Nishizawa T, Akimoto T et al. New endoscopic suturing method: string clip suturing method. *Gastrointest Endosc* 2016; 84: 1064–1065
- [24] Takimoto K, Toyonaga T, Matsuyama K. Endoscopic tissue shielding to prevent delayed perforation associated with endoscopic submucosal dissection for duodenal neoplasms. *Endoscopy* 2012; 44 (Suppl. 02): E414–E415
- [25] Tsuji Y, Ohata K, Gunji T et al. Endoscopic tissue shielding method with polyglycolic acid sheets and fibrin glue to cover wounds after colorectal endoscopic submucosal dissection (with video). *Gastrointest Endosc* 2014; 79: 151–155
- [26] Osada T, Sakamoto N, Ritsuno H et al. Process of wound healing of large mucosal defect areas that were sutured by using a loop clip-assisted closure technique after endoscopic submucosal dissection of a colorectal tumor. *Gastrointest Endosc* 2013; 78: 793–798
- [27] Osada T, Sakamoto N, Ritsuno H et al. Closure with clips to accelerate healing of mucosal defects caused by colorectal endoscopic submucosal dissection. *Surg Endosc* 2016; 30: 4438–4444
- [28] Oka S, Tanaka S, Saito Y et al. Local recurrence after endoscopic resection for large colorectal neoplasia: a multicenter prospective study in Japan. *Am J Gastroenterol* 2015; 110: 697–707
- [29] Terasaki M, Tanaka S, Shigita K et al. Risk factors for delayed bleeding after endoscopic submucosal dissection for colorectal neoplasms. *Int J Colorectal Dis* 2014; 29: 877–882
- [30] Sakamoto T, Saito Y, Fukunaga S et al. Learning curve associated with colorectal endoscopic submucosal dissection for endoscopists experienced in gastric endoscopic submucosal dissection. *Dis Colon Rectum* 2011; 54: 1307–1312