



Case report

Contact dermatitis on the lower eyelid related to tick infestation: A case report in Taiwan



Yun-Hsuan Lin ^a, Ling Yeung ^{a, b}, Chi-Chin Sun ^{a, b}, Wan-Chen Ku ^a, Ju-Wen Yang ^{a, b, *}

^a Department of Ophthalmology, Chang Gung Memorial Hospital, Keelung, Taiwan

^b College of Medicine, Chang Gung University, Kwei-Shan, Taoyuan, Taiwan

ARTICLE INFO

Article history:

Received 3 February 2016

Received in revised form

18 May 2016

Accepted 20 May 2016

Available online 16 July 2016

Keywords:

Ticks

Tick bites

Tick infestations

Contact dermatitis

Eyelids

ABSTRACT

Tick bite on the lower eyelid is a rare condition. We reported a case of contact dermatitis on the lower eyelid related to the tick infestation. Ticks are vectors for disease transmission. Symptoms and treatments for tick-borne diseases were reviewed.

Copyright © 2016, The Ophthalmologic Society of Taiwan. Published by Elsevier Taiwan LLC. This is an open access article under the CC BY-NC-ND license (<http://creativecommons.org/licenses/by-nc-nd/4.0/>).

1. Introduction

Tick infestation of the lower eyelid is a rare condition but one that requires close observation for the development of erythema migrans. We report a case of a skin rash on the lower eyelid that occurred after a tick bite and review the literature. This study received Institutional Review Board approval from the Ethics Committee at Chang Gung Memorial Hospital (Keelung City, Taiwan).

2. Case Report

A 50-year-old Taiwanese woman presented to our clinic with a right lower eyelid pigmented nodule associated with cheek tingling, pain, and numbness for 1 week. She reported a history of hiking 1 week before presentation. During the examination, a tick was found on the right lower eyelid skin, and its waste was visible around the eyelashes (Figure 1). The tick was removed using fine forceps and gentle scraping with cotton swabs; however, 1 month later, a localized pruritic erythematous rash developed on the right

lower eyelid (Figure 2). The patient remained afebrile without other systemic symptoms. She was diagnosed with tick bite-related contact dermatitis and was successfully treated with topical beta-methasone (Eye Betason-N, Winston, Taiwan) ointment applied twice daily for 2 weeks.

3. Discussion

Ticks are vectors for disease transmission.^{1,2} In our patient, the tick was attached for 36–48 hours or more, and thus the efficient transmission of spirochetes potentially occurred.^{3–6}

Lyme disease, caused by *Borrelia burgdorferi* and other closely related spirochetes,⁷ is the most commonly reported tick-borne infection. Because of the possibility of developing erythema migrans, it is important to observe the site of a tick bite for at least 40 days after the tick's removal because erythema migrans typically occurs days to weeks after a tick bite.⁸ This clinically presents as a macule or papule expanding over a period of days to weeks, and forms a red or blue–red patch with or without a central clearing (i.e., the classic “bull’s eye” rash). The lesions may cause burning, tenderness, or pruritus, or may be completely asymptomatic. Fatigue, fever, headache, mild stiff neck, arthralgia, and myalgia may accompany local symptoms. If no appropriate treatment is administered, other manifestations may follow because of spirochete dissemination to other tissues.

Conflicts of interest: The authors have no financial conflicts of interest to declare.

* Corresponding author. Department of Ophthalmology, Chang Gung Memorial Hospital, 6F., No. 222, Maijin Rd., Anle Dist., Keelung City 204, Taiwan.

E-mail address: m7046@cgmh.org.tw (J.-W. Yang).

<http://dx.doi.org/10.1016/j.tjo.2016.05.008>

2211-5056/Copyright © 2016, The Ophthalmologic Society of Taiwan. Published by Elsevier Taiwan LLC. This is an open access article under the CC BY-NC-ND license (<http://creativecommons.org/licenses/by-nc-nd/4.0/>).

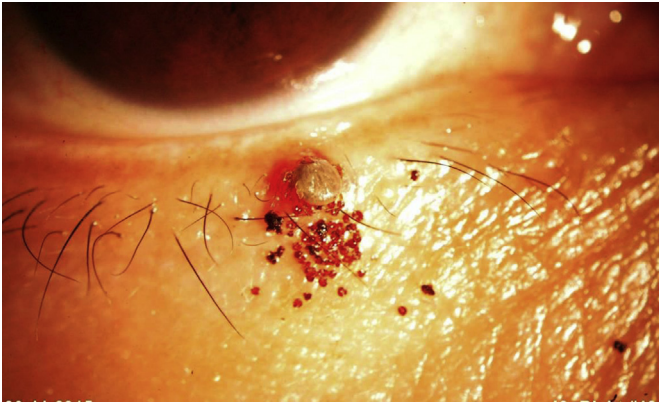


Figure 1. A tick is attached to the lower eyelid and its eliminated waste is visible around the eyelashes.

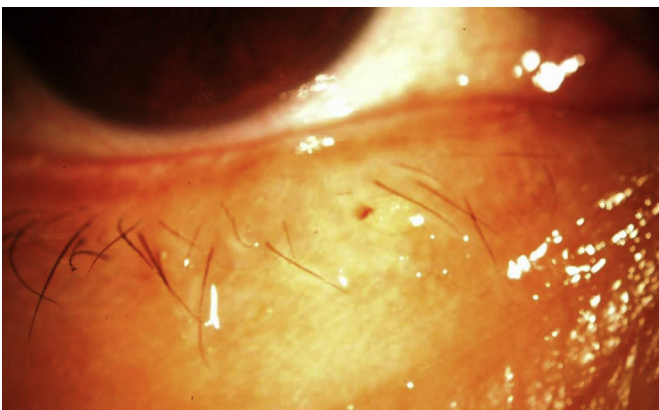


Figure 2. One month later, a localized skin rash has developed at the lesion site.

Symptoms related to tick-borne diseases can be mild and treated at home or can be severe enough to require hospitalization. Furthermore, two-thirds of patients with untreated early Lyme disease risk the development of disseminated disease.⁹ In adults, disseminated Lyme disease can present as neuroborreliosis (primarily the acute disease) and develop within a few weeks of infection. It typically presents as painful meningoradiculoneuritis with unilateral or bilateral facial palsy. Other manifestations include cranial neuropathies involving the oculomotor, trochlear, or abducens nerves, among others. Other rare manifestations are isolated meningitis, myelitis, encephalitis, and cerebral vasculitis presenting as stroke. In addition, systemic Lyme disease can present with recurrent or chronic arthritis or synovitis, and it typically affects large joints such as the knee.¹⁰

Conjunctivitis is usually the earliest ophthalmic manifestation. Uveitis (i.e., anterior, intermediate, posterior, or panuveitis), papillitis, keratitis, and episcleritis may also occasionally occur, although significant ophthalmic complications typically appear during the later stages of Lyme disease.^{11–15} Furthermore, blurred vision can develop secondary to papilledema, optic atrophy, optic or retrobulbar neuritis, or pseudotumor cerebri. Optic nerve disease may be unilateral or bilateral. Thus, early recognition and treatment of the infection decreases the risk of significant vision loss.

The prognosis for patients with Lyme disease is generally good when they are treated early with appropriate antibiotic regimens.¹⁶ The Infectious Disease Society of America (Arlington, VA, USA) recommends preventive treatment with antibiotics in people who meet all of the following criteria: (1) the attached tick is an adult or

nymphal *Ixodes scapularis* (i.e., “deer tick”); (2) the tick has been attached for ≥ 36 hours; (3) an antibiotic can be administered within 72 hours of tick removal; (4) the local rate of tick infection with *B. burgdorferi* is $\geq 20\%$ (e.g., parts of New England, parts of the mid-Atlantic states, and parts of Minnesota and Wisconsin, USA); and (5) the patient can take doxycycline (e.g., the person is not pregnant or breastfeeding or a child < 8 years old). If the person meets all of the aforementioned criteria, doxycycline can be prescribed. The recommended dose is 200 mg for adults and 4 mg/kg (up to a maximum dose of 200 mg) for children aged ≥ 8 years.¹⁷

Lyme disease is endemic in North America, Europe, and Asia, and the distribution of the vectors directly affects the incidence of the disease.¹⁸ In Asia, *B. burgdorferi* infection has been reported in countries such as China, Korea, Japan, Indonesia, Nepal, and eastern Turkey.¹⁹

The Taiwan Centers for Disease Control (Taipei City, Taiwan) confirmed two tick bite cases related to *Dermacentor taiwanensis* in Shuangxi District, New Taipei City in 2013 and in Hualien County in 2011.²⁰ Our case of infection by a tick bite in a Taiwanese woman in Keelung City in 2015 was the third tick bite case reported in this region. They were all associated with outdoor activities in the mountains. The public should take precautions against bug bites when farming, visiting wooded, brushy, and grassy areas, or when contacting animals in the mountains. Taiwan will probably become an endemic area for tick bites.

Tick bite of the lower eyelid is rare, and may cause contact dermatitis.²¹ There is no patch testing for this kind of irritant contact dermatitis. It is a clinical diagnosis. Unlike erythema migrans, which is an expanding annular skin rash, contact dermatitis is limited to a local area. Irritant contact dermatitis is an eczematous reaction in the skin caused by exposure to external agents or chemicals.²² Pruritus is a fundamental symptom of contact dermatitis. Other common symptoms may include stinging, a burning sensation, and pain.²³ The tick should be removed carefully using very fine forceps held as close to the skin as possible and pulled firmly out from the skin. The site should be thoroughly disinfected with a skin antiseptic. Squeezing the tick during removal should be avoided because this action may inject infectious material into the skin.²¹ The application of topical steroids and moisturizers may be useful. The prognosis of contact dermatitis is good after removing the causal agent.²⁴

Late onset skin rash at the lesion site should be managed with caution to prevent ocular and systemic tick bite-related diseases. Patients should be informed in detail about the presenting symptoms and the ocular and systemic signs of tick bite-related diseases.

References

- Edlow JA. Lyme disease and related tick-borne illnesses. *Ann Emerg Med.* 1999;33:680–693.
- Edlow JA. Preface: tick-borne diseases, part II. *Infect Dis Clin North Am.* 2008;22:xiii–xv.
- Piesman J, Hicks TC, Sinsky RJ, Obiri G. Simultaneous transmission of *Borrelia burgdorferi* and *Babesia microti* by individual nymphal *Ixodes dammini* ticks. *J Clin Microbiol.* 1987;25:2012–2013.
- Piesman J, Maupin GO, Campos EG, Happ CM. Duration of adult female *Ixodes dammini* attachment and transmission of *Borrelia burgdorferi*, with description of a needle aspiration isolation method. *J Infect Dis.* 1991;163:895–897.
- Piesman J. Dynamics of *Borrelia burgdorferi* transmission by nymphal *Ixodes dammini* ticks. *J Infect Dis.* 1993;167:1082–1085.
- Schwan TG, Piesman J. Vector interactions and molecular adaptations of Lyme disease and relapsing fever spirochetes associated with transmission by ticks. *Emerg Infect Dis.* 2002;8:115–121.
- Burgdorfer W, Barbour AG, Hayes SF, Benach JL, Grunwaldt E, Davis JP. Lyme disease—a tick-borne spirochetosis? *Science.* 1982;216:1317–1319.
- Dandache P, Nadelman RB. Erythema migrans. *Infect Dis Clin North Am.* 2008;22:235–260.
- Stanek G, Fingerle V, Hunfeld KP, et al. Lyme borreliosis: Clinical case definitions for diagnosis and management in Europe. *Clin Microbiol Infect.* 2011;17:69–79.

10. Smith BG, Cruz Jr AI, Milewski MD, Shapiro ED. Lyme disease and the orthopaedic implications of Lyme arthritis. *J Am Acad Orthop Surg*. 2011;19:91–100.
11. Klig JE. Ophthalmologic complications of systemic disease. *Emerg Med Clin North Am*. 2008;26:217–231.
12. Karma A, Seppala I, Mikkila H, Kaakkola S, Viljanen M, Tarkkanen A. Diagnosis and clinical characteristics of ocular Lyme borreliosis. *Am J Ophthalmol*. 1995;119:127–135.
13. Lesser RL. Ocular manifestations of Lyme disease. *Am J Med*. 1995;98(4A):60S–62S.
14. Lesser RL, Kornmehl EW, Pachner AR, et al. Neuro-ophthalmologic manifestations of Lyme disease. *Ophthalmology*. 1990;97:699–706.
15. Steere AC, Sikand VK. The presenting manifestations of Lyme disease and the outcomes of treatment. *N Engl J Med*. 2003;348:2472–2474.
16. Nau R, Christen HJ, Eiffert H. Lyme disease—current state of knowledge. *Dtsch Arztebl Int*. 2009;106:72–81.
17. Wormser GP, Dattwyler RJ, Shapiro ED, et al. The clinical assessment, treatment, and prevention of Lyme disease, human granulocytic anaplasmosis, and babesiosis: clinical practice guidelines by the Infectious Diseases Society of America. *Clin Infect Dis*. 2006;43:1089–1134.
18. Steere AC. Lyme borreliosis in 2005, 30 years after initial observations in Lyme, Connecticut. *Wien Klin Wochenschr*. 2006;118(21–22):625–633.
19. Masuzawa T. Terrestrial distribution of the Lyme borreliosis agent *Borrelia burgdorferi sensu lato* in East Asia. *Jpn J Infect Dis*. 2004;57:229–235.
20. Centers for Disease Control, R.O.C. (Taiwan). As Taiwan's Second Tick Bite Case Identified in a Woman, Taiwan CDC Urges Public to Take Precautions Against Bug Bites When Visiting Wooded, Brushy and Grassy Areas. News 2013 (Press release). Available at: <http://www.cdc.gov.tw/english/info.aspx?treeid=bc2d4e89b154059b&nowtreeid=ee0a2987cfba3222&tid=F13AF9B844E297AC>. [Accessed 3 Jun 2016].
21. Farrar J, Hotez P, Junghans T, Kang G, Lalloo D, White NJ. *Manson's Tropical Diseases*. Philadelphia, PA: Elsevier Health Sciences; 2013:1007–1008.
22. Rycroft RJG. *Textbook of Contact Dermatitis*. New York, NY: Springer Science and Business Media; 2001:70.
23. Frosch PJ, Menne T, Lepoittevin J-P. *Contact Dermatitis*. New York, NY: Springer Science and Business Media; 2006:205.
24. Ng SK, Goh CL. *The Principles and Practice of Contact and Occupational Dermatology in the Asia-Pacific Region*. Singapore: World Scientific; 2001:72–73.