

Received: 2018.11.25  
Accepted: 2019.01.11  
Published: 2019.03.21

# Increasing Size of Cholesterol Granuloma of the Breast in the Vicinity of a Previous Breast Biopsy: Imaging Features and Review of the Literature

Authors' Contribution:  
Study Design A  
Data Collection B  
Statistical Analysis C  
Data Interpretation D  
Manuscript Preparation E  
Literature Search F  
Funds Collection G

ABCDEF **Suk Jung Kim**

Department of Radiology, Haeundae Paik Hospital, Inje University College of Medicine, Busan, South Korea

**Corresponding Author:** Suk Jung Kim, e-mail: [pure0815@hanmail.net](mailto:pure0815@hanmail.net)  
**Conflict of interest:** None declared

**Patient:** Female, 52  
**Final Diagnosis:** Cholesterol granuloma of the breast  
**Symptoms:** None  
**Medication:** —  
**Clinical Procedure:** Core needle biopsy  
**Specialty:** Radiology

**Objective:** Rare co-existence of disease or pathology  
**Background:** Cholesterol granuloma is a benign condition that can occur in the breast following trauma, breast biopsy, or surgical procedures. Cholesterol granuloma can mimic breast cancer on imaging studies. This report is of a case of an enlarging breast mass due to a repeat needle biopsy in the vicinity of a previous biopsy that resulted in a cholesterol granuloma that appeared to increase in size on ultrasound imaging. The mammographic and high-resolution sonographic imaging features of cholesterol granuloma of the breast are described, with a review of the literature of published cases of cholesterol granuloma of the breast diagnosed on imaging.  
**Case Report:** A 52-year-old woman had undergone multiple rounds of breast ultrasound scans for multiple breast nodules. At six-month follow-up with a needle biopsy was performed that showed benign cystic change. At 18-months follow-up high-resolution sonographic imaging showed a circumscribed, oval, hypoechoic mass with a benign morphology in the vicinity of the biopsy site. The size of the hypoechoic nodule increased progressively, and histopathology confirmed the diagnosis of a benign cholesterol granuloma.  
**Conclusions:** This case demonstrated that cholesterol granuloma of the breast can increase in size after repeats adjacent breast biopsy, and may retain benign morphological features on ultrasound imaging, despite increasing in size.

**MeSH Keywords:** Biopsy • Breast • Mammography • Ultrasonography, Cholesterol Granuloma

**Full-text PDF:** <https://www.amjcaserep.com/abstract/index/idArt/914282>

1569 1 4 17



## Background

Cholesterol granuloma is a benign condition that can occur in the breast following trauma, breast biopsy, or surgical procedures. Cholesterol granuloma can mimic breast cancer on imaging studies. Currently, there have been 21 cases of cholesterol granuloma of the breast reported in the English literature [1–16]. The breast ultrasound or mammographic features of cholesterol granuloma have been described in 15 of these reports [1–3,5–14], while 11 of the reports also showed imaging findings [1–3,6–14]. The mammographic features of cholesterol granuloma have been described in 16 of these previous publications [1–3,6,8–15], and ten published reports also provided mammographic images [1–3,6,8–14].

This report is of a case of an enlarging breast mass due to a repeat needle biopsy in the vicinity of a previous biopsy that resulted in a cholesterol granuloma that appeared to increase in size on ultrasound imaging. The mammographic and high-resolution sonographic imaging features of cholesterol granuloma of the breast are described, with a review of the literature of published cases of cholesterol granuloma of the breast diagnosed on imaging.

## Case Report

A 52-year-old woman with a history of multiple breast nodules had undergone multiple rounds of mammography, performed with a Philips iU22 5-MHz to 12-MHz linear transducer (Philips Medical Systems, Bothell, WA, USA). The patient had no family history of breast cancer or chest wall trauma.

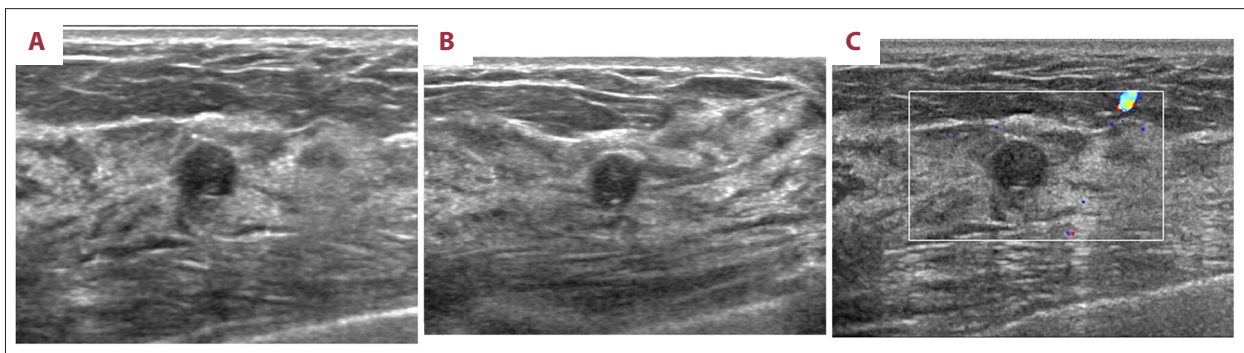
At the initial breast ultrasound scan, a circumscribed, round, hypoechoic mass, measuring 0.6 cm in diameter was identified in the right breast. The breast mass was without a posterior acoustic feature and was located at the 12 o'clock position of the right breast (Figure 1). The mass had no internal

vascularity on color Doppler ultrasound (Figure 1). Ultrasound imaging was not able to distinguish between a solid mass lesion or a complicated cyst with homogeneous internal echogenicity. The mass was classified as Breast Imaging-Reporting and Data System (BI-RADS) category III, or BI-RADS III (probably benign, short-interval follow-up recommended). Multiple cystic or hypoechoic nodular lesions with similar features were present in both breasts.

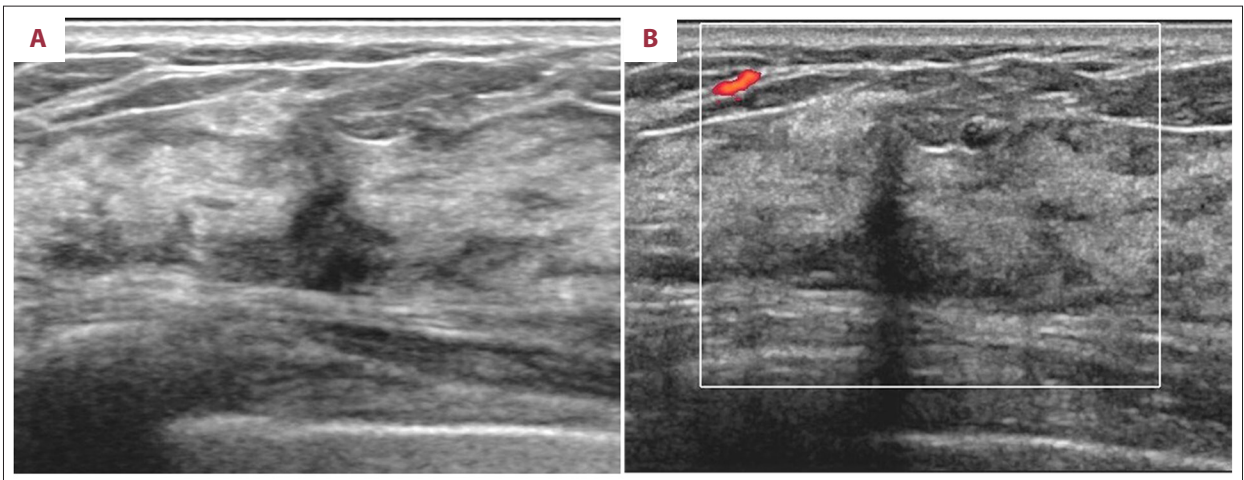
At six-month follow-up mammography, the mass at the 12 o'clock position of the right breast had not changed in size. However, a new focal non-mass lesion was detected at the 11 o'clock position in the right breast (Figure 2) and was classified as BI-RADS IVa (low level of suspicion for malignancy). Therefore a 14-gauge core needle biopsy was performed for the non-mass lesion. Histopathology confirmed a diagnosis of benign fibrocystic change.

At 18-month follow-up mammography, after the breast biopsy, the round mass at the 12 o'clock position of the right breast had slightly increased in size, from 0.6 cm to 0.7 cm, and had changed into an oval shape on longitudinal breast imaging (Figure 3). Mammography at that time revealed no corresponding abnormality in the mass at the 12 o'clock position in the right breast. The mass was again assessed as BI-RADS category 3 and follow-up breast ultrasound was recommended.

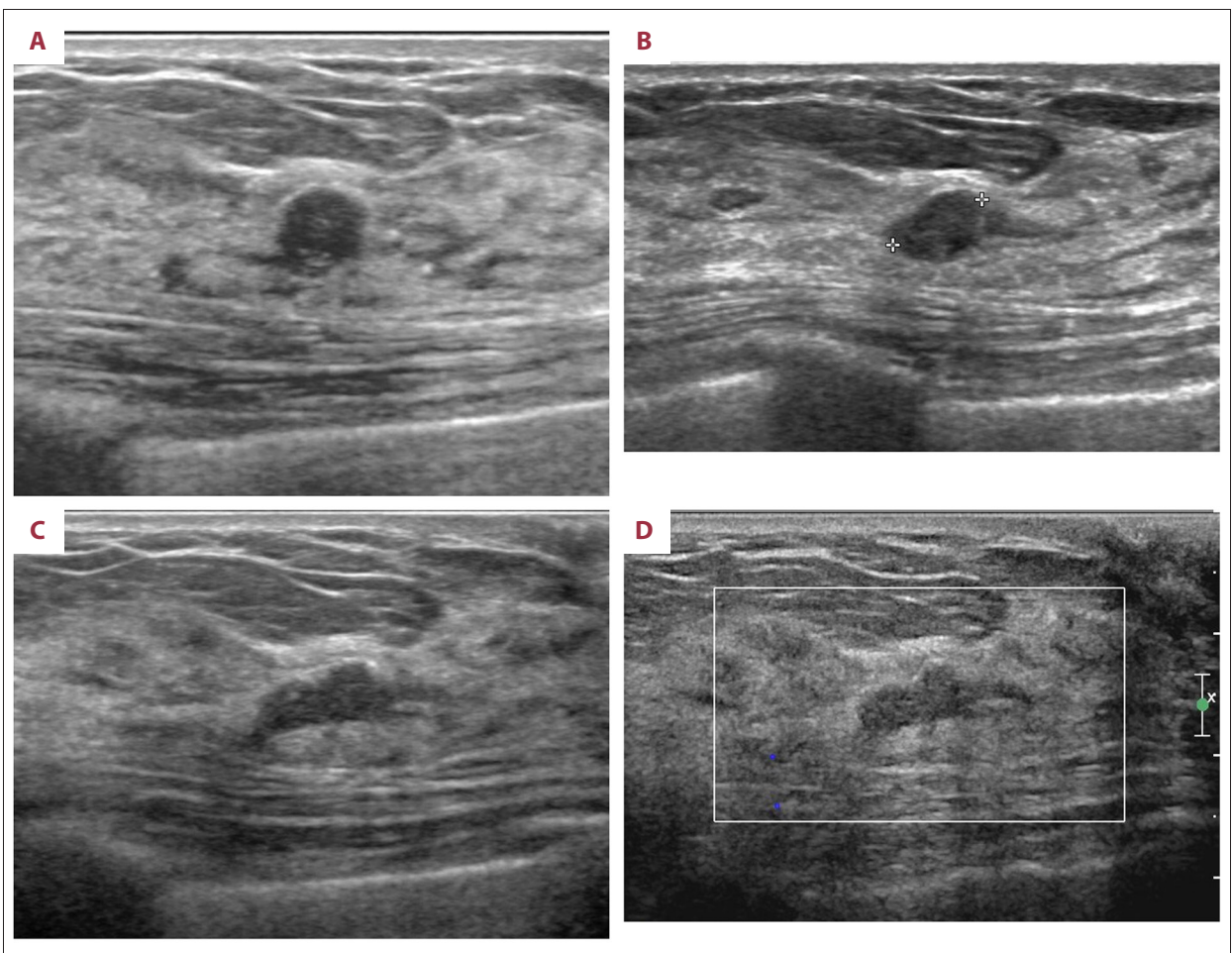
At the 25-month follow-up breast ultrasound after the biopsy, the mass at the 12 o'clock position of the right breast had further increased in size, from 0.7 cm to 0.9 cm, and had changed into a more elongated shape, in the longitudinal scan (Figure 3), and had no internal vascularity on color Doppler ultrasound (Figure 3). Mammography at that time also revealed no corresponding abnormality in the mass at the 12 o'clock position of the right breast. Although the mass was still assessed as BI-RADS III (probably benign, short-interval follow-up recommended), because the mass appeared to be increasing in size. Therefore, a further 14-gauge core needle biopsy of the



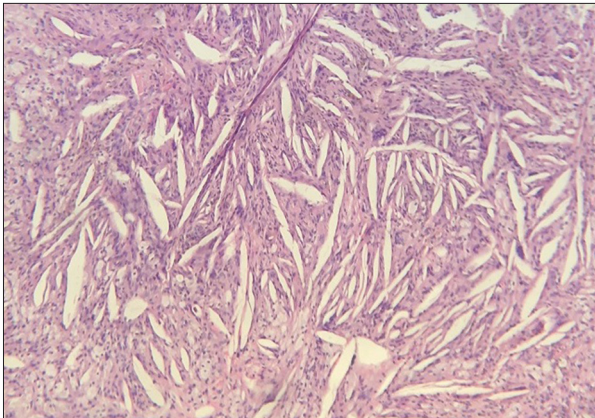
**Figure 1.** Initial ultrasound images of the right breast. (A, B) Initial transverse (A) and longitudinal (B) grayscale ultrasonograms of the right breast show a circumscribed, round, hypoechoic mass with no posterior features at the 12 o'clock position. (C) A color Doppler ultrasonogram demonstrates no vascularity within the mass.



**Figure 2.** Ultrasound images of the right breast at six-month follow-up. (A) At six-month follow-up, a transverse grayscale ultrasonogram shows a new focal non-mass lesion at the 11 o'clock position of the right breast. (B) A color Doppler ultrasonogram demonstrates no internal vascularity within the non-mass lesion.



**Figure 3.** Ultrasound images of the right breast at 18-months and 25-months after breast biopsy. (A–C) Successive grayscale ultrasonograms of the right breast prior to biopsy (A), and at 18 months (B), and at 25 months (C) after breast biopsy show a gradual increase in size in the longitudinal direction. Note the gradual changes from a round to an oval shape. (D) Color Doppler ultrasonogram at 25 months after biopsy shows no vascularity within the mass.



**Figure 4.** Photomicrograph of the histology of the breast biopsy shows typical features of a cholesterol granuloma. Histology shows the typical features of a benign cholesterol granuloma with needle-shaped spaces where cholesterol crystals have been dissolved during tissue processing, surrounded by chronic inflammation, histiocytes, and macrophage giant cells. Hematoxylin and eosin (H&E). Magnification  $\times 100$ .

breast was performed. Histopathology confirmed the diagnosis of a benign cholesterol granuloma (Figure 4).

Throughout the follow-up period, the patient did not present with a palpable breast mass or symptoms of breast disease.

## Discussion

Cholesterol granuloma is a benign non-neoplastic condition that has features of chronic inflammation [5]. The histological hallmark of cholesterol granuloma is fibrous granulation tissue, with abundant cholesterol crystals deposited centrally, surrounded by foreign-body giant cells [14]. Cholesterol granuloma is commonly described in the mastoid region and in the middle ear cavity, and is related to cholesteatoma, and has also been reported in other sites, including the parotid gland, lymph node, thyroglossal duct, kidneys, testis, liver, spleen, gall bladder, and peritoneum [2,3,9,14]. However, cholesterol granuloma is less common in the breast [7].

Cholesterol granuloma is a rare manifestation of mammary duct ectasia and duct rupture [7,14,15]. Some reports have suggested that mammary duct ectasia and subsequent periductal inflammation may result in rupture of a dilated duct [7]. The release of the lipid-rich content of the duct results in the formation of cholesterol crystals, leading to a foreign-body inflammatory reaction [7]. Other reports have suggested that periductal inflammation is the initial step, which causes damage to the elastic lamina of the duct wall, which is then followed by dilatation of the duct [7].

A history of previous breast biopsy or trauma can cause rupture of an ectatic breast duct [14,15]. Fat necrosis can also be associated with the formation of cholesterol granuloma [12,16]. Although a history of previous biopsy or trauma has been described as a possible underlying mechanism, only one case of cholesterol granuloma with this association has been identified by this author [12]. In this previously reported case, an excisional biopsy had been performed 40 years before the diagnosis of cholesterol granuloma, which developed adjacent to a surgical scar [12]. Duct ectasia was not found to be associated with cholesterol granuloma in this previously reported case [12].

To this author's knowledge, there have been no previous reports that have described the association between the development of cholesterol granuloma of the breast and a history of needle biopsy leading to the increase in the size of a pre-existing cholesterol granuloma also due to a previous needle biopsy of the breast. In the present case, the close spatial apposition and chronological context supported the relationship between the performance of the biopsy and the development of the cholesterol granuloma and enlargement of a pre-existing cholesterol granuloma.

In this case, the ultrasound features of the initial mass, prior to biopsy, raised the possibility of both a solid mass and a complicated cyst. Complicated cysts of the breast are sometimes difficult to differentiate from a solid mass [17]. Cysts are fluid-filled round or oval structures with an epithelial lining and usually arise from an obstructed duct [17]. Therefore, it is possible to deduce that the previous needle biopsy might have damaged a pre-existing complicated cyst.

The previously reported mammographic and ultrasound features of cholesterol granuloma have mainly emphasized the similarity with malignant breast lesions (Table 1). Reported suspicious mammographic features of cholesterol granuloma of the breast include a non-circumscribed margin [3,14], irregular shape [12], increased density [3,7,10,11], and calcifications [1,7,9,12,15]. Unusual annular calcifications were reported in one case [9]. Reported suspicious sonographic features included a non-circumscribed margin that was angular, ill-defined, and microlobulated [2,3,5,8,9,11], an irregular or lobulated shape [1,2,9–12,14], and complex cystic and solid echogenicity [7,13]. Complex cystic and solid echogenicity on ultrasound had been reported in two cases, in which corresponding features on the mammography were a circumscribed, oval, or round mass [7,13]. In two cases, breast carcinoma was present in close association with cholesterol granuloma, with the mass consisting of two components, the cholesterol granuloma and the breast cancer, which had contrasting imaging features on both ultrasound and magnetic resonance imaging (MRI) [1,10]. On ultrasound, part of the cholesterol granuloma was oval-shaped [1], or had hyperechoic internal echogenicity

**Table 1.** Summary of the findings from a review of the literature on previously published reports of cholesterol granuloma of the breast.

Authors	Year	Age (yrs)	Size (cm)	Mammography	US	MRI	FDG PET/CT	CT
Wilhelmus [15]	1982	64	4.5	ND	ND	ND	ND	ND
		56	NA	Suspicious calcification	ND	ND	ND	ND
		83	3.0	ND	ND	ND	ND	ND
		62	NA	ND	ND	ND	ND	ND
		70	0.6	Suspicious calcification	ND	ND	ND	ND
Reynolds [14]	1994	65	7.0	Partially ill-defined, noncalcified, isodense mass*	Slightly lobulated, homogeneous, hypoechoic, solid mass*	ND	ND	ND
Smith [13]	1997	51	3.5	Well-defined mass*	Large cyst with papillomatous intracystic mass*	ND	ND	ND
Ishizaki [12]	2001	74	0.8	Irregular mass with microcalcification*	Irregular hypoechoic mass with coarse internal echo*	ND	ND	ND
		51	1.5	Irregular mass without calcification	Irregular hypoechoic mass with a coarse internal echo	ND	ND	ND
Osada [11]	2002	62	0.7	High-density shadow lesion*	Ill-defined, irregular, hypoechoic mass*	ND	ND	ND
Furuhira [10]	2004	78	2.0	Circumscribed, oval, dense mass*	Heterogeneous lobulated mass composed of two parts*	Malignant time-intensity profile	ND	ND
					1. a slightly hyperechoic internal echo with increased posterior echo; 2. a hypoechoic internal echo with decreased posterior echo.			
Kim [8]	2008	60	1.1	Circumscribed mass without calcification	Microlobulated, round, hypoechoic mass*	ND	ND	ND
Garofalo [9]	2008	42	1.5	Annular calcification*	Ill-defined, irregular, hypoechoic mass*	ND	ND	ND
Bezic [6]	2013	55	0.6	Not visible	Nodular, hypoechoic mass*	ND	ND	ND
		57	0.6	Not visible.	Round, hypoechoic mass, slight acoustic shadowing	ND	ND	ND

**Table 1 continued.** Summary of the findings from a review of the literature on previously published reports of cholesterol granuloma of the breast.

Authors	Year	Age (yrs)	Size (cm)	Mammography	US	MRI	FDG PET/CT	CT
Khan [5]	2013	28	4	ND	Ill-defined, circumscribed heterogeneous, hypoechoic mass	ND	ND	ND
Ahn [7]	2013	62	4.5	Circumscribed, round, high-density mass with scattered coarse heterogeneous calcifications and peripheral radiolucency*	Circumscribed, oval, complex echoic mass* No increased vascularity on color Doppler imaging*	ND	ND	ND
Martineau [4]	2015	72	0.8	ND	ND	ND	Focal nodule, low FDG avidity*	ND
Jeong [3]	2016	78	1	Indistinct, oval, hyperdense mass*	Partially angular, oval, isoechoic mass*, no internal vascularity on color Doppler imaging*	ND	ND	Oval, ill-defined, progressively enhancing mass*
Kim [2]	2017	48	1.6	Not visible*	Non-parallel, angular, irregular, hypoechoic mass*, no internal vascularity on color Doppler imaging*	ND	ND	ND
Hu [1]	2018	52	0.7	Progressively enlarging mass*	Progressively enlarging oval mass	Oval mass with mild progressive enhancement*	ND	ND
				A cluster of amorphous calcifications (concomitant IDC)*	Adjacent irregular hypoechoic mass with microcalcification (concomitant IDC)*	Adjacent irregular mass with rapid enhancement and washout pattern (concomitant IDC)*		
Kim	This case report	52	0.9	Not visible*	Circumscribed, oval, hypoechoic mass*	ND	ND	ND

US – ultrasound; MRI – magnetic resonance imaging; FDG PET/CT – fluorodeoxyglucose positron-emission tomography-computed tomography; CT – computed tomography; ND – not described; IDC – invasive ductal carcinoma. \* Imaging were reproduced as figures or written descriptions of the imaging features.

with increased posterior echogenicity [10], whereas the breast cancer component showed an irregular shape, internal microcalcifications [1], or hypoechoic internal echogenicity with decreased posterior echogenicity [10]. On MRI, the cholesterol granuloma had an oval shape with mild progressive enhancement, whereas the breast cancer component showed an irregular shape with rapid enhancement [1]. In the case of breast cancer associated with cholesterol granuloma, shear wave elastography showed marked stiffness of the overall mass [1].

Rarely, cholesterol granulomas have been detected incidentally using a fluorodeoxyglucose (FDG) positron-emission tomography/computed tomography (PET/CT) scan, which demonstrated a nodule with mild FDG-avidity [4]. Rarely, cholesterol granuloma has been detected incidentally on abdominal CT, with an oval, ill-defined, heterogeneously enhancing mass with progressive delayed enhancement [3]. On physical examination, cholesterol granuloma is frequently palpable and is usually firm, mobile, and nontender [5,7,9–15]. The frequency of a palpable mass on presentation was found in 12 of the 21 reported cases [5,7,9–15].

A longstanding palpable mass that does not increase in size can distinguish between cholesterol granuloma and breast

cancer [7]. However, unlike previously published reports, this case of cholesterol granuloma retained benign radiological features on successive ultrasound examinations, but it increased in size. It is likely that the majority of cholesterol granulomas may be undetected due to their benign radiological features, and only some cases of cholesterol granuloma that have unusual and suspicious radiological features have been highlighted.

## Conclusions

This case has shown that cholesterol granuloma can develop following core biopsy of the breast and that biopsy can enlarge a pre-existing cholesterol granuloma. Despite the increasing size of cholesterol granuloma, ultrasound imaging may confirm the benign features. Cholesterol granuloma can be considered as a rare differential diagnosis when a mass develops or increases in size after a breast biopsy and is in the vicinity of the biopsy site, especially in cases of suspected injury to pre-existing duct ectasia or cysts of the breast.

## Conflict of interest

None.

## References:

1. Hu CC, Chang TH, Hsu HH et al: T1-weighted dynamic contrast-enhanced magnetic resonance imaging (DCE-MRI) to distinguish between concurrent cholesterol granuloma and invasive ductal carcinoma of the breast: A case report. *Am J Case Rep*, 2018; 19: 593–98
2. Kim YS, Chang JM: Sonographic appearance of a cholesterol granuloma mimicking breast cancer. *J Clin Ultrasound*, 2017; 45(9): 608–11
3. Jeong SH, Lee EH, Hong HS et al: Cholesterol granuloma of the breast incidentally detected on dynamic abdominal CT: A case report. *J Korean Soc Radiol*, 2016; 74(1): 22–25
4. Martineau P, Pelletier-Galarneau M, Leung E: Cholesterol granuloma: An unusual and benign cause of focal FDG uptake in the breast detected on PET/CT. *Clin Nucl Med*, 2015; 40(11): e511–13
5. Khan R, Narula V, Jain A et al: Cholesterol granuloma of the breast mimicking malignancy. *BMJ Case Rep*, 2013; 2013: pii: bcr2013200108
6. Bezic J, Piljic-Burazer M: Breast cholesterol granuloma: A report of two cases with discussion on potential pathogenesis. *Pathologica*, 2013; 105(6): 349–52
7. Ahn HS, Kim SM, Yun BL et al: The unusual ultrasound features of a breast cholesterol granuloma manifesting as an intracystic mass: Case report and literature review. *Korean J Radiol*, 2013; 14(2): 179–82
8. Kim Je, Park IS, Lee KH, et al. Cholesterol granuloma of the breast: A case report. *J Korean Radiol Soc*, 2008; 58(6): 627–29
9. Garofalo S, Casolino C, Accurso A et al: Cholesterol granuloma of the breast with unusual ossification features (osseous metaplasia). *Pathol Res Pract*, 2008; 204(5): 353–56
10. Furuhiro C, Ohshima A, Shimada K et al: A case of breast cholesterol granuloma accompanied by cancer. *Breast Cancer*, 2004; 11(2): 210–13
11. Osada T, Kitayama J, Nagawa H: Cholesterol granuloma of the breast mimicking carcinoma: report of a case. *Surg Today*, 2002; 32(11): 981–84
12. Ishizaki M, Ohsumi S, Takashima S et al: Two cases of cholesterol granuloma of the breast. *Breast Cancer*, 2001; 8(2): 158–61
13. Smith GL, Hicks P, Wijesinghe DP et al: Cholesterol granuloma of the breast presenting as an intracystic papilloma. *Br J Radiol*, 1997; 70(839): 1178–79
14. Reynolds HE, Cramer HM: Cholesterol granuloma of the breast: A mimic of carcinoma. *Radiology*, 1994; 191(1): 249–50
15. Wilhelmus JL, Schrodt GR, Mahaffey LM: Cholesterol granulomas of the breast. A lesion which clinically mimics carcinoma. *Am J Clin Pathol*, 1982; 77(5): 592–97
16. Doring L, Wedemeier G: [Cholesterol granuloma of the female breast]. *Chirurg*, 1974; 45(11): 520–21 [in German]
17. Berg WA, Sechtin AG, Marques H et al: Cystic breast masses and the ACRIN 6666 experience. *Radiol Clin North Am*, 2010; 48(5): 931–87