

Available online at www.sciencedirect.com

ScienceDirect

journal homepage: www.elsevier.com/locate/radcr

Case Report

Painful bipartite patella following injury: a case report[☆]

Zineb Zerouali Boukhal*, Hasna Belgadir, Abdelhamid Jadib, Omar Amriss, Achta Adam Fadoul, Aicha Merzem, Nadia Moussali, Naima El Benna

Radiology Department August 20, Ibn Rochd University Hospital Center, Faculty of Medicine and Pharmacy of Casablanca, 6 Rue Lahcen Al Aarjoun, Casablanca 20250, Morocco

ARTICLE INFO

Article history:

Received 19 November 2021

Revised 29 November 2021

Accepted 3 December 2021

Keywords:

Bipartite patella

Trauma

Imaging

ABSTRACT

Bipartite patella is a normal variation in ossification development. This variation is usually asymptomatic but can cause persistent and debilitating anterior knee pain with an injury.

We report the case of a 56-year-old man complaining of persistent anterior left knee pain following trauma.

Standard knee radiographs show a bilateral Bipartite Patella appearance, and magnetic resonance imaging shows discrete bony edema of the cancellous bone of the accessory bone and about the synchondrosis explaining the anterior knee pain, associated with a crack in the posterior compartment of the medial meniscus.

Conservative care including medical treatment with non-steroidal anti-inflammatory drugs, physical therapy was used.

Magnetic resonance imaging is the most valuable diagnostic tool for evaluating detailed morphologic and pathologic changes in patients with the bipartite patella.

© 2021 The Authors. Published by Elsevier Inc. on behalf of University of Washington.

This is an open access article under the CC BY-NC-ND license

(<http://creativecommons.org/licenses/by-nc-nd/4.0/>)

Introduction

Bipartite patella is considered a normal variation in ossification development, occurring in approximately 2% to 5% of the population, in which the peripheral and accessory ossification

centers do not fuse with the main body of the patella. It is usually asymptomatic, of incidental radiological finding, and sometimes difficult to distinguish from a patella fracture. Only 2% of bipartite patellas may become symptomatic following trauma, overuse, or strenuous sports activity. The bipartite patella is one of the few variations of patella development.

[☆] Competing Interests: None.

* Corresponding author.

E-mail addresses: drzinebzerouali@gmail.com (Z. Zerouali Boukhal), dr.belgadir@hotmail.fr (H. Belgadir), jadibabdelhamid@gmail.com (A. Jadib), omaramriss3@gmail.com (O. Amriss), adamfadoula@gmail.com (A. Adam Fadoul), merzem.arr@gmail.com (A. Merzem), nmoussali@gmail.com (N. Moussali), elbennan@gmail.com (N. El Benna).
<https://doi.org/10.1016/j.radcr.2021.12.007>

1930-0433/© 2021 The Authors. Published by Elsevier Inc. on behalf of University of Washington. This is an open access article under the CC BY-NC-ND license (<http://creativecommons.org/licenses/by-nc-nd/4.0/>)

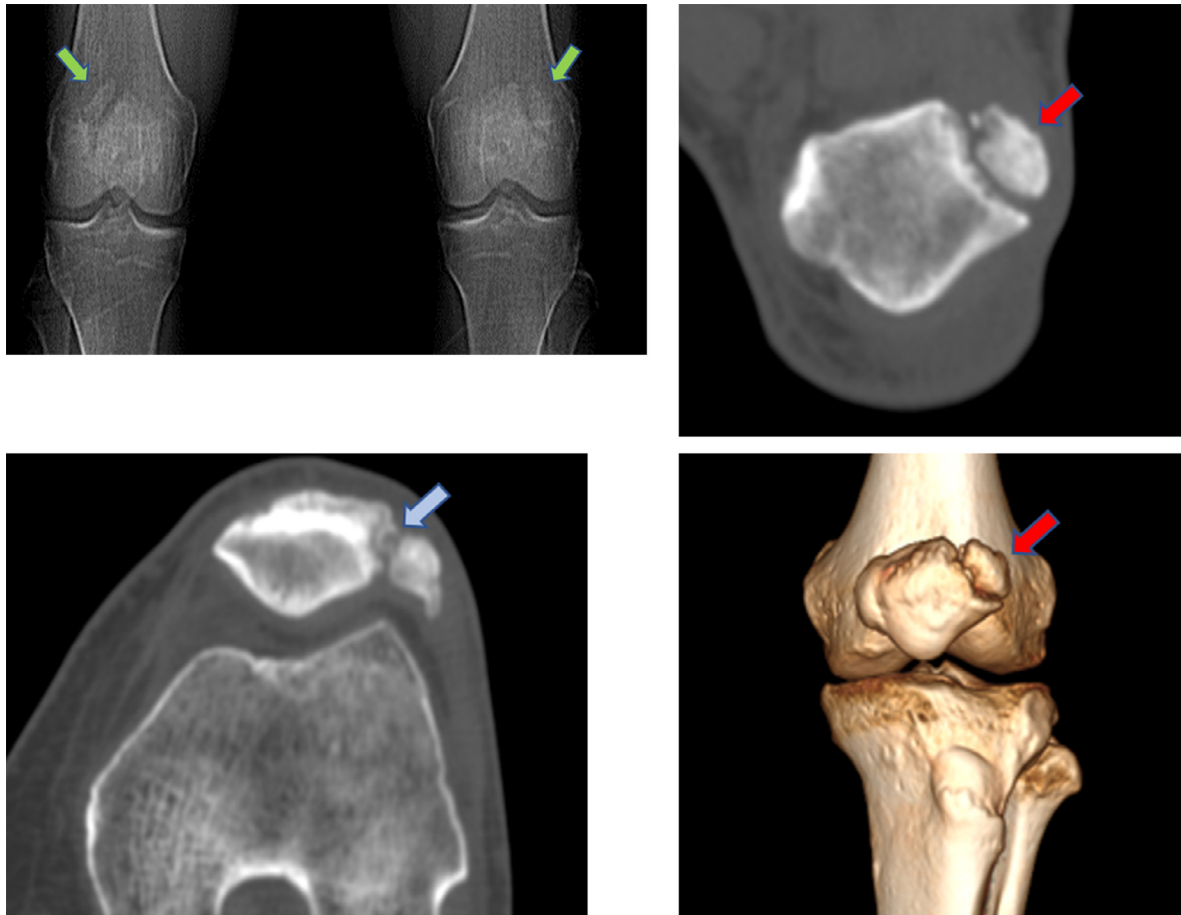


Fig. 1 – Frontal radiograph of the knees (A) and CT scan of the knees in coronal (B), axial (C), and Volume Rendering (D) reconstructions showing an appearance of the bilateral bipartite patella (green arrows) of interest in the superior-external portion (red arrows), with the irregular appearance of the synchondrosis (light blue arrow).

Case report

A 56-year-old man presented to the emergency room after a fall, complaining of persistent anterior left knee pain. After clinical examination, the meniscal rupture was suspected with patellar hypertrophy. Standard radiographs and CT scans of the knees revealed an appearance of bilateral patellar bipartite involving the superior-external part (classified as type III according to Saupe), with an irregular appearance of the synchondrosis (Fig. 1).

An magnetic resonance imaging (MRI) was performed 15 days after the date of injury and found a Bipartite Patella with discrete bony edema of the cancellous bone of the accessory bone and adjacent to the synchondrosis, associated with a crack in the posterior compartment of the medial meniscus classified as Stoller's grade III. She also found deep chondropathy adjacent to the trochlea with bone edema opposite. She also found a small multiloculated mucoid cyst of the posterior cruciate ligament (Fig. 2).

Conservative care including medical treatment with nonsteroidal anti-inflammatory drugs, physical therapy, and extracorporeal shock wave therapy was used, and the patient progressed well a few weeks after treatment.

Discussion

The patella is the largest sesamoid bone in the body and is located in the anterior part of the knee joint. It is the point of attachment for the quadriceps and patellar tendon and supports the extensor mechanism of the knee [1]. It presents as a cartilaginous structure that begins to ossify between the ages of 3 and 5 years and continues until 9 to 10 years of age. In the majority of cases, several small foci combine to form a central nest [2]. A single ossification center is observed in 77% of children, and two or three centers are observed in the others. In general, the centers unite to form a continuous subchondral plate. A bipartite patella results from failure of ossification of these centers, resulting in a fibrocartilaginous union between the patellar body and the bipartite fragment.

In some individuals, there may be multiple centers of ossification, resulting in a multipartite patella [3]. Saupe classified bipartite patellas into three groups based on the position of the accessory center: type I, at the inferior pole (5% of patients); type II, at the lateral margin (20%); and type III, at the superior-external pole (75%) [2,4].

Bipartite patella is a rare phenomenon, with a reported incidence ranging from 0.2% to 6%. It occurs more often in males

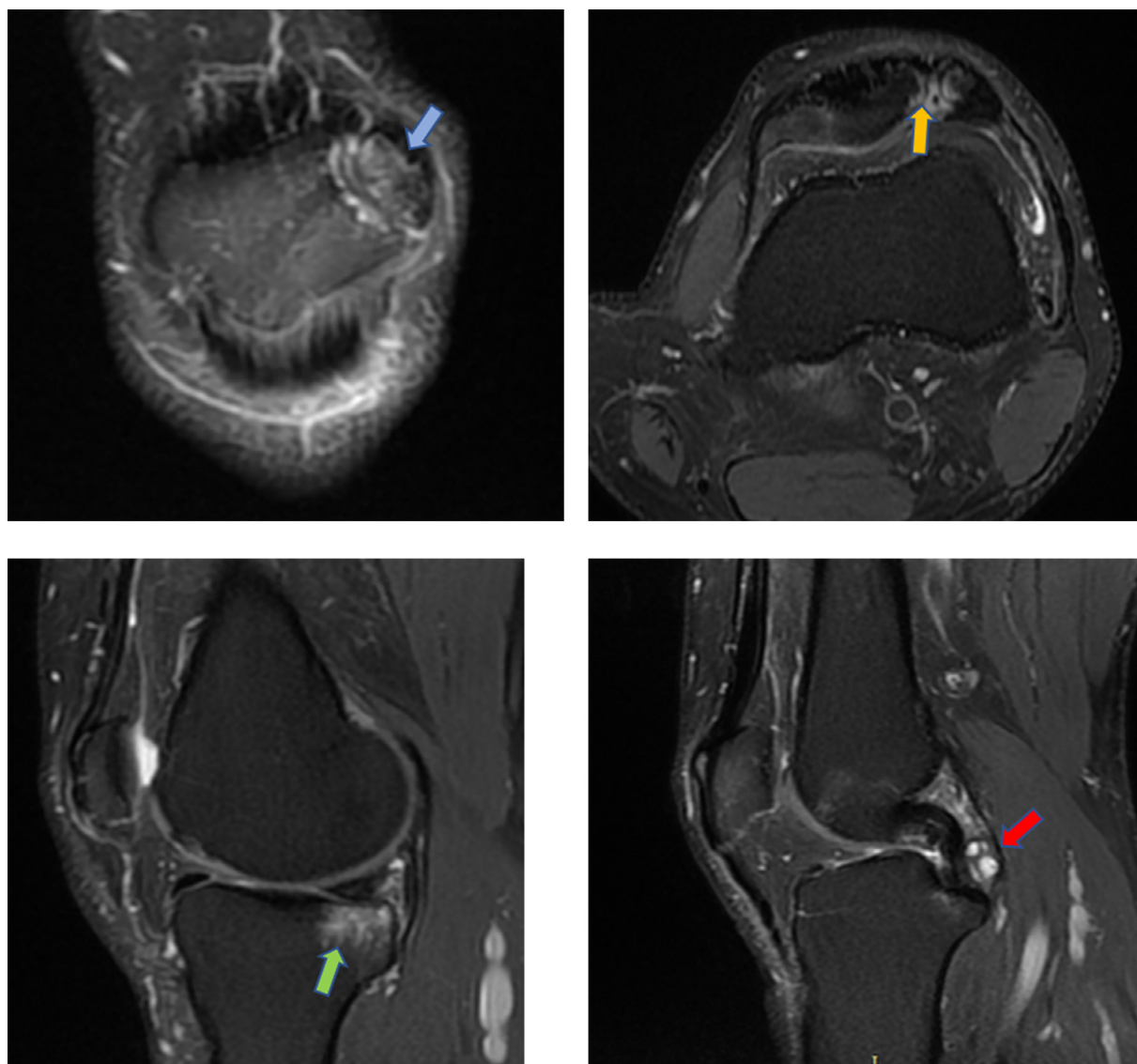


Fig. 2 – MRI of the right knee in coronal (A), axial (B) and sagittal Proton Density Fat Sat sequences (C, D): Bipartite patella with mild bony edema of the cancellous bone of the accessory bone (light blue arrow) and adjacent to the synchondrosis (orange arrow), associated with a fissure of the posterior compartment of the medial meniscus, and deep chondropathy adjacent to the trochlea with bony edema adjacent to it (green arrow) and small multiloculated mucoid cyst of the posterior collateral ligament (red arrow).

[5] and is bilateral in 50% of cases [3]. Less than 2% become symptomatic and require medical intervention [6,7].

The bipartite patella can be a cause of anterior knee pain, in young, active patients, following trauma, overuse, or strenuous sports activity. Patients report pain when squatting, climbing stairs, and jumping or during any movement in which the quadriceps extension mechanism is active.

This congenital anomaly is often reported as an incidental finding, without clinical significance. However, symptoms usually occur during overuse activities or direct trauma, typical of the sports population. Localized tenderness over the accessory fragment and symptoms of anterior knee pain usually occurs during activities involving knee extension, such as walking, stair climbing, and jump-

ing, or during knee flexions, such as prolonged sitting or squatting [2].

Physical examination reveals localized tenderness over the superior-external pole of the patella. An unusual prominence or palpable defect may be present. The patient may present with a larger-than-normal patella, effusion, or hematoma on the accessory fragment and inhibition of quadriceps function [2].

X-ray and CT scan only provide insight into the anatomical structure of the variant. MRI can successfully explain patients' symptoms by detecting bone marrow edema [1].

Radiographs were taken in anteroposterior projection show, in most circumstances, a well-corrected fragment adjacent to the superior-external aspect of the patella.

Magnetic resonance imaging (MRI) is the appropriate method to evaluate a patient with the bipartite patella and anterior knee pain.

Identification of edema at or near the bipartite fragment along the margins of the synchondrosis or pseudarthrosis on MRI [8], best seen on T2-weighted imaging with fat saturation [3], may indicate that the bipartite patella is the primary cause of symptoms. CT also reveals the bipartite fragment, but it does not identify bone marrow or soft tissue edema [2].

Ultrasound can also be used for diagnosis, which is based on the identification of a discontinuity of the patella with an area of low echogenicity at the interface, and irregularity of the bone contour [3]. Scintigraphy can be useful in the diagnosis of the symptomatic bipartite patella in doubtful cases. The increased radiotracer uptake localized around the fragment represents stress, which is caused by mobility along the chondro osseous junction.

Initial treatment of symptomatic bipartite patella is conservative. Most cases improve with restriction and rest from sports activities. In medical treatment, nonsteroidal anti-inflammatory drugs are used primarily [1].

Surgical treatment can be used for those who do not respond to conservative treatment. Surgical methods include excision of the fragment, soft tissue procedures such as lateral retinaculum release and vastus lateralis, and open reduction and internal fixation of the painful fragment [6,9].

Conclusion

MRI is the most valuable diagnostic tool for evaluating detailed morphologic and pathologic changes in patients with the bipartite patella.

Patient consent

Written and informed consent for publication of the case was obtained from the patient.

REFERENCES

- [1] Akdag T, Guldogan E, Coskun H, Turan A, Hekimoglu B. Magnetic resonance imaging for diagnosis of bipartite patella: usefulness and relationship with symptoms. *Pol J Radiol* 2019;84:491–7. doi:10.5114/pjr.2019.91163.
- [2] Matic GT, Flanigan DC. Return to activity among athletes with a symptomatic bipartite patella: a systematic review. *The Knee* 2015;22:280–5. doi:10.1016/j.knee.2015.01.005.
- [3] O'Brien J, Murphy C, Halpenny D, McNeill G, Torreggiani WC. Magnetic resonance imaging features of asymptomatic bipartite patella. *Eur J Radiol* 2011;78:425–9. doi:10.1016/j.ejrad.2009.11.001.
- [4] Zabierek S, Zabierek J, Kwapisz A, Domzalski ME. Bipartite patella in 35-year-old fitness instructor: A case report. *Int J Sports Phys Ther* 2016;11(5):777–83.
- [5] Oohashi Y, Koshino T, Oohashi Y. Clinical features and classification of bipartite or tripartite patella. *Knee Surg Sports Traumatol Arthrosc* 2010;18:1465–9. doi:10.1007/s00167-010-1047-y.
- [6] Matic GT, Flanigan DC. Efficacy of surgical interventions for a bipartite patella. *Orthopedics* 2014;37:623–8. doi:10.3928/01477447-20140825-07.
- [7] Çarlı AB, Turgut H. A rare cause of anterior knee pain: bipartite patella. *Joint Bone Spine* 2017;84:359. doi:10.1016/j.jbspin.2016.03.010.
- [8] Kavanagh EC, Zoga A, Omar I, Ford S, Schweitzer M, Eustace S. MRI findings in bipartite patella. *Skeletal Radiol* 2007;36:209–14. doi:10.1007/s00256-006-0232-z.
- [9] Oohashi Y. Developmental anomaly of ossification type patella partita. *Knee Surg Sports Traumatol Arthrosc* 2015;23:1071–6. doi:10.1007/s00167-014-2887-7.