

# EFFICACY OF INTRAVITREAL AFLIBERCEPT IN MACULAR TELANGIECTASIA TYPE 1 IS LINKED TO THE OCULAR ANGIOGENIC PROFILE

LAURA KOWALCZUK, PhD,\* ALEXANDRE MATET, MD,\* ALI DIRANI, MD,\*  
ALEJANDRA DARUICH, MD,\* AUDE AMBRESIN, MD,\* IRMELA MANTEL, MD,\*  
RICHARD F. SPAIDE, MD,† NATACHA TURCK, PhD,‡ FRANCINE BEHAR-COHEN, MD, PhD\*

**Purpose:** To evaluate intravitreal aflibercept in macular telangiectasia Type 1 (MacTel 1) patients and measure their ocular angiogenic profile.

**Methods:** Eight subjects with MacTel 1 refractory to bevacizumab, ranibizumab, or laser therapy and switched to aflibercept were included. Best-corrected visual acuity, central macular thickness, and cystic areas quantified on optical coherence tomography B-scans were assessed during 12 months. Perifoveal capillary densities were measured on optical coherence tomography angiography. Aqueous humor was sampled from six patients and eight control subjects undergoing cataract extraction. Growth factors were quantified using a multiarray immunoassay.

**Results:** Over 12 months, patients received  $6.6 \pm 1.4$  (range, 5–8) intravitreal aflibercept injections. Twelve months after switching to aflibercept, best-corrected visual acuity increased by  $\geq 5$  letters in 5 of 8 patients, compared with preaflibercept levels. Mean best-corrected visual acuity improved from 79.6 ( $\sim 20/50$ ) to 88.0 ( $\sim 20/35$ ) Early Treatment Diabetic Retinopathy Study letters ( $P = 0.042$ ), and central macular thickness decreased from  $434 \pm 98 \mu\text{m}$  to  $293 \pm 59 \mu\text{m}$  ( $P = 0.014$ ). Compared with control subjects, the profile of angiogenic factors in MacTel 1 eyes revealed no difference in vascular endothelial growth factor-A levels but significantly higher levels of placental growth factor ( $P = 0.029$ ), soluble vascular endothelial growth factor receptor-1 (sFlt-1;  $P = 0.013$ ), vascular endothelial growth factor-D ( $P = 0.050$ ), and Tie-2 ( $P = 0.019$ ). Placental growth factor levels inversely correlated with both superficial and deep capillary plexus densities on optical coherence tomography angiography ( $P = 0.03$ ).

**Conclusion:** The clinical response to aflibercept coupled to the angiogenic profile of MacTel 1 eyes support the implication of the placental growth factor/Flt-1 pathway in MacTel 1.

RETINA 37:2226–2237, 2017

“Idiopathic juxtafoveal telangiectasia” is a generic term that encompasses different clinical entities first classified by Gass and Oyakawa in 1982,<sup>1</sup> then by Gass and Blodi in 1993.<sup>2</sup> In 2006, Yannuzzi et al<sup>3</sup> proposed a simplified classification under the term “idiopathic macular telangiectasia,” with 2 distinct types: Type 1, “aneurysmal telangiectasia,” and Type 2, “perifoveal telangiectasia,” also known as MacTel. These classifications are based on the clinical features because no specific molecular signature or pathogenic mechanisms have yet been identified.

Idiopathic macular telangiectasia Type 1 (MacTel 1) is usually unilateral and affects mostly men of 40 years

to 50 years of age at presentation.<sup>1</sup> Microvascular ectasia and increased tortuosity of the macular capillary network are visible on fundus examination, may extend to the temporal side of the macula over an area of 2 disk diameter or greater,<sup>1,2</sup> and may be associated to peripheral vascular changes.<sup>3</sup> Telangiectasia frequently causes macular edema with lipid exudates of variable severity and subsequent vision loss. Location, morphologic feature, and degree of leakage of the microvascular ectasia and capillary nonperfusion are best identified on fluorescein angiography.

Whether MacTel 1 is a milder, later, and more central form of Coats disease is debated because both entities

associate vascular telangiectasia with aggressive exudation, unilateral involvement, and male predominance.<sup>3–5</sup> To confirm the diagnosis of MacTel 1, disorders causing secondary telangiectasia must be excluded, which included retinal vein occlusion, diabetic retinopathy, ocular ischemic syndrome, hypertensive retinopathy, and more rarely posterior segment inflammation, radiation maculopathy, sickle-cell maculopathy, or localized retinal capillary hemangioma.

MacTel 1 is a rare disease, and there is no consensus regarding treatment schemes. Laser photocoagulation can be performed on accessible ischemic areas but may also target leaky aneurysms. Intravitreal anti-vascular endothelial growth factor (VEGF) therapy has also been assessed, with inconstant results. Although bevacizumab<sup>6,7</sup> and ranibizumab<sup>8,9</sup> showed some efficacy in reducing macular edema and improving vision, three case series reported that only a minority of patients responded favorably to intravitreal bevacizumab.<sup>10–12</sup> Recently, three groups reported that MacTel 1 patients may be nonresponders or become refractory to bevacizumab<sup>13–15</sup> or ranibizumab,<sup>15</sup> including two case reports describing a favorable response after switching to intravitreal aflibercept.<sup>14,15</sup> Aflibercept is a soluble decoy receptor that associates an immunoglobulin backbone to extracellular sequences of the VEGF receptors, VEGFR-1 (also called Flt-1) and VEGFR-2. In contrast to specific anti-VEGF antibodies such as bevacizumab and ranibizumab, which bind to the VEGF-A isoform only, aflibercept also blocks

another ligand of Flt-1, placental growth factor (PlGF). Through its binding to Flt-1, PlGF is suspected to enhance vascular permeability and to amplify the effects of VEGF on pathologic angiogenesis.<sup>16</sup> Also, PlGF has been implicated in the resistance to anti-VEGF treatments in patients with malignant tumors<sup>17,18</sup> and various retinal diseases, including diabetic macular edema.<sup>19,20</sup> Aflibercept may overcome this hurdle by neutralizing PlGF along with VEGF.<sup>21,22</sup> Interestingly, in an adult rat model, the overexpression of rat PlGF did not induce preretinal neovessels, as observed when VEGF is overexpressed,<sup>23</sup> but produced retinal vessel abnormalization manifested by tortuosity, dilation, and capillary aneurysms,<sup>24</sup> suggesting a potential role of PlGF in the pathogenesis of aneurysmal telangiectasia.

In this context, the aim of this study was to retrospectively evaluate the effect of intravitreal aflibercept therapy in patients with macular edema caused by MacTel 1 and to correlate it to the profile of angiogenic factors in aqueous humor.

## Methods

### Subjects

This retrospective interventional case series involving eight human subjects and eight healthy control subjects adhered to the tenets of the Declaration of Helsinki. The protocol was approved by the local Ethics Committee of the Swiss Department of Health on research involving human subjects (CER-VD N° 95/15 and 340/15) and by an Institutional Review Board from the Western Institutional Review Board (Puyallup, WA). All patients signed an informed consent form before aqueous humor sampling. Six consecutive patients followed from December 2013 to July 2015 at the Jules-Gonin Eye Hospital (Lausanne, Switzerland) and two consecutive patients followed at the Vitreous, Retina, Macula Consultants of New York (New York, NY) were included in this study. Inclusion criteria were as follows: 1) macular edema caused by idiopathic MacTel 1 without medical or ophthalmologic history suggesting secondary macular telangiectasia and 2) persistence of macular edema after a well-conducted treatment by retina specialists with intravitreal bevacizumab (Avastin; Genentech, Inc, South San Francisco, CA), ranibizumab (Lucentis; Novartis Pharma AG, Basel, Switzerland, and Genentech, Inc), and/or laser photocoagulation, justifying a treatment switch to intravitreal aflibercept (Eylea; Bayer, Leverkusen, Germany).

Eight sex-matched and age-matched patients undergoing cataract surgery and having no history of diabetes or retinal disease were included during the same period as control subjects for aqueous humor sampling.

---

From the \*Department of Ophthalmology, University of Lausanne, Jules-Gonin Eye Hospital, Fondation Asile des Aveugles, Lausanne, Switzerland; †Vitreous, Retina, Macula Consultants of New York and LuEsther T. Mertz Retina Research Center, Manhattan Eye, Ear and Throat Hospital, New York, New York; and ‡Department of Human Protein Science, University of Geneva, Geneva, Switzerland.

Supported by a grant from the Lowy Medical Research Institute LTD. This work was supported by Swiss National Science Foundation Grants to N. Turck (#PMPDP3\_158370), and F. Behar-Cohen (#320030\_156401).

F. Behar-Cohen is a consultant for Bayer, Novartis, Allergan, and Genentech. The remaining authors have no any conflicting interests to disclose.

L. Kowalczyk and A. Matet contributed equally to the work.

Supplemental digital content is available for this article. Direct URL citations appear in the printed text and are provided in the HTML and PDF versions of this article on the journal's Web site ([www.retinajournal.com](http://www.retinajournal.com)).

The study was performed in the Fondation Asile des Aveugles, Jules-Gonin Eye Hospital, which is the Department of Ophthalmology of the University of Lausanne.

This is an open-access article distributed under the terms of the Creative Commons Attribution-Non Commercial-No Derivatives License 4.0 (CCBY-NC-ND), where it is permissible to download and share the work provided it is properly cited. The work cannot be changed in any way or used commercially without permission from the journal.

Reprint requests: Francine Behar-Cohen, MD, PhD, Jules-Gonin Eye Hospital, Avenue de France 15, CP 133, CH-1000, Lausanne 7, Switzerland; e-mail: [francine.behar@gmail.com](mailto:francine.behar@gmail.com)

### *Patient Treatment and Follow-up*

After two initial monthly loading doses, patients received intravitreal aflibercept on a pro re nata (as needed) regimen. Decision for reinjection was made by two retina specialists (R.F.S. or F.B.-C.), and reinjections were performed at an interval of 4 weeks or more. They were indicated in case of persistent or recurrent macular edema manifesting by intraretinal cysts and/or subretinal fluid.

At all visits, best-corrected visual acuity was measured using an Early Treatment Diabetic Retinopathy Study chart, and serial spectral-domain optical coherence tomography (SD-OCT) images on Spectralis (Heidelberg Engineering, Heidelberg, Germany) were obtained. Confocal fluorescein and indocyanine green angiography on Spectralis had been performed in all cases at presentation for the diagnosis of MacTel 1 and were repeated at the discretion of the treating retina specialist. Images of OCT angiography (OCTA) were acquired using the Angiovue RTx 100, based on the AngioVue Imaging System (Optovue, Inc, Fremont, CA).

Clinical charts were retrospectively reviewed, and data were recorded at baseline (corresponding to the last visit before the first intravitreal aflibercept injection), 1 month, and 3, 6, and 12 months after baseline.

### *Spectral-Domain Optical Coherence Tomography Imaging and Quantification of Intraretinal Cysts Area*

At each time point, high-quality, 30° horizontal, single, SD-OCT B-scans and 20° × 20° 97-section horizontal grids were acquired using the follow-up mode on Spectralis. The central macular thickness (CMT) was automatically measured in the central sub-field of an Early Treatment Diabetic Retinopathy Study grid on the built-in software. For graphical purposes, the boundaries of the cystoid edema regions were outlined with a red contour and superimposed over the original SD-OCT images, using a custom semiautomated algorithm on Matlab (Version R2015b; Mathworks, Natick, MA) detailed in the **Supplemental Digital Content 1** (see **Figure**, <http://links.lww.com/IAE/A563>).

### *Optical Coherence Tomography Angiography Imaging and Macular Capillary Density*

The OCTA Angiovue RTx 100 instrument was used to obtain amplitude decorrelation angiography images. This instrument has an A-scan rate of 70,000 scans per second, using a light source centered on 840 nm and a bandwidth of 50 nm. Each OCTA volume contains

304 × 304 A-scans with 2 consecutive B-scans captured at each fixed position before proceeding to the next sampling location. Split-spectrum amplitude-decorrelation angiography was used to extract the OCTA information. Each OCTA volume is acquired in 3 seconds, and 2 orthogonal OCTA volumes are acquired to perform motion correction. Angiography information displayed is the average of the decorrelation values when viewed perpendicularly through the thickness being evaluated.

To obtain comparable 3 × 3-mm OCTA scans between subjects, volumes were automatically segmented by the built-in software to provide images of the superficial plexus (3 μm below the inner limiting membrane to 16 μm below the outer border of the inner plexiform layer) and deep plexus (16–69 μm below the outer border of the inner plexiform layer). The correct segmentation for each patient was controlled before reporting the capillary densities calculated using the AngioVue software.

### *Aqueous Humor Sampling*

At the time of an aflibercept intravitreal injection indicated for macular edema, 50 μL to 150 μL of aqueous humor were sampled by anterior chamber tap before the injection, using a 30-gauge needle and a 1-mL syringe, and immediately frozen at –80°C. Before aqueous humor sampling, a time lapse of at least 7 weeks from the previous anti-VEGF injection (ranibizumab, bevacizumab, or aflibercept) was observed in all patients. Given that pharmacologic observations<sup>25–27</sup> and mathematical models<sup>28</sup> have estimated the vitreous elimination half-life ( $t_{1/2}$ ) of ranibizumab, bevacizumab, and aflibercept to be, respectively,  $t_{1/2} = 3.2$  days to 7.2 days,  $t_{1/2} = 4.9$  days to 5.6 days, and  $t_{1/2} = 4.6$  days to 4.8 days,<sup>25–28</sup> aqueous sampling was performed when no residual anti-VEGF drug remained in the vitreous, after a clearance time of  $\geq 7 \times t_{1/2}$ . In the control group, the anterior chamber tap was performed at the beginning of cataract surgery before any fluid was injected into the anterior chamber.

### *Angiogenic Factor Levels in Aqueous Humors*

Aqueous humor levels of soluble VEGFR-1 (sFlt-1), PlGF, the tyrosine kinase receptor Tie-2 with immunoglobulin-2 and EGF-like domains (Tie-2), VEGF-A<sub>165</sub>, VEGF-C, VEGF-D, and basic fibroblast growth factor were measured, on the same plate, using a multiarray high-sensitive immunoassay (V-PLex Angiogenesis Panel 1 Kit; Meso Scale Discovery, Rockville, MD). This standardized kit was used according to the manufacturer's

instructions. Standard curves for each angiogenic factor were generated with the provided calibration kit, and the samples were assayed in duplicate, without dilution. Data acquisition and analysis were performed with the Meso Scale reader (MSD Quickplex SQ-120; Meso Scale Diagnostics, Rockville, MD) and its dedicated software (Discovery Benchmark Version 4.0.12). Detection thresholds for all angiogenic factors were set between 1 pg/mL and 20 pg/mL, and coefficients of variation were inferior to 10%.

*Statistical Analysis*

Results were expressed as mean ± standard deviation. Biologic and clinical analyses were carried out on GraphPad Prism 5 (GraphPad Software, Inc, La Jolla, CA). The nonparametric Mann–Whitney *U* test and Wilcoxon paired test were used to compare data, when applicable. Spearman correlation was used to evaluate relationships between angiogenic factors levels and clinical parameters. A 2-tailed *P* value of <0.05 was considered statistically significant.

**Results**

*Patient Characteristics*

Eight patients with MacTel 1 (7 men and 1 women) with a mean age of 63.0 ± 10.3 years (range, 45–74 years) were included in this study. Clinical characteristics, previous treatments, and number of intravitreal aflibercept injections are reported in Table 1. All patients had been previously treated with extramacular and/or macular laser photocoagulation, combined with intravitreal anti-VEGF therapy in seven patients. Four patients had

received bevacizumab, two patients had received ranibizumab, and one patient had received sequentially bevacizumab, ranibizumab, and dexamethasone implant. After an optimal treatment regimen with these therapies, the patients had a mean CMT of 434 ± 98 μm. Over the 12-month study period, they received 6.6 ± 1.4 intravitreal aflibercept injections (range, 5–8 injections).

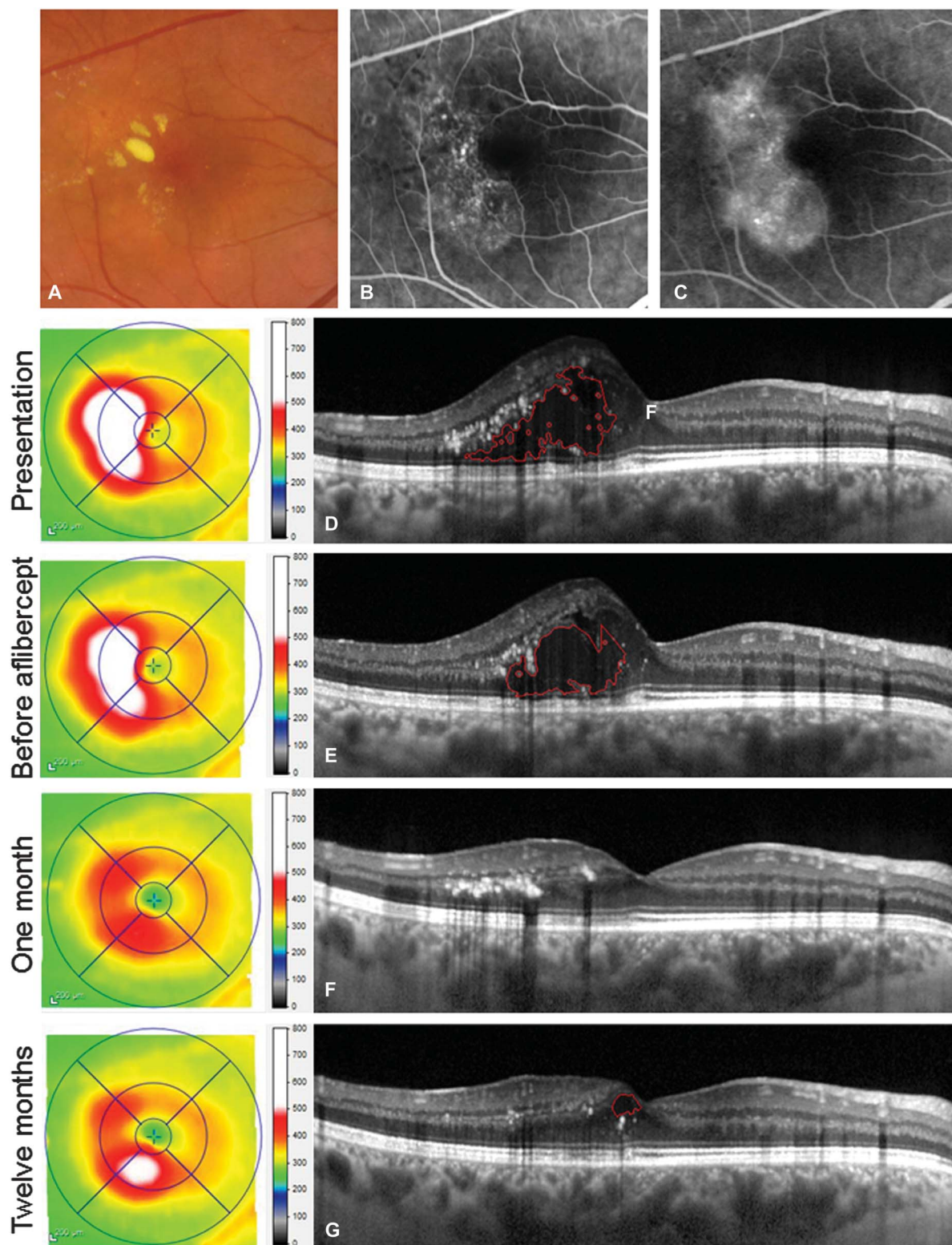
*Effect of Intravitreal Aflibercept Therapy*

A clinical illustration of a patient refractory to bevacizumab therapy and responsive to aflibercept therapy is provided in Figure 1 (Case 4). Figure 2 shows the baseline and 12-month SD-OCT B-scans and corresponding thickness maps from the 8 patients included in this study, demonstrating the clinical response to aflibercept treatment.

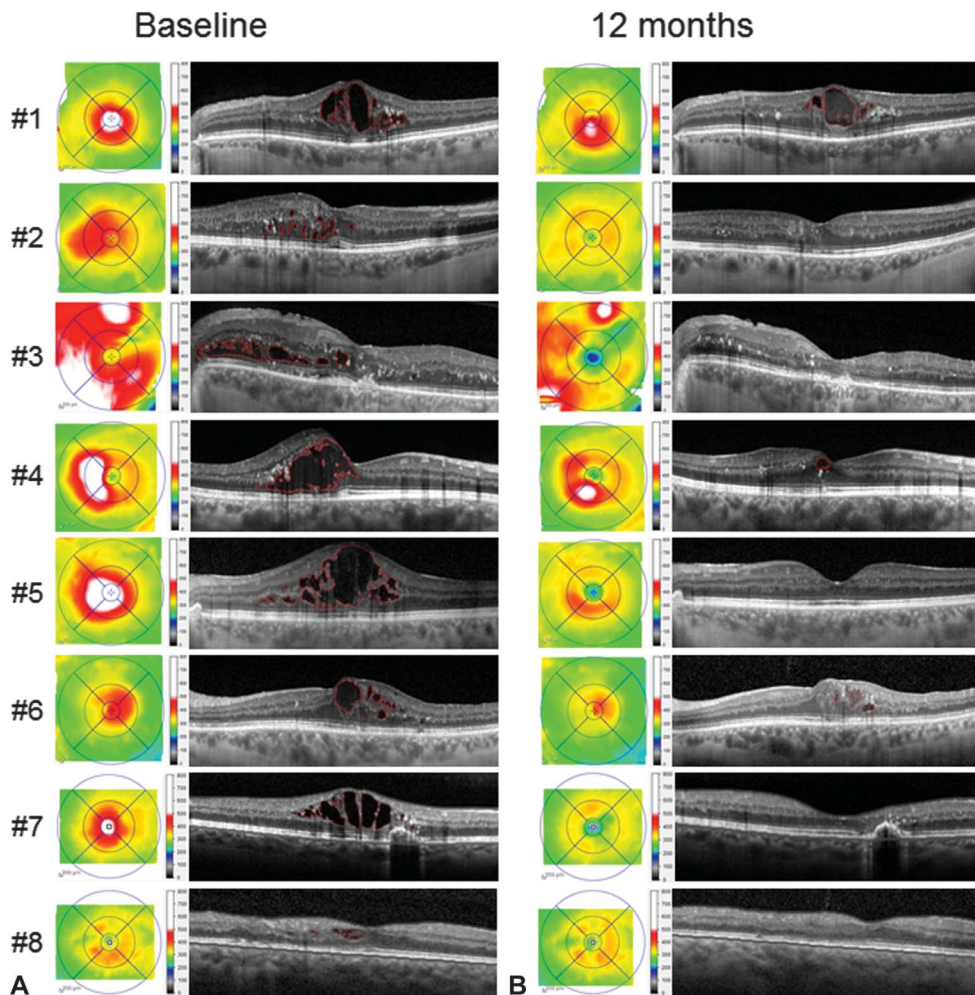
The anatomical and visual outcomes of intravitreal aflibercept therapy by 12 months are summarized in Table 2. The CMT decreased in all patients, with a significant reduction from 434 ± 98 μm to 293 ± 59 μm (*P* = 0.014). The best-corrected visual acuity improved in 7 of 8 patients with a mean significant improvement from 79.6 ± 16.3 (~20/52) letters to 88.0 ± 11.2 (~20/35) Early Treatment Diabetic Retinopathy Study letters (*P* = 0.042). There was an improvement by five or more Early Treatment Diabetic Retinopathy Study letters in five of eight patients. Both anatomical and visual parameters improved progressively over time, as illustrated in Figure 3. After 1 intravitreal aflibercept injection, a reduction in CMT was observed in all patients, with a significant reduction as compared with baseline (308.6 ± 32.9 μm; *P* = 0.016) that was maintained over the 12-month follow-up. By Month 6, visual acuity levels significantly

Table 1. Clinical Characteristics and Treatment History of 8 Patients With MacTel 1, Refractory to Previous Therapies and Treated by Intravitreal Aflibercept During a 12-Month Period

Eye#	Age, Years	Sex	Treatments Received Before Aflibercept		CMT Before Aflibercept Initiation, μm	Intravitreal Aflibercept Injections Over 12 Months
			Laser Photocoagulation	Intravitreal Injections (Number)		
1	71	M	Macular + extramacular	Ranibizumab (8)	528	8
2	68	M	Macular + extramacular	Ranibizumab (1)	394	7
3	56	M	Macular + extramacular	Bevacizumab (10)	348	5
4	45	M	Macular	Bevacizumab (6)	396	5
5	54	M	Macular (subthreshold) + extramacular	None	595	7
6	74	M	Macular + extramacular	Bevacizumab (6)	393	8
7	72	F	Macular + photodynamic therapy	Bevacizumab (2) + ranibizumab (2) + dexamethasone (1)	508	8
8	64	M	Macular	Bevacizumab (5)	312	5



**Fig. 1.** Differential effects of bevacizumab and aflibercept on macular edema in a 45-year-old patient with MacTel 1 (Case 4). **A.** Color fundus photograph showing capillary dilations and hard exudates. **B** and **C.** Fluorescein angiography frames at 47 seconds (**B**) and 3.5 minutes (**C**) after dye injection showing leaky microaneurysms. **D–G.** Horizontal optical coherence tomography B-scans of the macula acquired at different time points: At initial presentation (**D**), 1 month after the last of 6 intravitreal bevacizumab injections administered over 7 months (**E**), and 1 month (**F**) and 12 months (**G**) after the first intravitreal aflibercept injection. The patient received 5 intravitreal aflibercept injections over the 12-month follow-up. On each optical coherence tomography image, intraretinal cystoid cavities were outlined by a red line using a semiautomated algorithm.



**Fig. 2.** Clinical effect of aflibercept intravitreal therapy over 12 months in 8 patients with MacTel 1. Optical coherence tomography thickness maps and horizontal B-scans through the fovea at baseline **A** and 12 months after the initiation of intravitreal aflibercept (**B**). Central macular thickness and the area of cystoid spaces on the horizontal B-scans improved in all patients. The regions identified by a semiautomated algorithm as cystoid spaces were outlined by a red contour.

improved ( $88.0 \pm 11.3$  letters [ $\sim 20/35$ ];  $P = 0.02$ ), which was maintained at the 12-month time point.

*Angiogenic Factor Levels in Aqueous Humor*

The 8 individuals selected for the control group of aqueous humor analysis were male with a mean age of  $68 \pm 12$  years (range, 50–85 years), not significantly different from the 6 subjects with MacTel 1 from whom aqueous humor was sampled (Cases 1–6: mean age,  $61 \pm 11$  years;  $P = 0.40$ ).

The profiles of angiogenic factors in the aqueous humor of patients with MacTel 1, compared with healthy control subjects, are represented in Figure 4. There was no difference in VEGF-A levels ( $\times 1.3$ ;  $P = 0.95$ ) but significantly higher levels of sFlt-1 ( $\times 4.3$ ;  $P = 0.013$ ), PlGF ( $\times 2.2$ ;  $P = 0.029$ ), and Tie-2 ( $\times 3.7$ ;  $P = 0.019$ ) and VEGF-D ( $\times 6.8$ ;  $P = 0.049$ ). VEGF-C and basic fibroblast growth factor levels were higher without reaching statistical significance. Mean aqueous levels of angiogenic factors in affected and control subjects are reported in the Table 3.

*Correlations Between Imaging and Biologic Parameters*

The OCTA scans were analyzed to determine the perifoveal capillary densities in the superficial and deep capillary plexuses. Figure 5 provides an illustration of multimodal imaging in 1 patient (Case 1), with OCTA of the superficial and deep capillary plexuses and the corresponding capillary density maps.

An exhaustive account of the functional and anatomical parameters and aqueous levels of angiogenic factors is given in the **Supplemental Digital Content 2** (see **Table 1**, <http://links.lww.com/IAE/A564>). When exploring possible correlations between these parameters (see **Table 2**, **Supplemental Digital Content 3**, <http://links.lww.com/IAE/A565>), we found a significant inverse correlation between the perifoveal capillary density of both superficial and deep capillary plexuses on OCTA and aqueous levels of PlGF ( $P = 0.03$ ;  $r = -0.89$ ).

Table 2. Functional and Anatomical Outcome of Intravitreal Aflibercept in 8 Patients With MacTel 1

Mean ± SD	Baseline	12 Months	P*
Best-corrected visual acuity, ETDRS letter score (Snellen)	79.6 ± 16.3 (~20/52)	88.0 ± 11.2 (~20/35)	0.042
CMT, μm	434.3 ± 98.0	292.5 ± 58.6	0.014

Baseline values were recorded 1 month after the last administration of the previous intravitreal or laser treatment.

\*Wilcoxon signed rank test.

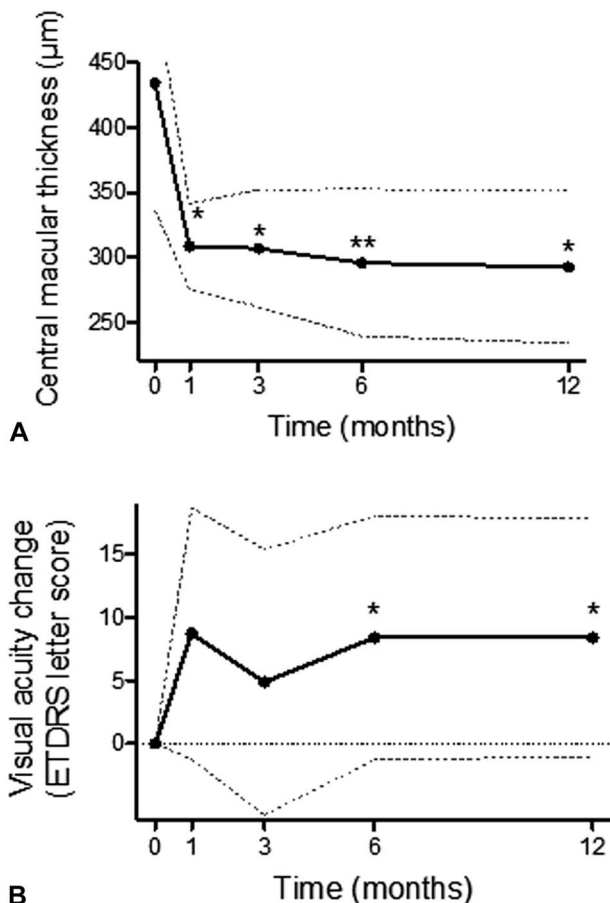
ETDRS, Early Treatment Diabetic Retinopathy Study; SD, standard deviation.

**Discussion**

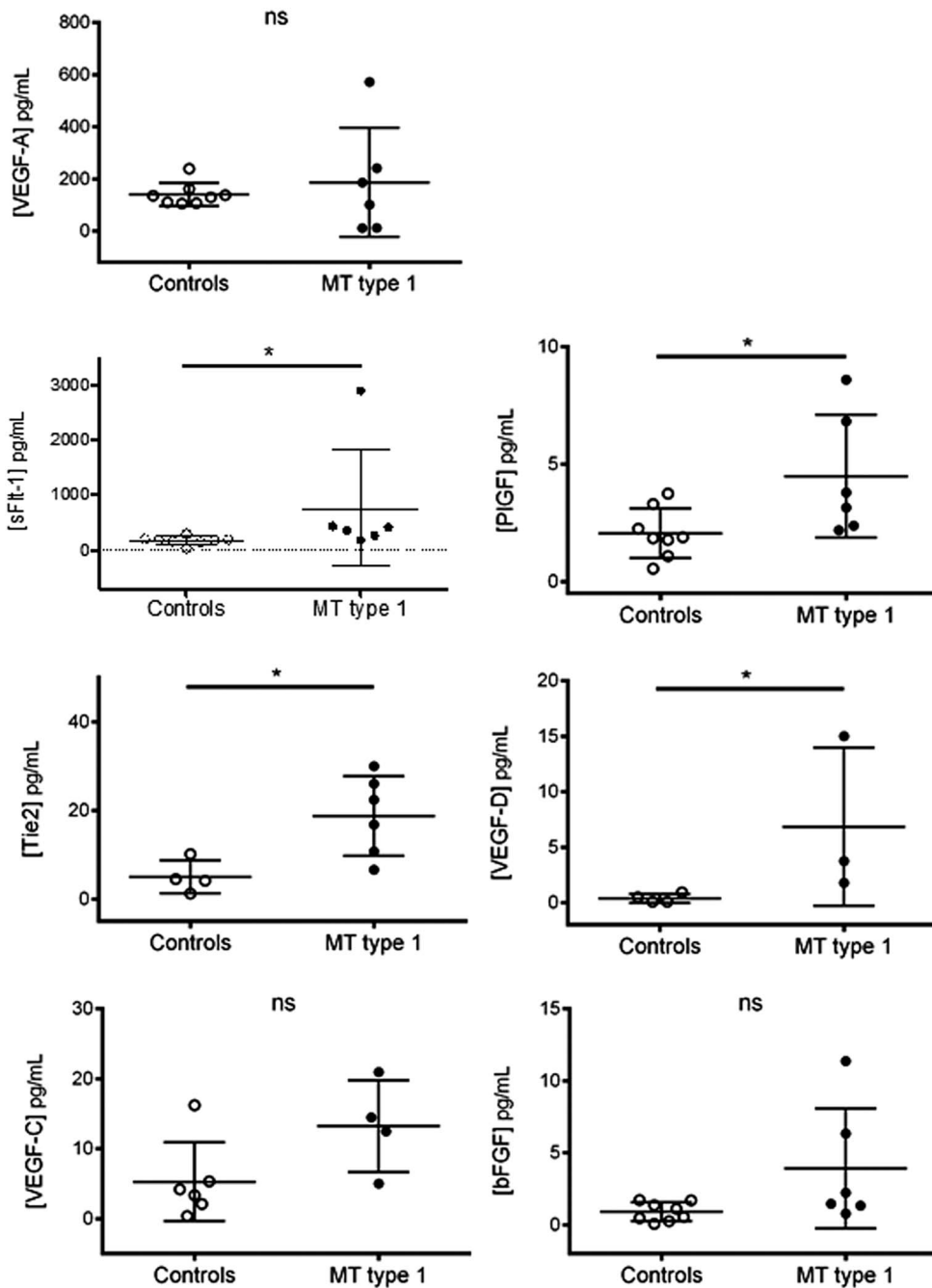
In this case series of 8 patients with MacTel 1, treatment with intravitreal aflibercept, that blocks both VEGF-A and PlGF, showed significant anatomical and functional effects on macular edema. Anatomical improvement was observed after one intravitreal injection of aflibercept in all cases, including those incompletely responsive to other anti-VEGF therapies

that do not inhibit the PlGF-mediated Flt1 pathway. These results are supported by measurements of higher levels of PlGF, but not VEGF-A, in the aqueous humor of patients with MacTel 1 compared with healthy control subjects.

To date, there are 2 case reports on the effects of intravitreal aflibercept in MacTel 1. Shibebe et al<sup>14</sup> described the complete resolution of macular edema and visual improvement after 4 aflibercept injections in 1 case of MacTel 1 refractory to 3 monthly bevacizumab injections and to laser photocoagulation. Recently, Kovach et al<sup>15</sup> reported the beneficial effect over 3 years of aflibercept therapy on macular edema secondary to MacTel 1 in 1 patient previously nonresponding to 6 monthly bevacizumab, 7 monthly ranibizumab, and 3 triamcinolone acetonide injections. Before aflibercept became available for retina indication, several investigators had evaluated intravitreal injections of bevacizumab and ranibizumab in Type 1 and Type 2 idiopathic macular telangiectasia, with limited outcomes. Noticeably, the exact role of VEGF in the development of primary telangiectasia is not clear, and intraocular VEGF levels in Type 1 or Type 2 idiopathic macular telangiectasia had not been reported before the present study. Two case reports have suggested a favorable effect of intravitreal bevacizumab on MacTel 1,<sup>6,7</sup> but these observations were not confirmed by 3 small case series. Matsumoto and Yuzawa<sup>10</sup> reported 4 patients with MacTel 1 who received 3 to 4 intravitreal bevacizumab injections over a 6-month period. The microaneurysms regressed in one of the four eyes, but visual acuity did not improve in any of the patients. Takayama et al<sup>11</sup> reported 5 cases with MacTel 1, treated with 2 to 3 intravitreal bevacizumab over 1 year, among which only 1 eye showed a reduction in macular edema and an improvement in visual acuity. Finally, Moon et al<sup>12</sup> also reported 7 patients with MacTel 1 treated with intravitreal bevacizumab during 4 months. Although a significant decrease in CMT was observed on SD-OCT, there was no significant improvement in visual acuity. In idiopathic macular telangiectasia Type 2 (or MacTel), several studies have demonstrated that anti-VEGF



**Fig. 3.** Anatomical and visual effect of intravitreal aflibercept therapy in 8 patients with MacTel 1, over 12 months. **A.** Mean CMT. **B.** Best-corrected visual acuity change (Early Treatment Diabetic Retinopathy Study letter score). All parameters were assessed at baseline, 1 month, 3, 6, and 12 months. The inferior and superior dotted lines indicate the standard deviation. Mean values were compared with baseline using a Wilcoxon paired test (\**P* < 0.05; \*\**P* < 0.01).



**Fig. 4.** Angiogenic factors profile in the aqueous humor determined by a multiarray high-sensitive immunoassay. VEGF-A, sFlt-1, PIGF, Tie-2, VEGF-D, VEGF-C, and basic fibroblast growth factor (bFGF) levels of male patients with MacTel 1 (n = 6, black dots) were compared with those of healthy age-matched male control subjects undergoing cataract extraction (n = 8, white dots). The levels of Tie-2, VEGF-C, and VEGF-D were below the detection threshold in some aqueous humor samples, explaining the lower number of represented values. Concentrations were compared between affected and control subjects using a Mann-Whitney *U* test. \**P* < 0.05; ns, not significant.

therapy by bevacizumab or ranibizumab did not improve the visual acuity on the long term, although it reduced leakage from telangiectasia in the nonproliferative form of the disease.<sup>29-33</sup>

In Coats disease, which belongs to the same spectrum of microvascular disorders as MacTel 1,<sup>5</sup> anti-VEGF agents have become an effective adjunct therapy in the management of retinal exudation.<sup>34-36</sup> Their clinical efficacy is supported by elevated VEGF levels in the subretinal fluid<sup>37</sup> and aqueous humor<sup>38</sup> of

eyes with Coats disease, as compared with control eyes from age-matched patients with rhegmatogenous retinal detachment or congenital cataract, respectively. Moreover, immune localization of VEGF and VEGF receptors were performed on enucleated eyes with advanced Coats disease<sup>39</sup> and showed that VEGF-A was expressed in vascular endothelial cells and macrophages and that VEGF-R2 (mediating angiogenesis after VEGF-A stimulation) was localized in endothelial cells lining abnormal vessels, but not



Table 3. Angiogenic Factors Levels in Aqueous Humors of Healthy Control Subjects and Patients With MacTel 1, Determined on a Multiarray Immunoassay

Concentrations, Mean ± SD	Control Subjects, pg/mL	MacTel 1, pg/mL	Fold Change, MacTel 1 vs. Control Subjects	P*
sFlt1	173.9 ± 71.17	755.9 ± 1050	×4.3	0.013
PlGF	2.1 ± 1.06	4.5 ± 2.62	×2.2	0.029
Tie-2	5.0 ± 3.73	18.7 ± 9.02	×3.7	0.019
VEGF-A	140.9 ± 44.01	187.3 ± 209.7	×1.3	0.950
VEGF-C	5.3 ± 5.63	13.2 ± 6.55	×2.4	0.110
VEGF-D	0.4 ± 0.40	6.8 ± 7.14	×17.4	0.049
bFGF	0.9 ± 0.65	3.9 ± 4.16	×4.3	0.060

\*Mann–Whitney test.

bFGF, basic fibroblast growth factor; ETDRS, Early Treatment Diabetic Retinopathy Study; SD, standard deviation; Tie-2, tyrosine kinase with immunoglobulin-2 and EGF-like domains.

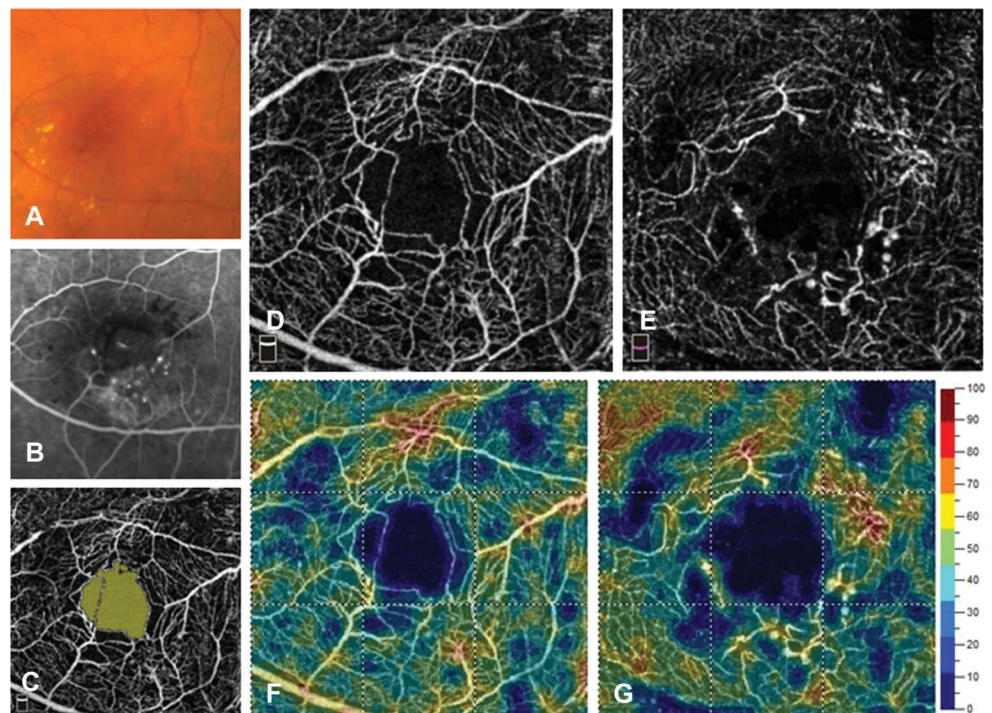
VEGF-R1/Flt1 (mediating vascular permeabilization and cell migration and possibly modulating VEGF-R2 activation<sup>16</sup>) or VEGF-R3 (signaling lymphangiogenesis). In contrast to MacTel 1, these data indicate that the VEGF-A–mediated VEGF-R2 pathway is specifically activated in Coats disease, supporting the better response to bevacizumab or ranibizumab in Coats disease than in MacTel 1. Similarly, PlGF was not detected in 18 aqueous humors from patients with wet age-related macular degeneration,<sup>40</sup> supporting the efficacy of bevacizumab in wet age-related macular degeneration.

In contrast, the higher efficacy of aflibercept over specific anti-VEGF antibodies in patients with MacTel 1, previously reported<sup>14,15</sup> and observed in our case

series, suggest that the PlGF-mediated VEGF-R1/Flt1-pathway is involved in the pathophysiology of MacTel 1, leading to vascular abnormalities, such as telangiectasias, microaneurysms, and vascular tortuosity. This assumption is supported by the increased aqueous humor levels of PlGF in MacTel 1 eyes as compared with age-matched healthy control eyes.

In the healthy retina, the level of PlGF expression in endothelial cells is 100-fold higher than the expression of VEGF,<sup>41</sup> and VEGF-R1/Flt-1 is the major VEGF receptor expressed in endothelial cells and in pericytes.<sup>42</sup> In our previous experimental study, long-lasting overexpression of rat PlGF in the rat eye induced vascular tortuosity and aneurysmal dilation of retinal capillaries, without neovascularization.<sup>24</sup>

**Fig. 5.** Multimodal imaging in a 71-year-old male patient with MacTel 1 affecting his left eye (Case 1). **A.** Color fundus photograph showing telangiectasic microaneurysms and hard exudates. **B.** Early-frame fluorescein angiogram (1 minute after dye injection) and **(C)** identification of the foveal avascular zone area on a 3 × 3-mm OCTA image. 3 × 3-mm OCTA images of the superficial **(D)** and deep **(E)** capillary plexus used to assess the corresponding capillary densities **(F and G)**. The deep plexus shows pronounced capillary telangiectasis and microaneurysm formation in the inferotemporal macula.



Similarly, overactivation of the PIGF-VEGFR-1/Flt-1 pathway induced a substantial increase in the branching, tortuosity, and leakiness of vessels in different organs of rodent models, including skin,<sup>43</sup> and branches of the aorta.<sup>44</sup> Moreover, in MacTel 1 patients, macular edema results from vascular abnormalization and leakage without true neovascularization,<sup>3</sup> which is consistent with the nonelevated VEGF-A levels measured in their aqueous humor. Along with the telangiectasia, variably extended focal area of decreased perfusion is a classical finding in MacTel 1.<sup>2,3</sup> This observation was recently confirmed using OCTA.<sup>45</sup> Under these minimally ischemic conditions, PIGF could be a major player in the development of abnormal vessels, as shown here by the positive correlation between aqueous PIGF levels and the extension of capillary loss in the superficial and deep capillary plexus on OCTA. In addition, higher levels of the sFlt-1, which binds with a high affinity to both PIGF and VEGF-A,<sup>46</sup> were measured in MacTel 1 eyes, as compared with control eyes, indicating a possible counterregulatory increase in sFlt-1 in response to high PIGF levels. Levels of the soluble form of the angiopoietin receptor Tie-2 were also higher in MacTel 1 eyes. Interestingly, the Flt-1/VEGF signaling,<sup>47</sup> and the Ang-Tie2 signaling are involved in the loss of pericytes,<sup>48</sup> which could contribute to microaneurysm formation.<sup>42</sup>

The role of VEGF-A has also been questioned in other aneurysmal disorders affecting smaller or larger vessels. For instance, in abdominal aortic aneurysm, no significant difference in VEGF-A expression was demonstrated between the aortic wall of pathologic specimens and normal aortas from organ donors, but the expression of VEGF-C and VEGF-D was significantly increased in the abluminal layer of the aorta.<sup>49</sup> Moreover, the difference in angiogenic factor levels could affect the response to treatments, as in colorectal cancer where high circulating levels of VEGF-D are suspected to reduce the efficacy of bevacizumab therapy.<sup>50</sup> Remarkably, VEGF-D levels, but not VEGF-A levels, were significantly increased in the aqueous humor of MacTel 1 patients, suggesting that it may also contribute to abnormal retinal vessel dilation and to resistance to intravitreal bevacizumab.

A similar approach has been recently proposed by Noma et al,<sup>51,52</sup> who investigated the aqueous profile of angiogenic factors in retinal vein occlusions and found increased levels of VEGF-A, PIGF, and sFlt-1 compared with control eyes. Noticeably, microvascular remodeling causing secondary telangiectasia occur in retinal vein occlusions that may be PIGF mediated. In contrast to MacTel 1, macular

edema caused by vein occlusions respond favorably to bevacizumab,<sup>53,54</sup> ranibizumab,<sup>55,56</sup> or aflibercept<sup>57</sup> therapy, which may be linked to the relative elevation of both VEGF-A and PIGF in the ocular media of these patients.

The present study has several limitations, including the small sample size, because of the low prevalence of MacTel 1. The only way to increase the statistical power and significance would be to get more samples from MacTel 1 patients, which requires an inordinate amount of time and would hinder reporting of a worthwhile treatment. In addition, the follow-up duration was limited to 12 months, as a result of the recent availability of aflibercept, and we did not report the follow-up on OCTA for possible microvascular changes with aflibercept therapy, also the result of the recent availability of this imaging technology. Also, other angiogenic or inflammatory factors could have been assessed with the multiarray immunoassay experiment, but we focused on the major angiogenic factors and receptors of the VEGF family presumed to be involved in retinal vascular diseases.

In conclusion, we found that MacTel 1 patients with macular edema have higher aqueous humor levels of PIGF, but not VEGF-A, as compared with sex-matched and age-matched control subjects. Aflibercept, a neutralizer of both VEGF-A and PIGF, exerts beneficial anatomical and functional effects in these patients who did not show a good response to therapy other than aflibercept. To elucidate this effect and the observed angiogenic profile, a hypothesis suggesting PIGF-VEGFR-1/Flt-1 pathway activation in MacTel 1 was generated, which best explained the data. These results should be confirmed by larger prospective studies.

**Key words:** aflibercept, macular telangiectasia, retina.

### Acknowledgments

The authors thank Christina Stathopoulos and Cédric Mayer from Jules-Gonin Eye Hospital for clinical assistance and Catherine Fouda from the Department of Human Protein Science, University of Geneva for technical assistance in the multiarray immune assays.

### References

1. Gass JD, Oyakawa RT. Idiopathic juxtafoveolar retinal telangiectasis. *Arch Ophthalmol* 1982;100:769-780.
2. Gass JD, Blodi BA. Idiopathic juxtafoveolar retinal telangiectasis. Update of classification and follow-up study. *Ophthalmology* 1993;100:1536-1546.

3. Yannuzzi LA, Bardal AM, Freund KB, et al. Idiopathic macular telangiectasia. *Arch Ophthalmol* 2006;124:450–460.
4. Smithen LM, Brown GC, Brucker AJ, et al. Coats' disease diagnosed in adulthood. *Ophthalmology* 2005;112:1072–1078.
5. Cahill M, O'Keefe M, Acheson R, et al. Classification of the spectrum of Coats' disease as subtypes of idiopathic retinal telangiectasis with exudation. *Acta Ophthalmol Scand* 2001;79:596–602.
6. Gamulescu MA, Walter A, Sachs H, Helbig H. Bevacizumab in the treatment of idiopathic macular telangiectasia. *Graefes Arch Clin Exp Ophthalmol* 2008;246:1189–1193.
7. Koay CL, Chew FLM, Visvaraja S. Bevacizumab and type 1 idiopathic macular telangiectasia. *Eye (Lond)* 2011;25:1663–1665. author reply 1665.
8. Ciarnella A, Verrilli S, Fenicia V, et al. Intravitreal ranibizumab and laser photocoagulation in the management of idiopathic juxtafoveolar retinal telangiectasia type 1: a case report. *Case Rep Ophthalmol* 2012;3:298–303.
9. Rouvas A, Malamos P, Douvali M, et al. Twelve months of follow-up after intravitreal injection of ranibizumab for the treatment of idiopathic parafoveal telangiectasia. *Clin Ophthalmol* 2013;7:1357–1362.
10. Matsumoto Y, Yuzawa M. Intravitreal bevacizumab therapy for idiopathic macular telangiectasia. *Jpn J Ophthalmol* 2010;54:320–324.
11. Takayama K, Ooto S, Tamura H, et al. Intravitreal bevacizumab for type 1 idiopathic macular telangiectasia. *Eye (Lond)* 2010;24:1492–1497.
12. Moon BG, Kim YJ, Yoon YH, Lee JY. Use of intravitreal bevacizumab injections to treat type 1 idiopathic macular telangiectasia. *Graefes Arch Clin Exp Ophthalmol* 2012;250:1697–1699.
13. Loutfi M, Papathomas T, Kamal A. Macular oedema related to idiopathic macular telangiectasia type 1 treated with dexamethasone intravitreal implant (ozurdex). *Case Rep Ophthalmol Med* 2014;2014:231913.
14. Shibebe O, Vaze A, Gillies M, Gray T. Macular oedema in idiopathic macular telangiectasia type 1 responsive to aflibercept but not bevacizumab. *Case Rep Ophthalmol Med* 2014;2014:219792. 1.
15. Kovach JL, Hess H, Rosenfeld PJ. Macular telangiectasia type 1 managed with long-term aflibercept therapy. *Ophthalmic Surg Lasers Imaging Retina* 2016;47:593–595.
16. Autiero M, Waltenberger J, Communi D, et al. Role of PIGF in the intra- and intermolecular cross talk between the VEGF receptors Flt1 and Flk1. *Nat Med* 2003;9:936–943.
17. Fischer C, Jonckx B, Mazzone M, et al. Anti-PIGF inhibits growth of VEGF(R)-inhibitor-resistant tumors without affecting healthy vessels. *Cell* 2007;131:463–475.
18. Fan F, Samuel S, Gaur P, et al. Chronic exposure of colorectal cancer cells to bevacizumab promotes compensatory pathways that mediate tumour cell migration. *Br J Cancer* 2011;104:1270–1277.
19. Miyamoto N, de Kozak Y, Jeanny JC, et al. Placental growth factor-1 and epithelial haemato-retinal barrier breakdown: potential implication in the pathogenesis of diabetic retinopathy. *Diabetologia* 2007;50:461–470.
20. Rahimy E, Shahlaee A, Khan MA, et al. Conversion to aflibercept after prior anti-VEGF therapy for persistent diabetic macular edema. *Am J Ophthalmol* 2016;164:118–127.e2.
21. Papadopoulos N, Martin J, Ruan Q, et al. Binding and neutralization of vascular endothelial growth factor (VEGF) and related ligands by VEGF Trap, ranibizumab and bevacizumab. *Angiogenesis* 2012;15:171–185.
22. Fischer C, Mazzone M, Jonckx B, Carmeliet P. FLT1 and its ligands VEGFB and PIGF: drug targets for anti-angiogenic therapy? *Nat Rev Cancer* 2008;8:942–956.
23. Okamoto N, Tobe T, Hackett SF, et al. Transgenic mice with increased expression of vascular endothelial growth factor in the retina: a new model of intraretinal and subretinal neovascularization. *Am J Pathol* 1997;151:281–291.
24. Kowalczyk L, Touchard E, Omri S, et al. Placental growth factor contributes to micro-vascular abnormalization and blood-retinal barrier breakdown in diabetic retinopathy. *PLoS One* 2011;6:e17462.
25. Krohne TU, Liu Z, Holz FG, Meyer CH. Intraocular pharmacokinetics of ranibizumab following a single intravitreal injection in humans. *Am J Ophthalmol* 2012;154:682–686.
26. Moisseiev E, Waisbourd M, Ben-Artzi E, et al. Pharmacokinetics of bevacizumab after topical and intravitreal administration in human eyes. *Graefes Arch Clin Exp Ophthalmol* 2014;252:331–337.
27. Christoforidis JB, Williams MM, Kothandaraman S, et al. Pharmacokinetic properties of intravitreal I-124-aflibercept in a rabbit model using PET/CT. *Curr Eye Res* 2012;37:1171–1174.
28. Stewart MW, Rosenfeld PJ, Penha FM, et al. Pharmacokinetic rationale for dosing every 2 weeks versus 4 weeks with intravitreal ranibizumab, bevacizumab, and aflibercept (vascular endothelial growth factor Trap-eye). *Retina* 2012;32:434–457.
29. Charbel Issa P, Scholl HP, Holz FG. Short-term effects of intravitreal bevacizumab in type II idiopathic macular telangiectasia. *Retin Cases Brief Rep* 2007;1:189–191.
30. Charbel Issa P, Finger RP, Kruse K, et al. Monthly ranibizumab for nonproliferative macular telangiectasia type 2: a 12-month prospective study. *Am J Ophthalmol* 2011;151:876–886.
31. Do DV, Bressler SB, Cassard SD, et al. Ranibizumab for macular telangiectasia type 2 in the absence of subretinal neovascularization. *Retina* 2014;34:2063–2071.
32. Kupitz EH, Heeren TFC, Holz FG, Charbel Issa P. Poor long-term outcome of anti-vascular endothelial growth factor therapy in nonproliferative macular telangiectasia type 2. *Retina* 2015;35:2619–2626.
33. Roller AB, Folk JC, Patel NM, et al. Intravitreal bevacizumab for treatment of proliferative and nonproliferative type 2 idiopathic macular telangiectasia. *Retina* 2011;31:1848–1855.
34. Sigler EJ, Randolph JC, Calzada JJ, et al. Current management of Coats disease. *Surv Ophthalmol* 2014;59:30–46.
35. Gaillard MC, Mataftsi A, Balmer A, et al. Ranibizumab in the management of advanced Coats disease stages 3B and 4: long-term outcomes. *Retina* 2014;34:2275–2281.
36. Daruich A, Matet A, Tran HV, et al. Extramacular fibrosis in Coats' disease. *Retina* 2016;36:2022–2028.
37. Zhang H, Liu ZL. Increased nitric oxide and vascular endothelial growth factor levels in the aqueous humor of patients with Coats' disease. *Ocul Pharmacol Ther* 2012;28:397–401.
38. He YG, Wang H, Zhao B, et al. Elevated vascular endothelial growth factor level in Coats' disease and possible therapeutic role of bevacizumab. *Graefes Arch Clin Exp Ophthalmol* 2010;248:1519–1522.
39. Kase S, Rao NA, Yoshikawa H, et al. Expression of vascular endothelial growth factor in eyes with Coats' disease. *Invest Ophthalmol Vis Sci* 2013;54:57–62.
40. Muether PS, Neuhann I, Buhl C, et al. Intraocular growth factors and cytokines in patients with dry and neovascular age-related macular degeneration. *Retina* 2013;33:1809–1814.

41. Yonekura H, Sakurai S, Liu X, et al. Placenta growth factor and vascular endothelial growth factor B and C expression in microvascular endothelial cells and pericytes. Implication in autocrine and paracrine regulation of angiogenesis. *J Biol Chem* 1999;274:35172–35178.
42. Witmer AN, Vrensen GF, Van Noorden CJ, Schlingemann RO. Vascular endothelial growth factors and angiogenesis in eye disease. *Prog Retin Eye Res* 2003;22:1–29. Review.
43. Odorisio T, Schietroma C, Zaccaria ML, et al. Mice over-expressing placenta growth factor exhibit increased vascularization and vessel permeability. *J Cell Sci* 2002;115:2559–2567.
44. Kearney JB, Kappas NC, Ellerstrom C, et al. The VEGF receptor flt-1 (VEGFR-1) is a positive modulator of vascular sprout formation and branching morphogenesis. *Blood* 2004;103:4527–4535.
45. Matet A, Daruich A, Dirani A, et al. Macular telangiectasia type 1: capillary density and microvascular abnormalities assessed by optical coherence tomography angiography. *Am J Ophthalmol* 2016;167:18–30.
46. Shibuya M. Vascular endothelial growth factor receptor-1 (VEGFR-1/Flt-1): a dual regulator for angiogenesis. *Angiogenesis* 2006;9:225–230. discussion 231.
47. Cao R, Xue Y, Hedlund EM, et al. VEGFR1-mediated pericyte ablation links VEGF and PLGF to cancer-associated retinopathy. *Proc Natl Acad Sci U S A* 2010;107:856–861.
48. Cai J, Ruan Q, Chen ZJ, Han S. Connection of pericyte-angiopoietin-Tie-2 system in diabetic retinopathy: friend or foe? *Future Med Chem* 2012;4:2163–2176.
49. Wolanska M, Bankowska-Guszczyn E, Sobolewski K, Kowalewski R. Expression of VEGFs and its receptors in abdominal aortic aneurysm. *Int Angiol* 2015;34:520–528.
50. Weickhardt AJ, Williams DS, Lee CK, et al. Vascular endothelial growth factor D expression is a potential biomarker of bevacizumab benefit in colorectal cancer. *Br J Cancer* 2015;113:37–45.
51. Noma H, Mimura T, Yasuda K, Shimura M. Role of soluble vascular endothelial growth factor receptors-1 and -2, their ligands, and other factors in branch retinal vein occlusion with macular edema. *Invest Ophthalmol Vis Sci* 2014;55:3878–3885.
52. Noma H, Mimura T, Yasuda K, Shimura M. Role of soluble vascular endothelial growth factor receptor signaling and other factors or cytokines in central retinal vein occlusion with macular edema. *Invest Ophthalmol Vis Sci* 2015;56:1122–1128.
53. Ferrara DC, Koizumi H, Spaide RF. Early bevacizumab treatment of central retinal vein occlusion. *Am J Ophthalmol* 2007;144:864–871.
54. Priglinger SG, Wolf AH, Kreutzer TC, et al. Intravitreal bevacizumab injections for treatment of central retinal vein occlusion: six-month results of a prospective trial. *Retina* 2007;27:1004–1012.
55. Brown DM, Campochiaro PA, Singh RP, et al. Ranibizumab for macular edema following central retinal vein occlusion: six-month primary end point results of a phase III study. *Ophthalmology* 2010;117:1124–1133.e1.
56. Kinge B, Stordahl PB, Forsaa V, et al. Efficacy of ranibizumab in patients with macular edema secondary to central retinal vein occlusion: results from the sham-controlled ROCC study. *Am J Ophthalmol* 2010;150:310–314.
57. Heier JS, Clark WL, Boyer DS, et al. Intravitreal aflibercept injection for macular edema due to central retinal vein occlusion: two-year results from the COPERNICUS study. *Ophthalmology* 2014;121:1414–1420.e1.