



A pigmented vitreous cyst floating in front of the macula: Case images and videos

Xuebi Cai^{a,b,*}, Kai-Jing Zhou^c, Jun-Liang Wang^a, Heding Zhou^{a,**}

^a Ningbo Eye Hospital, Wenzhou Medical University, Ningbo, Zhejiang, 315040, China

^b Biomedicine Discovery Institute, Department of Anatomy and Developmental Biology, Monash University, Clayton, VIC, 3800, Australia

^c School of Ophthalmology and Optometry and Eye Hospital, Wenzhou Medical University, Wenzhou, Zhejiang, 325027, China

1. Case report

A 40-year-old woman presented with a 1-month history of seeing a “floating ball” in her right eye which kept blocking her eyesight when she blinked. No systematic disease or recent infective history was found. On examination, both eyes had a best corrected visual acuity (BCVA) of 20/20, quiet anterior chambers, normal cornea and lens, and normal intraocular pressures. On slit-lamp funduscopy of the right eye, a spherical, light brown-pigmented mass was seen floating in the vitreous in front of the macula (Fig. 1A; Video 1). The presence of a pigmented mass right before the macula, very likely blocking the eyesight, was confirmed by fundus photography. A B-scan ultrasound examination was performed, showing a cystic mass with hyperechoic thin walls in the right eye. The retinal structures were found to be morphologically normal through optical coherence tomography (OCT). Routine health check including physical examination, laboratory testing, thorax X-ray and head tomography showed the patient had no systematic abnormalities. Finally, a diagnosis of pigmented vitreous cyst was made.

Supplementary video related to this article can be found at <https://doi.org/10.1016/j.ajoc.2024.102114>

Given the floating pigmented vitreous cyst frequently blocked the eyesight in the right eye which is her dominant eye, the patient had a strong willing to remove it. The patient was given treatment options of either laser photodisruption or vitrectomy, and she opted for vitrectomy. The cyst was incised and aspirated by a vitreous cutter, and the intact cyst wall was then taken out by intraocular microforceps (Video 2). After surgery, the histopathological material was sliced and hematoxylin and eosin (HE) stained, showing the collapsed cyst wall majorly consisted of pigmented epithelial cells (Fig. 1B). There was neither parasitic structure (specifically cysticercus) nor neoplastic or inflammatory cells in the examined microscopic slides. At follow-up 14 months after surgery, the

patient has no complaints of visual disturbance or any complications.

Supplementary video related to this article can be found at <https://doi.org/10.1016/j.ajoc.2024.102114>

2. Discussion

Vitreous cysts are uncommon ocular findings and generally found via routine ophthalmic examination of the anterior segment or, rarely, of the posterior segment.¹ High-resolution images have been recently reported directly visualizing free-floating cyst in the anterior vitreous, but not in the posterior vitreous.² Here we show intriguing images and video acquired by slit-lamp funduscopy connected to a high-resolution video device, first visualizing the typical appearance of a pigmented vitreous cyst near the macula. Surgical aspiration of the cyst can relieve the symptom and reduce the risk of late complications such as epiretinal membrane formation secondary to dispersed pigmented cells.¹

3. Conclusion

Vitreous cysts can be congenital or acquired with unknown mechanisms. When the cyst becomes symptomatic, then cyst excision with laser cystotomy or pars plana vitrectomy is recommended.

Patient consent

Verbal informed consent was obtained from the patient.

Funding

The author(s) received no financial support for the research, authorship, and/or publication of this article.

* Corresponding author. Ningbo Eye Hospital, Wenzhou Medical University, Ningbo, Zhejiang, 315040, China.

** Corresponding author.

E-mail addresses: xuebi.cai@monash.edu (X. Cai), zjnbzhd@126.com (H. Zhou).

<https://doi.org/10.1016/j.ajoc.2024.102114>

Received 18 April 2024; Received in revised form 12 June 2024; Accepted 29 June 2024

Available online 18 July 2024

2451-9936/© 2024 The Authors. Published by Elsevier Inc. This is an open access article under the CC BY-NC-ND license (<http://creativecommons.org/licenses/by-nc-nd/4.0/>).

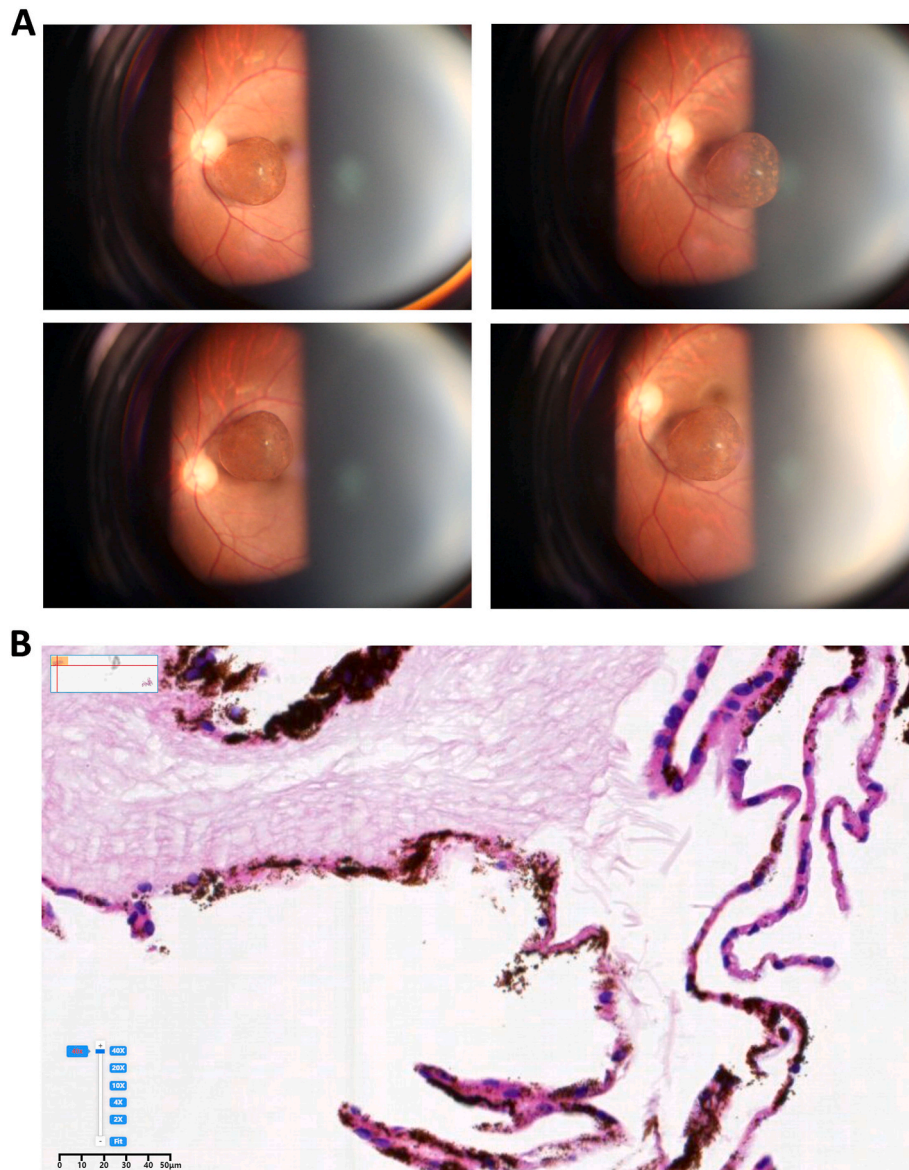


Fig. 1. Typical appearance of a pigmented vitreous cyst in front of the macula and analysis of its histopathological characteristics. (A) Images showing a pigmented vitreous cyst floating to the nasal side of the macula (*up, left*), to the temporal side of the macula (*up, right*), down the macula (*bottom, left*), and up the macula (*bottom, right*). (B) Histopathological analysis revealing the collapsed cyst wall comprised of pigmented epithelial cells.

Authorship

All authors attest that they meet the current ICMJE criteria for Authorship.

CRediT authorship contribution statement

Xuebi Cai: Writing – review & editing, Writing – original draft, Formal analysis, Data curation, Conceptualization. **Kai-Jing Zhou:** Data curation. **Jun-Liang Wang:** Project administration. **Heding Zhou:** Supervision.

Declaration of competing interest

The authors declare that they have no known competing financial interests or personal relationships that could have appeared to influence the work reported in this paper.

Acknowledgements

None.

Appendix A. Supplementary data

Supplementary data related to this article can be found at <https://doi.org/10.1016/j.ajoc.2024.102114>.

References

1. Al-Kahtani E, Alkatan HM. Surgical treatment and histopathology of a symptomatic free-floating primary pigment epithelial iris cyst in the anterior vitreous. *Middle East Afr J Ophthalmol.* 2011;18:331–332.
2. Sun CB. Free-floating cyst in the vitreous. *N Engl J Med.* 2022;386:e1.