



# Posterolateral corner knee injuries: a narrative review

Francisco Figueroa<sup>1,2</sup>

David Figueroa<sup>1</sup>

Sven Putnis<sup>3</sup>

Rodrigo Guiloff<sup>1,2</sup>

Patricio Caro<sup>1</sup>

João Espregueira-Mendes<sup>4–8</sup>

- Limited knowledge of the anatomy and biomechanics of the posterolateral corner (PLC) of the knee, coupled with poor patient outcomes with non-operative management, resulted in the PLC often being labelled as the ‘dark side’ of the knee. In the last two decades, extensive research has resulted in a better understanding of the anatomy and function of the PLC, and has led to the development of anatomic reconstructions that have resulted in improved patient outcomes.
- Despite considerable attention in the clinical orthopaedic literature (nearly 400 articles published in the last decade), a standardized algorithm for the diagnosis and treatment of the PLC is still lacking, and much controversy remains.
- Considering the literature review, there is not a reconstruction technique that clearly prevails over the others. As anatomic, biomechanical, and clinical knowledge of PLC injuries continues to progress, finding the balance between re-creating native anatomy and safely performing PLC reconstruction provides a big challenge. Treatment decisions should be made on a case-by-case basis.

**Keywords:** knee; multiligament; PLC; posterolateral

Cite this article: *EFORT Open Rev* 2021;6:676-685.

DOI: 10.1302/2058-5241.6.200096

## Introduction

Injuries to the posterolateral corner (PLC) of the knee have long been recognized as a component of knee instability, but the incidence was initially presumed to be infrequent. An early large single-centre study of 735 knee ligament injuries from DeLee et al<sup>1</sup> reported 12 cases of isolated posterolateral instability (1.6%), 22 cases combined with anterolateral instability (3%), and a further 10 cases with straight lateral instability (1.4%). The current reported incidence of isolated injuries remains at less than 2% of

patients presenting with a ligamentous knee injury.<sup>1–3</sup> However, of patients presenting with significant ligamentous knee injuries, trauma centres have now reported incidences of PLC injury ranging from 16% to 28%.<sup>2,3</sup>

Hughston et al first reported the clinical significance of a PLC injury in 1976; however, at that time the combination of injuries to different anatomical structures was yet to be explored.<sup>4</sup> Limited knowledge of the anatomy and biomechanics, coupled with poor patient outcomes with non-operative management, resulted in the PLC often being labelled as the ‘dark side’ of the knee.<sup>5</sup> In the last two decades, extensive research<sup>6–9</sup> has resulted in a better understanding of the anatomy and function of the PLC and led to the development of anatomic reconstructions that have improved patient outcomes.

## Anatomy and biomechanics

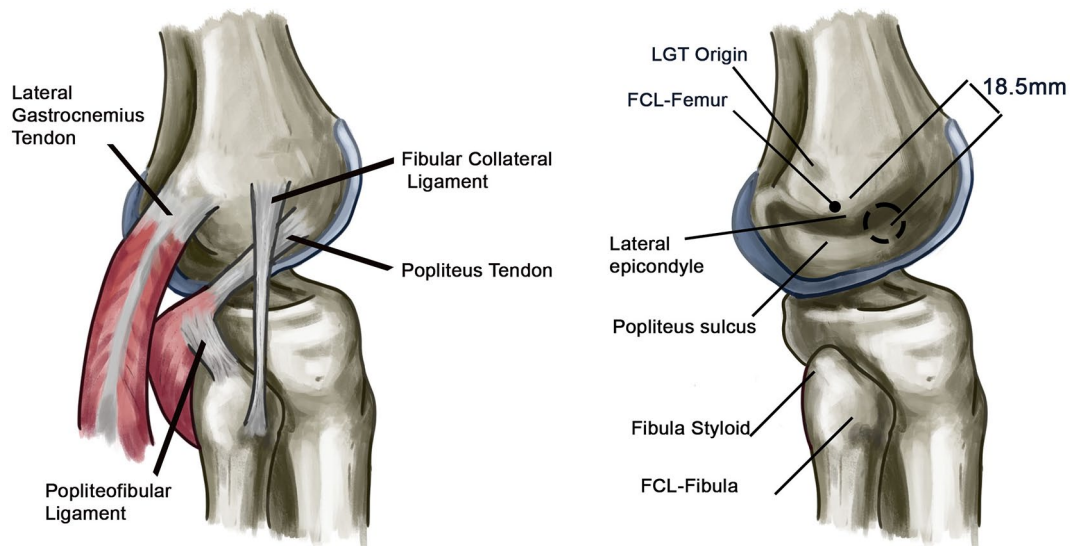
Three primary static stabilizing structures form the PLC: the fibular (or lateral) collateral ligament, the popliteus tendon, and the popliteofibular ligament (Fig. 1).

### *Fibular (or lateral) collateral ligament (FCL)*

The FCL is the most lateral structure of the PLC, with the centre of the origin of the ligament 1.4 mm proximal and 3.1 mm posterior to the lateral femoral epicondyle. The insertion is at the most lateral aspect of the fibula head, 8.2 mm posterior to the anterior margin and 28.4 mm distal to the apex of the fibular styloid process.<sup>6</sup> The FCL acts as the primary varus stabilizer of the knee,<sup>7,10–12</sup> while also providing restraint to tibial external rotation up to 30° of knee flexion,<sup>13</sup> and as a secondary stabilizer to internal rotation.<sup>14</sup>

### *Popliteus tendon (PT)*

The PT has a centre of origin directly anterior to the FCL on the lateral femoral condyle, within the proximal fifth



**Fig. 1** Left: posterolateral corner anatomy depicting the main stabilizing structures – fibular collateral ligament, popliteus tendon, and the popliteofibular ligament. Right: representation of the anatomical footprints of the structures depicted on left.

Note. LGT (lateral gastrocnemius tendon), FCL (fibular collateral ligament).

Source: Reproduced from LaPrade RF, Ly TV, Wentorf FA, Engebretsen L. The posterolateral attachments of the knee: a qualitative and quantitative morphologic analysis of the fibular collateral ligament, popliteus tendon, popliteofibular ligament, and lateral gastrocnemius tendon. *Am J Sports Med* 2003;31:854–860.

of the popliteal sulcus. The tendon courses medial to the FCL and posteromedially to become intra-articular, passing through the popliteal hiatus of the lateral meniscus. It continues its course to the posterior aspect of the tibia reaching its musculotendinous junction and a fan-shaped muscle belly, which has a narrow and broad tendinous insertion at the posteromedial aspect of the proximal tibia.<sup>6</sup> Whilst the popliteus assists in the initial flexion of the knee joint, the PT also has functions similar to a ligament, by functioning as a stabilizer for external rotation in the knee,<sup>14,15</sup> while also providing secondary stabilization to varus stress.<sup>15,16</sup> Another feature of the PT includes minor contributions to anteroposterior tibial translation (specifically in full extension or deficiency of either cruciate ligament).<sup>10,15,17</sup>

#### Popliteofibular ligament (PFL)

The PFL originates from the proximal and lateral aspect of musculotendinous junction of the popliteus and its tendon, composed of an anterior and a larger posterior division.<sup>6</sup> The anterior division attaches distal and laterally on the anterior downslope of the medial aspect of the fibular styloid process, 2.8 mm distal to the tip of the fibular styloid. The posterior division attaches at the apex of the fibular styloid process.<sup>6</sup> The PFL acts as a secondary stabilizer to varus and internal rotation.

Other static structures that form the PLC are thickening of the lateral capsule with meniscomfemoral and meniscotibial ligaments, and variably the fabellofibular ligament

and the arcuate ligament. A PLC injury with an avulsion of the fibula styloid is termed an arcuate fracture. The dynamic stabilizers are the lateral head of the gastrocnemius, the iliotibial band (ITB), and biceps femoris, which can also be injured alongside the PLC. Recently there has been anatomical focus on the importance of the relation between the lateral meniscus and the PLC; however, the clinical relevance of this ligamentous complex is still not well understood.<sup>18</sup> The stability of the proximal tibiofibular joint also plays a role. The incidence of disruption is reported at 9% in multiligament knee injuries, with evidence that subsequent stabilization of this joint plays a role in PLC repair and reconstruction outcomes.<sup>19</sup>

#### Injury mechanism

The mechanism of injury to the PLC usually involves a direct varus stress to the knee, contact or non-contact hyperextension, or twisting of the knee when combined with multiple ligamentous injury, including tibiofemoral dislocation. Of all PLC injuries, 28% occur in isolation, with the rest being typically associated with central pivot tears.<sup>9,20</sup> Vascular injury occurs in 7% to 15% of knee dislocations in contemporary series.<sup>21</sup> The rate of common peroneal nerve palsy in cases of knee dislocation is approximately 25%.<sup>22</sup> Especially in the setting of knee dislocations (type KD III-L), PLC injuries have been associated with concomitant common peroneal nerve injury (OR 42.0) and popliteal artery injury (OR 9.2).<sup>23</sup>

## Physical examination

Physical examination of the ligamentous stability of the knee is paramount, particularly in cases of sub-acute and chronic instability. In the acute phase after injury, swelling and pain can prevent a full physical examination, but examination is likely to detect gross instability.

Alongside a careful examination for anterior cruciate ligament (ACL), PCL and medial collateral ligament (MCL) insufficiency, examination techniques specific to the PLC should be performed whenever possible. Varus stress testing at 0° and 30° is compared to the contralateral side. Increase in varus gapping at 0° is indicative of injury to the PLC and one or more cruciate ligaments. Increase in varus gapping only at 30° is indicative of isolated injury to the FCL. Routinely, aperture opening is classified as grade I for a 0 to 5 mm increase, grade II for 5 to 10 mm, and grade III for greater than 10 mm.<sup>4</sup>

Hughston’s external rotation recurvatum test is performed by stabilizing the distal thigh of a supine patient with one hand and lifting the leg by the great toe with the other. The resulting knee hyperextension is compared to the contralateral side with increasing values representing disruption of the posterior ligamentous structures including the PLC.<sup>24</sup>

The dial test is performed with the patient in a prone position. External rotation of the foot at 30° and 90° of knee flexion is measured by thigh foot angle and is compared to the contralateral side. An increase of 10° to 15° of external rotation at 30° of knee flexion is indicative of an isolated PLC injury and at 90° is indicative of a combined posterior cruciate ligament (PCL) and PLC injury.<sup>25</sup>

In cases of chronic injury, specific attention should be given to the patient’s weight bearing lower limb alignment to look for a collapse into varus, and the patient’s ambulation should be carefully observed for a varus thrust gait. A posterior sag and hyperextension at the peak of stride in the non-weight bearing leg may be seen if the PCL is injured.

## Classification

PLC injuries can be classified according to the damage to the lateral structures or the degree of posterolateral rotatory instability. The two following classifications are the most commonly used (Table 1).

The Hughston classification,<sup>4</sup> is based on the assessment of varus instability or rotational instability under varus stress with the knee in full extension. Grade I represents minimal tearing of the PLC with no abnormal motion (0–5 mm lateral aperture or 0–5° rotation). Grade II injury shows partial tearing with slight or moderate abnormal motion (5–10 mm lateral aperture or 5–10° rotation). Grade III injury refers to complete tearing with marked abnormal movements (> 10 mm lateral aperture or > 10° rotation). Despite its subjectivity and lack of relation to anatomic studies, this classification method is still important in determining treatment choices.

Fanelli and Larson<sup>26</sup> classified PLC injuries into type A, B, and C based on damage to structures of the PLC. Type A injuries involve the PFL and PT. Clinically, only an increase in tibial external rotation is observed. Type B injuries affect the PFL, PT, and FCL. Instability is observed in the varus stress test at 30° of knee flexion along with an increase in tibial external rotation. Type C injuries involve the entire PLC and probable associated injuries (central pivot injuries). Marked varus instability is seen in type C injuries at 30° of knee flexion with an increase in tibial external rotation.

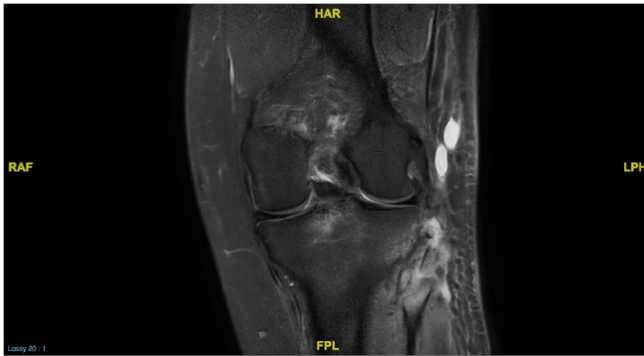## Imaging

Minimum routine plain radiographs are anteroposterior (AP) and lateral views are taken to assess joint congruence and assess for soft tissue swelling and fractures. Lateral joint space widening or anteromedial tibial fractures or fibular head avulsion fractures (arcuate fracture) can be seen on the AP view.<sup>27</sup> A standing long leg AP view must be taken in the case of chronic injuries for assessment of limb malalignment in the coronal and sagittal planes.<sup>28</sup> Plain film radiographs are important to demonstrate that the knee is aligned in the coronal and sagittal planes and magnetic resonance imaging (MRI) is essential to assess for ligamentous and concomitant injuries. Contrarily, in the chronic setting, the use of MRI alone for detection of PLC injury can be unreliable, as the sensitivity of MRI for detection of clinical instability is as low as 48% to 57%.<sup>29,30</sup>

Varus stress and kneeling PCL stress radiographs are useful tools in the diagnosis of PLC injuries. LaPrade et al<sup>31</sup> assessed varus stress radiographs with the knee at 20° of flexion to provide objective measures of lateral compartment gapping. They reported that an increased opening

**Table 1.** Posterolateral corner injury classifications

Hughston	Grade I	Grade II	Grade III
	0–5 mm aperture or 0–5° rotation	5–10 mm aperture or 5–10° rotation	> 10 mm aperture or > 10° rotation
Fanelli	A	B	C
	Increase in tibial external rotation	Increase in tibial external rotation plus mild–moderate instability in varus stress	Increase in tibial external rotation plus severe instability in varus stress



**Fig. 2** Magnetic resonance imaging coronal T2-weighted image showing an arcuate fracture with avulsion of the fibular collateral ligament.

of more than 4 mm might indicate a grade III PLC injury. The kneeling PCL stress radiograph also facilitates objective quantification of isolated or combined (PCL+PLC) injuries.<sup>32</sup>

MRI is essential in both the acute and sub-acute stages (Fig. 2). Reconstructed coronal oblique T2-weighted images are more useful in the evaluation of the PLC structures than the traditional coronal or sagittal view. It has been reported that only 26% of patients with PLC injuries can be diagnosed when an MRI is taken after 12 weeks post injury.<sup>33</sup>

## Treatment

Despite considerable attention in the clinical orthopaedic literature (nearly 400 articles published in the last decade), a standardized algorithm for the diagnosis and treatment of the PLC is still lacking and much controversy remains.<sup>34</sup> This is likely a result of these injuries most often presenting as part of a variety of different complex multiligamentous injuries rather than in isolation, as well as their lower incidence in comparison to single-ligament injuries.<sup>35</sup> In a recent international expert consensus review on the PLC, Chahla et al identified multiple areas reaching an expert consensus such as diagnostic aids, timing of treatment, and the need for anatomical reconstruction of injured structures.<sup>34</sup>

### Non-operative treatment

Few studies exist on the outcome of non-operatively treated isolated PLC knee injuries. Non-operative treatment is usually recommended for patients with grade I or grade II injuries, with follow-up scores showing positive results of return of activity level and radiographic evaluation displaying little to no evidence of posttraumatic osteoarthritis.<sup>36</sup> Krukhaug et al<sup>37</sup> reported that patients with grade I injuries had good outcomes despite persistent instability. Unfortunately, the mentioned studies do not describe specific rehabilitation protocols, only mentioning

early mobilization as an important goal to be achieved. Non-operative management of grade III injuries, however, not only displays persistent lateral instability but also commonly includes multidirectional knee instability.<sup>36</sup> Therefore, surgical management is recommended to restore knee stability in grade III PLC injuries.<sup>38–40</sup>

### Operative treatment

For grade III and grade II PLC injuries accompanied by other structural injuries, surgical management is recommended. The decision to repair or reconstruct the main structures of the PLC in grade III injuries has been debated in the literature. In general, a direct repair of the PLC is often unachievable due to tissue disruption, but focuses primarily on reattachment of the FCL and other important structures to their anatomic locations. Reconstruction aims to use autogenous or allograft tendons placed through bone tunnels at the appropriate anatomic attachment sites. Based on lower reported failure rates with PLC reconstruction, the pendulum has swung in favour of PLC reconstruction in most patient situations.

Stannard and colleagues<sup>41</sup> used a modified two-tailed technique for complete PLC reconstructions relative to repairs and reported failure rates of the repair cohort (37%) significantly higher than the reconstruction cohort (9%). Similar results were reported by Levy and colleagues,<sup>42</sup> when comparing the reconstruction versus repair of PLC tears; they found an overall failure rate of 40% for the repair cohort and 6% for the reconstruction cohort. Both studies included a postoperative rehabilitation protocol that was identical for both the repair and reconstruction groups. An aggressive early motion regimen beginning on postoperative day 1 in all patients was established in Stannard et al's<sup>41</sup> study, while a more conservative approach was set in Levy et al's study.<sup>42</sup>

Conversely, a recent multicentre retrospective review evaluated PLC reconstruction and repair in the setting of combined ACL and PLC injuries. Equivalent functional and patient-reported outcomes were seen in the repair and reconstruction groups.<sup>43</sup> Notably, only combined ACL and PLC injury patterns were assessed in this study, and time to surgery was a median of 19 days in the repair group and 121 days in the reconstruction group. Thus, the results do not apply to repair in the chronic setting and are not comparable to repair of the PLC in higher energy three and four ligament patterns seen in previous repair versus reconstruction studies.

Regarding timing for repair, Shelbourne et al<sup>44</sup> reported that patients treated later than four weeks after injury had worse scores than a group that underwent repairs within four weeks of the injury. In an attempt to elucidate what fixation method should be chosen for repairs, Hodax et al,<sup>45</sup> in a cadaveric biomechanical study, analysed three types of arcuate fragment fixation (suture tunnel, screw

and washer, or suture anchor) revealing robust fixation among all methods, supporting surgeon preference for fixation when a repair is attempted.

In the setting of a chronically injured knee (greater than six months), significant varus malalignment, especially with a dynamic varus gait thrust, is a contraindication to isolated PLC reconstruction. High tibial osteotomy is required before reconstruction is performed for multiligamentous knees with varus alignment. In a study by Arthur et al,<sup>46</sup> biplanar proximal tibial osteotomy was used as the initial treatment for varus malalignment in the setting of multiligament knee injuries; 38% of patients obtained sufficient stability from osteotomy alone and did not require further ligamentous reconstruction. In this study, sagittal slope was decreased in the setting of combined ACL and PLC injury and increased in the setting of combined PCL and PLC injury. Noyes et al<sup>47</sup> reviewed 41 patients with ACL deficiency and classified them as either double or triple varus. All of these patients underwent a lateral closing wedge high tibial osteotomy and ACL reconstruction. A total of 18 patients who were triple varus had a subsequent PLC reconstruction due to residual instability. The indication for an osteotomy in the context of PLC injuries has not had specifically cutoff values described in the literature, and the decision should be made on a case-by-case basis, taking into consideration the severity of malalignment if it is constitutional, changes in previous limb alignment related to the chronicity of the injury, the presence of varus thrust and damage in the tibiofemoral compartments.

*PLC reconstruction techniques*

Reconstruction techniques can be classified into non-anatomical or anatomical. Due to poor results and lack of control of stability, non-anatomical reconstructions have largely been abandoned in favour of anatomical reconstructions. The latter can be classified into fibular-based or tibiofibular-based.

Larson<sup>48</sup> was one of the first proponents of a fibular-based technique (Fig. 3), which reconstructs both the FCL and PFL ligaments. In 2004, LaPrade et al<sup>49</sup> published their biomechanical results based on an anatomic reconstruction of the PLC in 10 human cadaveric specimens. The anatomic locations of the FCL, PT, and PFL were reconstructed with a combined tibia and fibula-based technique with two free Achilles allograft tendons (Fig. 4). The results of their study demonstrated no significant difference between the intact and reconstructed knees with respect to varus translation or external rotation at any flexion angle. In 2005, Arciero<sup>50</sup> published a technique in which the PLC was reconstructed with a fibular-based free soft tissue graft recreating the insertion sites of the FCL and PT on the femur using a dual femoral socket

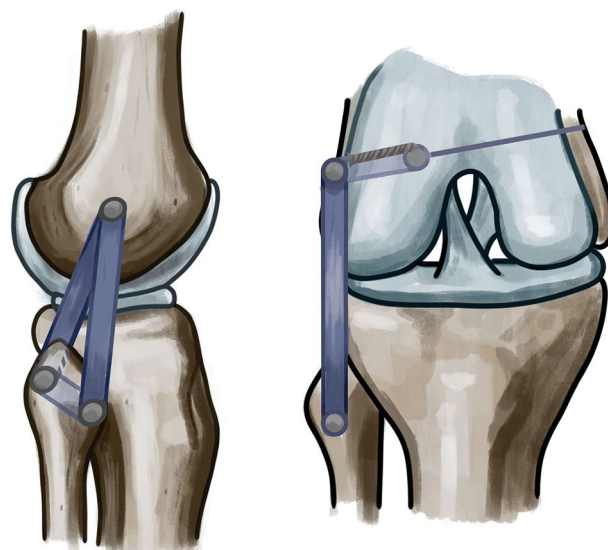


Fig. 3 Larson's posterolateral corner reconstruction technique.

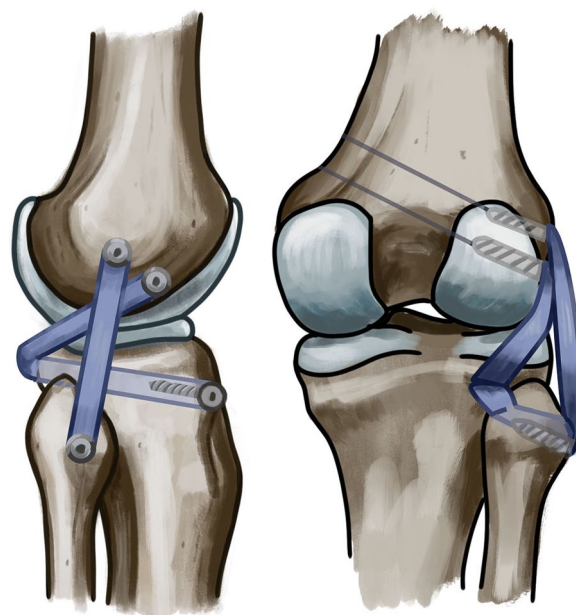
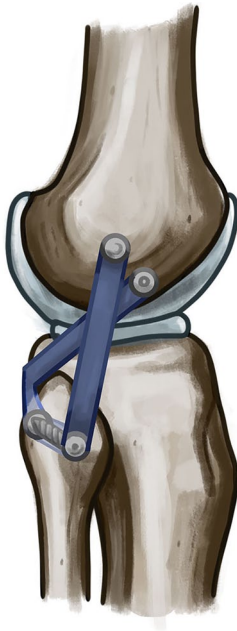
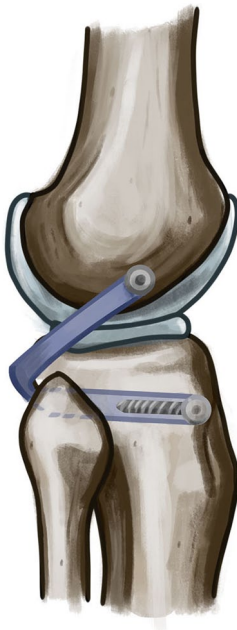
Fig. 4 LaPrade's posterolateral corner reconstruction technique.

technique (Fig. 5). The author noted in a clinical series that this reconstruction technique predictably restored varus and external rotation stability. In Europe, a popular technique involves performing a Larson procedure<sup>48</sup> combined with a popliteus bypass (Fig. 6) originating from the femoral footprint of the PLT to the posterolateral aspect of the tibia to restore the biomechanical properties of the PFL, as first described by Werner Müller.<sup>51</sup>



**Fig. 5** Arciero's posterolateral corner reconstruction technique.



**Fig. 6** Popliteal bypass reconstruction.

#### *Tunnel collision*

In multiligament knee reconstructions, where multiple femoral tunnels for reconstruction graft fixation are required, it may be difficult to determine the best angle for drilling to avoid tunnel collisions. Tunnel collisions may lead to graft rupture or to excessively short tunnels. Regarding this problem, Moatshe et al<sup>52</sup> concluded that

femoral tunnel orientations during PLC and ACL reconstructions need to be adjusted to avoid tunnel convergence. Aiming the FCL and PT tunnels 35° anteriorly eliminated convergence with the ACL tunnel. They also showed that PT tunnels aimed at 0° in the axial plane had an increased risk of violating the intercondylar notch.

Gelber et al<sup>53</sup> found that when PLC reconstructions are performed in combination with concomitant ACL or PCL reconstructions, the PT femoral tunnel should be drilled at 30° axial and 30° coronal angulations and FCL femoral tunnel at 30° axial and 0° coronal angulations to avoid tunnel convergence between reconstructions.

#### *Graft selection*

Graft selection in multiligament knee injuries needs careful planning, and most of the PLC lesions belong to this type of injury. From a rational point of view, harvesting of autograft tissue can increase the morbidity of the knee and the already damaged soft tissues.<sup>54</sup> A recent review<sup>55</sup> shows equivalent clinical results with the use of autografts or allografts. It remains, however, difficult to generate a conclusive evidence-based approach due to the paucity of high-level research. When confronted by the need for combined reconstructions with multiple grafts, preservation of synergistic muscles, and adapted postoperative rehabilitation; the current evidence does offer support for the use of allograft tissue.

#### *Comparative evidence between techniques*

Despite the recent advances in anatomic, biomechanical, and clinical understanding of the PLC of the knee, there is still no consensus about which technique is better for reconstructions.

Treme et al<sup>56</sup> compared the Arciero technique and the LaPrade reconstruction technique in a controlled laboratory study. They concluded that both techniques were equally effective at restoring stability to knees with PLC injuries, but neither reconstruction technique fully restored stability to knees with combined PLC and proximal tibiofibular joint injuries.

Van Gennip et al<sup>57</sup> presented the clinical results and varus stability (measured using stress X-rays) of a two-year follow-up cohort of Larson's PLC reconstruction in patients with symptomatic instability of the knee. These data were compared with data of a previous study<sup>58</sup> from the same authors where a LaPrade reconstruction of the PLC was made. No statistically significant differences in clinical outcomes and stress radiographs were observed.

Drenck et al<sup>59</sup> compared the biomechanical properties of an FCL reconstruction plus popliteus bypass technique against the Larson technique for the reconstruction of a combined PLC and PCL injury. The varus angulation was effectively reduced in both groups and did not

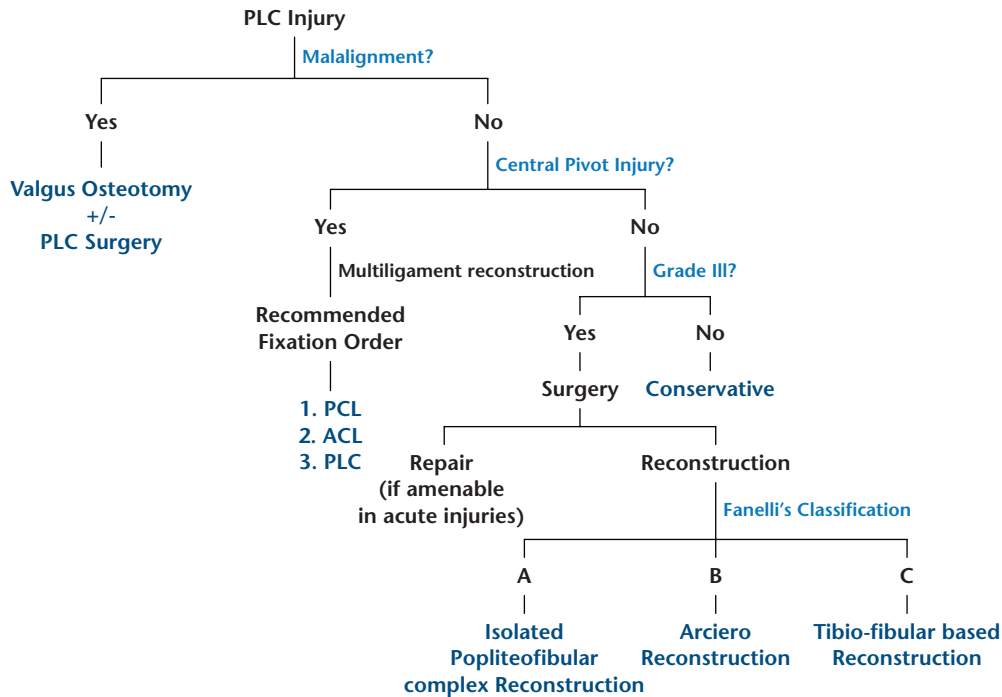


Fig. 7 Author’s surgical decision algorithm. PLC: posterolateral corner, PCL: posterior cruciate ligament, ACL: anterior cruciate ligament.

significantly differ from the intact knee. Posterior translation was reduced by both techniques with no differences, but none of the groups had restored stability to the intact state, with the exception of the FCL reconstruction plus popliteus bypass at 0° of flexion. The two techniques revealed major differences in their abilities to reduce external rotational instability, with the FCL reconstruction plus popliteus bypass restoring rotational instability compared to the state of the intact knee at all degrees of flexion. They concluded that the addition of a popliteus bypass for PLC reconstruction has superior biomechanical properties related to external rotational stability compared to the Larson technique.

Vezeridis et al<sup>60</sup> analysed the biomechanical integrity of two PLC reconstruction techniques in eight cadavers. They concluded that both a fibular-based docking technique and a tibiofibular-based technique for isolated PLC reconstruction provided appropriate constraint, yet the fibular-based technique underconstrained the knee at 90°, and the tibiofibular-based reconstruction overconstrained the knee at 60°.

Considering the evidence presented, no technique seems to clearly prevail over the others. Schillhammer,<sup>61</sup> in an editorial comment, described that as anatomic, biomechanical, and clinical knowledge of PLC injuries continues to progress, finding the balance between re-creating native anatomy and safely performing PLC reconstruction poses a big challenge, and that treatment decisions should be made on a case-by-case basis.

*Surgical decision algorithm*

A surgical algorithm was developed for this article based on the article by Weiler et al,<sup>62</sup> with some modifications based on author’s experience (Fig. 7):

1. Malalignment: There are ongoing discussions regarding which degree of varus malalignment requires bony realignment prior to reconstructive ligament surgery.<sup>63–65</sup> It is well known that a high varus moment increases the stress on a lateral ligament reconstruction. However, PLC instability does not necessarily need an osteotomy if there is no thrust and only mild varus malalignment. Conversely, in cases with a higher degree of varus malalignment and/or the presence of a varus thrust, an additional valgus producing osteotomy prior to the reconstruction or an osteotomy as a sole procedure is required.
2. Central pivot involvement: When there is central pivot ligament involvement. In these cases, it is generally accepted that the central pivot needs to be reconstructed in any case of a lateral instability irrespective of the degree of instability.<sup>66,67</sup> The following order of graft fixation is commonly recommended: PCL graft first, ACL graft second, and the PLC reconstruction last.
3. Grade III PLC injury: Repair can be envisaged, but reconstruction is the preferred method. The reconstruction is adapted to the level of injury:

- i. Fanelli A (isolated posterolateral rotation): An isolated reconstruction of the popliteofibular complex (popliteus bypass) may be considered, leaving the FCL untreated.
- ii. Fanelli B (posterolateral rotation instability with mild to moderate varus instability): an Arciero reconstruction technique<sup>50</sup> may be considered.
- iii. Fanelli C (posterolateral rotation instability with the addition of marked varus instability): A tibiofibular-based technique (for example LaPrade<sup>49</sup> reconstruction technique) may be considered.

## Conclusion

Injuries to the PLC of the knee are significant and occur most commonly in the context of a multiligament knee injury. Improved anatomic, biomechanical, and clinical understanding has led to the development of anatomic reconstructions that have resulted in improved patient outcomes. Non-operative treatment is usually recommended for patients with grade I or grade II injuries showing positive results of return of activity level and radiographic evaluation. For grade III injuries surgery is recommended. The surgical procedure depends on the type and chronicity of the lesion (repair, reconstruction, osteotomy). Based on lower reported failure rates with PLC reconstruction compared to repairs, the pendulum has swung in favour of PLC reconstruction in most patient situations.

### AUTHOR INFORMATION

<sup>1</sup>Clinica Alemana-Universidad del Desarrollo, Santiago, Chile.

<sup>2</sup>Hospital Sotero del Rio, Santiago, Chile.

<sup>3</sup>Southmead Hospital, Bristol, UK.

<sup>4</sup>Clinica do Dragão, Espregueira-Mendes Sports Centre – FIFA Medical Centre of Excellence, Portugal.

<sup>5</sup>Dom Henrique Research Centre, Portugal.

<sup>6</sup>3B's Research Group – Biomaterials, Biodegradables and Biomimetics, University of Minho, Portugal.

<sup>7</sup>ICVS/3B's-PT Government Associate Laboratory, Portugal.

<sup>8</sup>Orthopaedics Department of Minho University, Portugal.

Correspondence should be sent to: Francisco Figueroa, Vitacura 5951, Santiago, Chile.

Email: franciscofigueroab@gmail.com

### ICMJE CONFLICT OF INTEREST STATEMENT

The authors declare no conflict of interest relevant to this work.

### FUNDING STATEMENT

No benefits in any form have been received or will be received from a commercial party related directly or indirectly to the subject of this article.

### OPEN ACCESS

© 2021 The author(s)

This article is distributed under the terms of the Creative Commons Attribution-Non Commercial 4.0 International (CC BY-NC 4.0) licence (<https://creativecommons.org/licenses/by-nc/4.0/>) which permits non-commercial use, reproduction and distribution of the work without further permission provided the original work is attributed.

### REFERENCES

1. DeLee JC, Riley MB, Rockwood CA Jr. Acute posterolateral rotatory instability of the knee. *Am J Sports Med* 1983;11:199–207.
2. LaPrade RF, Wentorf FA, Fritts H, Gundry C, Hightower CD. A prospective magnetic resonance imaging study of the incidence of posterolateral and multiple ligament injuries in acute knee injuries presenting with a hemarthrosis. *Arthroscopy* 2007;23:1341–1347.
3. Fanelli GC, Edson CJ. Posterior cruciate ligament injuries in trauma patients: part II. *Arthroscopy* 1995;11:526–529.
4. Hughston JC, Andrews JR, Cross MJ, Moschi A. Classification of knee ligament instabilities. Part II. The lateral compartment. *J Bone Joint Surg [Am]* 1976;58:173–179.
5. Kennedy MI, Bernhardson A, Moatshe G, Buckley PS, Engebretsen L, LaPrade RF. Fibular collateral ligament/posterolateral corner injury: when to repair, reconstruct, or both. *Clin Sports Med* 2019;38:261–274.
6. LaPrade RF, Ly TV, Wentorf FA, Engebretsen L. The posterolateral attachments of the knee: a qualitative and quantitative morphologic analysis of the fibular collateral ligament, popliteus tendon, popliteofibular ligament, and lateral gastrocnemius tendon. *Am J Sports Med* 2003;31:854–860.
7. LaPrade RF, Tso A, Wentorf FA. Force measurements on the fibular collateral ligament, popliteofibular ligament, and popliteus tendon to applied loads. *Am J Sports Med* 2004;32:1695–1701.
8. Natsis K, Karasavvidis T, Kola D, Papadopoulos S, Totlis T. Menisofibular ligament: how much do we know about this structure of the posterolateral corner of the knee: anatomical study and review of literature. *Surg Radiol Anat* 2020;42:120–1208.
9. Terry GC, LaPrade RF. The posterolateral aspect of the knee: anatomy and surgical approach. *Am J Sports Med* 1996;24:732–739.
10. Gollehon DL, Torzilli PA, Warren RF. The role of the posterolateral and cruciate ligaments in the stability of the human knee: a biomechanical study. *J Bone Joint Surg [Am]* 1987;69:233–242.
11. Grood ES, Stowers SF, Noyes FR. Limits of movement in the human knee: effect of sectioning the posterior cruciate ligament and posterolateral structures. *J Bone Joint Surg [Am]* 1988;70:88–97.
12. Gwathmey FW Jr, Tompkins MA, Gaskin CM, Miller MD. Can stress radiography of the knee help characterize posterolateral corner injury? *Clin Orthop Relat Res* 2012;470:768–773.
13. Ranawat A, Baker CL III, Henry S, Harner CD. Posterolateral corner injury of the knee: evaluation and management. *J Am Acad Orthop Surg* 2008;16:506–518.
14. Parsons EM, Gee AO, Spiekerman C, Cavanagh PR. The biomechanical function of the anterolateral ligament of the knee: response. *Am J Sports Med* 2015;43:NP22.
15. LaPrade RF, Wozniczka JK, Stellmaker MP, Wijdicks CA. Analysis of the static function of the popliteus tendon and evaluation of an anatomic reconstruction: the 'fifth ligament' of the knee. *Am J Sports Med* 2010;38:543–549.
16. LaPrade RF. Arthroscopic evaluation of the lateral compartment of knees with grade 3 posterolateral knee complex injuries. *Am J Sports Med* 1997;25:596–602.



- 17. LaPrade RF, Resig S, Wentorf F, Lewis JL.** The effects of grade III posterolateral knee complex injuries on anterior cruciate ligament graft force: a biomechanical analysis. *Am J Sports Med* 1999;27:469–475.
- 18. Natsis K, Karasavvidis T, Kola D, Papadopoulos S, Totlis T.** Meniscomfibular ligament: how much do we know about this structure of the posterolateral corner of the knee: anatomical study and review of literature. *Surg Radiol Anat* 2020;42:1203–1208.
- 19. Jabara M, Bradley J, Merrick M.** Is stability of the proximal tibiofibular joint important in the multiligament-injured knee? *Clin Orthop Relat Res* 2014;472:2691–2697.
- 20. Geeslin AG, LaPrade RF.** Location of bone bruises and other osseous injuries associated with acute grade III isolated and combined posterolateral knee injuries. *Am J Sports Med* 2010;38:2502–2508.
- 21. Stannard JP, Schreiner AJ.** Vascular injuries following knee dislocation. *J Knee Surg* 2020;33:351–356.
- 22. Ridley TJ, McCarthy MA, Bollier MJ, Wolf BR, Amendola A.** The incidence and clinical outcomes of peroneal nerve injuries associated with posterolateral corner injuries of the knee. *Knee Surg Sports Traumatol Arthrosc* 2018;26:806–811.
- 23. Moatshe G, Dornan GJ, Løken S, Ludvigsen TC, LaPrade RF, Engebretsen L.** Demographics and injuries associated with knee dislocation: a prospective review of 303 patients. *Orthop J Sports Med* 2017;5:2325967117706521.
- 24. Hughston JC, Norwood LA Jr.** The posterolateral drawer test and external rotational recurvatum test for posterolateral rotatory instability of the knee. *Clin Orthop Relat Res* 1980;147:82–87.
- 25. Gollehon DL, Torzilli PA, Warren RF.** The role of the posterolateral and cruciate ligaments in the stability of the human knee: a biomechanical study. *J Bone Joint Surg [Am]* 1987;69:233–242.
- 26. Fanelli GC, Larson RV.** Practical management of posterolateral instability of the knee. *Arthroscopy* 2002;18:1–8.
- 27. Bae WH, Ha JK, Kim JG.** Treatment of posterolateral rotatory instability of the knee. *J Korean Knee Soc* 2010;22:1–10.
- 28. Crespo B, James EW, Metsavaht L, LaPrade RF.** Injuries to posterolateral corner of the knee: a comprehensive review from anatomy to surgical treatment. *Rev Bras Ortop* 2014;50:363–370.
- 29. Bonadio MB, Helito CP, Gury LA, Demange MK, Pécora JR, Angelini FJ.** Correlation between magnetic resonance imaging and physical exam in assessment of injuries to posterolateral corner of the knee. *Acta Ortop Bras* 2014;22:124–126.
- 30. Cinque ME, Geeslin AG, Chahla J, et al.** The heel height test: a novel tool for the detection of combined anterior cruciate ligament and fibular collateral ligament tears. *Arthroscopy* 2017;33:2177–2181.
- 31. LaPrade RF, Heikes C, Bakker AJ, Jakobsen RB.** The reproducibility and repeatability of varus stress radiographs in the assessment of isolated fibular collateral ligament and grade-III posterolateral knee injuries: an in vitro biomechanical study. *J Bone Joint Surg Am* 2008;90:2069–2076.
- 32. Jackman T, LaPrade RF, Pontinen T, Lender PA.** Intraobserver and interobserver reliability of the kneeling technique of stress radiography for the evaluation of posterior knee laxity. *Am J Sports Med* 2008;36:1571–1576.
- 33. Pacheco RJ, Ayre CA, Bollen SR.** Posterolateral corner injuries of the knee: a serious injury commonly missed. *J Bone Joint Surg [Br]* 2011;93:194–197.
- 34. Chahla J, Murray IR, Robinson J, et al.** Posterolateral corner of the knee: an expert consensus statement on diagnosis, classification, treatment, and rehabilitation. *Knee Surg Sports Traumatol Arthrosc* 2019;27:2520–2529.
- 35. Gelber PE, Drager J, Maheshwer B, et al.** Large variability exists in the management of posterolateral corner injuries in the global surgical community. *Knee Surg Sports Traumatol Arthrosc* 2020;28:2116–2123.
- 36. Kannus P.** Nonoperative treatment of grade II and III sprains of the lateral ligament compartment of the knee. *Am J Sports Med* 1989;17:83–88.
- 37. Krukhaug Y, Mølster A, Rodt A, Strand T.** Lateral ligament injuries of the knee. *Knee Surg Sports Traumatol Arthrosc* 1998;6:21–25.
- 38. DeLee JC, Riley MB, Rockwood CA Jr.** Acute straight lateral instability of the knee. *Am J Sports Med* 1983;11:404–411.
- 39. Grana WA, Janssen T.** Lateral ligament injury of the knee. *Orthopedics* 1987;10:1039–1044.
- 40. Krukhaug Y, Mølster A, Rodt A, Strand T.** Lateral ligament injuries of the knee. *Knee Surg Sports Traumatol Arthrosc* 1998;6:21–25.
- 41. Stannard JP, Brown SL, Farris RC, McGwin G Jr, Volgas DA.** The posterolateral corner of the knee: repair versus reconstruction. *Am J Sports Med* 2005;33:881–888.
- 42. Levy BA, Dajani KA, Morgan JA, Shah JP, Dahm DL, Stuart MJ.** Repair versus reconstruction of the fibular collateral ligament and posterolateral corner in the multiligament-injured knee. *Am J Sports Med* 2010;38:804–809.
- 43. Westermann RW, Marx RG, Spindler KP, et al; MOON Knee Group.** No difference between posterolateral corner repair and reconstruction with concurrent ACL surgery: results from a prospective multicenter cohort. *Orthop J Sports Med* 2019;7:2325967119861062.
- 44. Shelbourne KD, Haro MS, Gray T.** Knee dislocation with lateral side injury: results of an en masse surgical repair technique of the lateral side. *Am J Sports Med* 2007;35:1105–1116.
- 45. Hodax JD, Cohen BH, DeFroda SF, Sobel AD, Fadale PD.** Comparison of three fixation techniques for arcuate fractures. *Injury* 2020;51:478–482.
- 46. Arthur A, LaPrade RF, Agel J.** Proximal tibial opening wedge osteotomy as the initial treatment for chronic posterolateral corner deficiency in the varus knee. *Am J Sports Med* 2007;35:1844–1850.
- 47. Noyes FR, Barber-Westin SD, Hewett TE.** High tibial osteotomy and ligament reconstruction for varus angulated anterior cruciate ligament-deficient knees. *Am J Sports Med* 2000;28:282–296.
- 48. Cooley VJ, Harrington RM, Larson RV.** Effect of lateral ligament reconstruction on intra-articular posterior cruciate ligament graft force and knee motion. *University of Washington Research Report* 1996;14:37–41.
- 49. LaPrade RF, Johansen S, Wentorf FA, Engebretsen L, Esterberg JL, Tso A.** An analysis of an anatomical posterolateral knee reconstruction: an in vitro biomechanical study and development of a surgical technique. *Am J Sports Med* 2004;32:1405–1414.
- 50. Arciero RA.** Anatomic posterolateral corner knee reconstruction. *Arthroscopy* 2005;21:1147.
- 51. Müller W.** Clinical material and result. In: Müller W, ed. *The knee: form, function, and ligament reconstruction*. New York, NY: Springer-Verlag, 1982:chap 10.
- 52. Moatshe G, Brady AW, Slette EL, et al.** Multiple ligament reconstruction femoral tunnels: intertunnel relationships and guidelines to avoid convergence. *Am J Sports Med* 2017;45:563–569.
- 53. Gelber PE, Erquicia JI, Sosa G, et al.** Femoral tunnel drilling angles for the posterolateral corner in multiligamentary knee reconstructions: computed tomography evaluation in a cadaveric model. *Arthroscopy* 2013;29:257–265.

- 54. Figueroa F, Figueroa D, Calvo R, Vaisman A, Espregueira-Mendes J.** Graft choice in combined anterior cruciate ligament and medial collateral ligament reconstruction. *EFORT Open Rev* 2020;5:221–225.
- 55. Strauss MJ, Varatojo R, Boutefnouchet T, et al.** The use of allograft tissue in posterior cruciate, collateral and multi-ligament knee reconstruction. *Knee Surg Sports Traumatol Arthrosc* 2019;27:1791–1809.
- 56. Treme GP, Salas C, Ortiz G, et al.** A biomechanical comparison of the Arciero and LaPrade reconstruction for posterolateral corner knee injuries. *Orthop J Sports Med* 2019;7:2325967119838251.
- 57. van Gennip S, van der Wal WA, Heesterbeek PJC, Wymenga AB, Busch VJF.** Posterolateral corner reconstruction in combined injuries of the knee: improved stability with Larson's fibular sling reconstruction and comparison with LaPrade anatomical reconstruction. *Knee* 2020;27:124–131.
- 58. van der Wal WA, Heesterbeek PJ, van Tienen TG, Busch VJ, van Ochten JH, Wymenga AB.** Anatomical reconstruction of posterolateral corner and combined injuries of the knee. *Knee Surg Sports Traumatol Arthrosc* 2016;24:221–228.
- 59. Drenck TC, Preiss A, Domnick C, et al.** The Popliteus Bypass provides superior biomechanical properties compared to the Larson technique in the reconstruction of combined posterolateral corner and posterior cruciate ligament injury. *Knee Surg Sports Traumatol Arthrosc* 2021;29:732–741.
- 60. Vezeridis PS, Engler ID, Salzler MJ, et al.** Biomechanics following isolated posterolateral corner reconstruction comparing a fibular-based docking technique with a tibia and fibular-based anatomic technique show either technique is acceptable. *Arthroscopy* 2020;36:1376–1385.
- 61. Schillhammer CK.** Editorial commentary: posterolateral corner reconstruction: is better (anatomy) the enemy of good? *Arthroscopy* 2020;36:1363–1364.
- 62. Weiler A, Froesch KH, Gwinner C, Strobel MJ, Lobenhoffer P.** The Posterolateral Instability Score (PoLIS) of the knee joint: a guideline for standardized documentation, classification, and surgical decision-making. *Knee Surg Sports Traumatol Arthrosc* 2021;29:889–899.
- 63. Badhe NP, Forster IW.** High tibial osteotomy in knee instability: the rationale of treatment and early results. *Knee Surg Sports Traumatol Arthrosc* 2002;10:38–43.
- 64. Noyes FR, Barber-Westin SD, Albright JC.** An analysis of the causes of failure in 57 consecutive posterolateral operative procedures. *Am J Sports Med* 2006;34:1419–1430.
- 65. Tischer T, Paul J, Pape D, et al.** The impact of osseous malalignment and realignment procedures in knee ligament surgery: a systematic review of the clinical evidence. *Orthop J Sports Med* 2017;5:2325967117697287.
- 66. Höher J, Harner CD, Vogrin TM, Baek GH, Carlin GJ, Woo SL.** In situ forces in the posterolateral structures of the knee under posterior tibial loading in the intact and posterior cruciate ligament-deficient knee. *J Orthop Res* 1998;16:675–681.
- 67. Krudwig WK, Witzel U, Ullrich K.** Posterolateral aspect and stability of the knee joint. II. Posterolateral instability and effect of isolated and combined posterolateral reconstruction on knee stability: a biomechanical study. *Knee Surg Sports Traumatol Arthrosc* 2002;10:91–95.