

Lung carcinoma with small intestinal metastases and gastrointestinal bleeding: A rare case report

TIANZI LIU^{1*}, YAN GENG^{1*}, ZICHUAN WANG¹, XINTONG PENG¹, JING LIU² and YAN HUANG²

¹School of Clinical Medicine, Weifang Medical University, Weifang, Shandong 261053; ²Department of Oncology, The Affiliated Hospital of Weifang Medical University, Weifang, Shandong 261041, P.R. China

Received December 13, 2022; Accepted March 28, 2023

DOI: 10.3892/ol.2023.13827

Abstract. The occurrence of small intestinal metastases from primary lung cancer is rare. This report documents the case of a 57-year-old male patient initially diagnosed with non-metastatic lung adenocarcinoma, who presented with abdominal pain 6 months later. Postoperative pathological analysis confirmed the final diagnosis to be small intestinal metastasis from primary lung cancer. Thoracoscopic surgery and systemic chemotherapy were the preferred treatment options. However, the lung tumor spread to the small intestine, causing intestinal obstruction. As the patient could not tolerate anti-tumor therapy, only symptomatic treatment was provided. The patient experienced massive gastrointestinal bleeding and died the next day. Although small intestinal metastasis from lung cancer is rare and difficult to diagnose accurately, it should be considered when encountering a patient with lung cancer exhibiting abdominal symptoms and associated imaging findings. At this point, a pathological diagnosis should be performed immediately to determine the nature and source of the tumor. Furthermore, individualized treatment should be conducted in strict accordance with oncology guidelines. Of note, early detection and treatment are critical to ensure favorable outcomes.

Introduction

Lung cancer is the leading cause of cancer-related death worldwide, with most patients presenting with metastases during diagnosis (1). According to the GLOBOCAN 2020 report by the World Health Organization's International Agency for Research on Cancer, ~2.2 million new cases of lung cancer occur worldwide each year, making it the world's second most common but most fatal cancer type (2,3). Patients with early-stage lung cancer are asymptomatic, whereas those with advanced metastasis are frequently symptomatic due to metastatic sites. Once distant metastasis occurs, there is almost no opportunity for surgery and the prognosis is poor. Of note, distant metastases occur most commonly in the brain, liver, adrenal glands and bones. Furthermore, the gastrointestinal (GI) tract is not a common site of primary lung cancer metastasis (4). According to clinical studies, the incidence of gastrointestinal metastasis ranges from 0.2 to 1.7%, whereas the rate from autopsy reports ranges from 4.7 to 14%. This suggests that the process of GI metastasis of lung cancer is subtle and lacks specific clinical symptoms. GI metastasis is frequently found due to severe complications, such as intestinal obstruction and bleeding (5,6). The present report describes an uncommon case of small intestinal metastasis from lung cancer. Furthermore, the literature relevant to the occurrence, diagnosis and treatment of GI metastasis of lung cancer was reviewed.

Case report

A 57-year-old male patient had a paroxysmal cough and produced 5 ml of spit and sputum mixed with blood daily without any obvious underlying cause. The patient had a medical history of diabetes for 1 year and tobacco smoking for 3 years. In March 2020, 2 months after initial symptom development, the patient underwent a computed tomography (CT) scan, which revealed a mass 6.5x6.2x7.2 cm in size in the upper lobe of the right lung (Fig. 1A). The patient was subjected to right upper lobe resection with lymph node dissection at the end of March 2020 at a local hospital. Postoperative pathology indicated infiltrating adenocarcinoma (right upper lobe mass) with poor differentiation and lymph node metastasis. The protocol for histopathology was performed according to standard procedures. Immunohistochemistry

Correspondence to: Professor Yan Huang, Department of Oncology, The Affiliated Hospital of Weifang Medical University, 2428 Yuhe Road, Weifang, Shandong 261041, P.R. China
E-mail: yanhuangdr@126.com

*Contributed equally

Abbreviations: CK7, cytokeratin 7; CT, computed tomography; GI, gastrointestinal; HCT, hematocrit; IHC, immunohistochemistry; NSCLC, non-small cell lung cancer; PET, positron emission tomography; PD-L1, programmed cell death-ligand 1; PD-1, programmed cell death 1; TTF-1, thyroid transcription factor-1

Key words: chemotherapy, gastrointestinal bleeding, immunohistochemistry, lung cancer, small intestinal metastases, positron emission tomography-computed tomography

(IHC) stains for pan-cytokeratin (cat. no. ZM-0069), vimentin (cat. no. ZM-0260), cytokeratin 7 (CK7) (cat. no. ZM-0071), thyroid transcription factor-1 (TTF-1) (cat. no. ZM-0262) and Ki-67 labeling index (35%) (cat. no. ZM-0166) were positive (Fig. S1). IHC staining was performed according to standard procedures. Ready-to-use antibodies, which were not diluted, were purchased from Beijing Zhongshan Golden Bridge Biological Technology Co., Ltd. Whole-body CT examination revealed no distant metastases anywhere, including the brain. The patient was diagnosed with lung adenocarcinoma (pT4N2M0 stage IIIB) (7). Four cycles of chemotherapy with docetaxel and nedaplatin stabilized the patient's condition. After the chemotherapy, the patient received no additional radiotherapy or other related treatments for personal reasons.

Approximately 6 months after completing chemotherapy, the patient presented with abdominal pain and melena. He was transferred to Affiliated Hospital of Weifang Medical University (Weifang, China) in January 2021. The abdominal CT revealed multiple small intestinal tumors in the left lower abdomen, whereas chest CT indicated no primary tumor in both lungs or hilum (Fig. 1B). No obvious enlarged lymph nodes were found in the mediastinum (Fig. 1C). Simultaneously, the abdominal CT displayed intrahepatic calcification without metastasis (Fig. 2A and B). Imaging examination revealed a high possibility of small intestinal lymphoma (Fig. 2C). Upon hospital admission, the patient underwent small bowel tumor resection and intestinal adhesiolysis with tissue sampling to ascertain the nature of the tumor. The patient tolerated the procedure well and the postoperative course was uneventful. The postoperative CT indicated that the surgical staples were present after resecting the small bowel mass and the patient recovered well (Fig. 2D). Furthermore, the postoperative pathology of the enteral mass indicated metastatic lesions from poorly differentiated lung adenocarcinoma. Molecular analysis revealed no mutations in the proto-oncogene. Hematoxylin and eosin staining showed that the tumor permeated the whole small intestinal wall and regional lymph node carcinoma was positively identified (Fig. 3A). IHC staining was positive for CK7 (cat. no. Kit-0021) and TTF-1 (cat. no. MAB-0599), with negative CK20 (cat. no. Kit-0025) (Fig. 3B-D). These antibodies were purchased from Fuzhou Maixin Biotech, Co., Ltd. Furthermore, IHC stains for CK7, TTF-1, epithelial membrane antigen and Ki-67 labeling index (60%) were positive (Fig. 3E). None of these antibodies were diluted. Immunohistochemistry (IHC) staining was performed according to standard procedures. This IHC staining profile supported metastatic adenocarcinoma from the lungs, rather than primary intestinal adenocarcinoma. The expression rate of programmed cell death-ligand 1 (PD-L1) (cat. no. 22C3) was 40%. This antibody was purchased from Dako North America, Inc. And PD-L1 staining was performed according to standard procedures. The patient was diagnosed with small intestinal metastasis from lung cancer. The patient demonstrated slow recovery of intestinal function postoperatively, and due to being in a poor personal economic situation, the patient refused systemic treatment; therefore, no systemic therapy was administered.

After another two months, the patient was admitted to the emergency department of our institution with persistent abdominal pain. The patient reported the absence of gas and feces with

abdominal pain during the previous few days. Furthermore, a physical examination revealed a distended abdomen with epigastric tenderness. An abdominal CT indicated multiple metastatic masses on the small intestinal wall and multiple metastatic low-density lesions in the liver (Fig. 4A and B). The multiple intestinal metastases caused small bowel obstruction. Tarry stools were observed after an enema, and GI bleeding was suspected. Furthermore, laboratory evaluations revealed a hemoglobin concentration of 71 g/l (reference range, 115-150 g/l) and a hematocrit (HCT) value of 23.8% (reference range, 35-45%), both below the normal range. Based on these observations, the patient was diagnosed with multiple small bowel metastases from lung cancer accompanied by complete intestinal obstruction and GI bleeding. The patient was too compromised for surgery at this time to control disease progression, as the performance status (PS) was >2. The PS score was developed by the Eastern Cooperative Oncology Group (ECOG), also known as the ECOG-PS score, which refers to the general health status and treatment tolerance of patients from their physical strength (8). Instead, the patient was placed on systemic therapy with pemetrexed, carboplatin and camrelizumab [a programmed cell death 1 (PD-1) inhibitor]. Subsequently, the patient developed severe anemia (HCT 19.6%) from GI bleeding and received blood transfusion and fluid rehydration therapy. Severe abdominal pain and reduced HCT during systemic treatment significantly reduced the patient's physical condition. The final abdominal CT revealed multiple metastases in the liver, small intestine and abdominal cavity, which had increased in number and size (Fig. 4C and D). The patient was no longer able to tolerate anti-tumor therapy; therefore, only symptomatic treatment was continued. The patient experienced excessive GI bleeding and died the next day.

Discussion

Lung cancer is one of the most common malignant tumors in humans (1). The following are the two main histological types of lung cancer: small cell lung cancer and non-small cell lung cancer (NSCLC). NSCLC is the most common histological type of lung cancer, which includes squamous cell carcinoma, adenocarcinoma, large cell carcinoma, adenosquamous carcinoma and sarcomatoid carcinoma (9,10). As demonstrated in autopsy studies, lung cancer metastases may infiltrate every systemic tissue (11). Squamous cell carcinoma (28.5%), adenocarcinoma (27.6%) and large cell carcinoma (20.9%) are the three most common histological types of NSCLC to develop distant metastasis (5). Small intestinal metastasis from NSCLC is unusual (11-14). Recently, the incidence of GI metastasis from lung cancer has been reported to be <2% (14). The small intestine has a low incidence of metastasis, which may be attributed to abundant lymphoid tissue in the intestinal wall, which includes numerous T lymphocytes, and provides the wall with a high level of protection. Of note, the jejunum and ileum are the most common metastatic sites of the digestive tract, followed by the duodenum (15,16). As indicated in the abdominal CT of the patient, the intestinal wall of the ileum in the left lower abdomen was thickened and multiple lymph node shadows were observed. The reason for the difference in small intestinal metastasis site may be the abundant lymphoid tissue and blood supply around the empty ileum.

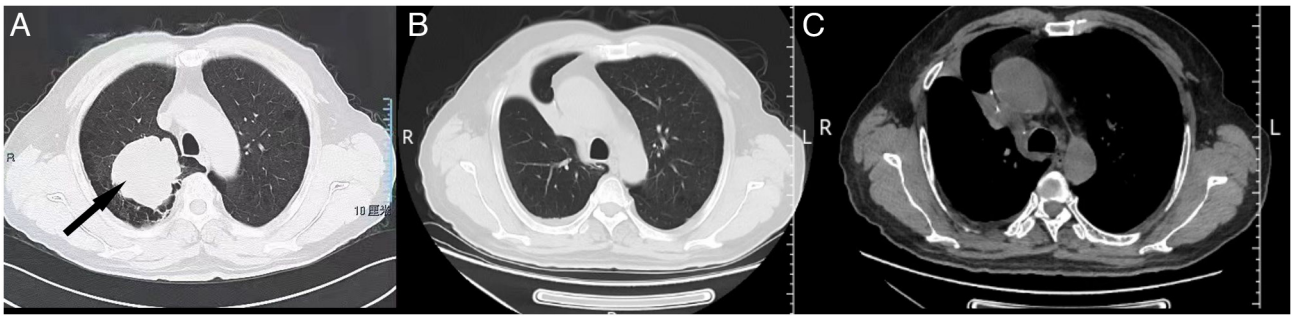


Figure 1. Chest CT scans of a 57-year-old male patient prior to and after surgery. (A) Preoperative chest CT displaying a mass in the upper lobe of the right lung. The black arrow indicates the mass. (B) The postoperative chest CT indicated no primary tumor in both lungs or hilum. (C) The postoperative CT revealing no obviously enlarged lymph nodes in the mediastinum. CT, computed tomography.

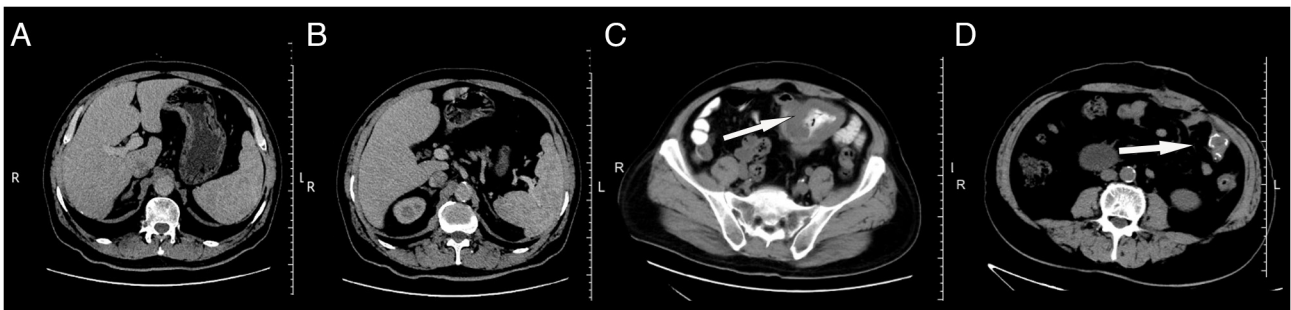


Figure 2. Abdominal CT scans of the 57-year-old male patient with multiple small intestinal metastases from lung cancer. (A) Initial abdominal CT indicating intrahepatic tumor without metastasis. (B) Initial abdominal CT indicating no tumor metastasis in the liver. (C) The initial abdominal CT revealed multiple small intestinal tumors in the left lower abdomen. The white arrow indicates the metastatic tumors. (D) Abdominal CT displaying surgical staples after resection of the small bowel mass. The white arrow indicates the surgical staples. CT, computed tomography.

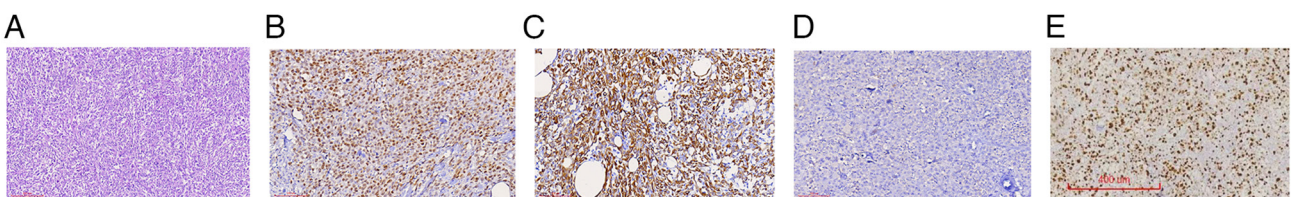


Figure 3. Histological analyses of small bowel tumors after resection (January 2021). (A) The tumor cells are polygonal, with a cytoplasm, eosinophilic, nuclear polygonal and without any obvious adenoid structure (hematoxylin and eosin staining; magnification, x100; scale bar, 200 μ m). (B) Tumor cells had positive staining for CK7 (IHC staining; magnification, x200, scale bar, 100 μ m). (C) Tumor cells exhibited positive staining for thyroid transcription factor-1 (IHC staining; magnification, x200; scale bar, 100 μ m). (D) Tumor cells had negative staining for CK20 (IHC staining; magnification, x200; scale bar, 100 μ m). (E) The tumor cells had a Ki-67 labeling index of 60% (IHC staining; scale bar, 400 μ m). CK, cytokeratin; IHC, immunohistochemical.

An analysis of 366 cases revealed that of those patients with lung cancer diagnosed with small bowel metastasis, >50% die within 3 months (5) and <10% of lung cancer patients with small bowel metastasis have been reported to survive for >1 year. In the present case, the patient died within <3 months of the diagnosis due to small intestinal metastasis. The reasons for the short survival may be as follows: First, previous studies have indicated that lung cancer metastasis in the small intestine is frequently accompanied by metastasis from other sites, such as the kidney and liver. In this scenario, multiple metastases in the liver and abdominal cavity also occurred in the late stage of small intestinal metastasis, which implies that the prognosis of patients with tumors is poor, and the median survival time was <3 months (17). Furthermore, because small intestinal metastasis from lung cancer is uncommon and has

no obvious clinical symptoms in its early stage, it may lead to life-threatening abdominal symptoms, such as hemorrhage (24.6%), obstruction (20.4%) and perforation (20%) (5,18). In the present case, intestinal obstruction and bleeding symptoms occurred during the late stage of small intestinal metastasis of the patient. Due to the patient's poor physical condition, instead of surgery to relieve the obstruction, conservative treatment such as enema was performed, which may have exacerbated the possibility of intestinal bleeding and further aggravated the condition. Third, due to the patient's limited economic situation, no effective radiotherapy was provided in the early stage and no systemic treatment was administered to the small intestine tumor postoperatively. Therefore, as this treatment opportunity was missed, the tumor was not effectively controlled, resulting in a poor prognosis for the patient.

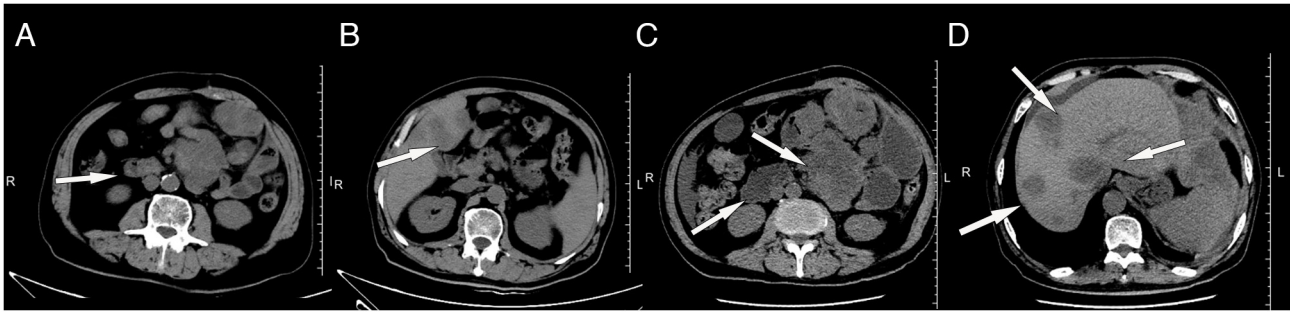


Figure 4. Abdominal CT scans of the 57-year-old male patient with multiple small intestinal metastases from lung cancer. (A) CT revealing multiple metastatic masses on the small intestinal wall 2 months after surgery. (B) CT revealing multiple metastatic low-density lesions in the liver 2 months after surgery. (C) The final CT indicating multiple large metastases on the small intestinal wall. (D) The final CT indicating multiple large metastases in the liver. The white arrows point to the metastatic tumors. CT, computed tomography.

Finally, although this patient was eligible for the first-line treatment of advanced or metastatic lung cancer and PD-L1 expression was 40%, the patient had a poor constitution and an ECOG PS >2. For treating small intestinal metastasis of lung cancer, particularly for patients who have undergone small intestinal surgery, first-line treatment for lung cancer is still the main treatment, including chemotherapy, radiotherapy, immunotherapy, targeted therapy and various combination therapies (19). By contrast, National Comprehensive Cancer Network guidelines recommend that systemic treatment may be applied to advanced or metastatic first-line treatment when the PS is 0-2. This disease progresses rapidly, and to control the disease, the combination of immunotherapy with chemotherapy may be the reason for the poor prognosis, which the patient may not tolerate.

Based on the patient's symptoms, imaging examinations help detect extrapulmonary lesions. Kim *et al* (20) evaluated the CT scanning results of 28 patients with GI metastasis from lung cancer and found that 5/26 and 21/26 had two and one lesion, respectively. The shapes of the GI lesions varied on CT scans, including wall thickening in 14 cases, an intraluminal polypoid mass in 14 and an exophytic mass in the other 3 (20). Lardinois *et al* (21) reported that solitary extrapulmonary lesions were observed in 21% of patients with NSCLC using positron emission tomography (PET)-CT imaging. Compared with conventional CT and other imaging methods, PET-CT may detect solitary extrapulmonary malignant lesions, such as GI tumors (18,20-22). However, PET-CT is not yet routinely performed, as it is expensive. For instance, in the case of the present study, PET-CT was not performed due to the economic limitations of this patient. Furthermore, imaging studies cannot determine the intestinal tumor's source or histopathological type. Pathological diagnosis using IHC, in contrast to imaging methods, remains the gold standard for differentiating primary and metastatic lesions of small intestinal malignancies. IHC staining for TTF-1, caudal type homeobox transcription factor 2, CK7 and CK20 helps distinguish a primary small bowel tumor from lung cancer metastasis (23,24). Primary lung carcinomas usually exhibit a CK7⁺/CK20⁻ immunophenotype, as opposed to the common CK7⁺/CK20⁺ pattern of intestinal adenocarcinomas (23). However, primary small bowel adenocarcinomas may also be CK7⁺/CK20⁻ (6). Therefore, TTF-1 and Napsin A positivity is critical in establishing a primary lung cancer

origin. TTF-1 is highly specific for lung adenocarcinomas, exhibiting a positive predictive value of >90% (23,25).

Based on the histological characteristics, an effective treatment plan for patients may be formulated. Liu *et al* (26) reported that postoperative adjuvant chemotherapy, radiotherapy, immunotherapy, targeted therapy or various combination therapies improved the survival rate of patients with intestinal metastasis of lung cancer presenting with GI obstruction, perforation or other acute abdominal issues. In addition, Nitipir *et al* (27) reported a case of GI metastasis in a patient with lung carcinoma with poor physical fitness who received chemotherapy, and the disease was controlled for 22 weeks. AlSaeed *et al* (28) reported a case of GI metastasis in patients with lung carcinoma who received radiotherapy, and the symptoms were relieved. Furthermore, Letaief-Ksontini *et al* (29) reported that the prognosis was prolonged in the case of GI metastasis of patients with lung carcinoma who underwent surgery and postoperative adjuvant chemotherapy. In addition, clinical studies indicated that PD-1/PD-L1 inhibitors successfully progressed in treating advanced NSCLC (30-32). The PD-1 inhibitor camrelizumab (SHR-1210) (33) is a novel and popular anti-tumor immunotherapy. Camrelizumab combination chemotherapy with pemetrexed and carboplatin is the first-line treatment for advanced non-squamous NSCLC without genetic mutations (34). Improvement of overall survival was reported in patients with NSCLC regardless of PD-L1 expression; however, patients with high levels of PD-L1 benefited the most (35). Although the outcome of the patient of the present study was poor, it does not discredit the efficacy and safety of immunotherapy combined with chemotherapy (35). Based on the latest National Comprehensive Cancer Network guidelines, the combination of pembrolizumab, pemetrexed and carboplatin may be given as a first-line treatment for patients with advanced or metastatic disease (36). This supports the viability of combined immunotherapy and chemotherapy. Clinical studies have demonstrated that camrelizumab combined with pemetrexed and carboplatin has long-term survival benefits and controllable toxicity (34,37). Depending on the type of lung carcinoma, metastases in multiple sites, heavy tumor load and postoperative complications may result in poor prognosis. GI cancers with perforation, obstruction or hemorrhage have been associated with less favorable outcomes. Effective treatment may increase the duration of patient survival; however, the prognosis significantly depends

on the predominant symptoms at the initial presentation and the subsequent massive bleeding 2 months after the diagnosis of small intestinal metastasis. The patient of the present study was intolerant to treatment and ultimately died the day after the obstruction was discovered. If this patient had been able to receive timely and effective treatment, his survival may have been prolonged. Furthermore, early detection and therapeutic intervention may have improved survival (24).

In conclusion, the occurrence of small intestinal metastasis from lung cancer is rare and may be life-threatening. Therefore, GI metastases should be considered when patients with a history of primary lung cancer have abdominal symptoms. When a patient is diagnosed with lung cancer, abdominal CT or MRI should be performed regularly, regardless of whether the cancer is in its early or late stage. If conditions permit, a PET-CT examination may be performed. Furthermore, when abnormalities occur, a pathological diagnosis should be performed immediately to determine the nature and source of the tumor, and patients with lung cancer with small intestinal metastasis should be thoroughly evaluated. Those who meet the indications of surgery should undergo surgery immediately, while for those who cannot tolerate surgery, their physical condition should be strictly assessed and individualized treatment should be administered in strict accordance with oncology guidelines to effectively prevent complications, improve quality of life and prolong overall survival.

Acknowledgements

Not applicable.

Funding

No funding was received.

Availability of data and materials

The datasets used and/or analyzed during the current study are available from the corresponding author on reasonable request.

Authors' contributions

TZL, YG, ZCW, JL, XTP and YH contributed to the study conception and design. Material preparation, and data collection and analysis were performed by ZCW, JL, XTP and YH. The original draft of the manuscript was written by TZL and YG. And all authors commented on previous versions of the manuscript. TZL, YG and YH confirm the authenticity of all the raw data. All authors have read and agreed to the published version of the manuscript.

Ethics approval and consent to participate

Not applicable.

Patient consent for publication

Written informed consent has been obtained from family members of the patient to publish this case report with the accompanying images.

Competing interests

The authors declare that they have no competing interests.

References

- Balata H, Fong KM, Hendriks LE, Lam S, Ostroff JS, Peled N, Wu N and Aggarwal C: Prevention and early detection for NSCLC: Advances in thoracic oncology 2018. *J Thorac Oncol* 14: 1513-1527, 2019.
- Xia C, Dong X, Li H, Cao M, Sun D, He S, Yang F, Yan X, Zhang S, Li N and Chen W: Cancer statistics in China and United States, 2022: profiles, trends, and determinants. *Chin Med J (Engl)* 135: 584-590, 2022.
- Siegel RL, Miller KD, Fuchs HE and Jemal A: Cancer statistics, 2022. *CA Cancer J Clin* 72: 7-33, 2022.
- Niu FY, Zhou Q, Yang JJ, Zhong WZ, Chen ZH, Deng W, He YY, Chen HJ, Zeng Z, Ke EE, *et al*: Distribution and prognosis of uncommon metastases from non-small cell lung cancer. *BMC Cancer* 16: 149, 2016.
- Hu Y, Feit N, Huang Y, Xu W, Zheng S and Li X: Gastrointestinal metastasis of primary lung cancer: An analysis of 366 cases. *Oncol Lett* 15: 9766-9776, 2018.
- Yoshimoto A, Kasahara K and Kawashima A: Gastrointestinal metastases from primary lung cancer. *Eur J Cancer* 42: 3157-3160, 2006.
- Goldstraw P, Chansky K, Crowley J, Rami-Porta R, Asamura H, Eberhardt WE, Nicholson AG, Groome P, Mitchell A, Bolejack V, *et al*: The IASLC lung cancer staging project: Proposals for revision of the TNM stage groupings in the forthcoming (Eighth) edition of the TNM classification for lung cancer. *J Thorac Oncol* 11: 39-51, 2016.
- Neeman E, Gresham G, Ovasapians N, Hendifar A, Tuli R, Figlin R and Shinde A: Comparing physician and nurse eastern cooperative oncology group performance status (ECOG-PS) ratings as predictors of clinical outcomes in patients with cancer. *Oncologist* 24: e1460-e1466, 2019.
- Herbst RS, Morgensztern D and Boshoff C: The biology and management of non-small cell lung cancer. *Nature* 553: 446-454, 2018.
- Barta JA, Powell CA and Wisnivesky JP: Global epidemiology of lung cancer. *Ann Glob Health* 85: 8, 2019.
- Hoffman PC, Mauer AM and Vokes EE: Lung cancer. *Lancet* 355: 479-485, 2000.
- McNeill PM, Wagman LD and Neifeld JP: Small bowel metastases from primary carcinoma of the lung. *Cancer* 59: 1486-1489, 1987.
- Hung TI, Chu KE, Chou YH and Yang KC: Gastric metastasis of lung cancer mimicking an adrenal tumor. *Case Rep Gastroenterol* 8: 77-81, 2014.
- Jevremovic V: Is gastrointestinal metastasis of primary lung malignancy as rare as reported in the literature? A comparison between clinical cases and post-mortem studies. *Stud Oncol Hematol Rev* 12: 51-57, 2016.
- Yamada H, Akahane T, Horiuchi A, Shimada R, Shibuya H, Hayama T, Nozawa K, Ishihara S, Matsuda K and Watanabe T: A case of lung squamous cell carcinoma with metastases to the duodenum and small intestine. *Int Surg* 96: 176-181, 2011.
- Janež J: Acute intestinal obstruction due to metastatic lung cancer-case report. *J Surg Case Rep* 2017: rjx031, 2017.
- Di JZ, Peng JY and Wang ZG: Prevalence, clinicopathological characteristics, treatment, and prognosis of intestinal metastasis of primary lung cancer: A comprehensive review. *Surg Oncol* 23: 72-80, 2014.
- Yang CJ, Hwang JJ, Kang WY, Chong IW, Wang TH, Sheu CC, Tsai JR and Huang MS: Gastro-intestinal metastasis of primary lung carcinoma: Clinical presentations and outcome. *Lung Cancer* 54: 319-323, 2006.
- Xue C, Hu Z, Jiang W, Zhao Y, Xu F, Huang Y, Zhao H, Wu J, Zhang Y, Zhao L, *et al*: National survey of the medical treatment status for non-small cell lung cancer (NSCLC) in China. *Lung Cancer* 77: 371-375, 2012.
- Kim SY, Ha HK, Park SW, Kang J, Kim KW, Lee SS, Park SH and Kim AY: Gastrointestinal metastasis from primary lung cancer: CT findings and clinicopathologic features. *AJR Am J Roentgenol* 193: W197-W201, 2009.

21. Lardinois D, Weder W, Roudas M, von Schulthess GK, Tutic M, Moch H, Stahel RA and Steinert HC: Etiology of solitary extrapulmonary positron emission tomography and computed tomography findings in patients with lung cancer. *J Clin Oncol* 23: 6846-6853, 2005.
22. Stinchcombe TE, Socinski MA, Gangarosa LM and Khandani AH: Lung cancer presenting with a solitary colon metastasis detected on positron emission tomography scan. *J Clin Oncol* 24: 4939-4940, 2006.
23. Rossi G, Marchioni A, Romagnani E, Bertolini F, Longo L, Cavazza A and Barbieri F: Primary lung cancer presenting with gastrointestinal tract involvement: Clinicopathologic and immunohistochemical features in a series of 18 consecutive cases. *J Thorac Oncol* 2: 115-120, 2007.
24. Sakai H, Egi H, Hinoi T, Tokunaga M, Kawaguchi Y, Shinomura M, Adachi T, Arihiro K and Ohda H: Primary lung cancer presenting with metastasis to the colon: A case report. *World J Surg Oncol* 10: 1-5, 2012.
25. Goh BK, Yeo AW, Koong HN, Ooi LL and Wong WK: Laparotomy for acute complications of gastrointestinal metastases from lung cancer: Is it a worthwhile or futile effort? *Surg Today* 37: 370-374, 2007.
26. Liu W, Zhou W, Qi WL, Ma YD and Xu YY: Gastrointestinal hemorrhage due to ileal metastasis from primary lung cancer. *World J Gastroenterol* 21: 3435-3440, 2015.
27. Nitipir C, Ginghina O, Popa L, Andrei F, Tudor N, Radu I, Iaciu C, Orlov C, Vasilescu F, Balalau C, *et al*: A rare case of advanced lung cancer presenting as a symptomatic gastric tumor. *Mol Clin Oncol* 8: 595-599, 2018.
28. AlSaeed EF, Tunio MA, AlSayari K, AlDandan S and Riaz K: Duodenal metastasis from lung adenocarcinoma: A rare cause of melena. *Int J Surg Case Rep* 13: 91-94, 2015.
29. Letaief-Ksontini F, Boujnah R, Yahiaoui Y, Zaimi Y, Ksentini M, Aloui R, Meddeb K and Mezlini A: An acute jejunojejunal intussusception revealing a metastatic combined lung cancer. *Case Rep Surg* 2021: 9999605, 2021.
30. Rittmeyer A, Barlesi F, Waterkamp D, Park K, Ciardiello F, von Pawel J, Gadgeel SM, Hida T, Kowalski DM, Dols MC, *et al*: Atezolizumab versus docetaxel in patients with previously treated non-small-cell lung cancer (OAK): A phase 3, open-label, multicentre randomised controlled trial. *Lancet* 389: 255-265, 2017.
31. Vokes EE, Ready N, Felip E, Horn L, Burgio MA, Antonia SJ, Aren Frontera O, Gettinger S, Holgado E, Spigel D, *et al*: Nivolumab versus docetaxel in previously treated advanced non-small-cell lung cancer (CheckMate 017 and CheckMate 057): 3-year update and outcomes in patients with liver metastases. *Ann Oncol* 29: 959-965, 2018.
32. Socinski MA, Jotte RM, Cappuzzo F, Orlandi F, Stroyakovskiy D, Nogami N, Rodriguez-Abreu D, Moro-Sibilot D, Thomas CA, Barlesi F, *et al*: Atezolizumab for First-Line Treatment of Metastatic Nonsquamous NSCLC. *N Engl J Med* 378: 2288-2301, 2018.
33. Mo H, Huang J, Xu J, Chen X, Wu D, Qu D, Wang X, Lan B, Wang X, Xu J, *et al*: Safety, anti-tumour activity, and pharmacokinetics of fixed-dose SHR-1210, an anti-PD-1 antibody in advanced solid tumours: A dose-escalation, phase 1 study. *Br J Cancer* 119: 538-545, 2018.
34. Zhou C, Chen G, Huang Y, Zhou J, Lin L, Feng J, Wang Z, Shu Y, Shi J, Hu Y, *et al*: Camrelizumab plus carboplatin and pemetrexed versus chemotherapy alone in chemotherapy-naive patients with advanced non-squamous non-small-cell lung cancer (Camel): A randomised, open-label, multicentre, phase 3 trial. *Lancet Respir Med* 9: 305-314, 2021.
35. Hou X, Zhou C, Wu G, Lin W, Xie Z, Zhang H, Yi J, Peng Z, Yin L, Ma C and Chen L: Efficacy, safety, and health-related quality of life with camrelizumab plus pemetrexed and carboplatin as first-line treatment for advanced nonsquamous NSCLC with brain metastases (CAP-BRAIN): A multicenter, open-label, single-arm, phase 2 study. *J Thorac Oncol* 2: S1556-S0864(23)00092-8, 2023.
36. Ettinger DS, Wood DE, Aisner DL, Akerley W, Bauman JR, Bharat A, Bruno DS, Chang JY, Chirieac LR, D'Amico TA, *et al*: Non-small cell lung cancer, version 3.2022, NCCN clinical practice guidelines in oncology. *J Natl Compr Canc Netw* 20: 497-530, 2022.
37. Zhou C, Chen G, Huang Y, Zhou J, Lin L, Feng J, Wang Z, Shu Y, Shi J, Hu Y, *et al*: Camrelizumab plus carboplatin and pemetrexed as first-line treatment for advanced nonsquamous NSCLC: Extended follow-up of camel phase 3 trial. *J Thorac Oncol* 13: S1556-S0864(22)01993-1, 2023.



This work is licensed under a Creative Commons Attribution-NonCommercial-NoDerivatives 4.0 International (CC BY-NC-ND 4.0) License.