



CASE REPORT

REVISED Case Report: Rare site for intraoral meningioma
 [version 2; peer review: 2 approved, 1 approved with reservations]

Hatem Wael Amer ¹, Layla Hafed ², Sally Ibrahim³, Shady Shaker¹

¹Faculty of Dentistry, Cairo University, Cairo, Egypt

²Faculty of Dentistry, Ahram Canadian University, Cairo, Egypt

³Faculty of Dentistry, El-Fayoum University, Cairo, Egypt

v2 First published: 07 Feb 2020, 9:95
<https://doi.org/10.12688/f1000research.21999.1>

Latest published: 06 Apr 2020, 9:95
<https://doi.org/10.12688/f1000research.21999.2>

Abstract

Extracranial meningioma is very rare with few cases reported, especially in the oral cavity. Its diagnosis is considered a challenge owing to the unusual site of occurrence. We report, to the best of our knowledge, the first case of extra-cranial meningioma as a primary tumor in the hard palate with no detected intracranial extension. A 59-year-old Egyptian female patient presented with a 22-year history of a large painless swelling at the right side of the hard palate, which could not be seen on radiographs. An incisional biopsy was taken and, after assessment with a panel of immunohistochemical markers, the lesion was diagnosed as extracranial grade I meningothelial meningioma. The patient did not show up for surgical excision and follow-up was not performed because of the loss of contact with the patient. Intraoral meningioma is a rare tumor. Immunohistochemical markers are important for confirming this diagnosis.

Keywords

Intra-oral meningioma, Benign tumor, Ectopic meningioma, Palatal lesion

Open Peer Review

Reviewer Status

	Invited Reviewers		
	1	2	3
version 2 (revision) 06 Apr 2020	 report		 report
version 1 07 Feb 2020	 report	 report	

1. **Eman Abdelzاهر** , Alexandria University, Alexandria, Egypt
2. **Maha M. Abdelsalam**, Imam Abdulrahman Bin Faisal University, Dammam, Saudi Arabia
3. **Hasan Onur Şimşek** , Aydın Adnan Menderes University, Aydın, Turkey

Any reports and responses or comments on the article can be found at the end of the article.

Corresponding author: Layla Hafed (layla.hafed@gmail.com)

Author roles: **Amer HW:** Conceptualization, Investigation, Resources, Writing – Review & Editing; **Hafed L:** Data Curation, Software, Visualization, Writing – Original Draft Preparation; **Ibrahim S:** Data Curation, Resources, Software, Writing – Original Draft Preparation; **Shaker S:** Investigation, Methodology, Validation, Writing – Original Draft Preparation

Competing interests: No competing interests were disclosed.

Grant information: The author(s) declared that no grants were involved in supporting this work.

Copyright: © 2020 Amer HW *et al.* This is an open access article distributed under the terms of the [Creative Commons Attribution License](#), which permits unrestricted use, distribution, and reproduction in any medium, provided the original work is properly cited.

How to cite this article: Amer HW, Hafed L, Ibrahim S and Shaker S. **Case Report: Rare site for intraoral meningioma [version 2; peer review: 2 approved, 1 approved with reservations]** F1000Research 2020, 9:95 <https://doi.org/10.12688/f1000research.21999.2>

First published: 07 Feb 2020, 9:95 <https://doi.org/10.12688/f1000research.21999.1>

REVISED Amendments from Version 1

We have corrected grammar and language mistakes.
 We have added a new reference and changed the numbering of citations and added the data to text.
 We have added some lesions to the differential diagnosis list and discussed them.

Any further responses from the reviewers can be found at the end of the article

Introduction

Meningioma is a benign neoplasm of meningeothelial cells¹. Meningioma may develop as a direct extension of a primary intra-cranial meningioma or as a true primary extra-cranial meningioma².

Extra-cranial (ectopic) tumors are mostly seen in the head and neck region with no connection intra-cranially³. The most common extra-cranial site is the orbits. Meningioma arising in the oral cavity is extremely rare⁴. To the best of our knowledge, 19 cases have currently been reported in the oral cavity^{2,4-20} and we are reporting the first case in the hard palate.

Case report

A 59-year-old female patient presented to the outpatient clinic in the Oral and Maxillofacial Surgery Department, Cairo University in January 2019 complaining of a large painless swelling in the hard palate (Figure 1). The patient reported that the swelling had been present in her oral cavity for 22 years. The patient’s medical and familial histories were unremarkable. As well as there was not a history of exposure to radiation. Upon clinical examination on the day of admission, a large hard palatal swelling (3 cm × 3 cm) was evident on the right side of the hard palate. The swelling was covered by normal mucosa and showed a slight bluish tinge. A provisional diagnosis of a benign peripheral nerve neoplasm and a minor salivary gland benign neoplasm were made. CT scan was performed with no evidence of bone involvement.

An incisional biopsy of the lesion was performed. Hematoxylin and eosin stained sections revealed meningeothelial cells arranged in lobules. The cells exhibited round to oval nuclei (Figure 2). Psammoma bodies were also present (Figure 3). No mitotic activity and no cellular atypia were found. Immunohistochemical staining for tumor-associated markers was performed to confirm the diagnosis of meningioma and to exclude other mimic tumors as metastatic carcinomas, schwannoma, neurofibroma, paraganglioma and perineurioma. Cells were positively stained using primary antibodies for epithelial membrane antigen (EMA) and vimentin (Figure 4a, b), but were not stained when using primary antibodies for S100, pancytokeratin, p63, chromogranin and renal cell carcinoma glycoprotein (Figure 5a–e).

No therapy was administered to the patient during her admission. Unfortunately, the patient did not show up for surgical excision and follow-up.

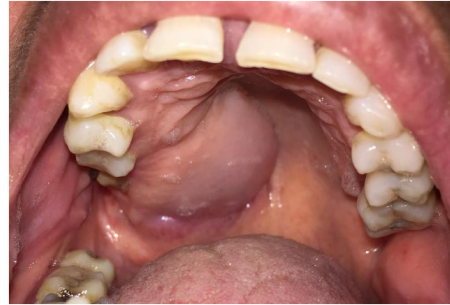

Figure 1. Preoperative clinical picture showing 3 × 3cm swelling in the hard palate.

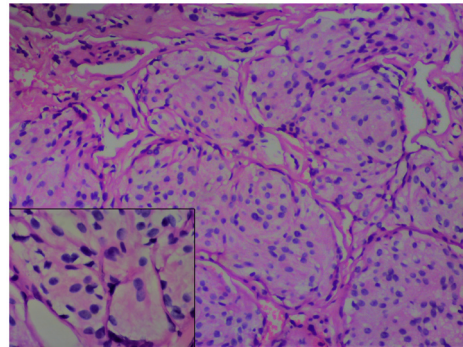


Figure 2. Hematoxylin and eosin-stained sections showing epithelioid cells forming meningeothelial whorls (magnification, ×100). Indistinct cell membranes with uniform nuclei and no mitotic figures (inset; magnification, ×200).

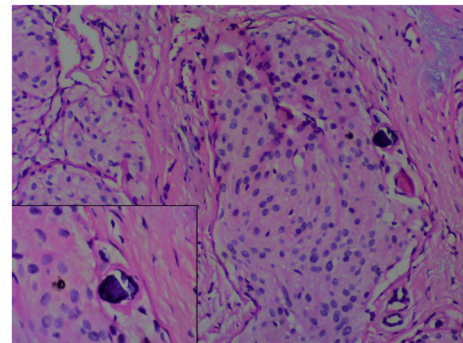


Figure 3. Hematoxylin and eosin-stained sections showing syncytial cells (magnification, ×100). Psammoma bodies seen between meningeothelial cells (inset), (×200).

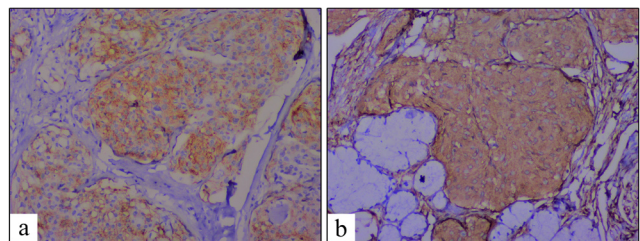


Figure 4. Meningioma tumor cells showing a positive cytoplasmic immunohistochemical reaction for (a) epithelial membrane antigen and (b) Vimentin (magnification, ×200).

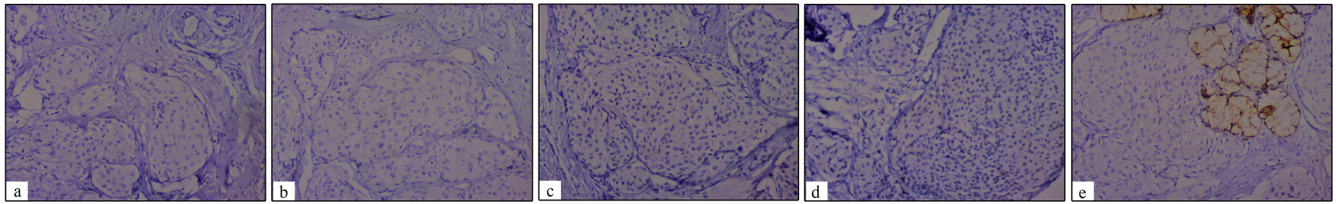


Figure 5. Meningioma tumor cells react negatively following immunohistochemical staining for (a) renal cell carcinoma glycoprotein, (b) S100, (c) chromoginin, (d) p63, (e) PanCK (magnification, $\times 100$).

Table 1. Clinicopathological and radiographic data of the documented cases of extracranial meningioma.

Study	Age, years	Gender	Site	Tumor size	Radiographic findings	Treatment	Follow-up
Brown <i>et al.</i> ⁵	69	M	Maxilla	NA	ML RL	Not completed	8 years
Simpson and Sneddon ⁶	63	F	Maxillary alveolus	4.5 \times 2.7 \times 2.7 cm	Well-defined mixed RL RO	Surgical excision.	Under review
Landini and Kitano ⁷	48	F	Mandible	NA	Well-defined RL	Block resection	2 years
Reddi <i>et al.</i> ²	26	F	Maxilla	3 cm	Ill-defined RL	Surgical excision	2 years
Kishore <i>et al.</i> ⁸	44	F	Soft Palate	3 \times 2 cm	NS	Excisional biopsy	4 years
Pfeifer <i>et al.</i> ⁹	77	F	Maxilla (temporal fossa)	NA	Dense soft tissue mass	Surgical resection	NS
Jones and Freedman ¹⁰	41	F	Mandible	4 \times 2 cm	Well defined RL	Excisional biopsy	NS
Jones and Freedman ¹⁰	74	F	Mandible	4 \times 3 cm	Well-defined RL	Excisional biopsy	NS
Kubotaa <i>et al.</i> ¹¹	10	M	Mandible	NA	Well-defined RL	Enucleated	4 years
Mussak <i>et al.</i> ¹²	62	M	Mandible	7 \times 3 cm	Well-defined RL	Segmental mandibulectomy	NS
Lell <i>et al.</i> ¹³	40	F	Mandible	NA	Well-defined RL	NS	NS
Mosquede-Taylor <i>et al.</i> ¹⁴	53	F	Mandible	4 cm	Ill-defined mixed RO RL	Surgical excision	6 months
Rushing <i>et al.</i> ¹⁵		NA	Mandible	NA			
Simsek and Komerik ⁴	51	F	Maxilla	2 \times 2 cm	Ill-defined mixed RL-RO	Surgical excision	5 years
Pinting <i>et al.</i> ¹⁶	59	M	Maxilla	NA	Well-defined RL	Surgical excision and radiotherapy	NS
Maeng <i>et al.</i> ¹⁷	66	F	Buccal mucosa	2 cm	Heterogenously enhanced mass	Surgical excision	Year and half
Nair <i>et al.</i> ¹⁸	60	F	Buccal mucosa	4 \times 3 cm	Mass of heterogeneous density	Surgical resection	One year
Rege <i>et al.</i> ¹⁹	35	M	Mandible	NA	Ill-defined ML RL	Partial resection	5 years
Rommel <i>et al.</i> ²⁰	20	F	Mandible	2 \times 1.8 cm	Well defined RL	No surgical intervention.	One year

M, male; F, female; RL, radiolucent; RO, radioopaque; UL, unilocular; ML, multilocular; NA, not available; NS, not stated.

Discussion

Primary extra-cranial meningioma is an unusual tumor, especially in the oral cavity⁴. The first intraoral meningioma reported was by Brown *et al.* in 1976, which presented as a periapical radiolucency in the anterior maxillary region⁵.

To the best of our knowledge, 19 cases of primary meningioma in the oral cavity have been reported. Of these, 13 were in female patients, which is also true of the present case. However, the age range was wide in the reported cases – between 10 and 77 years old^{2,4–20}; in the present case, the patient was

59 years old. Regarding the reported cases of intraoral primary meningioma, 6 of the 18 were in the maxilla^{2,4-6,9,16}, 10 were in the mandible^{7,10-15,19,20}, 2 in the buccal mucosa^{17,18} and one in soft palate⁸. To the best of our knowledge, we report the first case in the hard palate.

The histopathological criteria of extracranial meningiomas are similar to those of their intracranial counterparts. All documented cases shared the same characteristics: whorls of spindle cells or epithelioid cell proliferation and psammoma bodies. In our case, diagnosis was challenging because of the tumor's similarity with other tumor entities of peripheral nerve origin, as well as the uncommon location of the tumor. An immunohistochemical panel of tumor-associated markers was used to confirm the diagnosis and to avoid unnecessary aggressive treatment. Most of the 19 cases reported in the literature were diagnosis using immunohistochemical markers. All reported cases that used immunohistochemistry techniques to diagnose meningioma^{4,9-11,13,14,16,17,19,20} observed that the tumor cells stained positive for monoclonal antibodies against EMA and vimentin, with no immunoreactivity for S-100 protein, which was similar to our findings. However, EMA and vimentin are not useful to differentiate between meningioma and perineuroma as they both express positivity for EMA and vimentin but perineuroma the cells are spindle and elongated however, in our case they are rounded and polyhedral (meningiothelial pattern).

Unfortunately, our patient did not show up for surgical excision and follow-up was not done because of the loss of contact with the patient. However, most of the documented cases were treated successfully without recurrence by surgical excision. Some of the studies, such as that by Rommel *et al.*²⁰, preferred only to follow-up with the patient rather than conduct surgical intervention. However, others preferred to perform aggressive treatment, such as as segmental mandibulectomy or segmental resection^{7,12}.

In conclusion, meningioma is a rare intraoral benign neoplasm. Immunohistochemical markers are an important tool to achieve a final diagnosis, especially for the differentiation from histological mimic entities of peripheral nerve origin, such as perineuroma and neurothekeoma and to avoid unnecessary aggressive treatment. Vimentin and EMA are the two important markers to confirm extra-cranial meningioma diagnosis.

Data availability

All data underlying the results are available as part of the article and no additional source data are required.

Consent

Written informed consent for publication of their clinical details and clinical images was obtained from the patient.

References

- El-Naggar AK, Chan JK, Grandis JR, *et al.*: **WHO Classification of Head and Neck Tumours**. 4th edition. Lyon: IARC Press, 2017.
[Reference Source](#)
- Reddi SP, Strauss SI, Strauss JE, *et al.*: **Anterior maxillary lesion**. *J Oral Maxillofac Surg*. 1999; **57**(10): 1234–8.
[PubMed Abstract](#) | [Publisher Full Text](#)
- Agaimy A, Buslei R, Coras R, *et al.*: **Comparative study of soft tissue perineuroma and meningioma using a five-marker immunohistochemical panel**. *Histopathology*. 2014; **65**(1): 60–70.
[PubMed Abstract](#) | [Publisher Full Text](#)
- Simsek H, Komerik N: **Ectopic Meningioma in the Maxillary Alveolar Ridge: Report of a Case with a Review of the Literature**. *IJEDS*. 2012; **1**(2): 98–101.
[Publisher Full Text](#)
- Brown AM, Fordham KC, Lally ET: **Meningioma presenting as an intraoral mass**. *Oral Surg Oral Med Oral Pathol*. 1976; **41**(6): 771–6.
[PubMed Abstract](#) | [Publisher Full Text](#)
- Simpson MT, Sneddon KJ: **Extracranial meningioma of the oral cavity**. *Br J Oral Maxillofac Surg*. 1987; **25**(6): 520–5.
[PubMed Abstract](#) | [Publisher Full Text](#)
- Landini G, Kitano M: **Meningioma of the mandible**. *Cancer*. 1992; **69**(12): 2917–20.
[PubMed Abstract](#) | [Publisher Full Text](#)
- Kishore A, Roy D, Irvine BW: **Primary extracranial meningioma of the soft palate**. *J Laryngol Otol*. 2000; **114**(2): 149–50.
[PubMed Abstract](#) | [Publisher Full Text](#)
- Pfeifer JD, Ashley Hill D, Ramos CV, *et al.*: **Meningioma Presenting as an Intraoral Mass in a Patient With Neurofibromatosis Type 1**. *Arch Pathol Lab Med*. 2000; **124**(6): 898–901.
[PubMed Abstract](#)
- Jones AC, Freedman PD: **Primary extracranial meningioma of the mandible: A report of 2 cases and a review of the literature**. *Oral Surg Oral Med Oral Pathol Oral Radiol Endod*. 2001; **91**(3): 338–41.
[PubMed Abstract](#) | [Publisher Full Text](#)
- Kubota Y, Yamashiro T, Kobayashi I, *et al.*: **Primary meningioma of the mandible**. *Oral Onco Extra*. 2005; **41**(2): 18–21.
[Publisher Full Text](#)
- Mussak EN, Holodny AI, Karimi SK, *et al.*: **Meningioma of the mandible: imaging with CT**. *AJNR Am J Neuroradiol*. 2007; **28**(6): 1157–9.
[PubMed Abstract](#) | [Publisher Full Text](#)
- Lell M, Tudor C, Aigner T, *et al.*: **Primary intraosseous meningioma of the mandible: CT and MR imaging features**. *AJNR Am J Neuroradiol*. 2007; **28**(1): 129–31.
[PubMed Abstract](#)
- Mosqueda-Taylor A, Domínguez-Malagon H, Cano-Valdez AM, *et al.*: **Primary extracranial meningioma of the mandible**. *Med Oral Patol Oral Cir Bucal*. 2009; **14**(4): E167–70.
[PubMed Abstract](#)
- Rushing EJ, Bouffard JP, McCall S, *et al.*: **Primary extracranial meningiomas: an analysis of 146 cases**. *Head Neck Pathol*. 2009; **3**(2): 116–30.
[PubMed Abstract](#) | [Publisher Full Text](#) | [Free Full Text](#)
- Pinting L, Xiaofeng H, Zhiyong W, *et al.*: **Extracranial meningioma in the maxillary region**. *J Craniofac Surg*. 2013; **24**(2): e142–4.
[PubMed Abstract](#) | [Publisher Full Text](#)
- Maeng JW, Kim Y, Seo J, *et al.*: **Primary Extracranial Meningioma Presenting as a Cheek Mass**. *Clin Exp Otorhinolaryngol*. 2013; **6**(4): 266–268.
[PubMed Abstract](#) | [Publisher Full Text](#) | [Free Full Text](#)
- Ravindran Nair KS, Suresh Babu P, Manoj S, *et al.*: **The meningioma that got cheeky**. *J Maxillofac Oral Surg*. 2016; **15**(Suppl 2): 279–281.
[PubMed Abstract](#) | [Publisher Full Text](#) | [Free Full Text](#)
- Rege IC, Garcia RR, Mendonça EF: **Primary Extracranial Meningioma: A Rare Location**. *Head Neck Pathol*. 2017; **11**(4): 561–6.
[PubMed Abstract](#) | [Publisher Full Text](#) | [Free Full Text](#)
- Rommel N, Bissinger O, Rau A, *et al.*: **Ectopic meningioma of the mandible in a 20-year-old woman: a case report and literature review**. *J Surg Case Rep*. 2017; **2017**(3): rjx047.
[PubMed Abstract](#) | [Publisher Full Text](#) | [Free Full Text](#)

Open Peer Review

Current Peer Review Status:   

Version 2

Reviewer Report 18 August 2020

<https://doi.org/10.5256/f1000research.25478.r68269>

© 2020 Şimşek H. This is an open access peer review report distributed under the terms of the [Creative Commons Attribution License](#), which permits unrestricted use, distribution, and reproduction in any medium, provided the original work is properly cited.



Hasan Onur Şimşek 

Department of Oral and Maxillofacial Surgery, Faculty of Dentistry, Aydın Adnan Menderes University, Aydın, Turkey

- Ectopic Meningiomas are seen less frequently in oral regions, so it can be considered as a case report. However, the lack of follow-up of the case reduces the power of the article.
- Clinical data and radiographic findings can be given in more detail.
- Differential diagnoses should be discussed in the discussion section.

Is the background of the case's history and progression described in sufficient detail?

Yes

Are enough details provided of any physical examination and diagnostic tests, treatment given and outcomes?

Partly

Is sufficient discussion included of the importance of the findings and their relevance to future understanding of disease processes, diagnosis or treatment?

Partly

Is the case presented with sufficient detail to be useful for other practitioners?

Yes

Competing Interests: No competing interests were disclosed.

Reviewer Expertise: maxillofacial surgery

I confirm that I have read this submission and believe that I have an appropriate level of expertise to confirm that it is of an acceptable scientific standard.

Reviewer Report 06 April 2020

<https://doi.org/10.5256/f1000research.25478.r62034>

© 2020 Abdelzaher E. This is an open access peer review report distributed under the terms of the [Creative Commons Attribution License](#), which permits unrestricted use, distribution, and reproduction in any medium, provided the original work is properly cited.



Eman Abdelzaher 

Department of Pathology, Faculty of Medicine, Alexandria University, Alexandria, Egypt

The requested changes were made.

Is the background of the case's history and progression described in sufficient detail?

Yes

Are enough details provided of any physical examination and diagnostic tests, treatment given and outcomes?

Yes

Is sufficient discussion included of the importance of the findings and their relevance to future understanding of disease processes, diagnosis or treatment?

Yes

Is the case presented with sufficient detail to be useful for other practitioners?

Yes

Competing Interests: No competing interests were disclosed.

Reviewer Expertise: Neuropathology

I confirm that I have read this submission and believe that I have an appropriate level of expertise to confirm that it is of an acceptable scientific standard.

Version 1

Reviewer Report 02 March 2020

<https://doi.org/10.5256/f1000research.24261.r59735>

© 2020 Abdelsalam M. This is an open access peer review report distributed under the terms of the [Creative Commons Attribution License](#), which permits unrestricted use, distribution, and reproduction in any medium, provided the original work is properly cited.



Maha M. Abdelsalam

Department of Biomedical Dental Sciences, College of Dentistry, Imam Abdulrahman Bin Faisal University, Dammam, Saudi Arabia

Case Report: Case Report: Rare site for intraoral meningioma

The case report presents an extracranial meningioma of the hard palate. The patient's gender is conformed to the tumor but there are (likely) no contributing or risk factors associated with its occurrence. The lesion is asymptomatic and incisional biopsy was examined routinely and certain microscopic features were suggestive of meningioma. The specimen was further stained with a panel of markers and was diagnosed as meningioma of the palate. Unfortunately the patient did not return for surgical removal.

- **Is the background of the case's history and progression described in sufficient detail?**

The patient's background can be improved if relevant findings are reported such as previous exposure to radiation as a potential risk for development of meningioma.

- **Are enough details provided of any physical examination and diagnostic tests, treatment given and outcomes?**

This is one of the unfortunate incidents where patient is not committed to treatment.

1. Although it seems that the patient is asymptomatic except for the size of the palatal swelling, absence of radiograph (even if non-indicative) and not mention neurofibromatosis-type2, undermine the reader's understanding of the case.

2. The clinical picture is good and clear.

- **Is sufficient discussion included of the importance of the findings and their relevance to future understanding of disease processes, diagnosis or treatment?**

1. Discussion is fine although it would've been beneficial to cite the other reported palatal lesions by Kishore A (2000) and Sinha (2002), for example.^{1,2}
2. The immunohistochemistry test panel discussion would be more useful for the non-pathology reader if there were brief comment on the value of such tests of uncommon oral lesions with perplexing presentations.
3. Consequently, a short list of lesions to be included in a general dentist's record when similar cases are detected, would be useful.
4. Few editing or English language corrections would help. For example "follow-up was not done because of loose of contact" in which "loss not loose" is meant. The statement is repeated in abstract and discussion and significantly alters the meaning of the sentence.

- **Is the case presented with sufficient detail to be useful for other practitioners?**

Extracranial meningioma are rare and intraoral lesions are even rarer. It is of high pathological interest of both specialist and general practitioner to get updated on occurrence, presentation and diagnostic methods of such tumors.

1. The case and the tumor presented are useful, relevant and with corrections, the report would be more impactful.
2. Conclusions must be more powerful and instructive for the practitioner to:

1. Expect the unexpected when similar lesions are encountered.
2. Suggest an effective strategy to ensure patient's return when the outcomes are suspicious.

References

1. Kishore A, Roy D, Irvine BW: Primary extracranial meningioma of the soft palate. *J Laryngol Otol.* 2000; **114** (2): 149-50 [PubMed Abstract](#) | [Publisher Full Text](#)
2. Sinha R, Paul R, Sen I, Sikdar B: A solitary huge neurofibroma of the soft palate. *J Laryngol Otol.* 2002; **116** (8): 637-8 [PubMed Abstract](#) | [Publisher Full Text](#)

Is the background of the case's history and progression described in sufficient detail?

Partly

Are enough details provided of any physical examination and diagnostic tests, treatment given and outcomes?

Partly

Is sufficient discussion included of the importance of the findings and their relevance to future understanding of disease processes, diagnosis or treatment?

Partly

Is the case presented with sufficient detail to be useful for other practitioners?

Partly

Competing Interests: No competing interests were disclosed.

Reviewer Expertise: Oral Pathology, Oral medicine, medical and Dental Education

I confirm that I have read this submission and believe that I have an appropriate level of expertise to confirm that it is of an acceptable scientific standard, however I have significant reservations, as outlined above.

Author Response 26 Mar 2020

Layla Hafed, Ahram Canadian University, Cairo, Egypt

Firstly, thank you doctor for your valuable comments. We added that data and answers that you commented to the new version of the manuscript. And I will answer them too here as a respond to your report.

1- There was no previous exposure to radiation as a potential risk for development of meningioma. This is one of the unfortunate incidents where patient is not committed to treatment.

2- CT scan was done and there was no bone involvement and neurofibromatosis-type 2 was

excluded because the lesion is single and been present in her oral cavity for 22 year.
3- Discussion is fine although it would've been beneficial to cite the other reported palatal lesions.
4- The immunohistochemistry test panel discussion was added
5- Benign salivary gland neoplasm add to the list of lesions to be included in a general dentist's record when similar cases are detected.
6- English language corrections were done.
7- Conclusions were also corrected to include the consequence of wrong diagnosed.

Thanks again for your comments which add a lot to our knowledge and for your time too

Competing Interests: No competing interests

Reviewer Report 25 February 2020

<https://doi.org/10.5256/f1000research.24261.r59777>

© 2020 Abdelzاهر E. This is an open access peer review report distributed under the terms of the [Creative Commons Attribution License](#), which permits unrestricted use, distribution, and reproduction in any medium, provided the original work is properly cited.



Eman Abdelzاهر

Department of Pathology, Faculty of Medicine, Alexandria University, Alexandria, Egypt

The case report is well written and presents an interesting case of ectopic meningioma. Some amendment is needed however.

1. Radiological findings should be included. The authors merely mention that the lesion was not seen by radiology. Please clarify the technique used and relevant findings.
2. The grade of meningioma was not given
3. The differential diagnosis of meningioma from mimics was not sufficiently addressed. Different entities in the differential diagnosis were mentioned at different parts of the article without discussing the differentiating points. And the performed stains would not help in differentiating meningioma from perineurioma, both are positive for EMA and vimentin.
4. Grammatical and spelling mistakes are noted [here](#).

Is the background of the case's history and progression described in sufficient detail?

Yes

Are enough details provided of any physical examination and diagnostic tests, treatment given and outcomes?

Partly

Is sufficient discussion included of the importance of the findings and their relevance to future understanding of disease processes, diagnosis or treatment?

Partly

Is the case presented with sufficient detail to be useful for other practitioners?

Partly

Competing Interests: No competing interests were disclosed.

Reviewer Expertise: Neuropathology.

I confirm that I have read this submission and believe that I have an appropriate level of expertise to confirm that it is of an acceptable scientific standard, however I have significant reservations, as outlined above.

Author Response 26 Mar 2020

Layla Hafed, Ahram Canadian University, Cairo, Egypt

Thank you Dr. Eman for your valuable comments and for your time. We added that data and answers that you commented to the new version of the manuscript. And I will answer them here too as a respond to your report.

- 1- All the English language corrections were done.
- 2- CT scan was done and there was no bone involvement.
- 3- Meningioma grade I.
- 4- The list of differential diagnosis was done and discussed.

Competing Interests: No competing interests were disclose

The benefits of publishing with F1000Research:

- Your article is published within days, with no editorial bias
- You can publish traditional articles, null/negative results, case reports, data notes and more
- The peer review process is transparent and collaborative
- Your article is indexed in PubMed after passing peer review
- Dedicated customer support at every stage

For pre-submission enquiries, contact research@f1000.com

F1000Research