

Contents lists available at [ScienceDirect](http://www.sciencedirect.com)

International Journal of Surgery Case Reports

journal homepage: www.casereports.com

Preoperative diagnosis of an asymptomatic cancer restricted to the cystic duct



Shuji Komori*, Juji Tsuchiya, Iwao Kumazawa, Hajime Kawagoe, Kimitoshi Nishio, Yuki Misao

Department of Surgery, Ibi Welfare Hospital, Gifu, Japan

ARTICLE INFO

Article history:

Received 20 February 2014

Received in revised form 13 April 2014

Accepted 21 April 2014

Available online 30 April 2014

Keywords:

Cystic duct cancer

Preoperative diagnosis

Curative surgery

ABSTRACT

INTRODUCTION: Even now, cystic duct cancer (CDC) as defined by Farrar is rare and has a better prognosis than gallbladder cancer, although CDC as defined by Ozden et al., the definition of which could apply to early and advanced cases of CDC, is not rare and has a poorer prognosis than the CDC defined by Farrar.

PRESENTATION OF CASE: A 78-year-old woman with no complaints was found to have a tumor restricted to the cystic duct. Three cytology examinations of the patient's bile could not establish that the tumor was an adenocarcinoma. However, adenocarcinoma was suspected due to the hypervascularity shown on contrast-enhanced computed tomography. Cholecystectomy and extrahepatic bile duct resection with D2 lymph node dissection was performed. The pathological study revealed it to be CDC. Her postoperative course has been uneventful and without recurrence for 21 months.

DISCUSSION: At their first medical examination, many CDC patients are found to have such advanced spread of the cancer to adjacent organs that an extended operation might be necessary. As in our case, better patient outcome results when no lymph node or remote metastasis is present.

CONCLUSION: Diagnosing CDC as early as possible contributes to curative resections and favorable patient outcomes and also allows surgeons to recommend a mini-invasive procedure to their patients rather than extended resection including that of adjacent organs.

© 2014 The Authors. Published by Elsevier Ltd. on behalf of Surgical Associates Ltd. This is an open access article under the CC BY-NC-ND license (<http://creativecommons.org/licenses/by-nc-nd/3.0/>).

1. Introduction

Classic carcinoma originating from the cystic duct, i.e., cystic duct cancer (CDC) was defined by Farrar as (a) growth restricted to the cystic duct; (b) absence of neoplasia in the gallbladder, hepatic ducts, or common bile duct; and (c) histological confirmation of carcinoma cells in the mass.¹ Classic CDC is a rare tumor that has been identified in only 2.6% of all bile duct and 1.5% of all gallbladder cancers.^{2–5} Recently, some authors reported that the compared with the new classification of CDC, CDC defined by the classic definition of 60 years ago is outdated, and many CDCs are detected only when they are at a far advanced stage.^{6–8} However, patients with the classically defined CDC have good outcomes after surgery and lower rates of regional lymph node metastasis than do gallbladder cancer patients.⁹ Therefore, diagnosis of and therapy based on the status of classic CDC are very important.

We report a case of asymptomatic CDC that was suspected preoperatively, and we discuss the available diagnostic and

therapeutic strategies for surgical treatment from our experience with the present case and with reference to previously reported cases.

2. Presentation of case

A 78-year-old Japanese woman underwent a medical examination for symptom-free mild liver dysfunction. The patient had hypertension and a past history of cerebral infarction. Enhanced computed tomography (CT) and ultrasonography both showed a hypervascular tumor of 10 mm in diameter in the cystic duct (Figs. 1 and 2); therefore, additional detailed studies were undertaken. Laboratory blood tests were normal except for slight hyperglycemia and a high value of carbohydrate antigen 19-9 (CA19-9) of 99.3 U/ml (normal range: <37 U/ml). A cytological examination was performed with endoscopic retrograde cholangiopancreatography (ERCP) rather than magnetic resonance cholangiopancreatography (MRCP) because CT showed the tumor to be in the cystic duct. The ERCP revealed an obstruction of the cystic duct and no pancreaticobiliary maljunction (Fig. 3). Three cytological examinations of bile taken from the endoscopic nasobiliary drainage tube did not reveal any cancer cells. However, the tumor was suspected to be malignant due to the hypervascularity shown by CT. No regional lymph node swelling, metastasis or direct

* Corresponding author at: Department of Surgery, Ibi Welfare Hospital, 2547-4 Miwa, Ibigawa, Ibi, Gifu 501-0696, Japan. Tel.: +81 585 21 1111; fax: +81 585 21 1112.

E-mail address: b-joel55shuji-k@violin.ocn.ne.jp (S. Komori).

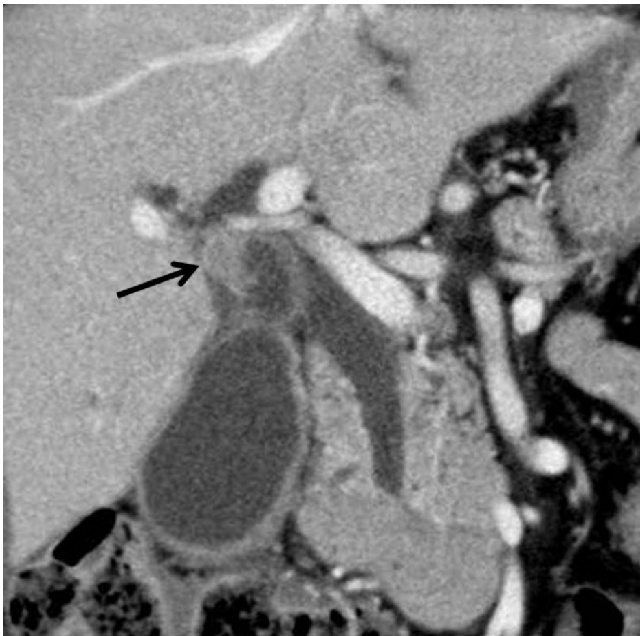


Fig. 1. Enhanced computed tomography showed a hypervascular tumor, 10 mm in diameter, in the cystic duct.

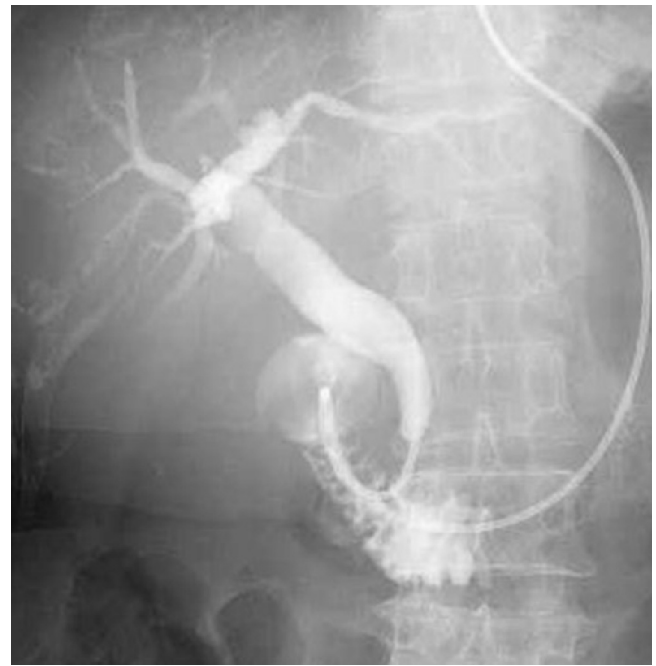

Fig. 3. Endoscopic retrograde cholangiopancreatography showed an obstruction of the cystic duct.

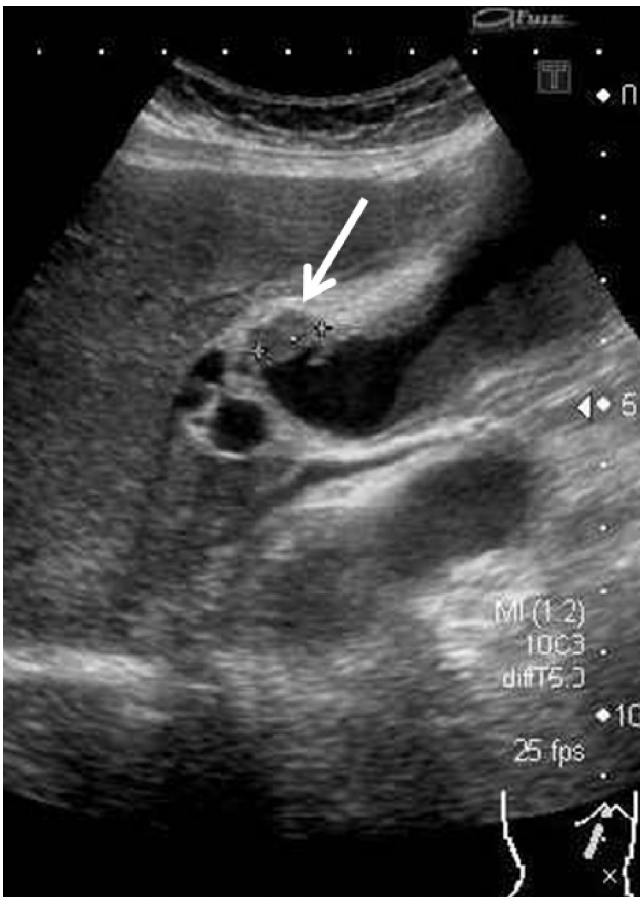

Fig. 2. Ultrasonography also showed a tumor of 10 mm in diameter in the cystic duct.

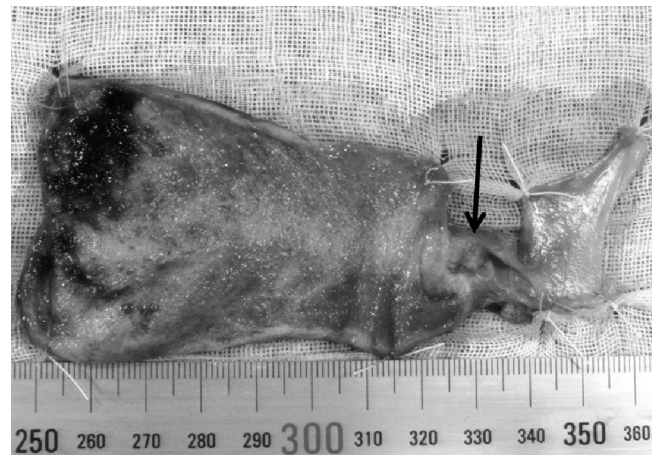

Fig. 4. The surgically resected specimen comprised a 6.0 mm × 5.0-mm nodular infiltrating tumor (arrow) surrounded by a shallow ulcer, 11 mm × 10 mm in diameter, restricted to the cystic duct.

invasion to adjacent organs was detected on chest and abdominal CT scans. We then performed cholecystectomy, extrahepatic bile duct resection and regional lymph node dissection (D2) followed by hepaticojejunostomy.

The surgically resected specimen showed a 6.0 mm × 5.0-mm nodular infiltrating tumor surrounded by shallow ulcer, 11 mm × 10 mm in diameter, that was restricted to the cystic duct (Fig. 4). The pathological study demonstrated the presence of moderately differentiated tubular adenocarcinoma and classified according to the Classification of Biliary Tract Carcinoma of the Japanese Society of Biliary Surgery (2nd English edition) (pStage: II; invasion level: subserosa; lymphatic duct invasion: not detected; vessel invasion: not detected; pHinf0, pBinf0, pPVO, pAO, pBMO, pHMO, pEMO) (Fig. 5). Regional lymph node, liver and distant metastasis and peritoneal dissemination were not noted (pN0, H0, MO, P0). The patient is currently in good health without recurrence at 21 months after surgery.

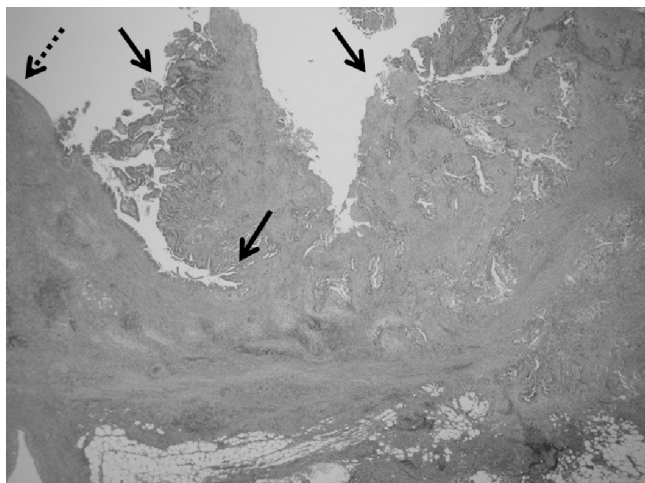


Fig. 5. The pathological study revealed the presence of a moderately differentiated tubular adenocarcinoma (arrows). The dotted arrow indicates the gallbladder wall, which contained no malignant cells. (H and E staining, 40 \times).

3. Discussion

Classic primary CDC was defined in 1951 by Farrar,¹ but that definition excluded advanced CDC, which invades the gallbladder or common bile duct.^{6–8} Accordingly, Sasaki et al.,⁵ Yokoyama et al.⁶ and Nakata et al.⁷ provided new classifications and clinical and pathological features of CDC, and the CDC based on this new classification is not rare, comprising 22–24% of all gallbladder cancers. However, even now the CDC fulfilling Farrar's criteria is known to be rare and to have a better prognosis compared with that in locations in the other biliary ducts and the gallbladder.^{5,9,10} One reason for this favorable outcome is that the rate of lymph node metastasis with subserosal-invading CDC (6.7%) is less than that with gallbladder cancer (39–46%) and upper and middle-lower biliary duct cancer (38–39%).^{9,11–13} To date, however, there remains no good reason why CDC not invading the subserosa results in less lymph node metastasis. We would hypothesize one possible reason for the problem as follows: the major feeding artery and drainage vein for the gallbladder are the cystic artery and vein, respectively, and those for the common bile duct are the hepatic artery and portal vein, respectively. Namely, the gallbladder and the common bile duct are supplied by major “dependable” vessels with abundant blood flow. In contrast, the cystic duct has no major feeding or drainage vessels, excluding blood capillaries from the four above-mentioned vessels, suggesting that the cystic duct is not well supplied by any major “dependable” vessels. This condition of the cystic duct might be similar to that of lymphatic flow: “undependable” lymphatic flow might play some role in producing an outcome from CDC that is better than that of the gallbladder cancers. At the very least, future oncological, pathological and surgical studies will be required to determine the exact cause of the lower lymph node metastasis seen in many patients with CDC.

Typical symptoms and findings of CDCs have been reported by several authors and include right upper quadrant pain, jaundice, fever, hydrops of the gallbladder, and/or increasing serum total bilirubin levels, which are usual symptoms of gallbladder stones due to cystic duct obstruction.^{7,8,10,14,15} However, there are some asymptomatic cases such as that reported by Miura et al.¹⁶ and our case. To detect CDC at an early stage, with the exception of a gallbladder stone in the cystic duct, the physician must suspect a mass in the cystic duct if the duct and/or gallbladder is not imaged by MRCP, ERCP or drip infusion cholecystocholangiography CT. After obtaining such diagnostic information and the patients' informed consent, the patients can be referred for

surgical exploration or resection, as in our case. However, patients who reject the surgical procedures might need further examinations (e.g., intraductal ultrasonography, contrast-enhanced color Doppler endoscopic ultrasonography, peroral cholangioscopy or cytological examination) to determine whether they should be left treated and closely observed instead. Some authors report that the typical surgical procedure for CDC is resection of the gallbladder and the extrahepatic bile duct with lymph node dissection in the hepatoduodenal ligament^{14,17} and that for more advanced CDCs, combined resection with hepatectomy or pancreatoduodenectomy might be necessary because perineural or lymphatic infiltration can potentially be present in the adjacent organs through hepatoduodenal or hepatic routes.^{6,7,14} However, from the viewpoint of mini-invasive procedures, open or laparoscopic cholecystectomy alone might be a mini-invasive approach for early CDC limited to the cystic duct located close to the gallbladder, as in early gallbladder cancer (e.g., depth of mural invasion, *m*; *mp*).¹⁸ The procedure would not be applicable to advanced CDC located close to the gallbladder because of remnant cancer at the cut end and insufficient lymph node dissection in the hepatoduodenal ligament. In contrast, resection of the gallbladder and the extrahepatic bile duct with lymph node dissection in the hepatoduodenal ligament are preferable for CDC located close to the common bile duct.¹⁸ Moreover, hepatectomy and/or pancreaticoduodenectomy may be recommended in patients judged to be tolerant to these procedures and may offer the possibility of curative resection with a strict diagnosis of advanced CDC located close to the common bile duct because of perineural or lymphatic infiltration.^{6,7,14,18}

4. Conclusion

In the future, expanded oncological, pathological and surgical knowledge of CDC might bring many patients a relevant diagnosis and allow treatment with a mini-invasive surgical procedure. Diagnosing CDC as early as possible contributes to the avoidance of extended resection including that of adjacent organs such as the pancreas, duodenum or liver. Although there is still room for consideration, cholecystectomy might be preferable as the treatment for early CDC in some cases.

Conflict of interest statement

The authors report that there are no conflicts of interest.

Funding

None.

Ethical approval

Written informed consent was obtained from the patient for publication of this case report and accompanying images. A copy of the written consent is available for review by the Editor-in-Chief of this journal on request.

Authors' contributions

Shuji Komori: Study design, acquisition of data, drafting and critical revision of the manuscript. Juji Tsuchiya: Study design and critical revision of the manuscript. Iwao Kumazawa: Study design. Hajime Kawagoe: Analysis and interpretation of data. Kimitoshi Nishio: Analysis and interpretation of data. Yuki Misao: Acquisition of data.

Key learning points

1. Cystic duct cancer (CDC) as defined by Farrar is rare and has a better prognosis than gallbladder cancer.
2. There remains no good reason why CDC not invading the subserosa results in less lymph node metastasis.
3. We discuss the available diagnostic and therapeutic strategies for surgical treatment from our experience with the present case and with reference to previously reported cases.

References

1. Farrar DA. Carcinoma of the cystic duct. *Br J Surg* 1951;**39**:183–5.
2. Glenn F, Hill Jr MR. Extrahepatic biliary-tract cancer. *Cancer* 1955;**8**:1218–25.
3. Vaittinen E. Carcinoma of the gall-bladder. A study of 390 cases diagnosed in Finland 1953–1967. *Ann Chir Gynaecol Fenn Suppl* 1970;**168**:1–81.
4. Paraskevopoulos JA, Dennison AR, Johnson AG. Primary carcinoma of the gall-bladder. *HPB Surg* 1991;**4**:277–89.
5. Sasaki K, Matsuda M, Hashimoto M, Harano T, Fujii T, Watanabe G. Early cystic duct carcinoma of new classification. *Int J Surg Case Rep* 2011;**2**:246–9.
6. Yokoyama Y, Nishio H, Ebata T, Abe T, Igami T, Oda K, et al. New classification of cystic duct carcinoma. *World J Surg* 2008;**32**:621–6.
7. Nakata T, Kobayashi A, Miwa S, Soeda J, Uehara T, Miyagawa S. Clinical and pathological features of primary carcinoma of the cystic duct. *J Hepatobiliary Pancreat Surg* 2009;**16**:75–82.
8. Ozden I, Kamiya J, Nagino M, Uesaka K, Oda K, Sano T, et al. Cystic duct carcinoma: a proposal for a new working definition. *Langenbecks Arch Surg* 2003;**387**:337–42.
9. Hiramitsu T, Nagata J, Ohnishi E, Nakanishi K, Ohya H, Nishi H, et al. A case of primary cystic duct carcinoma based on Farrar's criteria necessitating additional resection because of difficult preoperative diagnosis. *Nihon Shokaki Geka Gakkai Zasshi* 2009;**42**:1687–92.
10. Benchellal ZA, Soro KG, Orain I, Poret H, Ferhi AH, Darquies-Chevalley J. Thirteen-year disease-free survival after surgery for cystic duct carcinoma: a case report. *Case Rep Gastroenterol* 2008;**2**:428–32.
11. Chijiwa K, Nakano K, Ueda J, et al. Surgical treatment of patients with T2 gallbladder carcinoma invading the subserosal layer. *J Am Coll Surg* 2001;**192**:600–7.
12. Tsukada K, Kurosaki I, Uchida K, Shirai Y, Oohashi Y, Yokoyama N, et al. Lymph node spread from carcinoma of the gallbladder. *Cancer* 1997;**80**:661–7.
13. Kayahara M, Nagakawa T, Ueno K, Ohta T, Takeda T, Miyazaki I. Lymphatic flow in carcinoma of the distal bile duct based on a clinicopathologic study. *Cancer* 1993;**72**:2112–7.
14. Sato M, Watanabe Y, Kikkawa H, et al. Carcinoma of the cystic duct associated with pancreaticobiliary maljunction. *J Gastroenterol* 2001;**36**:276–80.
15. Shiba H, Misawa T, Ito R, Imazu H, Suzuki M, Yanaga K. Preoperative diagnosis of early cystic duct cancer using endoscopic ultrasonography and endocholangioscopy: report of a case. *J Gastrointest Surg* 2011;**15**:1477–9.
16. Miura F, Takada T, Amano H, Yoshida M. Restricted cystic duct carcinoma. *Am J Surg* 2007;**193**:738–9.
17. Chijiwa K, Torisu M. Primary carcinoma of the cystic duct. *J Clin Gastroenterol* 1993;**16**:309–13.
18. Kondo S, Takada T, Miyazaki M, Miyakawa S, Tsukada K, Nagino M, et al. Guidelines for the management of biliary tract and ampullary carcinomas: surgical treatment. *J Hepatobiliary Pancreat Surg* 2008;**15**:41–54.

Open Access

This article is published Open Access at scimedirect.com. It is distributed under the [IJSCR Supplemental terms and conditions](#), which permits unrestricted non commercial use, distribution, and reproduction in any medium, provided the original authors and source are credited.