

## Case report

## Unexplained acute coronary occlusion causing anterior myocardial infarction

Daniel C.S. Chan<sup>1,\*</sup>, Andrew D'Silva<sup>2</sup> and Konrad Grosser<sup>2</sup>

<sup>1</sup>Department of Cardiology, Kettering General Hospital, Kettering NN16 8UZ, UK and <sup>2</sup>Department of Cardiology, Queen Elizabeth the Queen Mother Hospital, Margate CT9 4AN, UK

\*Correspondence address. Department of Cardiology, Kettering General Hospital, Kettering NN16 8UZ, UK.  
Tel: +44-153-649-1373; Fax: +44-153-649-1421; E-mail: daniel.chan@nhs.net

Received 19 February 2014; revised 31 March 2014; accepted 7 April 2014

We present a diagnostic conundrum with a case of a young woman presenting with an acute myocardial infarction in cardiogenic shock who was found to have an occluded left main stem (LMS). Despite ballooning the LMS, multiple re-occlusions in the same area warranted stent deployment. There was a filling defect in the left aortic sinus which was evaluated further with a CT scan and transoesophageal echocardiogram, confirming a mass consistent with a papillary fibroelastoma. The patient went on to have a left ventricular assist device and died while awaiting a heart transplant, but the mass was never found at surgery.

### INTRODUCTION

We present an unusual cause of myocardial infarction which presents a diagnostic challenge.

### CASE REPORT

A 46-year-old female, ex-smoker with recent recurrent transient ischemic attacks (TIAs), collapsed with an acute anterior ST elevation myocardial infarction (STEMI). The patient was in cardiogenic shock necessitating immediate insertion of an intra-aortic balloon pump (IABP) and cardiac catheterization.

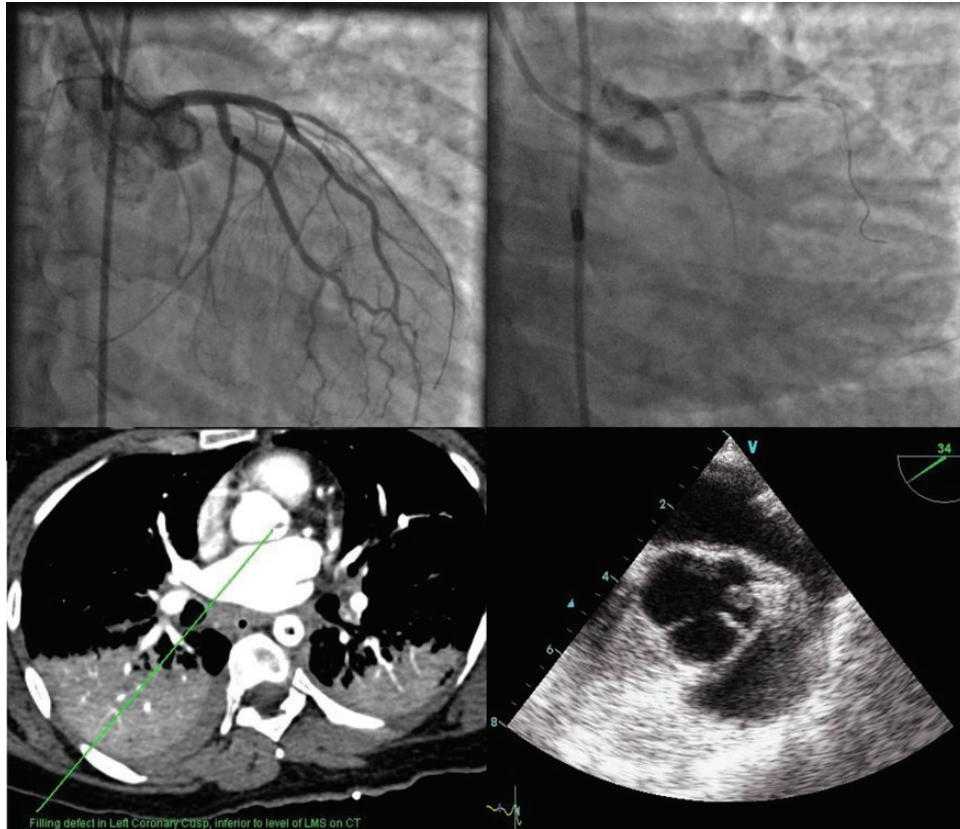
During left heart catheterization, intubation of the left main stem (LMS) was not achieved and an unselected contrast injection into the left aortic sinus was performed. This revealed ostial LMS occlusion and a filling defect in the aortic sinus.

An angioplasty wire was used to 'fish' for the LMS through a JL3.5 guide catheter. After the wire was inserted into the LMS, contrast injection revealed a normal left coronary system with TIMI 3 flow; all side-branches were patent with normal flow. Shortly after the first injection, the LMS again occluded completely. The occlusion was ballooned with a 2.5 × 10 mm balloon resulting in near-normal appearances with normal flow but was followed shortly thereafter by further sudden total occlusion of the LMS (See Figure 1 and [Supplementary videos Image 1–3](#)).

A 3.5 × 8 mm drug-eluting stent was deployed into the ostium of the LMS with some struts deliberately protruding into the aorta due to suspicion that an extra-coronary cause was occluding the coronary artery. No further occlusion was observed thereafter. The right coronary artery was normal. An aortogram revealed a mobile filling defect in the left aortic sinus ([Supplementary video Image 4](#)). CT aortogram confirmed the filling defect and excluded aortic dissection.

The patient was transferred to the intensive treatment unit (ITU), requiring ventilation and inotropic support. She remained in cardiogenic shock on the balloon pump. A focused transoesophageal echocardiogram (TOE) was performed showing poor LV function, a structurally normal mitral valve, no evidence of pericardial effusion or septal defect. However, on the tricuspid aortic valve a round mass of ~5 × 6 mm was seen. The mass was attached to the left aortic sinus and the tip of the aortic valve by thin 'chordae like structures'. The length of the stalks and the exact location meant that with each heart beat the mass was forcefully pushed into the ostium of the LMS ([Supplementary video Images 5 and 6](#)). Antibiotic treatment was prescribed empirically, and the patient was heparinized. Serial blood cultures were negative.

The patient failed to improve despite continuous inotropic and balloon pump support and was transferred ventilated on Day 9 to the nearest transplant centre where a left ventricular assist device (LVAD) was inserted on Day 15. At the time of LVAD implantation, no tumour was found on the aortic cusps.



**Figure 1:** Clockwise from top left. There is a mobile filling defect in the left aortic sinus seen on angiography; transoesophageal echocardiography, where the stent is also visible; and on CT scan of the aortic root.

The stent was removed by the surgeon because the mass had disappeared and to facilitate any future coronary angiography as the stent-struts protruded into the aorta. The patient survived a further 3 months but unfortunately had difficult-to-manage anticoagulation and suffered two cerebral infarctions and died in hospital as a consequence of the second stroke. Unfortunately, no autopsy was performed.

## DISCUSSION

Finding a mass in the aortic sinus attached to a valve leaflet is rare, but its absence at the time of surgery is surprising. During the angioplasty we observed two sudden occlusions of the LMS. Balloon dilatation of the LMS resulted in near-normal appearances of the complete left coronary system including the LMS. This is consistent with either a dissection-flap causing occlusion of the LMS and/or an extra-coronary cause. The latter was confirmed on TOE.

The patient did not demonstrate any evidence of infection pre- or peri-hospitalization and serial blood cultures were negative. Thrombus is unlikely as the TOE appearance argues against this. Nevertheless, thrombus cannot be ruled out because the mass was absent when the LVAD was inserted. The surgeon had direct vision of the aortic valve, the sinotubular junction and relevant parts of the aorta and did not report anything unusual.

However, during the preceding months, she suffered multiple TIAs and was already referred to a consultant physician suggesting longer-standing pathology. Therefore, it is more likely a tumour was the cause of her presentation.

The mass found on TOE had characteristic echocardiographic appearances of a papillary fibroelastoma. It is possible that the fibroelastoma sheared-off after the PCI procedure while the patient was on ITU. Clinical signs of distal embolization may have escaped detection while the patient was sedated.

It is also possible that the repetitive trauma caused by the mass being pushed against the ostium of the LMS caused a dissection of the LMS. While it is conceivable that a thrombus attached to the mass dislodged and occluded the LMS, the absence of occluded side branches or slow-flow in the coronaries during angioplasty argues against this. Sudden re-occlusions with a coronary guide wire inserted also favour a dissection flap of the LMS as the cause of her recurrent LMS occlusion. The fact that no further occlusions were seen after stenting also argues against the mass itself occluding the LMS ostium, although the stent was left deliberately protruding into the aorta to prevent this.

We conclude that the most likely diagnosis is a papillary fibroelastoma causing traumatic LMS dissection with intermittent LMS occlusion causing anterior myocardial infarction and cardiogenic shock.

Although rare, papillary fibroelastomas are the commonest valvular cardiac tumours [1]. They tend to present with distal

embolism, causing cryptogenic strokes, TIAs or coronary occlusion [2, 3]. CT has been used in the past [4, 5] to detect the presence of an aortic valve papillary fibroelastoma correlating with surgical and echocardiographic findings. Whilst histologically benign, it carries a high risk of embolic complications due to the frond-like papillary tissues of the tumour itself. Due to its fragile nature, once diagnosed, urgent surgical management is indicated even in the asymptomatic patients [6].

Once suspected, a TOE should be arranged and the patient should be anticoagulated to prevent thrombotic embolization. Early surgical referral is indicated [7]. Surgical resection (with shave excision) is preferred with the following features: pedunculated lesions, >1 cm in size, mobile tumour and symptoms or complications related to the tumour. Typically surgery involves extracorporeal bypass and aortotomy similar to aortic valve replacement procedures. Ideally, the valve apparatus should be preserved. Resultant valvular defect, if present, should be repaired or replaced. Surgical resection is curative and well-tolerated [7–10].

#### SUPPLEMENTARY MATERIAL

Supplementary material is available at *Oxford Medical Case Reports* online.

#### REFERENCES

1. Bossert T, Gummert JF, Battellini R, Richter M, Barten M, Walther T, et al. Surgical experience with 77 primary cardiac tumors. *Interact Cardiovasc Thorac Surg* 2005;**4**:311–5.
2. Munhoz Da Fontoura Tavares C, Araujo De Oliveira N, Miguel R, Atie J. Recurrent ventricular fibrillation secondary to aortic valve tumor. *Heart Rhythm* 2004;**1**:348–51.
3. Mezilis NE, Dardas PS, Tsikaderis DD, Zaraboukas T, Hantas A, Makrygiannakis K, et al. Papillary fibroelastoma of the cardiac valves: a rare cause of embolic stroke. *Hellenic J Cardiol* 2005;**46**:310–3.
4. Kim AY, Kim JS, Yoon Y, Kim EJ. Multidetector computed tomography findings of a papillary fibroelastoma of the aortic valve: a case report. *J Korean Med Sci* 2010;**25**:809–12.
5. Chia PL. Incidental finding of an aortic valve mass on 64-slice computed tomographic coronary angiography. *Ann Acad Med Singapore* 2009;**38**:926–7.
6. Jha NK, Khouri M, Murphy DM, Salustri A, Khan JA, Saleh MA, et al. Papillary fibroelastoma of the aortic valve—a case report and literature review. *J Cardiothorac Surg* 2010;**5**:84.
7. Gopaldas RR, Atluri PV, Blaustein AS, Bakaeen FG, Huh J, Chu D. Papillary fibroelastoma of the aortic valve: operative approaches upon incidental discovery. *Tex Heart Inst J* 2009;**36**:160–3.
8. Boodhwani M, Veinot JP, Hendry PJ. Surgical approach to cardiac papillary fibroelastomas. *Can J Cardiol* 2007;**23**:301–2.
9. Darvishian F, Farmer P. Papillary fibroelastoma of the heart: report of two cases and review of the literature. *Ann Clin Lab Sci* 2001;**31**:291–6.
10. Sato Y, Yokoyama H, Satokawa H, Takase S, Maruyama Y. A report of a surgical case of papillary fibroelastoma in the left ventricular outflow tract. *Ann Thorac Cardiovasc Surg* 2003;**9**:270–3.