CASE REPORT – OPEN ACCESS

International Journal of Surgery Case Reports 17 (2015) 121–125

Contents lists available at ScienceDirect

International Journal of Surgery Case Reports

journal homepage: www.casereports.com

Effectiveness of neoadjuvant chemotherapy with cisplatin and irinotecan followed by surgery on small-cell carcinoma of the esophagus: A case report

Yuji Akiyama[a,*], Takeshi Iwaya[a], Yoshihiro Shioi[a], Fumitaka Endo[a], Takehiro Chiba[a], Koki Otsuka[a], Hiroyuki Nitta[a], Keisuke Koeda[a], Masaru Mizuno[a], Noriyuki Uesugi[b], Yusuke Kimura[c], Akira Sasaki[a]

[a] Department of Surgery, Iwate Medical University School of Medicine, Iwate, Japan
[b] Division of Molecular Diagnostic Pathology, Department of Pathology, Iwate Medical University School of Medicine, Iwate, Japan
[c] Department of Palliative Care Medicine, Iwate Medical University School of Medicine, Iwate, Japan

ARTICLE INFO

Article history:
Received 15 September 2015
Accepted 10 November 2015
Available online 17 November 2015

Keywords:
Small-cell carcinoma
Esophagus
Neoadjuvant chemotherapy
Esophagectomy

ABSTRACT

INTRODUCTION: Small-cell carcinoma of the esophagus (SCCE) is a rare disease with aggressive progression and a poor prognosis. A standard treatment strategy for SCCE is yet to be established.
PRESENTATION OF CASE: A 40-year-old woman with dysphagia was admitted to our hospital. A clinical diagnosis of SCCE (T3N1N0 stage IIIA) was established. She was initially treated with chemotherapy using cisplatin (CDDP) and irinotecan (CPT-11). After two courses of treatment, the primary lesion in the esophagus was not detectable by esophageal endoscopy. Likewise, swelling of the right recurrent nerve lymph node present prior to treatment could not be detected. The chemotherapy resulted in a complete response. One month after the conclusion of chemotherapy, radical esophagectomy with three-field lymph node dissection was performed. Histopathological examination of the excised specimen revealed no residual tumor or lymph node metastasis. The patient was discharged from hospital 29 days after surgery with no complications. The patient is alive and has remained cancer-free for 48 months after the surgery.
DISCUSSION: Systemic chemotherapy for SCCE in combination with surgery was treated after surgery in most reports. Neoadjuvant chemotherapy is advantageous from three viewpoints, namely achievement of downstaging, increasing complete resection rates, and a better completion of treatment compared with postoperative chemotherapy. Neoadjuvant chemotherapy following esophagectomy could be a useful treatment option for patients with limited disease (LD) of SCCE.
CONCLUSION: We report a case of SCCE achieving a pathologically complete response with neoadjuvant chemotherapy using CDDP and CPT-11, and long-term survival followed by surgery.

1. Introduction

Extrapulmonary small-cell carcinoma is a rare condition, accounting for 2–5% of all small-cell carcinomas [1]. The most common extrapulmonary sites of small-cell carcinoma include the esophagus, other gastrointestinal organs, genitourinary tract, head and neck area, and the breast [2]. Gastrointestinal small-cell carcinomas, including small-cell carcinoma of the esophagus (SCCE), have a poor prognosis [3]. SCCE is a rare disease, accounting for 0.94–1.6% of all esophageal cancers [4,5]. SCCE has a poor prognosis because of its aggressive progression and widespread dissemination with a median survival time (MST) of 3.4–19 months, and the 5-year survival rate is 6.7–15.4% [6].

A standard treatment strategy for SCCE is yet to be established because of its low incidence. Here, we report a case of SCCE achieving a pathologically complete response following chemotherapy with cisplatin and irinotecan, and long-term survival following surgery.

2. Presentation of case

A 40-year-old woman with dysphagia was admitted to our hospital. Esophagogastroscopy revealed an ulcerated mass in the upper thoracic esophagus (Fig. 1a), and histopathological examination of the biopsy showed primary small-cell carcinoma (Fig. 2). A barium esophagram revealed a 20-mm mass with central ulceration in

* Corresponding author. Fax: +81 19 651 7166.
E-mail address: yakiyama@iwate-med.ac.jp (Y. Akiyama).

http://dx.doi.org/10.1016/j.ijscr.2015.11.005

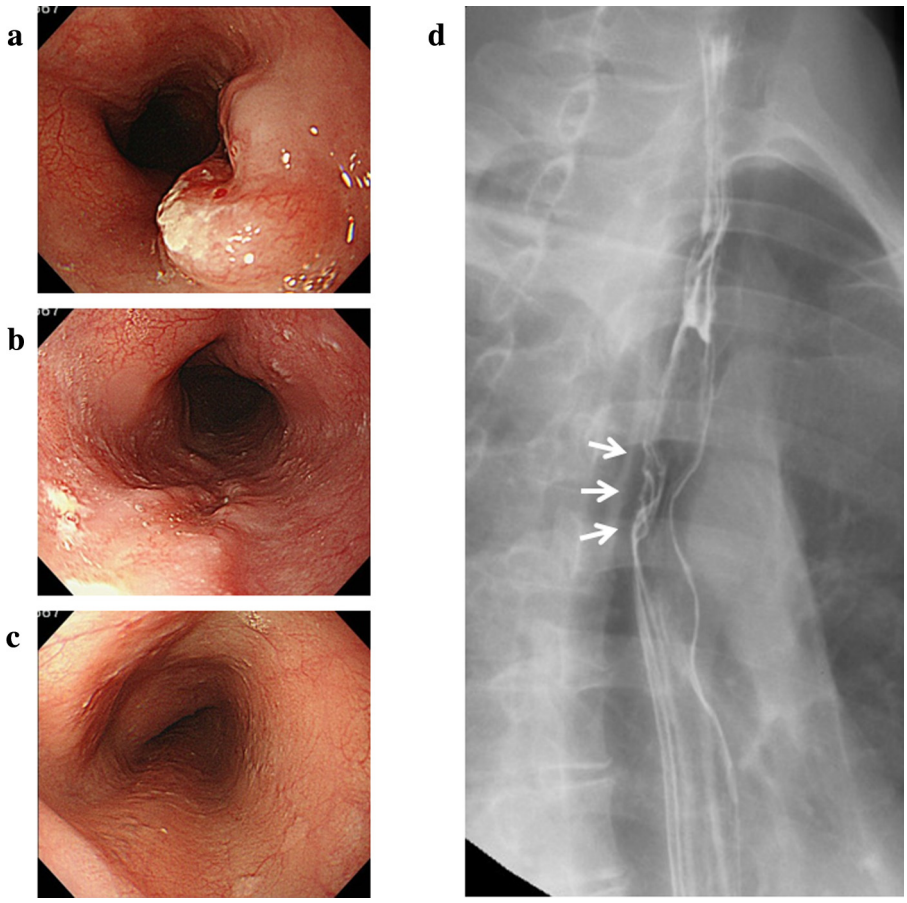

Fig. 1. Esophagogastroscopy and barium esophagography for small-cell carcinoma. (a) Esophagogastroscopy performed at admission revealed an ulcerated mass in the upper thoracic esophagus. (b) Esophagogastroscopy after one course of preoperative chemotherapy with cisplatin and irinotecan revealed that the lesion had markedly flattened. (c) Esophagogastroscopy after two courses of preoperative chemotherapy with cisplatin and irinotecan failed to detect any remaining signs of the tumor. (d) A barium esophagram generated upon admission revealed a 20-mm mass with central ulceration in the upper thoracic esophagus.

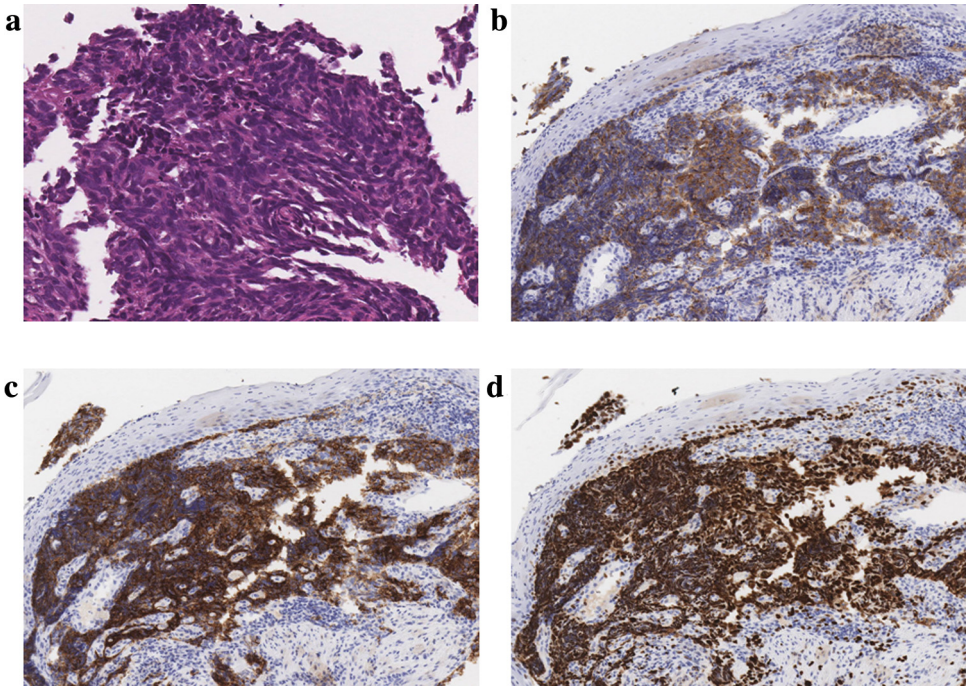

Fig. 2. Pathological examination of endoscopic biopsy specimens from the esophagus. (a) The tumor cells had small round or spindle-shaped nuclei, ill-defined cell borders, finely granular nuclear chromatin, and inconspicuous nucleoli (hematoxylin-eosin stain; 400× magnification). (b) The tumor cells stained positive for synaptophysin (200× magnification). (c) The tumor cells stained positive for CD56 (200× magnification). (d) More than 80% of the nuclei were positive for Ki-67 (200× magnification).

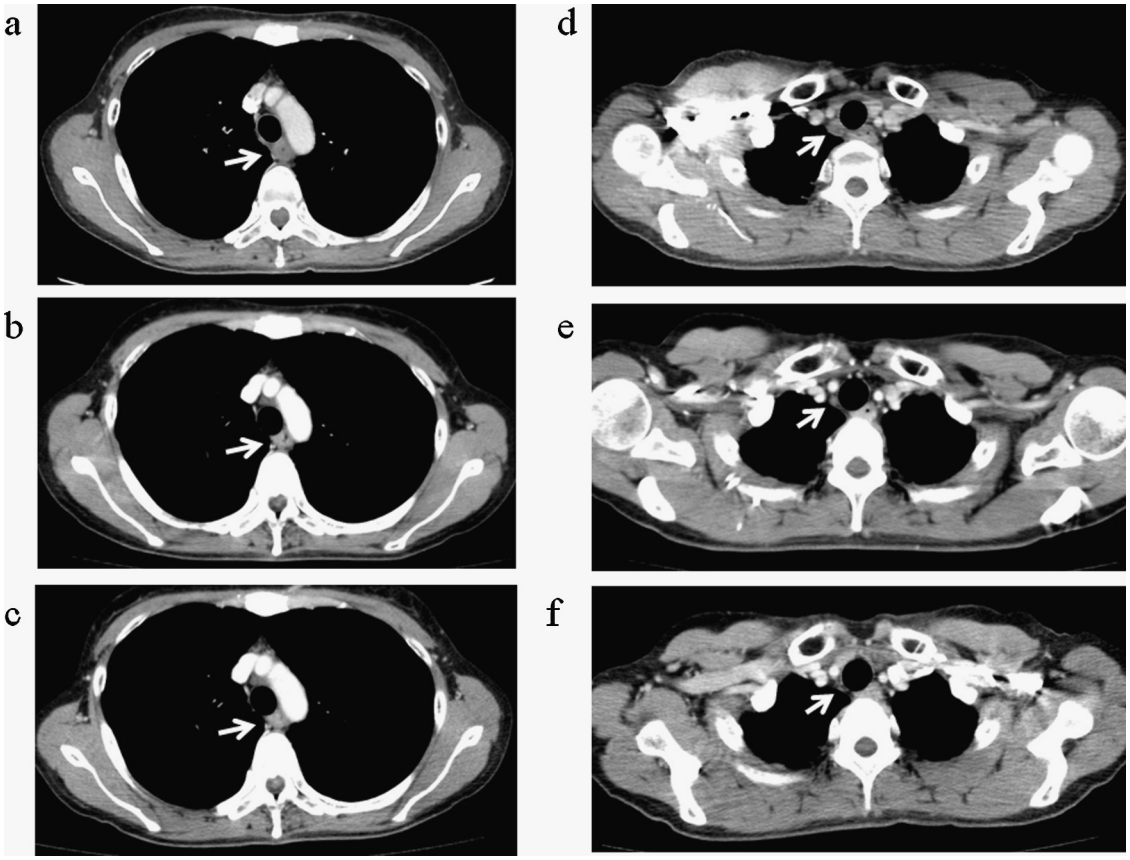

Fig. 3. Chest computed tomography. (a) CT at admission shows wall thickening in the upper thoracic esophagus. (b) After one course of preoperative chemotherapy, the wall thickening in the upper thoracic esophagus was reduced. (c) After two courses of preoperative chemotherapy, the wall thickening in the upper thoracic esophagus could not be detected. (d) The enlarged right recurrent nerve lymph node at admission. (e) After one course of preoperative chemotherapy, the swelling of the right recurrent nerve lymph node was reduced. (f) After two courses of preoperative chemotherapy, the swelling of the right recurrent nerve lymph node could not be detected.

the upper thoracic esophagus (Fig. 1d). Computed tomography (CT) scan revealed an esophageal-wall thickening (Fig. 3a) and enlarged right recurrent nerve lymph node (Fig. 3d). The patient was diagnosed with SCCE (T3N1N0, stage IIIA).

She was initially treated with chemotherapy using cisplatin (CDDP) and irinotecan (CPT-11). She received two courses of CDDP (80 mg/m^2 on day 1) and CPT-11 (70 mg/m^2 on days 1 and 15) with each cycle repeated every 4 weeks. Grade 1 headache (according to the Common Terminology Criteria for Adverse Events Version 4.0) was observed during each course, whereas grade 3/4 adverse effects were not observed. After one course of chemotherapy, esophageal endoscopy revealed that the primary lesion in the esophagus had markedly flattened (Fig. 1b). Furthermore, after two courses of treatment, the tumor could not be detected (Fig. 1c). A CT scan revealed a reduction in the esophageal-wall thickening (Fig. 3c), and the swelling of the right recurrent nerve lymph node (Fig. 3f) was not detected.

One month after the conclusion of chemotherapy, radical esophagectomy with three-field lymph node dissection and gastric tube reconstruction was performed using a thoracoscopic approach in the prone position, laparotomy, and bilateral cervical approaches (Fig. 4). Posterior mediastinal route reconstruction was achieved using a gastric tube. The surgical duration was 666 min, and blood loss was 44 mL. Histopathological examination of the resected specimen failed to reveal any residual cancer, and the histological efficacy of the chemotherapy was grade 3—markedly effective,

Fig. 4. Surgical specimen of the esophagus. No residual tumor tissue could be detected.

with no variable cancer cells observed (according to the Japanese Classification of Esophageal Cancer, 10th edition) [7]. No lymph node metastasis was observed, and there were no chemotherapy-associated complications during or after the surgery. The patient was discharged from the hospital 29 days after the surgery with no complications and treated with adjuvant chemotherapy using CDDP and CPT-11 in one course 2 months after the surgery, with a dose similar to that given prior to treatment. The patient is alive and has remained cancer-free for 48 months after the surgery.

3. Discussion

Although surgery, chemotherapy, radiotherapy, and a combination of these modalities have been used for SCCE as well as for other common types of esophageal cancer, the optimum treatment strategy for SCCE remains to be established. The National Comprehensive Cancer Network (NCCN) guidelines for small-cell carcinoma of the lung (SCCL) are usually used as references to determine the management of extrapulmonary small-cell carcinoma. According to the NCCN guidelines, the indication of surgical resection for SCCL is limited to clinical stage I (T1-2, N0), because patients with diseases which have progressed beyond T1-2, N0 do not benefit from surgery. In patients with extrapulmonary small-cell carcinoma, surgical resection is also performed in cases with limited disease (LD). Zhu et al. reviewed 64 cases of SCCE and reported that 37 out of 46 (80.4%) patients with LD underwent surgical resection [5]. Shinohara et al. summarized 23 cases of SCCE, which achieved >5 years of survival, reported in the literature and reported that surgery had been performed in 17 cases (73.9%) [6]. Furthermore, clinical data reviewed by Brenner et al. showed that surgery could effectively extend the survival time of LD patients [3]. Therefore, it appears that esophagectomy is the predominant treatment modality for patients with LD of SCCE. However, because SCCE is considered a systemic disease with a high risk of distant metastasis, multimodal therapy based on systemic chemotherapy has been suggested for treating this disease [8]. It has been reported that the MST of patients treated using a single method was significantly shorter than those treated using multimodality approaches, and that systemic chemotherapy significantly improved MST for patients with extensive disease (ED) compared with that of locoregional treatment alone [5]. Chen et al. demonstrated that operation and chemotherapy were independent prognostic factors for SCCE in multivariate analysis and recommended surgical resection combined with chemotherapy to treat patients with LD of SCCE [9]. It appears that our present case of SCCE is a good example of a patient achieving long-term survival by surgical resection combined with chemotherapy.

For systemic chemotherapy of SCCL, etoposide/cisplatine (EP) [10] or irinotecan/cisplatin (IP) regimens are frequently used [11]. Although significant differences were not observed in overall survival between IP and EP in two phase III studies in USA [12,13], it has been demonstrated that IP significantly improves progression-free survival and overall survival compared with EP in a randomized phase III study of SCCL with ED in Japan [11]. Moreover, in Japan, IP is the standard therapy for SCCL with ED; therefore, we have selected the IP regimen for our patients. In terms of extrapulmonary small-cell carcinoma, a randomized phase III study conducted by the Japanese Clinical Oncology Group (JCOG) for advanced extrapulmonary neuroendocrine carcinoma comparing IP therapy with EP therapy is currently in progress.

Although systemic chemotherapy for SCCE in combination with surgery was treated after surgery in most reports, several studies have reported cases of preoperative treatment with chemotherapy for SCCE [14,15]. In addition, it has been reported that preoperative chemotherapy improves survival time compared with postoperative chemotherapy for patients with resectable stage II/III esophageal squamous cell carcinoma (JCOG 9907) [16]. Neoadjuvant chemotherapy is advantageous from three viewpoints, namely achievement of downstaging, increasing complete resection rates, and a better completion of treatment compared with postoperative chemotherapy [16]. In the present case, the patient was treated with IP for SCCE, in accordance with the concept of neoadjuvant chemotherapy for stage II/III esophageal squamous cell carcinoma. Considering the aggressive behavior and poor prognosis of SCCE, we added postoperative adjuvant chemotherapy with IP. The patient achieved complete response following two courses of preoperative IP. The rate of complete response and response rate of chemotherapy with IP for SCCL were 2.6% and 84.4%, respectively [11]. Chin et al. reported 12 cases of IP for SCCE, with 2 out of 12 (16.6%) patients with IP achieving complete response [17]. Neoadjuvant chemotherapy following esophagectomy could be a useful treatment option for patients with LD of SCCE.

4. Conclusions

Here, we reported on the successful treatment of SCCE with preoperative chemotherapy using IP followed by surgery. Neoadjuvant chemotherapy following esophagectomy could be a useful treatment option for patients with LD of SCCE.

Conflicts of interest

None.

Funding

None.

Ethical approval

None.

Consent

Written informed consent was obtained from the patient for publication of this case report and accompanying images. A copy of the written consent is available for review by the Editor-in-Chief of this journal on request.

Author contribution

YA and TI conceived the case presentation and drafted the manuscript.

NU interpreted pathological aspects of the case.

KO, HN, KK, MM, and YK participated in the design of the case presentation.

YS, FE, and TC took care of the management of the patient.

AS read and approved the final manuscript.

Guarantor

Takeshi Iwaya.

Acknowledgement

This work was supported by JSPS KAKENHI Grant Number 26461995.

References

[1] S. Howard, K. O'Regan, J. Jagannathan, K. Krajewski, A. Giardino, N. Ramaiya, Extrapulmonary small cell carcinoma: a pictorial review, Am J. Roentgenol. 197 (2011) W392–W398.
[2] Y.N. Wong, R.H. Jack, V. Mak, M. Henrik, E.A. Davies, The epidemiology and survival of extrapulmonary small cell carcinoma in South East England, 1970–2004, BMC Cancer 9 (2009) 209.
[3] B. Brenner, L.H. Tang, D.S. Klimstra, D.P. Kelsen, Small-cell carcinomas of the gastrointestinal tract: a review, J. Clin. Oncol. 22 (2004) 2730–2739.
[4] M. Huncharek, J. Muscat, Small cell carcinoma of the esophagus. The Massachusetts general hospital experience, 1978–1993, Chest 107 (1995) 179–181.
[5] Y. Zhu, B. Qiu, H. Liu, Q. Li, W. Xiao, Y. Hu, M. Liu, Primary small cell carcinoma of the esophagus: review of 64 cases from a single institution, Dis. Esophagus 27 (2014) 152–158.
[6] Y. Shinohara, S. Takeno, Y. Takahashi, T. Moroga, S. Yamashita, K. Kawahara, Successful chemoradiotherapy for small-cell carcinoma of the esophagus in an octogenarian Japanese woman: report of the oldest case and review of long-term survival cases, Ann. Thorac. Cardiovasc. Surg. 20 (2014) 237–242.
[7] Japan Esophageal Society, Japanese Classification of Esophageal Cancer, 10th ed., Kanehara, Tokyo, 2008.
[8] J. Lv, J. Liang, J. Wang, L. Wang, J. He, Z. Xiao, W. Yin, Primary small cell carcinoma of the esophagus, J. Thorac. Oncol. 12 (2008) 1460–1465.
[9] S.B. Chen, J.S. Yang, W.P. Yang, H.R. Weng, H. Li, D.T. Liu, Y.P. Chen, Treatment and prognosis of limited disease primary small cell carcinoma of esophagus, Dis. Esophagus 24 (2011) 114–119.
[10] B.J. Roth, D.H. Johnson, L.H. Einhorn, L.P. Schacter, N.C. Cherng, H.J. Cohen, J. Crawford, J.A. Randolph, J.L. Goodlow, G.O. Broun, G.A. Omura, Randomized study of cyclophosphamide, doxorubicin, and vincristine versus etoposide and cisplatin versus alternation of these two regimens in extensive small-cell lung cancer: a phase III trial of the Southeastern Cancer Study Group, J. Clin. Oncol. 10 (1992) 282–291.
[11] K. Noda, Y. Nishiwaki, M. Kawahara, S. Negoro, T. Sugiura, A. Yokoyama, M. Fukuoka, K. Mori, K. Watanabe, T. Tamura, S. Yamamoto, N. Saijo, Japan Clinical Oncology Group: irinotecan plus cisplatin compared with etoposide plus cisplatin for extensive small-cell lung cancer, N. Engl. J. Med. 346 (2002) 85–91.
[12] N. Hanna, P.A. Bunn Jr., C. Langer, L. Einhorn, T. Guthrie Jr., T. Beck, R. Ansari, P. Ellis, M. Byrne, M. Morrison, S. Hariharan, B. Wang, A. Sandler, Randomized phase III trial comparing irinotecan/cisplatin with etoposide/cisplatin in patients with previously untreated extensive-stage disease small-cell lung cancer, J. Clin. Oncol. 24 (2006) 2038–2043.
[13] P.N. Lara Jr., R. Natale, J. Crowley, H.J. Lenz, M.W. Redman, J.E. Carleton, J. Jett, C.J. Langer, J.P. Kuebler, S.R. Dakhil, K. Chansky, D.R. Gandara, Phase III trial of irinotecan/cisplatin compared with etoposide/cisplatin in extensive-stage small-cell lung cancer: clinical and pharmacogenomic results from SWOG S0124, J. Clin. Oncol. 27 (2009) 2530–2535.
[14] C.D. Medgyesy, R.A. Wolff, J.B. Putnam Jr., J.A. Ajani, Small cell carcinoma of the esophagus: the University of Texas M. D. Anderson Cancer Center experience and literature review, Cancer 88 (2000) 262–267.
[15] N. Koide, M. Hiraguri, K. Kishimoto, T. Nakamura, W. Adachi, H. Miyabayashi, N. Terai, J. Amano, Small cell carcinoma of the esophagus with reference to alternating multiagent chemotherapy: report of two cases, Surg. Today 33 (2003) 294–298.
[16] N. Ando, H. Kato, H. Igaki, M. Shinoda, S. Ozawa, H. Shimizu, T. Nakamura, H. Yabusaki, N. Aoyama, A. Kurita, K. Ikeda, T. Kanda, T. Tsujinaka, K. Nakamura, H. Fukuda, A randomized trial comparing postoperative adjuvant chemotherapy with cisplatin and 5-fluorouracil versus preoperative chemotherapy for localized advanced squamous cell carcinoma of the thoracic esophagus (JCOG9907), Ann. Surg. Oncol. 19 (2012) 68–74.
[17] K. Chin, S. Baba, H. Hosaka, A. Ishiyama, N. Mizunuma, E. Shinozaki, M. Suenaga, T. Kozuka, Y. Seto, N. Yamamoto, K. Hatake, Irinotecan plus cisplatin for therapy of small-cell carcinoma of the esophagus: report of 12 cases from single institution experience, Jpn. J. Clin. Oncol. 38 (2008) 426–431.