

A novel composite two-stage urethroplasty for complex penile strictures: A multicenter experience

Pankaj M. Joshi*, Guido Barbagli¹, Vikram Batra, Sandesh Surana, Atef Hamouda, Salvatore Sansalone², Dimitris Costi³, Massimo Lazzeri⁴, Craig Hunter, Devang J Desai, Fabio Castiglione, Sanjay B. Kulkarni

Kulkarni Centre for Reconstructive Urology, Pune, Maharashtra, India, ¹Department of Reconstructive Urology, Centro Chirurgico Toscano, Arezzo, ²Department of Experimental Medicine and Surgery, University of Tor Vergata, Rome, ³Evangelistria Medical Centre, Nicosia, Cyprus, ⁴Humanitas Clinical and Researcher Centre, Humanitas University, Rozzano, Italy

*E-mail: drpankajmjoshi@gmail.com

ABSTRACT

Introduction: Complex penile strictures are usually repaired using a two-stage urethroplasty. Buccal mucosal graft (BMG) placed in the first stage can have a significant contraction rate, which may require a subsequent revision surgery. We describe a composite two-stage penile urethroplasty using BMG for patients of complex penile strictures who have some salvageable urethral plate.

Methods: Within a multi-institutional cohort, 82 patients underwent a two-stage urethroplasty for complex stricture of the penile urethra. Of these 42 patients who underwent our composite two-stage penile urethroplasty using BMG implanted at the second-stage were included. Patients with genital lichen sclerosus or incomplete clinical records were excluded from this study. The primary outcome of the study was to evaluate stricture-free success rate.

Results: Of total 42, 4 patients were lost to follow-up. 42% of stricture etiology was failed hypospadias repair. Mean stricture length was 4.5 cm (range 3–8 cm). Seventeen (44.7%) patients had undergone the previous urethroplasty. At a median follow-up of 44 months, of 38 patients, 34 (89.5%) were successful, and 4 (10.5%) had a recurrence. No patient required revision surgery before the second-stage and required redo buccal graft harvesting for subsequent urethroplasty.

Conclusions: The composite two-stage technique in repairing complex penile urethral strictures is a valid and reproducible surgical treatment for complex penile stricture and it may reduce the rate of contraction of the transplanted BMG.

INTRODUCTION

Penile urethral strictures can be repaired using either one-stage or two-stage procedures.^[1-4] A one-stage procedure that includes the use of free grafts or pedicled flaps prevents psychological trauma of having an abnormal hypospadiac meatus and poor esthetic appearance of penis as in a two-stage procedure. However, a two-stage approach is necessitated in a complex penile urethral stricture. This would include patients with a narrow meatus and navicular

fossa stricture [Figure 1], chordee, multiple fistula [Figure 2 a], diverticulum, and marked fibrosis, which may extend proximally.^[1]

Two-stage penile urethroplasty was described by Johanson, as an evolution of the Denis-Browne technique used for hypospadias repair.^[5] In patients of complex strictures with lichen sclerosus (LS) or those due to failed hypospadias repair, the diseased urethral plate and surrounding tissue requires complete removal and replacement by a large strip of buccal mucosal graft (BMG), to be tubularized in a

Access this article online	
Quick Response Code:	Website:
	www.indianjurol.com
	DOI:
	10.4103/0970-1591.203426

This is an open access article distributed under the terms of the Creative Commons Attribution-NonCommercial-ShareAlike 3.0 License, which allows others to remix, tweak, and build upon the work non-commercially, as long as the author is credited and the new creations are licensed under the identical terms.

For reprints contact: reprints@medknow.com

Received: 23.03.2016, **Accepted:** 12.10.2016

Financial support and sponsorship: Nil.

Conflicts of interest: There are no conflicts of interest.

second-stage.^[1] In this two-stage penile urethroplasty, BMG is applied at the first stage and closure is performed at the second-stage. Using this technique, up to 30% of patients have a tendency of scarring and retraction of the BMG, requiring revision of graft in second-stage.^[6]

There are patients who have some recoverable urethral plate that is not good enough for a single-stage repair but, at the same time, is not so severe that it merits a traditional two-stage Bracka urethroplasty with complete excision. In such patients, we believe that a two-stage urethroplasty using BMG in the second-stage rather than the first may help avoid the risk of shrinkage and retraction of the graft. We describe the technique and outcomes of a such composite penile 2-stage urethroplasty using BMG in the second-stage.

METHODS

Within two large volume centers, 3654 urethroplasties were performed between 2004 and 2014 of which 347 were for penile urethra. Eighty-three patients had complex penile strictures. Of this group, 42 had some recoverable urethral plate and underwent staged urethroplasty by our technique with BMG insertion in the second-stage.

Objective clinical parameters such as age, clinical history, previous events of dilatation, urethrotomy and urethroplasty, uroflowmetry, ultrasonography, retrograde and voiding cystography were collected for each patient. Clinical failure was considered when any postoperative instrumentation, including dilation, was needed. Uroflowmetry and urine culture were repeated every 6 months in the first 2 years and annually thereafter. When symptoms of reduced flow were present and uroflowmetry was <12 ml/s, meatal calibration, urethrography, urethral ultrasound, and urethroscopy were done to evaluate the cause of failure. The primary outcome of the study was to compare the postoperative stricture-free rate and minimizing need for multiple surgeries.

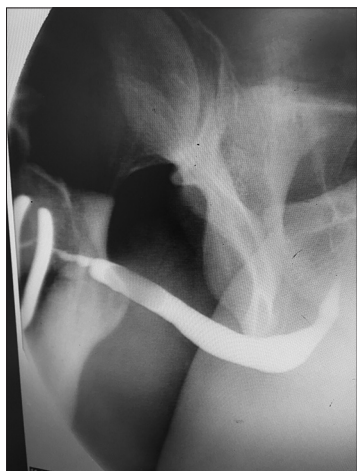

Figure 1: Urethrogram showing penile stricture after failed hypospadias repair

Surgical technique

First stage

Having assessed the patient clinically in the outpatient department, patients were admitted a day before surgery. Patients were requested to apply chlorhexidine solution to genitalia from a day before surgery. A single dose of intravenous antibiotic was administered. The patient was placed in supine position. Urethroscopy was performed with a narrow endoscope such as 6–7.5 or 4.5 Fr ureteroscope and length of stricture assessed. The urethra was fully longitudinally opened along its ventral surface [Figure 2b], and the spongiosum tissue was sutured [Figure 2b]. The penile skin margins were sutured to the margins of the urethral plate, and the new urinary meatus was located in the healthy urethral mucosa 2 cm proximally to the stricture, leaving a wide open meatus proximally to void through [Figure 2b]. A Foley 12 F silicone catheter was left in place for 3 days. A soft dressing was applied. The dressing was removed on day 2 and patient was discharged from the hospital. Catheter was removed on day 7, and uroflowmetry was performed.

Second-stage urethroplasty using oral mucosal graft

Six months after the first stage, the patients were evaluated clinically for closure of the urethra by second-stage urethroplasty. Uroflowmetry and urine culture were performed. Three days before surgery patients were requested to apply chlorhexidine to genitalia twice a day and Chlorhexidine gargles twice a day. A day before surgery intravenous broad spectrum antibiotics were administered. The patients were intubated through the nose, allowing the mouth to be completely free. The patients were operated by two surgical teams who work simultaneously, each having its own set of surgical instruments. The oral mucosa graft was harvested from the cheek according to our standard technique used on more than 553 patients.^[7] The graft was tailored as per individual case. The patient was placed in supine position. A stay suture was taken at glans and penis stretched [Figure 3a]. The meatus was calibrated with the progressive insertion of 10, 12, 14, 16 Fr Nelaton catheters. This gave us the size of proximal normal urethra.

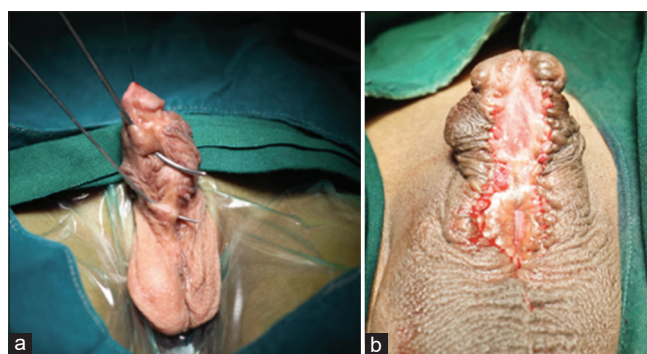


Figure 2: (a) Multiple urethrocuteaneous fistula after failed hypospadias surgery. (b) Stage I Johanson's urethroplasty

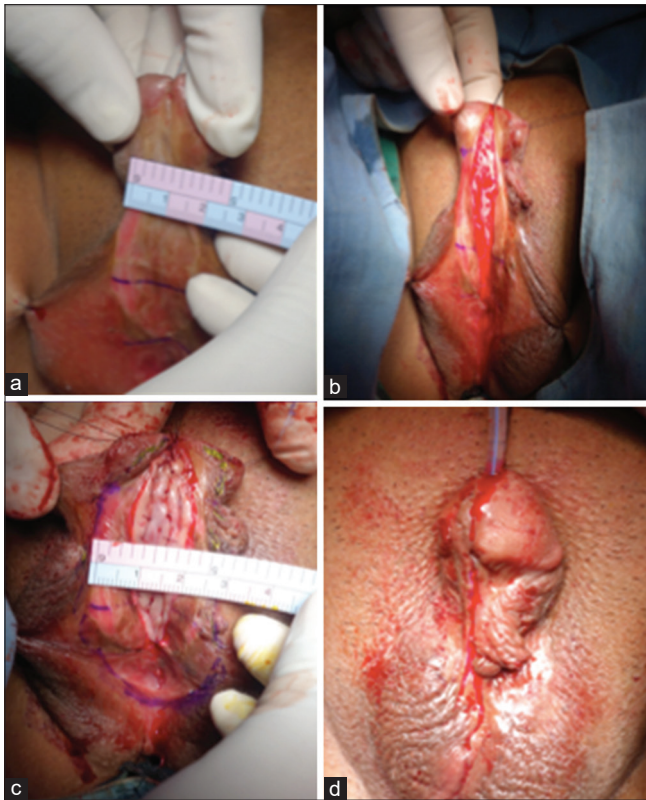


Figure 3: Stage II urethroplasty: (a) Narrow urethral plate (b) midline dorsal incision (c) buccal mucosal graft inserted as dorsal inlay (d) final outcome

The lateral skin incisions of the urethral plate were outlined depicting the narrow urethral plate [Figure 3a]. The lateral margins of the urethral plate were dissected from the penile skin. A midline dorsal longitudinal mucosal incision of the urethral plate was outlined from the existing meatus to where the neomeatus at glans would be. The urethral plate was fully longitudinally incised and opened [Figure 3b]. This was deepened until corpora. Any scarred tissue from previously failed surgeries was excised. A wide bed for the graft was created. The buccal graft harvested was then applied as dorsal inlay [Figure 3c]. Multiple quilting sutures were taken with 6-0 polyglactin. The concept is to make a wide urethral plate using a dorsal inlay buccal graft. This should be as wide as the native proximal urethra. A suprapubic catheter was inserted. A 8 Fr soft tube was used as urethral stent. Urethra was tabularized with subcuticular sutures of polydioxanone. Glansplasty was performed to give a wide vertical slit-like meatus [Figure 3d]. Meatal reconstruction is most important technically as meatal stenosis will lead to fistula formation.

Dartos was mobilized and used to cover the suture line. A narrow strip of dartos may be inserted in between the urethra and glans. The penile skin was meticulously closed. A soft dressing was applied. The soft tube used as a urethral stent was kept just across the constructed urethra, and it

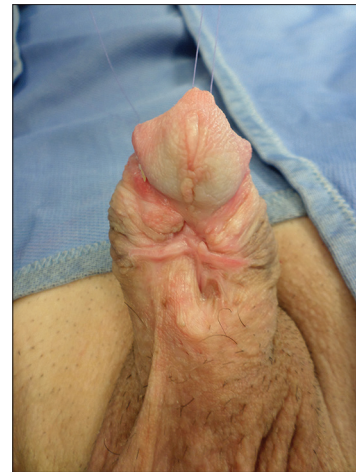

Figure 4: Contracted and scarred buccal graft inserted in Stage I

does not need to enter the bladder. This avoids discomfort to the patient of having two catheters.

Dressings were removed on day 4 and the patients were discharged. They were requested to follow-up on day 21. After clinical assessment, the urethral stent was removed, and suprapubic tube was clamped. After successful voiding per urethra, the suprapubic tube was removed. Uroflowmetry was recorded. Patients were asked to regularly follow-up every 3 months for 1 year and then bi-annually.

RESULTS

Of the 42 patients included, 4 were excluded for having lost to follow-up. The median age was 49 years (range 34–69). Stricture etiology was failed hypospadias repair in 16 (42.1%) patients, idiopathic in 13 (34.2%), catheter induced in 6 (15.8%), and instrumentation in 3 (7.9%). Mean stricture length was 4.5 cm (range 3–8 cm). Seventeen (44.7%) patients had undergone previous urethroplasty, 17 (44.7%) urethrotomy and 2 (5.4%) dilation. Median follow-up was 44 months (range 12–158 months). Of 38 patients, 34 (89.5%) were successful and 4 (10.5%) failed. No patient required revision of surgery before the second-stage. Of the 4 failed patients 2 had glans dehiscence, 1 had fistula, and 1 had complete dehiscence due to infection. The failure cases were all successfully treated by a redo urethroplasty after an interval of 6 months. It was important to note that none of the patients required redo buccal graft harvesting for subsequent urethroplasty.

DISCUSSION

In patients with complex penile strictures, the rationale for the use of second-stage repair using oral mucosa is well documented in the literature.^[1,6,8-10] Complex penile strictures should be classified into two types based on

etiology. The first type is due to LS and second due to other causes such as failed hypospadias, iatrogenic, and infection. LS is an auto-immune disease involving the whole genital skin. A two-stage surgery in LS has a risk of incorporation of the diseased skin in the urethra increasing the risk of failure. Patients with LS should either merit a single-stage repair using BMG. In case of staged repair, the entire white looking urethral plate should be excised with the application of BMG and second-stage closure after 6 months. For all these reasons, we did not perform composite two-stage urethroplasty in LS patients.

Traditionally two-staged urethroplasty involves the application of buccal mucosa in the first stage for subsequent tubularization after 6 months.^[11] In our previous study, involving data of two high volume centers, we found that the use of oral mucosa in the first stage showed a high incidence of scarring and retraction [Figure 4], requiring multiple revisions, with high surgeon and patient disappointment.^[6] Andrich and Mundy presented similar results of staged BMG.^[12] The contraction rate of BMG in first stage was 4% in the UK as compared to 33% in Saudi Arabia in his hands. Overall the contraction rate of BMG placed in first stage varies between 20% and 38% across all high volume centers. This contraction rate leads often to revision surgeries.

Oral mucosa is normally in a moist environment in oral cavity. Application as a staged graft exposes it to dry air and friction with clothes. In our experience, marsupialization of the urethra at the first stage without using any substitution of oral graft appears to be more suitable for an anatomical reconstruction at the second-stage using an oral graft as dorsal inlay.^[2] The oral mucosa is deeply closed inside the urethra that is a humid canal like the oral cavity thus reinstating the original environment of the oral mucosa. Based on these reasons, we believed that our composite two-stage urethroplasty might improve the success rate of complex penile urethroplasty, avoiding the traps of scarring and retraction of the transplanted oral graft. Apart from climatic reasons infection, hematoma, seroma, excessive defatting, or failure to adequately dissect away dense avascular scar tissue from the wound bed, may also contribute to compromised graft viability. However, it is difficult to exactly decide individually the cause for graft contracture [Box 1].

Our study is not devoid of limitations. First, our findings must be interpreted with all the limitations applicable to retrospective studies. Second, its sample size is relatively small. Further prospective, randomized studies are necessary to validate our technique.

Box 1: Surgical options in complex penile stricture

- *Very narrow scarred urethral plate
"Bracka urethroplasty"^[11]
- *Multiple failed surgeries with very narrow urethra <9 Fr with or without fistula
Stage I Johanson's urethroplasty
After 6 months
Dorsal inlay buccal mucosal graft urethroplasty
"Our technique of Composite urethroplasty"
- *Complex penile stricture with urethral plate >10 Fr
Single-stage dorsal inlay augmentation
"Hayes and Malone/Asopa urethroplasty"

CONCLUSIONS

We proposed a new variant of two-stage urethroplasty for repairing complex penile strictures. According to our findings, using BMG in the second stage rather than in first stage may reduce the rate of BMG retraction and the rate of redo surgeries.

REFERENCES

- Mundy AR, Andrich DE. Urethral strictures. *BJU Int* 2011;107:6-26.
- Asopa HS, Garg M, Singhal GG, Singh L, Asopa J, Nischal A. Dorsal free graft urethroplasty for urethral stricture by ventral sagittal urethrotomy approach. *Urology* 2001;58:657-9.
- Barbagli G, Morgia G, Lazzeri M. Retrospective outcome analysis of one-stage penile urethroplasty using a flap or graft in a homogeneous series of patients. *BJU Int* 2008;102:853-60.
- Barbagli G, Lazzeri M. Penile urethral stricture reconstruction – Flap or graft? *Graft. J Urol* 2011;186:375-6.
- Johanson B. Reconstruction of the male urethra in strictures. Application of the buried intact epithelium technic. *Acta Chir Scand* 1953;176 Suppl 176:1-89.
- Barbagli G, De Angelis M, Palminteri E, Lazzeri M. Failed hypospadias repair presenting in adults. *Eur Urol* 2006;49:887-94.
- Barbagli G, Fossati N, Sansalone S, Larcher A, Romano G, Dell'Acqua V, *et al.* Prediction of early and late complications after oral mucosal graft harvesting: Multivariable analysis from a cohort of 553 consecutive patients. *J Urol* 2014;191:688-93.
- Kulkarni S, Barbagli G, Kirpekar D, Mirri F, Lazzeri M. Lichen sclerosis of the male genitalia and urethra: Surgical options and results in a multicenter international experience with 215 patients. *Eur Urol* 2009;55:945-54.
- Barbagli G, Perovic S, Djinoovic R, Sansalone S, Lazzeri M. Retrospective descriptive analysis of 1,176 patients with failed hypospadias repair. *J Urol* 2010;183:207-11.
- Perovic S, Barbagli G, Djinoovic R, Sansalone S, Vallasciani S, Lazzeri M. Surgical challenge in patients who underwent failed hypospadias repair: Is it time to change? *Urol Int* 2010;85:427-35.
- Bracka A. The role of two-stage repair in modern hypospadiology. *Indian J Urol* 2008;24:210-8.
- Andrich DE, Mundy AR. Climate – A potential cause of primary graft failure in buccal mucosal graft urethroplasty. *J Urol* 2009;181(Supp): Abstract 40, pp15.

How to cite this article: Joshi PM, Barbagli G, Batra V, Surana S, Hamouda A, Sansalone S, *et al.* A novel composite two-stage urethroplasty for complex penile strictures: A multicenter experience. *Indian J Urol* 2017;33:155-8.