

Available online at www.sciencedirect.com

ScienceDirect

journal homepage: <http://Elsevier.com/locate/radcr>

Case Report

Sonographic and magnetic resonance imaging findings of neurocutaneous melanosis

Yingming Amy Chen MD^{a,*}, Joel Woodley-Cook MD^a, Michael Sgro MD^b,
Aditya Bharatha MD^a

^a Department of Medical Imaging, St. Michael's Hospital, University of Toronto, 30 Bond Street, Toronto, ON M5B 1W8, Canada

^b Department of Pediatrics, St. Michael's Hospital, University of Toronto, 30 Bond Street, Toronto, ON M5B 1W8, Canada

ARTICLE INFO

Article history:

Received 3 November 2015

Accepted 10 December 2015

Available online 12 January 2016

Keywords:

Neurocutaneous melanosis

Congenital nevus

Neonatal brain ultrasound

MRI

ABSTRACT

Neurocutaneous melanosis is a rare nonfamilial phakomatosis characterized by large or multiple congenital melanocytic nevi plus the presence of central nervous system melanosis or melanoma. We report a case of a male infant with a giant posteroaxial nevus and evidence of intracranial melanosis on ultrasound and magnetic resonance imaging.

Copyright © 2016, the Authors. Published by Elsevier Inc. under copyright license from the University of Washington. This is an open access article under the CC BY-NC-ND license (<http://creativecommons.org/licenses/by-nc-nd/4.0/>).

Case report

Clinical presentation

A male infant with normal prenatal investigations was born at term by uneventful vaginal delivery. Physical examination at birth showed a giant hairy nevus and multiple satellite nevi covering most of his back and buttocks (Fig. 1). Neurologic examinations were normal. Family history revealed large nevi in his paternal great aunt and paternal grandfather.

Imaging findings

Transfontanelar ultrasound was performed on the day of birth, which demonstrated a few small echogenic foci in the left thalamus and left choroidal fissure, without mass effect (Fig. 2). Brain magnetic resonance imaging (MRI) confirmed the presence of those foci, which were T1 hyperintense. Additional foci were noted in the right thalamus (not shown), bilateral inferior basal ganglia, and right cerebellum (Figs. 3A-C). The lesions appeared hypointense on T2-weighted and susceptibility-weighted images. There was no evidence of leptomeningeal

Disclosures: Dr. Yingming Amy Chen, Dr. Joel Woodley-Cook, Dr. Michael Sgro, and Dr. Aditya Bharatha: None.

Competing Interests: The authors have declared that no competing interests exist.

* Corresponding author.

E-mail address: yingming.chen@utoronto.ca (Y.A. Chen).

<http://dx.doi.org/10.1016/j.radcr.2015.12.004>

1930-0433/Copyright © 2016, the Authors. Published by Elsevier Inc. under copyright license from the University of Washington. This is an open access article under the CC BY-NC-ND license (<http://creativecommons.org/licenses/by-nc-nd/4.0/>).

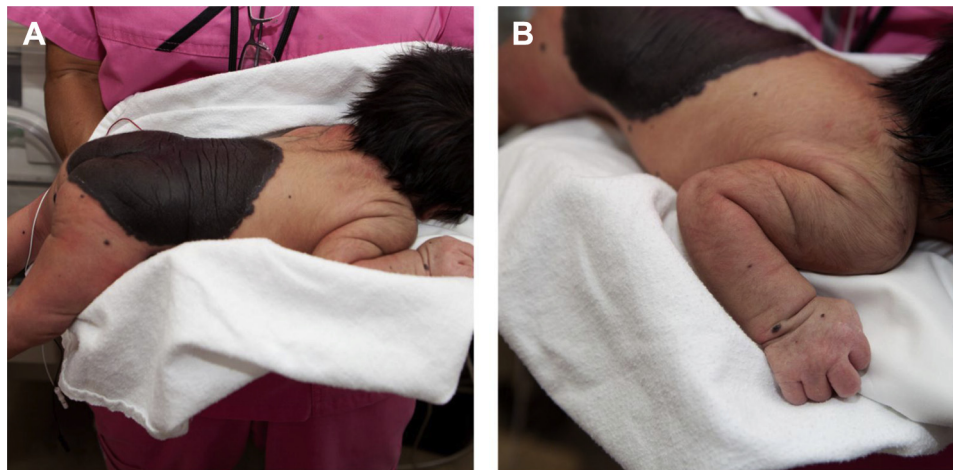

Fig. 1 – Congenital giant nevi on the back of a term baby, with dominant “cape-like” lesion on his back and buttocks (A), and multiple surrounding small lesions extending to both upper and lower extremities (B).

enhancement. Given the presence of the giant nevi, the provisional diagnosis of neurocutaneous melanosis (NCM) was established.

Outcome and follow-up

The patient remained neurologically asymptomatic at 3 months. A follow-up MRI demonstrated stable T1-hyperintense lesions (Figs. 3D-F).

Discussion

NCM is a rare nonfamilial phakomatosis first described in 1861 [1], with approximately 100 cases reported in the literature. Patients usually present with giant nevus in the lumbosacral region at birth, with normal neurologic examination [2]. Diagnostic criteria involves a large nevi (>20 cm in diameter) or multiple (>3) congenital melanocytic nevi, plus the presence of benign central nervous system (CNS) melanosis or malignant CNS melanoma [2]. Patients with large congenital melanocytic nevus in the posterior axial location [3] especially when associated with satellite nevi, are at higher risk for

developing CNS melanosis [4,5]. The condition is associated with other brain abnormalities, including Dandy–Walker malformation [6–9], Chiari I malformation [10], and arachnoid cyst [10].

Normal melanocytes originate from the ectodermal cells of the neural crest and are found in the reticular formation of medulla and pons, substantia nigra, and the leptomeninges [11]. In NCM, there is an over-proliferation of melanocytes in the leptomeninges at the base of the brain [2,12], as well as in the parenchymal perivascular spaces of the anterior temporal lobes, thalami, basal ganglia, cerebellum, pons, and medulla [13,14]. The proliferation of CNS melanocytes may be either benign or malignant and remain difficult to determine even on histologic examination [15].

Despite the presence of CNS melanosis, most patients are asymptomatic at birth [4,10]. Neurologic symptoms if present, occur within the first 2 years of life, and portend a poor prognosis [2]. The most common symptoms are hydrocephalus, lethargy, seizures, and cranial nerve dysfunction. Hydrocephalus is believed to occur secondary to melanocytic

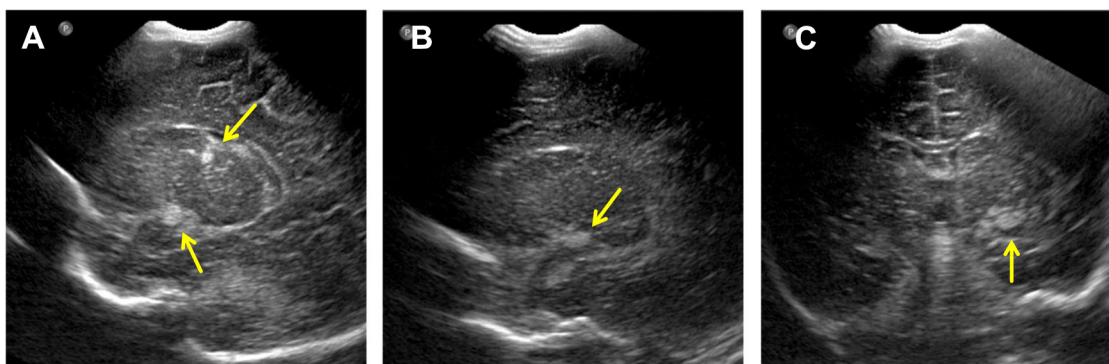


Fig. 2 – Neonatal transfontanellar ultrasound images in left parasagittal (A, B) and coronal (C) planes demonstrate echogenic lesions in the left thalamus and left choroidal fissure (arrows).

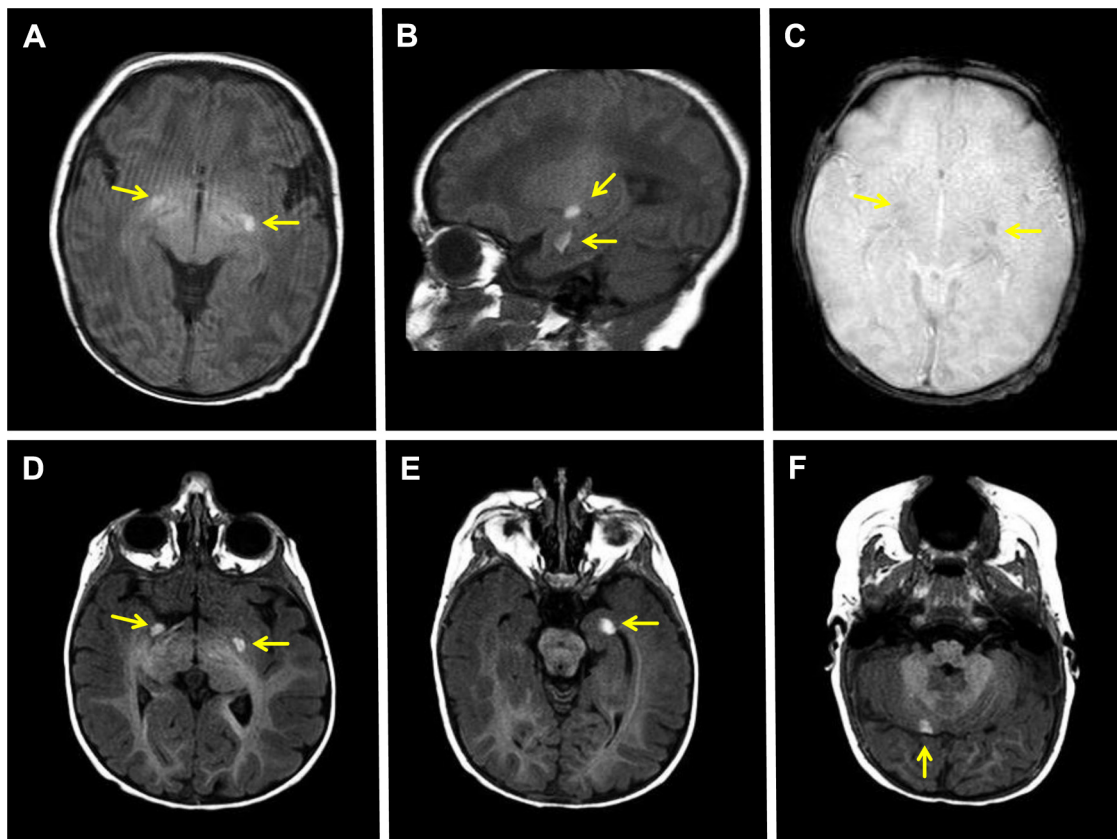


Fig. 3 – Neonatal brain MR images show multiple T1-hyperintense intraparenchymal lesions in bilateral inferior basal ganglia (A), left thalamus and left mesial temporal lobe (B). The lesions are mildly hypointense on susceptibility-weighted images (C). Repeat MR images, 3 months later, demonstrate stable T1-hyperintense lesions in bilateral inferior basal ganglia (D), left mesial temporal lobe (E), and right cerebellum (F). Arrows point to the intraparenchymal lesions.

infiltration of the brain stem, causing leptomeningeal resorption disturbance [15].

Our case elegantly demonstrates the features of intracranial melanocytosis on ultrasound. Although the diagnosis of NCM is not definitive on ultrasound, it is important for radiologists to recognize the sonographic appearance of the lesions and be alerted to the potential diagnosis given an appropriate clinical history [16]. Differential diagnosis of echogenic lesions on ultrasound in a neonate would include hemorrhage, primary or metastatic neoplasm, and hamartomas in tuberous sclerosis.

MRI remains the modality of choice in the diagnosis and characterization of CNS melanosis in NCM, although the sensitivity remains unknown. Parenchymal melanocyte deposits appear hyperintense on T1-weighted images, because of T1-shortening effects of melanin and its paramagnetic free radicals [13,14]. The lesions are usually T2-hypointense, and without significant mass effect or surrounding edema. Leptomeningeal deposits in the sulci, and cisterns have variable signal characteristics and may appear hyperintense on fluid attenuated inversion recovery sequences [12] and/or demonstrate enhancement [17]. Gradient echo images may show susceptibility artefact in the location of parenchymal deposits, due to hemorrhage and melanin. Differential diagnosis of a T1-hyperintense lesion would include hemorrhage,

melanin, fat, protein, and some paramagnetic substances (manganese, copper, and so forth). The T2-hypointensity of the lesions, in our case, makes hemorrhage and fat less likely.

Similar to findings on histology, MRI is insensitive in differentiating between benign vs malignant intracranial melanosis. Malignant transformation may be preceded by the increasing number and size of intracranial or intraspinal masses, or by interval direct parenchymal invasion of known masses, which can be demonstrated by serial MRI [10,18]. Features of intralesional necrosis and hemorrhage would also be suggestive of malignancy but may be absent [8,13,19].

In patients with intracranial melanoma, prognosis is poor regardless of chemotherapy or radiation therapy [18,20]. Neurosurgical resection can prevent sudden death from acute hydrocephalus and herniation, but curative tumor resection is not possible because of massive parenchymal infiltration and rapid regrowth of lesions [21].

Learning points

1. NCM is a rare nonfamilial phakomatosis characterized by large or multiple congenital melanocytic nevi plus the presence of CNS melanosis or melanoma.

2. Neonatal brain ultrasound can alert radiologists to the potential diagnosis of NCM given the clinical history of congenital melanocytic nevi.
3. MRI is the modality of choice in the diagnosis of CNS melanosis, with the parenchymal melanocyte deposits appearing hyperintense on T1-weighted images because of the T1-shortening effects of melanin.
4. MRI scans should be performed to detect brain melanosis in all infants with large or multiple congenital nevi. If positive, regular interval MRI scans should be performed to assess lesion progression and to monitor development of acute complications.

REFERENCES

- [1] Rokitansky J. An excellent case of a pigmented mole with effused pigmentation of the inner meninges of the brain and the spinal cord [in German]. *Allg Wien Mediz* 1861;26:113–6.
- [2] Kadonaga JN, Frieden IJ. Neurocutaneous melanosis: definition and review of the literature. *J Am Acad Dermatol* 1991;24(5 Pt 1):747–55.
- [3] DeDavid M, Orlow SJ, Provost N, Marghoob AA, Rao BK, Huang CL, et al. A study of large congenital melanocytic nevi and associated malignant melanomas: review of cases in the New York University Registry and the world literature. *J Am Acad Dermatol* 1997;36(3 Pt 1):409–16.
- [4] DeDavid M, Orlow SJ, Provost N, Marghoob AA, Rao BK, Wasti Q, et al. Neurocutaneous melanosis: clinical features of large congenital melanocytic nevi in patients with manifest central nervous system melanosis. *J Am Acad Dermatol* 1996;35(4):529–38.
- [5] Marghoob AA, Dusza S, Oliveria S, Halpern AC. Number of satellite nevi as a correlate for neurocutaneous melanocytosis in patients with large congenital melanocytic nevi. *Arch Dermatol* 2004;140(2):171–5.
- [6] Kalayci M, Cağavi F, Bayar U, Gül S, Dursun A, Ermis B, et al. Neurocutaneous melanosis associated with Dandy-Walker malformation. *Acta Neurochir (Wien)* 2006;148(10):1103–6. discussion 1106.
- [7] Berker M, Oruckaptan HH, Oge HK, Benli K. Neurocutaneous melanosis associated with Dandy-Walker malformation. Case report and review of the literature. *Pediatr Neurosurg* 2000;33(5):270–3.
- [8] Kadonaga JN, Barkovich AJ, Edwards MS, Frieden IJ. Neurocutaneous melanosis in association with the Dandy-Walker complex. *Pediatr Dermatol* 1992;9(1):37–43.
- [9] Schreml S, Gruendobler B, Schreml J, Bayer M, Ladoyanni E, Prantl L, et al. Neurocutaneous melanosis in association with Dandy-Walker malformation: case report and literature review. *Clin Exp Dermatol* 2008;33(5):611–4.
- [10] Frieden IJ, Williams ML, Barkovich AJ. Giant congenital melanocytic nevi: brain magnetic resonance findings in neurologically asymptomatic children. *J Am Acad Dermatol* 1994;31(3 Pt 1):423–9.
- [11] Kinsler VA, Aylett SE, Coley SC, Chong WK, Atherton DJ. Central nervous system imaging and congenital melanocytic naevi. *Arch Dis Child* 2001;84(2):152–5.
- [12] Hayashi M, Maeda M, Maji T, Matsubara T, Tsukahara H, Takeda K. Diffuse leptomeningeal hyperintensity on fluid-attenuated inversion recovery MR images in neurocutaneous melanosis. *Am J Neuroradiol* 2004;25(1):138–41.
- [13] Barkovich AJ, Frieden IJ, Williams ML. MR of neurocutaneous melanosis. *Am J Neuroradiol* 1994;15(5):859–67.
- [14] Demirci A, Kawamura Y, Sze G, Duncan C. MR of parenchymal neurocutaneous melanosis. *Am J Neuroradiol* 1995;16(3):603–6.
- [15] Pavlidou E, Hageg C, Papavasiliou A, Giouroukos S, Panteliadis C. Neurocutaneous melanosis: report of three cases and up-to-date review. *J Child Neurol* 2008;23(12):1382–91.
- [16] Johnson JM, Patten LL, Robson CD, Teele RL. Ultrasonographic detection of intracranial melanocytosis in an infant. *Pediatr Radiol* 2010;40(2):210–4.
- [17] Byrd SE, Darling CF, Tomita T, Chou P, de Leon GA, Radkowski MA. MR imaging of symptomatic neurocutaneous melanosis in children. *Pediatr Radiol* 1997;27(1):39–44.
- [18] Chu WCW, Lee V, Chan Y, Shing MMK, Chik K, Li C, et al. Neurocutaneous melanomatosis with a rapidly deteriorating course. *AJNR Am J Neuroradiol* 2003;24(2):287–90.
- [19] Mena-Cedillos CA, Valencia-Herrera AM, Arroyo-Pineda AI, Salgado-Jiménez MA, Espinoza-Montero R, Martínez-Avalos AB, et al. Neurocutaneous melanosis in association with the Dandy-Walker complex, complicated by melanoma: report of a case and literature review. *Pediatr Dermatol* 2002;19(3):237–42.
- [20] Makin GW, Eden OB, Lashford LS, Moppett J, Gerrard MP, Davies HA, et al. Leptomeningeal melanoma in childhood. *Cancer* 1999;86(5):878–86.
- [21] Livingstone E, Claviez A, Spengler D, Barth H, Stark AM, Hugo H-H, et al. Neurocutaneous melanosis: a fatal disease in early childhood. *J Clin Oncol* 2009;27(13):2290–1.