



Case Report

Chronic CSF leak from lumbar-peritoneal shunt tract: A case report

Ali Bakhsh, Mohamed Elmolla, Neil Buxton, Andrew Brodbelt

Department of Neurosurgery, NHS, Liverpool, Merseyside, United Kingdom.

E-mail: *Ali Bakhsh - ali.bakhsh.liv@gmail.com; Mohamed Elmolla - mohamed.elmolla@thewaltoncentre.nhs.uk; Neil Buxton - neil.buxton@thewaltoncentre.nhs.uk; Andrew Brodbelt - abrodbelt@doctors.org.uk



*Corresponding author:

Ali Bakhsh,
Department of Neurosurgery,
NHS, Liverpool, Merseyside,
United Kingdom.

ali.bakhsh.liv@gmail.com

Received : 28 October 2021

Accepted : 13 April 2022

Published : 20 May 2022

DOI

10.25259/SNI_1084_2021

Quick Response Code:



ABSTRACT

Background: We describe a case of long-standing intracranial hypotension caused by an iatrogenic arachnoid diverticulum. This case illustrates two learning points. First, excessive CSF absorption may occur through an acquired arachnoid-epidural venous plexus at a dural defect. Second, a long-standing CSF leak may benefit from definitive surgical repair in the first instance.

Case Description: A 55-year-old female, with known idiopathic intracranial hypertension, presented with disabling chronic low-pressure symptoms after having a lumboperitoneal shunt removed 5 years previously. MRI scan revealed a Chiari I malformation (CMI) and a small dural interruption at the L3/4 space. CT myelography confirmed the abnormality. Intraoperatively, a dural defect and arachnoid bleb with an overlying attachment of adipose tissue and a vessel were found. Postoperatively, the patient has marked resolution of her headaches and dizziness and is mobilizing independently.

Conclusion: Excessive CSF absorption appears to have occurred through an acquired arachnoid-epidural venous plexus. A high index of suspicion for intracranial hypotension is required in patients with low pressure symptoms and a CMI.

Keywords: Chiari, CSF, Intracranial hypotension, Shunt, Spine

INTRODUCTION

Symptomatic CSF leaks are commonplace and have an established diagnostic pathway. Usually, treatment is conservative and failing that simple dural repair may be required. We present a case with long-standing debilitating low-pressure symptoms which were explained by high flow CSF escape through an acquired arachnoid-epidural venous plexus. Such a mechanism has not been reported in the literature to the author's knowledge. Furthermore, the established initial conservative treatment approach may not be suitable and direct surgical repair may be indicated in the first instance. The patient gave their written consent to publish this report.

CASE STUDY

A 55-year-old female presented with an 18-month history of progressive postural holocranial headaches, dizziness, brain fog, dull neck pain, left facial numbness and twitching, and pain

in both arms in a C7–C8 distribution. Symptoms were severe when upright but resolved on recumbency such that the patient was confined to bed for the majority of the day. Twenty years previously, a diagnosis of idiopathic intracranial hypertension (IIH) had been made and a lumboperitoneal (LP) shunt inserted. The following year, a fixed-pressure valve ventriculoperitoneal (VP) shunt was placed for ongoing symptoms. In the 5 years before the current presentation, the low-pressure symptoms described above first appeared. Both the LP and VP shunts were removed due to concerns of CSF over draining. The low-pressure symptoms then initially resolved after the eventual removal of both the LP and VP shunts, until gradually reappearing for the current episode.

Diagnostic work-up

MRI head and spine were performed to investigate this patients' low-pressure symptoms. MRI head was reported as a Chiari I malformation (CMI). MRI spine was reported as normal. On close inspection, however, a small dural interruption was seen on sagittal MRI [Figure 1]. Subsequent CT myelography showed a CSF bleb L3/4. This dural defect was at the same level at which the LP shunt was removed.

Surgical repair

Initial attempts at an epidural blood patch failed to provide symptom relief. The patient underwent an operation. The L3/L4 dural level was approached through a posterior and midline approach. A dural defect and arachnoid bleb were found with an overlying attachment of adipose tissue and a vessel [Figure 2].

The vessel was coagulated and cut. The adipose tissue was dissected off the dura and cauterized. The arachnoid was preserved. The dura was fine and friable, and the interrupted 5/0 Prolene® caused holes that leaked as the stitch was made. The dural defect was eventually closed and covered with TISSEEL glue (Baxter International Inc. Deerfield, Illinois, U.S). Due to concerns of ongoing CSF leakage if a further defect was made, a lumbar drain was not inserted. Acetazolamide 500 mg BD was started postoperatively and was continued long-term, with a view to wean according to the symptom severity. The patient remained on strict bed rest. The patient's symptoms, however, remained unchanged. A repeat MRI demonstrated a significant pseudomeningocele and an ongoing leak.

A further exploration occurred. Intraoperatively, CSF was seen leaking around the previous stitches. All the sutures were removed and the arachnoid reopened. The dural defect was extended and then closed with continuous 5/0 Prolene®. A small piece of muscle was crushed and placed on the suture line. A lumbar drain was inserted in an adjacent segment for

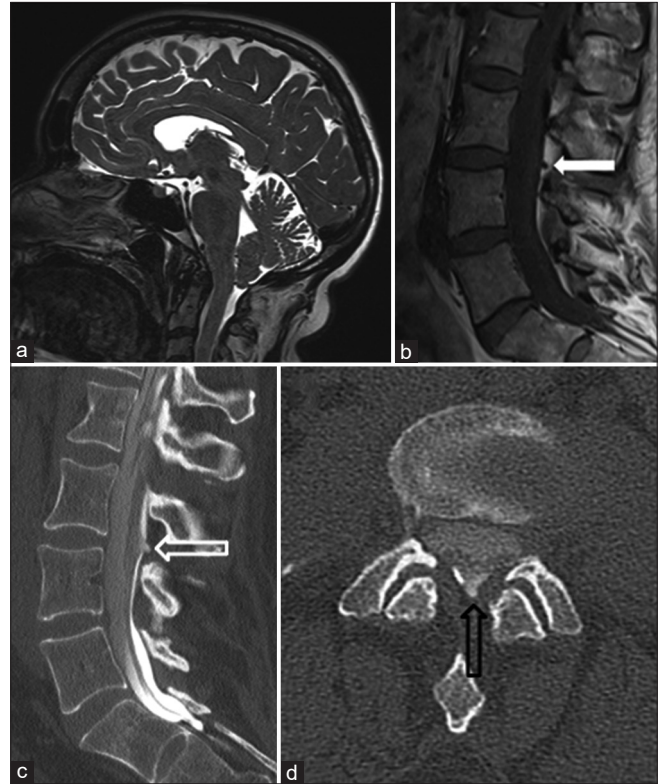

Figure 1: (a) Sagittal T2W MRI scan showing tonsillar descent with effacement of cisterna magna. (b) Sagittal T1W MRI reported as normal but reveals dural defect (white arrow) at L3/4. (c) Sagittal CT myelogram showing a posterior dural outpouching at L3/4 (hollow white arrow). (d) Axial CT myelogram view of same central dural defect at L3/4 (hollow black arrow).

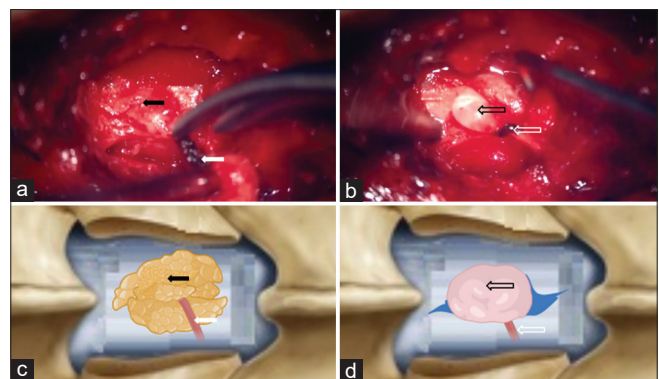


Figure 2: (a) Intraoperative view (diagrammatically illustrated below) shows adipose tissue (black arrow) with a vessel (white arrow) attached to underlying dura. (b) After adipose tissue excision, arachnoid enclosed CSF seen (hollow black arrow). Ligated vessels indicated by hollow white arrow. (c) Diagram of intra-operative pre-repair image above (black arrow showing adipose tissue). (d) Diagram of intra-operative post-repair image above (arachnoid enclosed CSF indicated by hollow white arrow).

5 days and then removed. At 4 months post repair, the patient has marked improvement in her main symptoms of postural

headache and dizziness. She is mobilizing independently and is being weaned off acetazolamide.

DISCUSSION

We present a unique case of chronic CSF overdrainage secondary to a persistent dural defect formed after a LP shunt was removed. This case is distinct from well-recognized cases of spontaneous intracranial hypotension^[5,7,13] and cases where CSF bypasses *in situ* LP shunts.^[8] LP shunts are often used to manage medically refractory idiopathic IHH.^[6]

Overdrainage is a common consequence and can cause an acquired CMI. CMI associated with LP shunts is common, with one study reporting an incidence of 70%.^[10] The concurrent insertion of both LP and VP shunts is unusual and may risk further overdrainage.^[11] Both the LP and VP shunt may have caused headaches by acquired CMI and by overdraining the ventricles, respectively. The wider adoption of adjustable and anti-siphon LP valve systems has been shown to reduce overdrainage and reduce revision rates.^[15]

A high index of suspicion for a CSF leak based on the history was required in this case. CSF leaks may be occult on routine CT and MRI images, especially with a slow velocity or low volume leak.^[14] CT myelography (CTMy) and intrathecal gadolinium magnetic resonance myelography (GdMRMy) both have higher sensitivity and better spatial resolution than standard MR sequences to localize the existence and site of the leak.^[8,9] GdMRMy has a reported true positive rate of 80% for CSF leak detection.^[2] CMI is most commonly caused by a small posterior fossa, but a small proportion are caused by a CSF leak and positional symptomatology is a key clinical factor toward that diagnosis.^[3]

A comprehensive surgical approach and careful postsurgical course was required to ensure definitive repair. Extending the dural defect and opening the arachnoid facilitated a watertight closure. Muscle placed directly onto the dura after suturing, coupled with a short period (5 days) of lumbar drainage and acetazolamide aided the repair during the initial stages of healing, and could have avoided reoperation if performed on the first exploration. Strict bed rest with incremental head elevation reduced postural pressure challenges on the dural repair in the early stages. A reverse trandelberg position was not used but has been suggested previously. Combining these measures maximized the chances of dural healing to reduce the risk of further leakage.^[1,17]

The intraoperative findings confirm the radiological findings of an arachnoid bleb. In the spine, multiple CSF absorption pathways are known, including pathways across nerve root sheaths and arachnoid granulations.^[4] Some spinal arachnoid villi have been shown to be in direct contact with the epidural venous plexus.^[12,16] In this case, we propose that the adipose

tissue and vessel acted as a conduit for CSF absorption. Symptom improvement after successful dural closure with adipose and vessel removal supports this proposal.

CONCLUSION

In patients with significant postural symptoms and a history of spinal CSF diversion, a CSF leak needs to be ruled out with CTMy or GdMRMy. An aggressive surgical repair with post op precautions is more likely to achieve definitive repair.

Declaration of patient consent

The authors certify that they have obtained all appropriate patient consent.

Financial support and sponsorship

Nil.

Conflicts of interest

There are no conflicts of interest.

REFERENCES

1. Abrishamkar S, Khalighinejad N, Moein P. Analysing the effect of early acetazolamide administration on patients with a high risk of permanent cerebrospinal fluid leakage. *Acta Med Iran* 2013;51:467-71.
2. Akbar JJ, Luetmer PH, Schwartz KM, Hunt CH, Diehn FE, Eckel LJ. The role of MR myelography with intrathecal gadolinium in localization of spinal CSF leaks in patients with spontaneous intracranial hypotension. *AJNR Am J Neuroradiol* 2012;33:535-40.
3. Atkinson JL, Weinshenker BG, Miller GM, Piepgras DG, Mokri B. Acquired Chiari I malformation secondary to spontaneous spinal cerebrospinal fluid leakage and chronic intracranial hypotension syndrome in seven cases. *J Neurosurg* 1998;88:237-42.
4. Brodbelt A, Stoodley M. CSF pathways: A review. *Br J Neurosurg* 2007;21:510-20.
5. Chumas PD, Armstrong DC, Drake JM, Kulkarni AV, Hoffman HJ, Humphreys RP, et al. Tonsillar herniation: The rule rather than the exception after lumboperitoneal shunting in the pediatric population. *J Neurosurg* 1993;78:568-73.
6. El-Saadany WF, Farhoud A, Zidan I. Lumboperitoneal shunt for idiopathic intracranial hypertension: Patients' selection and outcome. *Neurosurg Rev* 2012;35:239-44.
7. Fang Z, Tian R, Jia YT, Xu TT, Liu Y. Treatment of cerebrospinal fluid leak after spine surgery. *Chin J Traumatol* 2017;20:81-3.
8. Ferrante E, Trimboli M, Rubino F. Spontaneous intracranial hypotension: Review and expert opinion. *Acta Neurol Belg* 2020;120:9-18.
9. Luetmer PH, Schwartz KM, Eckel LJ, Hunt CH, Carter RE, Diehn FE. When should I do dynamic CT myelography? Predicting fast spinal CSF leaks in patients with spontaneous

- intracranial hypotension. *Am J Neuroradiol* 2012;33:690-4.
10. Mokri B. Spontaneous intracranial hypotension. *Continuum (Minneapolis Minn)* 2015;21:1086-108.
 11. Nikić I, Radoš M, Frobe A, Vukić M, Orešković D, Klarica M. The effects of lumboperitoneal and ventriculoperitoneal shunts on the cranial and spinal cerebrospinal fluid volume in a patient with idiopathic intracranial hypertension. *Croat Med J* 2016;57:293-7.
 12. Sakka L, Coll G, Chazal J. Anatomy and physiology of cerebrospinal fluid. *Eur Ann Otorhinolaryngol Head Neck Dis* 2011;128:309-16.
 13. Shahab S, Soliman MA, Alkhamees AF, Eaton S, Quint E, Im J, *et al.* Surgical intervention for spontaneous intracranial hypotension Type 4 CSF leak: A case report. *Surg Neurol Int* 2020;11:421.
 14. Starling A, Hernandez F, Hoxworth JM, Trentman T, Halker R, Vargas BB, *et al.* Sensitivity of MRI of the spine compared with CT myelography in orthostatic headache with CSF leak. *Neurology* 2013;81:1789-92.
 15. Toma AK, Dherijha M, Kitchen ND, Watkins LD. Use of lumboperitoneal shunts with the Strata NSC valve: A single-center experience. *J Neurosurg* 2010;113:1304-8.
 16. Welch K, Pollay M. The spinal arachnoid villi of the monkeys *Cercopithecus aethiops sabaesus* and *Macaca irus*. *Anat Record* 1963;145:43-8.
 17. Yadav YR, Parihar V, Sinha M. Lumbar peritoneal shunt. *Neurol India* 2010;58:179.

How to cite this article: Bakhsh A, Elmolla M, Buxton N, Brodbelt A. Chronic CSF leak from lumbar-peritoneal shunt tract: A case report. *Surg Neurol Int* 2022;13:205.