






CLINICAL REPORT

A novel *SPINK5* donor splice site variant in a child with Netherton syndrome

Dillon Mintoff¹  | Isabella Borg^{2,3,4}  | Julia Vornweg⁵  | Liam Mercieca¹ |
Rijad Merdzanic⁶ | Johannes Numrich⁶ | Susan Aquilina¹ | Nikolai Paul Pace⁴  |
Judith Fischer⁵ 

¹Department of Dermatology, Mater Dei Hospital, Msida, Malta

²Department of Pathology, Faculty of Medicine and Surgery, University of Malta, Msida, Malta

³Medical Genetics Unit, Department of Pathology, Mater Dei Hospital, Msida, Malta

⁴Centre for Molecular Medicine and Biobanking, Faculty of Medicine and Surgery, University of Malta, Msida, Malta

⁵Institute of Human Genetics, Medical Center – University of Freiburg, Faculty of Medicine, University of Freiburg, Freiburg im Breisgau, Germany

⁶CENTOGENE AG, Rostock, Germany

Correspondence

Dillon Mintoff, Dermatology OP, Outpatients Department, Level -1, Mater Dei Hospital, Triq id-Donaturi tad-Demm, MSD 2090 Msida, Malta.
Email address: dillon.mintoff@gov.mt

Abstract

Background: Netherton syndrome (NS) is a genodermatosis caused by loss-of-function mutations in *SPINK5*, resulting in aberrant LEKTI expression.

Method: Next-generation sequencing of *SPINK5* (NM_001127698.1) was carried out and functional studies were performed by immunofluorescence microscopy of a lesional skin biopsy using anti-LEKTI antibodies.

Results: We describe a novel *SPINK5* likely pathogenic donor splice site variant (NM_001127698.1:c.2015+5G>A) in a patient with NS and confirm its functional significance by demonstrating complete loss of LEKTI expression in lesional skin by immunofluorescence analysis.

Conclusion: The 2015+5G>A is a novel, likely pathogenic variant in NS. Herein we review and assimilate documented *SPINK5* pathogenic variants and discuss possible genotype–phenotype associations in NS.

KEY WORDS

LEKTI, Netherton syndrome, *SPINK5*, Splice donor site pathogenic variant

1 | INTRODUCTION

Netherton syndrome (NS) (OMIM #256500; ORPHA:634) is an autosomal recessive genodermatosis characterized by congenital ichthyosiform erythroderma, trichorrhexis invaginata (TI), and an atopic diathesis (Netherton, 1958), with an incidence estimated at 1/200,000 births. The condition is caused by pathogenic variants in *SPINK5* on chromosome 5q32 (Chavanas, Garner, et al., 2000) that code for

the Lymphoepithelial Kazal Type Inhibitor (LEKTI) protease (Mägert et al., 1999). LEKTI is a 15-Domain Human Serine Protease Inhibitor (Serpine) (Mägert et al., 1999) that is strongly expressed in the granular and spinous layer of cutaneous epithelium (Bitoun et al., 2003; Hachem et al., 2006), as well as lymphatic tissue such as the thymus and tonsil, and other mucosal epithelia (Mägert et al., 1999). In NS, *SPINK5* mutations lead to the decay and/or complete proteolytic breakdown of LEKTI (Raghunath et al., 2004) resulting

Funding: La Roche Posay partially contributed to open access publication.

This is an open access article under the terms of the Creative Commons Attribution-NonCommercial License, which permits use, distribution and reproduction in any medium, provided the original work is properly cited and is not used for commercial purposes.

© 2021 The Authors. *Molecular Genetics & Genomic Medicine* published by Wiley Periodicals LLC.

in the unabated activation of kallikreins and dysfunctional epidermal homeostasis. Ultrastructurally, the stratum corneum exhibits premature degradation of corneodesmosomes (Chao et al., 2005; Hachem et al., 2006). Disrupted epidermal homeostasis manifests cutaneously as ichthyosiform erythroderma, ichthyosis linearis circumflexa (ILC), and eczematous changes.

About 200 cases of NS have been described. A diagnosis of NS should be considered in infants presenting with recalcitrant eczema, especially if associated with short stature, lusterless hair, recurrent skin infections, and/or food allergies in the setting of hyperIgEemia (Komatsu et al., 2002).

In this report, we describe a novel *SPINK5* likely pathogenic variant in a NS patient and review the established pathological variants in *SPINK5*.

2 | CLINICAL PRESENTATION

The patient is the younger of two siblings born to non-consanguineous parents of Maltese-Caucasian ethnicity. He was referred for a dermatological consultation at the age of 3 years for what was described as “generalized recalcitrant eczema” associated with hyperIgEemia, as well as IgE-proven allergies to egg-white albumen, soy, wheat, and nut mix. The patient did not have a personal or family history of asthma or allergic rhinitis.

The child was born at term by vaginal delivery. He did not demonstrate any skin pathology during the first days of life; however, 2 weeks postnatally, erythema and scaling of the skin were noted which subsequently progressed to involve approximately 75% of the body surface area. The patient also had required treatment with oral and intravenous antibiotics in view of recurrent cellulitis (mainly staphylococcal). No electrolyte disturbances were noted during in-patient care. The child maintained a weight-for-age development on the 25th centile, while his length-for-age growth hovered between the 2nd and 5th centiles. Apart from an older sister with Down syndrome, the patient's family history was unremarkable.

Clinical examination of the child at the age of 3 years revealed erythematous plaques with a double-edged scale characteristic of ILC involving 50% of his body surface area. ILC affected the trunk predominantly, and the limbs to a lesser extent (Figure 1). The hair was lusterless but the typical bamboo hairs TI were absent on trichoscopy. The nails and teeth were unremarkable. There were no concerns about his vision and hearing. The patient did not demonstrate any learning difficulties or neurological deficits. Prior to presentation at the dermatology clinic, various emollients, topical corticosteroids, and pimecrolimus cream had been prescribed for the treatment of his recalcitrant disease with only slight and temporary improvement. The parents recalled a significant improvement in the child's eczematous lesions during a

Key points

- Netherton syndrome is a genodermatosis caused by *SPINK5* mutations
- This article shows the functional proof for a novel homozygous *SPINK5* donor splice site variant and
- Expands and reviews the known *SPINK5* mutational spectrum and its potential phenotypic associations.

tailing-down course of oral prednisolone, but he experienced a rebound a couple of days after the course of steroids was completed. The patient's symptoms were controlled by liberal application of bland emollients and the use of antihistamines as required. The parents were encouraged to bring their son for urgent review upon suspecting cellulitis. Early skin swabbing for bacterial culture and judicious antibiotic treatment diminished the frequency and severity of episodes of cellulitis.

A diagnosis of Netherton syndrome was suspected and genetic studies were subsequently carried out.

3 | MATERIAL AND METHODS

3.1 | Genetic analysis

Written consent for genetic analysis was obtained from the parents. Peripheral blood samples were collected from the proband, parents, and sibling.

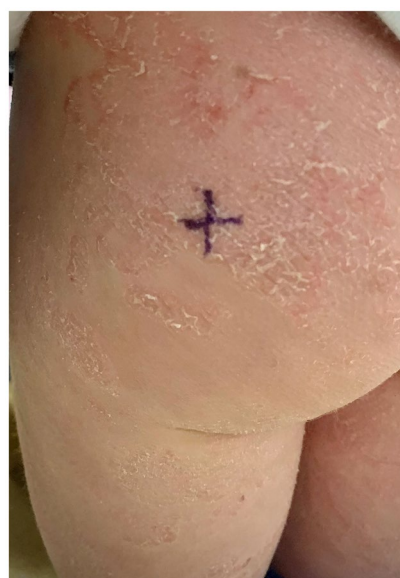

FIGURE 1 Ichthyosis linearis circumflexa. Typical double-edge scale in patients with NS. The cross indicates the biopsy site

Next-generation sequencing of *SPINK5* (NM_001127698.1) was carried out. Genomic DNA was enzymatically fragmented, and regions of interest enriched, using DNA capture probes targeted against the coding regions of *SPINK5*.

The captured library was subsequently sequenced on an Illumina® platform. A coverage depth of at least 50X was obtained for 100% of the targeted bases. Raw sequence data analysis, including base calling, demultiplexing, alignment to the hg19 human reference genome (Genome Reference Consortium GRCh37), and variant calling (single nucleotide variants, Indels, and copy number variations [CNVs]), was performed using validated in-house software. Analysis of the entire coding region of *SPINK5*, including 10 bp of flanking intronic sequences, was carried out. Segregation studies on the asymptomatic parents and sibling were performed using bidirectional Sanger sequencing of the identified *SPINK5* variant. Classification of the variant was according to established guidelines from the American College of Medical Genetics/Association for Molecular Pathology (ACMG/

AMP) (Richards et al., 2015). All analyses were performed in concordance with the provisions of the German Gene Diagnostic Act (Gendiagnostikgesetz).

A homozygous intronic variant (chromosome 5, position 147494057 in hg19 reference assembly) NM_001127698.1:c.2015+5 G>A was identified in *SPINK5* (Figure 2). The variant is predicted to disrupt the highly conserved donor splice site of intron 21 and is absent from healthy cohorts in homozygous state. The frequency of this variant in heterozygotes is extremely low (gnomAD: 0.000004, ESP: 0.000082) and the variant had not been detected previously in Centogene's database (CentoMD). No other clinically relevant variant was identified.

In the relatives, the *SPINK5* variant NM_001127698.1:c.2015+5G>A was identified in the heterozygous carrier state (Figure 3). This result also confirmed homozygosity of the variant identified in the patient.

In silico analysis using splice site prediction tools was implemented (Table S1). The predictions from different algorithms, namely the Human Splicing Finder (HSF),

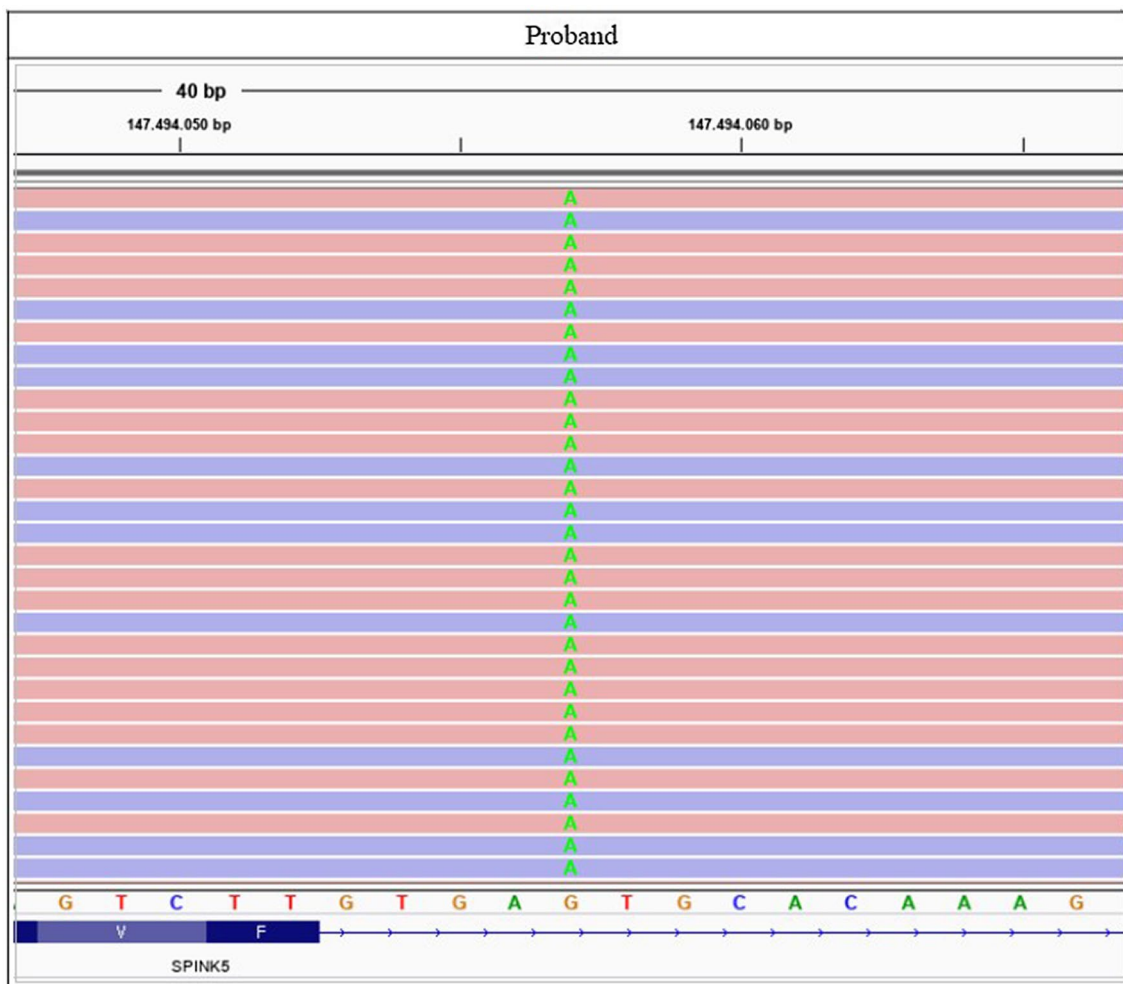


FIGURE 2 Excerpt from BAM file showing homozygous G>A base change at position c.2015+5(NM_001127698 *SPINK5* gene; Chr5(GRCh37):g.147494057G>A)




FIGURE 3 Chromatograms of Sanger sequencing. Sequences show heterozygous G>A base change at position c.2015+5 (NM_001127698 *SPINK5* gene)

MaxEntScan (MES), NNSplice, and NetGene2, showed that the substitution has deleterious predictions and is likely to alter the splicing mechanism through either exon skipping or the use of cryptic splice sites.

3.2 | Histology and Immunofluorescence

A 6 mm punch biopsy of lesional skin was obtained from the patient's left buttock (Figure 1). Histological examination of hematoxylin and eosin (H&E)-stained formalin-fixed paraffin-embedded (FFPE) sections revealed hyperkeratosis and epidermal thickening as well as reduction of keratohyalin granules in the stratum granulosum of the patient's skin (Figure 4).

LEKTI expression was subsequently evaluated by immunofluorescence microscopy using commercially available monoclonal antibodies (Primary antibodies: rabbit anti-LEKTI 1:200, HPA011351 by Sigma; rabbit anti-loricrin 1:500, ab24722 by Abcam) and secondary antibody (anti-rabbit IgG Fab2 Alexa Fluor R594 1:500). Immunofluorescence analysis demonstrated complete loss of

LEKTI protein, which is encoded by *SPINK5* (Figure 4). In view of a low 4',6-diamidino-2-phenylindole (DAPI) signal, a false negative result was excluded by positive loricrin staining (Figure S1).

The absence of immunoreactivity for LEKTI in the lesional skin supports the diagnosis of NS in the patient. Based on these findings, the NM_001127698.1:c.2015+5G>A substitution is classified as a likely pathogenic variant according to the ACMG, applying the criteria: PS3 (functional studies provide evidence for damaging effect on protein), PM2 (present at extremely low frequency in controls), PP3 (multiple lines of computational evidence support a deleterious effect on the gene or gene product—splicing impact), and PP4 (patient's phenotype or family history is highly specific for a disease with a single genetic etiology) (Richards et al., 2015).

4 | DISCUSSION

In this report, we describe a novel homozygous *SPINK5* donor splice site variant in intron 21 leading to absent LEKTI expression in the epidermis.

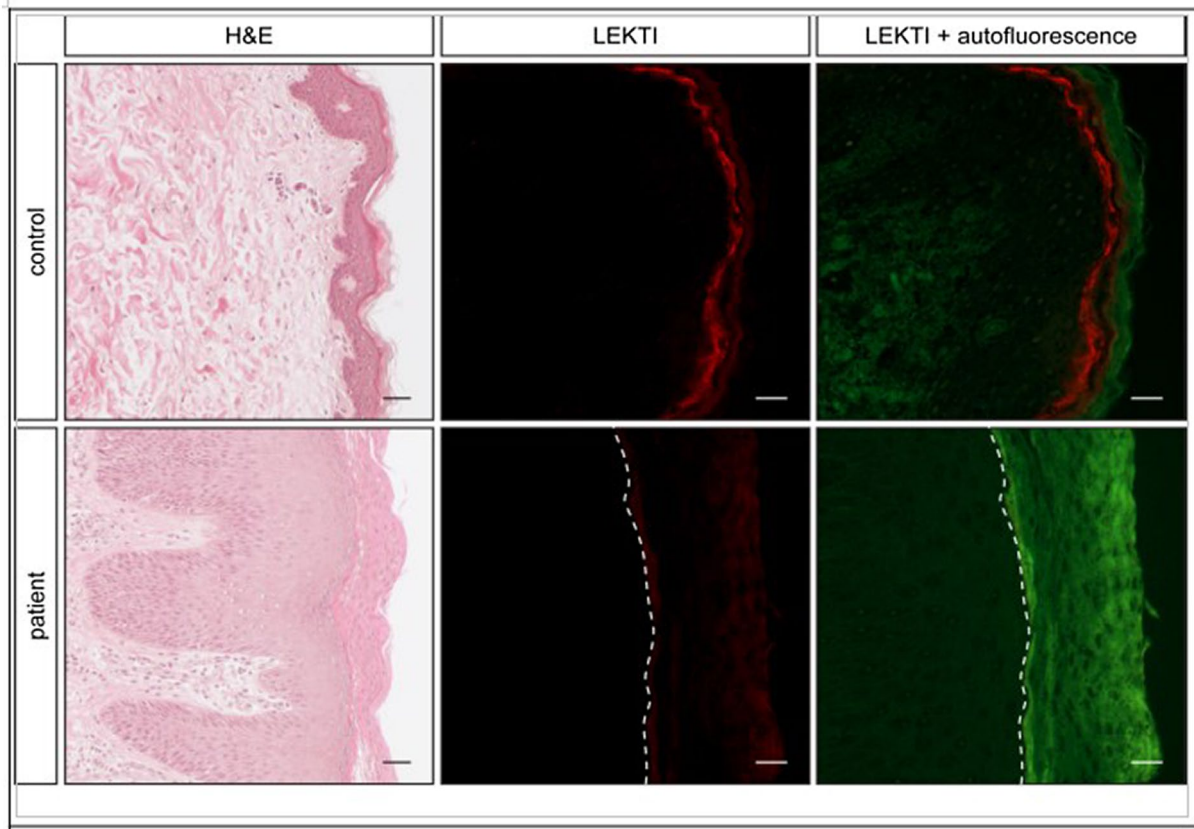


FIGURE 4 Histopathological and immunofluorescence analysis of control and patient's skin. Hematoxylin and eosin (H&E) staining of patient's skin shows hyperkeratosis, epidermal thickening, and reduction of the basophilic keratohyalin granules (40 μ m). Immunofluorescence revealed no LEKTI signal in the individual carrying homozygous *SPINK5* c.2015+5G>A variant (20 μ m)

Many pathogenic exonic and intronic *SPINK5* variants have been described, the majority being loss-of-function, nonsense, or frameshift variants. These variants are summarized in Table 1. Complete *SPINK5* deletions have also been described (Hachem et al., 2006). Most *SPINK5* pathogenic variants in NS patients from the Mediterranean region are exonic, including the commonest mutation; c.891C>T (p.Cys297Cys) in exon 11 (Lacroix et al., 2012). This synonymous mutation induces incomplete exon skipping, resulting in residual LEKTI production and a relatively mild phenotype (Fortugno et al., 2012). The *SPINK5* variant c.2015+5G>A described in this report is intronic and the patient's non-consanguineous parents were both heterozygous carriers. Additionally, this variant was not detected in an in-house Maltese genome dataset.

The heterogeneous NS phenotype reported in the literature is due to variable expressivity of *SPINK5* variants, which would explain why robust genotype–phenotype associations have been difficult to establish (Bitoun et al., 2002; Komatsu et al., 2008; Lacroix et al., 2012). Pathophysiologically, the severity of cutaneous findings can be related to the extent of epidermal serpine activity. In patients exhibiting moderate to severe NS phenotypes, serpine activity extends across the superficial and

deep epidermis and includes degradation of Desmoglein 1 (Dsg1) and (to a lesser extent) Desmocollin 1 (Dsc1). Patients with a milder NS phenotype have serpine activity which is limited to the epidermis with preservation of Dsg1 and Dsc1 (Hachem et al., 2006). Homozygous frameshift and splicing pathogenic variants resulting in early truncation of LEKTI are more likely to be associated with a severe NS phenotype and potential lethality (Sprecher et al., 2001). Patients harboring pathogenic variants that generate transcripts allowing residual LEKTI synthesis exhibit a milder phenotype (Fortugno et al., 2012; Lacroix et al., 2012). For example, compound heterozygotes for the *SPINK5* p.Arg371Ter variant as well as compound heterozygotes for the c.375-376delAT *SPINK5* variant demonstrate milder NS phenotypes when compared to patients harboring these variants in their homozygous state. The latter may potentially result in lethal forms of the disease (Diociaiuti et al., 2013; Itoh et al., 2015). Similarly, a NS patient demonstrating heterozygosity for the *SPINK5* variants c.1431-12G>A and c.1816_1820+21delinsCT was described as having a severe clinical phenotype (erythroderma, hypotonia, hypernatremia, sepsis, and respiratory failure) (Śmigiel et al., 2016), while three patients (born to consanguineous parents) who were homozygous for the

TABLE 1 Published *SPINK5* pathogenic variants according to their location on the gene and the corresponding protein effect

| Location | Pathogenic variant | Protein effect | First Reported |
|----------|----------------------------|--------------------|----------------------------------|
| Exon | | | |
| 1 | c.20C>A | p.Ser7Ter | Bellon et al. (2020) |
| 3 | c.153delT | p.Gln52LysfsTer6 | Bellon et al. (2020) |
| 3 | c.136C>T | p.Gln46Ter | Sprecher et al. (2001) |
| 3 | c.153delT | p.Gln52LysfsTer6 | Chavanas, Bodemer, et al. (2000) |
| 3 | c.184A>T | p.Lys62Ter | Bellon et al. (2020) |
| 4 | c.238dupG | p.Ala80glyfsTer19 | Chavanas, Bodemer, et al. (2000) |
| 4 | c.286_269insT | p.Thr90IlefsTer9 | Descargues et al. (2006) |
| 5 | c.301A>T | p.Lys101Ter | Diociaiuti et al. (2016) |
| 5 | c.316_317delGA | p.Asp106TrpfsTer7 | Kogut et al. (2015) |
| 5 | c.318G>A | p.Asp106Ter | Xi-Bao et al. (2012) |
| 5 | c.354_357delTTGT | p.Cys119fs | Roedl et al. (2011) |
| 5 | c.355_357delTGinsGC | p.Cys119Ala | Renner et al. (2009) |
| 5 | c.378T>G | p.Tyr126Ter | Komatsu et al. (2002) |
| 5 | c.377_378delAT | p.Tyr126Ter | Bitoun et al. (2002) |
| 5 | c.389_392dupCTGC | p.Leu132CysfsTer5 | Sprecher et al. (2001) |
| 5 | c.399_400delTG | p.Ala134Ter | Raghunath et al. (2004) |
| 5 | c.307G>T | p.Gly103Ter | Sprecher et al. (2001) |
| 6 | c.474G>A | p.Gln158= | Numata et al. (2016) |
| 7 | c.581_582delGT | p.Cys194fsTer4 | Kilic et al. (2006) |
| 8 | c.628C>T | p.Arg210Ter | Bitoun et al. (2002) |
| 8 | c.649 C>T | p.Arg217Ter | Bitoun et al. (2002) |
| 8 | c.652C>T | p.Arg218Ter | Chavanas, Bodemer, et al. (2000) |
| 9 | c.691delC | p.Gln231LysfsTer2 | Sprecher et al. (2004) |
| 9 | c.715dupT | p.Cys239fs | Raghunath et al. (2004) |
| 9 | c.720_721InsT | p.Arg241fs | Chavanas, Bodemer, et al. (2000) |
| 9 | c.724G>T | p.Glu242Ter | LOVD Database |
| 10 | c.803G>A | p.Arg268Cys | Lin et al. (2007) |
| 11 | c.891C>T | p.Cys297= | Lacroix et al. (2012) |
| 11 | c.900T>G | p.Tyr300Ter | Roedl et al. (2011) |
| 11 | c.957_960dupTGGT | p.Pro321TrpfsTer23 | Alpigiani et al. (2012) |
| 11 | c.966_967insC | p.Gly323fs | Mizuno et al. (2006) |
| 11 | c.995delT | p.Met332fs | Nebet et al. (2017) |
| 11 | c.997C>T | p.Gln333Ter | Fong et al. (2011) |
| 12 | c.1024ins5 | p.Lys344fs | Sprecher et al. (2001) |
| 12 | c.1036insG(A) ₄ | p.Lys346ArgfsTer4 | Bitoun et al. (2002) |
| 12 | c.1048C>T | p.Arg350Ter | Macknet et al. (2008) |
| 12 | c.1086delAT | p.Tyr363CysfsTer6 | Chavanas, Bodemer, et al. (2000) |
| 13 | c.1111C>T | p.Arg371Ter | Bitoun et al. (2002) |
| 15 | c.1258G>A | p.Glu420Lys | Ilias et al. (2015) |
| 15 | c.1320C>G | p.Tyr440Ter | Bellon et al. (2020) |
| 15 | c.1346_1352insT | p.Cys451LeufsTer5 | Renner et al. (2009) |
| 16 | c.1432C>T | p.Gln478Ter | LOVD Database |
| 16 | c.1476delA | p.Arg899Ter | Nijman et al. (2014) |

(Continues)

TABLE 1 (Continued)

| Location | Pathogenic variant | Protein effect | First Reported |
|---|-------------------------|--------------------------|---|
| 17 | c.1530C>A | p.Cys510Ter | Skoczen et al. (2020) Zelieskova et al. (2020) |
| 18 | c.1621G>T | p.Glu541Ter | Komatsu et al. (2002) |
| 19 | c.1772delT | p.Leu591GlnfsTer124 | Hannula-Jouppi et al. (2016) |
| 19 | x.1732C>T | p.Arg578Ter | Sprecher et al. (2001) |
| 20 | c.1887G>C | p.Lys629Asn | Patel et al. (2020) |
| 21 | c.1913delT | p.Leu639CysfsTer76 | Roedl et al. (2011) |
| 22 | c.2039_2049del | p.Lys680ArgfsTer26 | Goujon et al. (2010) |
| 22 | c.2041delA | p.Arg681GlyfsTer34 | Bitoun et al. (2002) |
| 22 | c.2098G>T | p.Gly700Ter | Renner et al. (2009) |
| 23 | c.2137C>T | p.Gln713Ter | Shimomura et al. (2005) |
| 24 | c.2258dupG | p.Asn755fs | Chavanas, Bodemer, et al. (2000) |
| 24 | c.2260A>T | p.Lys754Ter | Chao et al. (2005) |
| 24 | c.2264dupA | p.Asn755LysfsTer2 | Sprecher et al. (2001) |
| 24 | c.2313G>A | p.Lys771= | Chavanas, Bodemer, et al. (2000) |
| 25 | c.2423C>T | p.Thr808Ile | Lin et al. (2007) |
| 25 | c.2368 C>T | p.Arg790Ter | Chavanas, Bodemer, et al. (2000) |
| 26 | c.2459_2468delA | p.Lys823ArgfsTer100 | Renner et al. (2009) |
| 26 | c.2468delA | p.Lys823ArgfsTer119 | Bitoun et al. (2002) |
| 26 | c.2468dupA | p.Lys824fs | Chavanas, Bodemer, et al. (2000) |
| 26 | c.2471_2474delAAGA | p.Lys824ArgfsTer99 | Bellon et al. (2020) |
| 26 | c.2471_2475delAAGAG | p.Lys824ArgfsTer2 | Goujon et al. (2010) |
| 26 | c.2473-4delGA | p.Glu825GlyfsTer1 | Renner et al. (2009) |
| 26 | c.2487_2490dupGAGC | p.Asn831GlnfsTer15 | Nijman et al. (2014) |
| 27 | c.2557C>T | p.Arg853Ter | Lacroix et al. (2012) |
| 27 | c.2579_2587delAGCTTATCT | p.Lys860_Cys863delinsSer | Sprecher et al. (2001) |
| 28 | c.2677delG | p.Ala893LeufsTer49 | Patel et al. (2020) |
| Intronic Variants Causing Splicing Defects | | | |
| Intron | | | |
| 2 | c.81+5G>A | | Bitoun et al. (2002) |
| 2 | c.81+2T>A | | Sprecher et al. (2001) |
| 4 | c.283-12T>A | | Lacroix et al. (2012) |
| 4 | c.283-2 A > T | | Chavanas, Bodemer, et al. (2000) |
| 4 | c.410+1G>A | | Renner et al. (2009) |
| 6 | c.475-2 G>A | | Sprecher et al. (2001) |
| 8 | c.603+1G>A | | Renner et al. (2009) |
| 9 | c.794+6T>C | | LOVD database |
| 11 | c.1010+7A>G | | Bellon et al. (2020) |
| 12 | c.1092+5G>A | | Bellon et al. (2020) |
| 14 | c.1302+4A>T | | Hachem et al. (2006) |
| 15 | c.1430+2T>G | | Zhao et al. (2007) |
| 15 | c.1431-12G>A | | Renner et al. (2009) |
| 15 | c.1432-13G>A | | Raghunath et al. (2004) |
| 17 | c.1607+2T>C | | Diociaiuti et al. (2016) |

(Continues)

TABLE 1 (Continued)

| Intron | Intronic Variants Causing Splicing Defects | |
|--------|--|----------------------------------|
| 17 | c.1608-1 G>A | Bitoun et al. (2002) |
| 19 | c.1816-1820+21delinsCT | Śmigiel et al. (2016) |
| 19 | c.1820+53G>A | Lacroix et al. (2012) |
| 20 | c.1888-1G>A | Chavanas, Bodemer, et al. (2000) |
| 21 | c.2015+5 G>A | <i>Present</i> |
| 22 | c.2112+2T>A | Özyurt et al. (2019) |
| 22 | c.2108_2112+4delCTCAGGTGA | Sprecher et al. (2001) |
| 22 | c.2212+1G>A | Sprecher et al. (2001) |
| 23 | c.2240+1 G>A | Sprecher et al. (2001) |
| 23 | c.2240+5G>A | Israeli et al. (2014) |
| 25 | c.2441+3delGAGT | Tüysüz et al. (2010) |

c.1431-12G>A *SPINK5* variant exhibited a lethal form of disease (Capri et al., 2011). It is important to note that these inferences are non-dogmatic, especially since NS patients, who are homozygous for more upstream nonsense mutations than the aforementioned (such as c.997C>T), exhibit a milder, non-lethal form of NS (Fong et al., 2011). With regard to LEKTI expression, some intronic *SPINK5* variants, such as c.1820+53G>A and c.283-12T>A, are described as “leaky” as they do not abolish normal splicing in its entirety thereby allowing for a low-level production of the protein (Lacroix et al., 2012).

In a study of five Japanese NS patients, early correlations have been claimed between genotype and cutaneous severity, growth retardation, and frequency of infections. However, such association could not be made for the occurrence of allergic disease, TI, sweat secretion, and temperature homeostasis (Komatsu et al., 2008). Similarly, conflicting results were obtained in a larger study of 21 NS families where no genotype–phenotype associations were established (Bitoun et al., 2002).

The absence of epidermal LEKTI expression demonstrated in this study should be correlated with evidence from in vitro assays, including *SPINK5* mRNA expression studies to identify nonsense-mediated decay and analysis of LEKTI activity by in situ zymography. Potentially, additional insight into variant pathogenicity can be obtained through targeted editing of cell lines with the use of CRISPR-Cas9 techniques. Recently, *SPINK5*-knockout keratinocyte clones were successfully made to re-express *SPINK5* through treatment with lentiviral vectors of the gene, reverting NS skin to normal skin phenotype both in vivo and in vitro (Gálvez et al., 2020).

Apart from cutaneous and hair manifestations, patients with NS exhibit atopic and allergic tendencies. Several loci influencing serum IgE levels lie in close proximity to *SPINK5* on 5q31.3 (Meyers et al., 1994). The common

c.1258G>A missense variant has been associated with atopy and atopic dermatitis in NS families (Walley et al., 2001). In the perinatal period, infants with NS are also susceptible to growth failure and electrolyte disturbances. The latter is partly due to lamellar barrier dysfunction as a result of the proteolytic degradation of extracellular hydrolases such as β -glucocerebrosidase and acidic sphingomyelinase (Hachem et al., 2006).

Despite the severe skin barrier dysfunction, most NS patients survive to adulthood, with compensatory mechanisms such as the upregulation of Desmoglein (Dsg3), Desmocollin 3 (Dsc3), and lamellar body secretion coming into play, protecting against water loss and skin fragility (Hachem et al., 2006).

Due to the varied phenotypic manifestations in patients with NS, severity is difficult to score objectively. Attempts at creating a NS-severity scoring system have been made whereby patients are scored according to the area of skin involvement, severity of hair shaft abnormalities, serum IgE levels, and other associated features of NS (Sprecher et al., 2001). This scoring system has not been reproduced in other studies.

In summary, none of the few attempts made at identifying genotype–phenotype associations in NS have been conclusive or replicated. This can be partly explained by the lack of a universally accepted NS severity classification as well as the variable expressivity of *SPINK5* mutations and the extent of the compensatory molecular mechanisms at play.

5 | CONCLUSION

We have identified a novel *SPINK5* c.2015+5G>A likely pathogenic variant in a Maltese family thus expanding the *SPINK5* mutational spectrum. The characterization of this c.2015+5G>A likely pathogenic variant in a Mediterranean

island population where a high propensity for founder effects exists warrants further investigation. The functional evaluation of *SPINK5* variants of unknown significance is often necessary and may be obtained through immunohistochemical analysis which helps elucidate pathogenicity.

AUTHOR CONTRIBUTIONS

DM, IB, NPP conceived the design and wrote the paper. JV, RM, JN and JF contributed analysis tools. All authors contributed data and revised the manuscript.

INFORMED CONSENT

The patient's legal guardians (parents) have given explicit, informed consent for the publication of the case details, for which we thank them.

DATA AVAILABILITY STATEMENT

The data that support the findings of this study are available in the text and supplementary material of this article.

ORCID

Dillon Mintoff  <https://orcid.org/0000-0003-3705-0119>

Isabella Borg  <https://orcid.org/0000-0003-0639-3055>

Julia Vornweg  <https://orcid.org/0000-0001-9808-4983>

Nikolai Paul Pace  <https://orcid.org/0000-0002-7332-874X>

Judith Fischer  <https://orcid.org/0000-0002-8580-8118>

REFERENCES

- Alpigiani, M. G., Salvati, P., Schiaffino, M. C., Occella, C., Castiglia, D., Covaciu, C., & Lorini, R. (2012). A new *SPINK5* mutation in a patient with Netherton syndrome: A case report. *Pediatric Dermatology*, *29*(4), 521–522. <https://doi.org/10.1111/j.1525-1470.2011.01525.x>
- Bellon, N., Hadj-Rabia, S., Moulin, F., Lambe, C., Lezmi, G., Charbit-Henrion, F., Alby, C., Le Saché-de Peuffeilhoux, L., Leclerc-Mercier, S., Hadchouel, A., Steffann, J., Hovnanian, A., Lapillonne, A., & Bodemer, C. (2020). The challenging management of a series of 43 infants with Netherton syndrome: Unexpected complications and novel mutations. *British Journal of Dermatology*. <https://doi.org/10.1111/bjd.19265>
- Bitoun, E., Chavanas, S., Irvine, A. D., Lonie, L., Bodemer, C., Paradisi, M., Hamel-Teillac, D., Ansai, S.-I., Mitsuhashi, Y., Taïeb, A., de Prost, Y., Zambruno, G., Harper, J. I., & Hovnanian, A. (2002). Netherton syndrome: Disease expression and spectrum of *SPINK5* mutations in 21 families. *The Journal of Investigative Dermatology*, *118*(2), 352–361. <https://doi.org/10.1046/j.1523-1747.2002.01603.x>
- Bitoun, E., Micheloni, A., Lamant, L., Bonnart, C., Tartaglia-Polcini, A., Cobbold, C., Al Saati, T., Mariotti, F., Mazereeuw-Hautier, J., Boralevi, F., & Hohl, D. (2003). LEKTI proteolytic processing in human primary keratinocytes, tissue distribution and defective expression in Netherton syndrome. *Human Molecular Genetics*, *12*(19), 2417–2430. <https://doi.org/10.1093/hmg/ddg247>
- Capri, Y., Vanlieferinghen, P., Boeuf, B., Dechelotte, P., Hovnanian, A., & Lecomte, B. (2011). A lethal variant of Netherton syndrome in a large inbred family. *Archives De Pédiatrie: Organe Officiel De La Société Française De Pédiatrie*, *18*(3), 294–298. <https://doi.org/10.1016/j.arcped.2010.12.005>
- Chao, S.-C., Richard, G., & Lee, J.-Y.-Y. (2005). Netherton syndrome: Report of two Taiwanese siblings with staphylococcal scalded skin syndrome and mutation of *SPINK5*. *British Journal of Dermatology*, *152*(1), 159–165. <https://doi.org/10.1111/j.1365-2133.2005.06337.x>
- Chavanas, S., Bodemer, C., Rochat, A., Hamel-Teillac, D., Ali, M., Irvine, A. D., Bonafé, J.-L., Wilkinson, J., Taïeb, A., Barrandon, Y., Harper, J. I., de Prost, Y., & Hovnanian, A. (2000). Mutations in *SPINK5*, encoding a serine protease inhibitor, cause Netherton syndrome. *Nature Genetics*, *25*(2), 141–142. <https://doi.org/10.1038/75977>
- Chavanas, S., Garner, C., Bodemer, C., Ali, M., Teillac, D. H., Wilkinson, J., Bonafé, J.-L., Paradisi, M., Kelsell, D. P., Ansai, S.-I., Mitsuhashi, Y., Larrègue, M., Leigh, I. M., Harper, J. I., Taïeb, A., Prost, Y. D., Cardon, L. R., & Hovnanian, A. (2000). Localization of the Netherton syndrome gene to chromosome 5q32, by linkage analysis and homozygosity mapping. *American Journal of Human Genetics*, *66*(3), 914–921.
- Descargues, P., Deraison, C., Prost, C., Fraïtag, S., Mazereeuw-Hautier, J., D'Alessio, M., Ishida-Yamamoto, A., Bodemer, C., Zambruno, G., & Hovnanian, A. (2006). Corneodesmosomal cadherins are preferential targets of stratum corneum trypsin- and chymotrypsin-like hyperactivity in Netherton syndrome. *The Journal of Investigative Dermatology*, *126*(7), 1622–1632. <https://doi.org/10.1038/sj.jid.5700284>
- Diociaiuti, A., Castiglia, D., Fortugno, P., Bartuli, A., Pascucci, M., Zambruno, G., & El Hachem, M. (2013). Lethal Netherton syndrome due to homozygous p.Arg371X mutation in *SPINK5*. *Pediatric Dermatology*, *30*(4), e65–e67. <https://doi.org/10.1111/pde.12076>
- Diociaiuti, A., El Hachem, M., Pisaneschi, E., Giancristoforo, S., Genovese, S., Sirleto, P., Boldrini, R., & Angioni, A. (2016). Role of molecular testing in the multidisciplinary diagnostic approach of ichthyosis. *Orphanet Journal of Rare Diseases*, *11*, 4. <https://doi.org/10.1186/s13023-016-0384-4>
- Fong, K., Akdeniz, S., Isi, H., Taskesen, M., McGrath, J. A., & Lai-Cheong, J. E. (2011). New homozygous *SPINK5* mutation, p.Gln333X, in a Turkish pedigree with Netherton syndrome. *Clinical and Experimental Dermatology*, *36*(4), 412–415. <https://doi.org/10.1111/j.1365-2230.2010.03976.x>
- Fortugno, P., Grosso, F., Zambruno, G., Pastore, S., Faletra, F., & Castiglia, D. (2012). A synonymous mutation in *SPINK5* exon 11 causes Netherton syndrome by altering exonic splicing regulatory elements. *Journal of Human Genetics*, *57*(5), 311–315. <https://doi.org/10.1038/jhg.2012.22>
- Gálvez, V., Chacón-Solano, E., Bonafont, J., Mencía, Á., Di, W.-L., Murillas, R., Llames, S., Vicente, A., Del Rio, M., Carretero, M., & Larcher, F. (2020). Efficient CRISPR-Cas9-mediated gene ablation in human keratinocytes to recapitulate genodermatoses: Modeling of Netherton syndrome. *Molecular Therapy - Methods & Clinical Development*, *18*, 280–290. <https://doi.org/10.1016/j.omtm.2020.05.031>

- Goujon, E., Beer, F., Fraitag, S., Hovnanian, A., & Vabres, P. (2010). "Matchstick" eyebrow hairs: A dermoscopic clue to the diagnosis of Netherton syndrome. *Journal of the European Academy of Dermatology and Venereology*, 24(6), 740–741. <https://doi.org/10.1111/j.1468-3083.2009.03459.x>
- Hachem, J.-P., Wagberg, F., Schmutz, M., Crumrine, D., Lissens, W., Jayakumar, A., Houben, E., Mauro, T. M., Leonardsson, G., Brattsand, M., Egelrud, T., Roseeuw, D., Clayman, G. L., Feingold, K. R., Williams, M. L., & Elias, P. M. (2006). Serine protease activity and residual LEKTI expression determine phenotype in Netherton syndrome. *The Journal of Investigative Dermatology*, 126(7), 1609–1621. <https://doi.org/10.1038/sj.jid.5700288>
- Hannula-Jouppi, K., Laasanen, S. L., Ilander, M., Furio, L., Tuomiranta, M., Marttila, R., Jeskanen, L., Häyry, V., Kanerva, M., Kivirikko, S., & Tuomi, M. L. (2016). Intrafamily and interfamilial phenotype variation and immature immunity in patients with Netherton syndrome and Finnish SPINK5 founder mutation. *JAMA Dermatology*, 152(4), 435–442. <https://doi.org/10.1001/jamadermatol.2015.5827>
- Ilias, C., Evgenia, B., Aikaterini, P., Asimina, G.-T., Constantina, S., Maria, L., George, M., Paraskevi, K., Christos, T., Zissis, M., & Nikolaos, N. (2015). Netherton syndrome in a neonate with possible growth hormone deficiency and transient hyperaldosteronism. *Case Reports in Pediatrics*, 2015, 818961. <https://doi.org/10.1155/2015/818961>
- Israeli, S., Sarig, O., Garty, B. Z., Indelman, M., Bergman, R., Sprecher, E., & Goldberg, I. (2014). Molecular analysis of a series of Israeli families with Comèl-Netherton syndrome. *Dermatology*, 228(2), 183–188. <https://doi.org/10.1159/000357560>
- Itoh, K., Kako, T., Suzuki, N., Sakurai, N., Sugiyama, K., & Yamanishi, K. (2015). Severe lethal phenotype of a Japanese case of Netherton syndrome with homozygous founder mutations of SPINK5 c.375_376delAT. *Journal of Dermatology*, 42(12), 1212–1214. <https://doi.org/10.1111/1346-8138.13090>
- Kilic, G., Guler, N., Ones, U., Tamay, Z., & Guzel, P. (2006). Netherton syndrome: Report of identical twins presenting with severe atopic dermatitis. *European Journal of Pediatrics*, 165(9), 594–597. <https://doi.org/10.1007/s00431-006-0141-0>
- Kogut, M., Salz, M., Hadaschik, E. N., Kohlhasse, J., & Hartmann, M. (2015). New mutation leading to the full variety of typical features of the Netherton syndrome. *JDDG: Journal Der Deutschen Dermatologischen Gesellschaft*, 13(7), 691–693. <https://doi.org/10.1111/ddg.12453>
- Komatsu, N., Saijoh, K., Jayakumar, A., Clayman, G. L., Tohyama, M., Suga, Y., Mizuno, Y., Tsukamoto, K., Taniuchi, K., Takehara, K., & Diamandis, E. P. (2008). Correlation between SPINK5 gene mutations and clinical manifestations in Netherton syndrome patients. *The Journal of Investigative Dermatology*, 128(5), 1148–1159. <https://doi.org/10.1038/sj.jid.5701153>
- Komatsu, N., Takata, M., Otsuki, N., Ohka, R., Amano, O., Takehara, K., & Saijoh, K. (2002). Elevated stratum corneum hydrolytic activity in Netherton syndrome suggests an inhibitory regulation of desquamation by SPINK5-derived peptides. *The Journal of Investigative Dermatology*, 118(3), 436–443. <https://doi.org/10.1046/j.0022-202x.2001.01663.x>
- Lacroix, M., Lacaze-Buzy, L., Furio, L., Tron, E., Valari, M., Van der Wier, G., Bodemer, C., Bygum, A., Bursztejn, A.-C., Gaitanis, G., Paradisi, M., Stratigos, A., Weibel, L., Deraison, C., & Hovnanian, A. (2012). Clinical expression and new SPINK5 splicing defects in Netherton syndrome: Unmasking a frequent founder synonymous mutation and unconventional intronic mutations. *The Journal of Investigative Dermatology*, 132(3 Pt 1), 575–582. <https://doi.org/10.1038/jid.2011.366>
- Lin, S.-P., Huang, S.-Y., Tu, M.-E., Wu, Y.-H., Lin, C.-Y., Lin, H.-Y., & Lee-Chen, G.-J. (2007). Netherton syndrome: Mutation analysis of two Taiwanese families. *Archives of Dermatological Research*, 299(3), 145–150. <https://doi.org/10.1007/s00403-007-0751-z>
- Macknet, C. A., Morkos, A., Job, L., Garberoglio, M. C., Clark, R. D., Macknet, K. D., & Peverini, R. L. (2008). An infant with Netherton syndrome and persistent pulmonary hypertension requiring extracorporeal membrane oxygenation. *Pediatric Dermatology*, 25(3), 368–372. <https://doi.org/10.1111/j.1525-1470.2008.00685.x>
- Mägert, H.-J., Ständker, L., Kreutzmann, P., Zucht, H.-D., Reinecke, M., Sommerhoff, C. P., Fritz, H., & Forssmann, W.-G. (1999). LEKTI, a novel 15-domain type of human serine proteinase inhibitor. *Journal of Biological Chemistry*, 274(31), 21499–21502. <https://doi.org/10.1074/jbc.274.31.21499>
- Meyers, D. A., Postma, D. S., Panhuysen, C. I., Xu, J., Amelung, P. J., Levitt, R. C., & Bleeker, E. R. (1994). Evidence for a locus regulating total serum IgE levels mapping to chromosome 5. *Genomics*, 23(2), 464–470. <https://doi.org/10.1006/geno.1994.1524>
- Mizuno, Y., Suga, Y., Haruna, K., Muramatsu, S., Hasegawa, T., Kohroh, K., Shimizu, T., Komatsu, N., Ogawa, H., & Ikeda, S. (2006). A case of a Japanese neonate with congenital ichthyosiform erythroderma diagnosed as Netherton syndrome. *Clinical and Experimental Dermatology*, 31(5), 677–680. <https://doi.org/10.1111/j.1365-2230.2006.02207.x>
- Netherton, E. W. (1958). A unique case of trichorrhexis nodosa; Bamboo hairs. *Archives of Dermatology*, 78(4), 483–487. <https://doi.org/10.1001/archderm.1958.01560100059009>
- Nevet, M. J., Indelman, M., Ben-Ari, J., & Bergman, R. (2017). A case of Netherton syndrome with intestinal atresia, a novel SPINK5 mutation, and a fatal course. *International Journal of Dermatology*, 56(10), 1055–1057. <https://doi.org/10.1111/ijd.13730>
- Nijman, I. J., van Montfrans, J. M., Hoogstraat, M., Boes, M. L., van de Corput, L., Renner, E. D., van Zon, P., van Lieshout, S., Elferink, M. G., van der Burg, M., Vermont, C. L. (2014). Targeted next-generation sequencing: A novel diagnostic tool for primary immunodeficiencies. *The Journal of Allergy and Clinical Immunology*, 133(2), 529–534. <https://doi.org/10.1016/j.jaci.2013.08.032>
- Numata, S., Teye, K., Krol, R. P., Okamatsu, Y., Hashikawa, K., Matsuda, M., Fortugno, P., Di Zenzo, G., Castiglia, D., Zambruno, G., & Hamada, T. (2016). A compound synonymous mutation c.474G>A with p.Arg578X mutation in SPINK5 causes splicing disorder and mild phenotype in Netherton syndrome. *Experimental Dermatology*, 25(7), 568–570. <https://doi.org/10.1111/exd.13011>
- Özyurt, K., Atasoy, M., Ertaş, R., Ulaş, Y., Akkuş, M. R., Kiraz, A., & Hennies, H. C. (2019). Netherton syndrome previously misdiagnosed as hyper IgE syndrome caused by a probable mutation in SPINK5 C. *The Turkish Journal of Pediatrics*, 61(4), 604–607. <https://doi.org/10.24953/turkjp.2019.04.020>
- Patel, T. D., Padhiyar, J. K., Patel, N. H., & Trivedi, N. S. (2020). A case of netherton syndrome with novel mutation in SPINK5 gene expressing incomplete phenotype. *Indian Journal of Paediatric Dermatology*, 21(1), 73. https://doi.org/10.4103/ijpd.IJPD_76_19
- Raghunath, M., Tontsidou, L., Oji, V., Aufenvenne, K., Schürmeyer-Horst, F., Jayakumar, A., Ständer, H., Smolle, J., Clayman, G. L., & Traupe, H. (2004). SPINK5 and Netherton syndrome: Novel mutations, demonstration of missing LEKTI, and differential

- expression of transglutaminases. *The Journal of Investigative Dermatology*, 123(3), 474–483.
- Renner, E. D., Hartl, D., Rylaarsdam, S., Young, M. L., Monaco-Shawver, L., Kleiner, G., Markert, M. L., Stiehm, E. R., Belohradsky, B. H., Upton, M. P., Torgerson, T. R., Orange, J. S., & Ochs, H. D. (2009). Comèl-Netherton syndrome defined as primary immunodeficiency. *The Journal of Allergy and Clinical Immunology*, 124(3), 536–543. <https://doi.org/10.1016/j.jaci.2009.06.009>
- Richards, S., Aziz, N., Bale, S., Bick, D., Das, S., Gastier-Foster, J., Grody, W. W., Hegde, M., Lyon, E., Spector, E., Voelkerding, K., & Rehms, H. L. (2015). Standards and guidelines for the interpretation of sequence variants: A joint consensus recommendation of the American College of Medical Genetics and Genomics and the Association for Molecular Pathology. *Genetics in Medicine*, 17(5), 405–424. <https://doi.org/10.1038/gim.2015.30>
- Roedl, D., Oji, V., Buters, J. T. M., Behrendt, H., & Braun-Falco, M. (2011). rAAV2-mediated restoration of LEKTI in LEKTI-deficient cells from Netherton patients. *Journal of Dermatological Science*, 61(3), 194–198. <https://doi.org/10.1016/j.jdermsci.2010.12.004>
- Shimomura, Y., Sato, N., Kariya, N., Takatsuka, S., & Ito, M. (2005). Netherton syndrome in two Japanese siblings with a novel mutation in the SPINK5 gene: Immunohistochemical studies of LEKTI and other epidermal molecules. *British Journal of Dermatology*, 153(5), 1026–1030. <https://doi.org/10.1111/j.1365-2133.2005.06900.x>
- Skoczen, S., Stepień, K., Młynarski, W., Centkowski, P., Kwiecinska, K., Korostynski, M., Piechota, M., Wyrobek, E., Moryl-Bujakowska, A., Strojny, W., Rej, M., Kowalczyk, J., & Balwierz, W. (2020). Genetic signature of acute lymphoblastic Leukemia and Netherton syndrome co-occurrence—First report in the literature. *Frontiers in Oncology*, 9, 1447. <https://doi.org/10.3389/fonc.2019.01477>
- Śmigiel, R., Królak-Olejnik, B., Śniegórska, D., Rozensztrauch, A., Szafrńska, A., Sasiadek, M. M., & Wertheim-Tysarowska, K. (2016). Is c.1431-12G>A common European mutation of SPINK5? Report of a patient with Netherton syndrome. *Balkan Journal of Medical Genetics*, 19(2), 81–84. <https://doi.org/10.1515/bjmg-2016-0040>
- Sprecher, E., Amin, S., Nielsen, K., Pfendner, E., Uitto, J., Richard, G., Chavanas, S., DiGiovanna, J. J., Prendiville, J. S., Silverman, R., & Esterly, N. B. (2001). The spectrum of pathogenic mutations in SPINK5 in 19 families with Netherton syndrome: Implications for mutation detection and first case of prenatal diagnosis. *The Journal of Investigative Dermatology*, 117(2), 179–187. <https://doi.org/10.1046/j.1523-1747.2001.01389.x>
- Sprecher, E., Tesfaye-Kedjela, A., Ratajczak, P., Bergman, R., & Richard, G. (2004). Deleterious mutations in SPINK5 in a patient with congenital ichthyosiform erythroderma: Molecular testing as a helpful diagnostic tool for Netherton syndrome. *Clinical and Experimental Dermatology*, 29(5), 513–517. <https://doi.org/10.1111/j.1365-2230.2004.01589.x>
- Tüysüz, B., Ojalvo, D., Mat, C., Zambruno, G., Covaciu, C., Castiglia, D., & D'Alessio, M. (2010). A new SPINK5 donor splice site mutation in siblings with Netherton syndrome. *Acta Dermato Venereologica*, 90(1), 95–96. <https://doi.org/10.2340/00015555-0769>
- Walley, A. J., Chavanas, S., Moffatt, M. F., Esnouf, R. M., Ubhi, B., Lawrence, R., Wong, K., Abecasis, G. R., Jones, E. Y., Harper, J. I., Hovnanian, A., & Cookson, W. O. C. M. (2001). Gene polymorphism in Netherton and common atopic disease. *Nature Genetics*, 29(2), 175–178. <https://doi.org/10.1038/ng728>
- Xi-Bao, Z., San-Quan, Z., Yu-Qing, H., Yu-Wu, L., Quan, L., & Chang-Xing, L. (2012). Netherton syndrome in one Chinese adult with a novel mutation in the SPINK5 gene and immunohistochemical studies of LEKTI. *Indian Journal of Dermatology*, 57(4), 265–268. <https://doi.org/10.4103/0019-5154.97660>
- Zelieskova, M., Banovcin, P., Kozar, M., Kozarova, A., Nudzajova, Z., & Jesenak, M. (2020). A novel SPINK5 mutation and successful subcutaneous immunoglobulin replacement therapy in a child with Netherton syndrome. *Pediatric Dermatology*, 37(6), 1202–1204. <https://doi.org/10.1111/pde.14318>
- Zhao, Y., Ma, Z. H., Yang, Y. et al (2007). SPINK5 gene mutation and decreased LEKTI activity in three Chinese patients with Netherton's syndrome. *Clinical and Experimental Dermatology*, 32(5), 564–567. <https://doi.org/10.1111/j.1365-2230.2007.02438.x>

SUPPORTING INFORMATION

Additional supporting information may be found online in the Supporting Information section.

How to cite this article: Mintoff D, Borg I, Vornweg J, et al. A novel *SPINK5* donor splice site variant in a child with Netherton syndrome. *Mol Genet Genomic Med*. 2021;9:e1611. <https://doi.org/10.1002/mgg3.1611>