



Since January 2020 Elsevier has created a COVID-19 resource centre with free information in English and Mandarin on the novel coronavirus COVID-19. The COVID-19 resource centre is hosted on Elsevier Connect, the company's public news and information website.

Elsevier hereby grants permission to make all its COVID-19-related research that is available on the COVID-19 resource centre - including this research content - immediately available in PubMed Central and other publicly funded repositories, such as the WHO COVID database with rights for unrestricted research re-use and analyses in any form or by any means with acknowledgement of the original source. These permissions are granted for free by Elsevier for as long as the COVID-19 resource centre remains active.



Case Report

Acute pericarditis and severe acute respiratory syndrome coronavirus 2: Case report



Nikola R. Blagojevic^{a,*}, Dragana Bosnjakovic^a, Vladan Vukomanovic^a, Srdjan Arsenovic^a, Jelena Suzic Lazic^{a,b}, Marijana Tadic^a

^a University Clinical Center “Dr. Dragisa Misovic-Dedinje”, Belgrade, Serbia

^b Medical Faculty, University of Belgrade, Serbia

ARTICLE INFO

Article history:

Received 21 August 2020

Received in revised form 22 September 2020

Accepted 22 September 2020

Keywords:

Pericarditis

COVID-19

SARS-CoV-2

ABSTRACT

We present the case of a 51-year-old patient with acute pericarditis as the dominant manifestation of severe acute respiratory syndrome coronavirus 2 (SARS-CoV-2) infection. The patient was admitted to the emergency department during a coronavirus disease 2019 (COVID-19) outbreak with a suspected ST-elevation myocardial infarction. A coronary angiogram was normal. Real-time reverse transcriptase PCR for the detection of nucleic acid from SARS-CoV-2 in a nasopharyngeal swab was positive. Laboratory tests revealed an increased white blood cell count, with neutrophilia and lymphocytopenia, elevated level of C-reactive protein, borderline elevated erythrocyte sedimentation rate, and slightly elevated interleukin 6. Echocardiography showed a hyperechogenic pericardium posterolaterally with minimal localized pericardial effusion. A chest computed tomography scan showed a small zone of ground-glass opacity in the right lower lobe (classified as CO-RADS 3). In patients with chest pain, ST elevation on electrocardiogram, a normal coronary angiogram, and suspected COVID-19, we should think of pericarditis as an unusual presentation of SARS-CoV-2 infection.

© 2020 The Author(s). Published by Elsevier Ltd on behalf of International Society for Infectious Diseases. This is an open access article under the CC BY-NC-ND license (<http://creativecommons.org/licenses/by-nc-nd/4.0/>).

Introduction

The association between cardiovascular diseases and the new viral agent severe acute respiratory syndrome coronavirus 2 (SARS-CoV-2) has been a matter of debate since the coronavirus disease 2019 (COVID-19) pandemic began in Wuhan, China in December 2019. This issue has mainly concerned the prognosis and treatment of COVID-19 in patients with cardiovascular diseases (CVD) (Zeng et al., 2020; Tian-Yuan et al., 2020). On the other hand, several studies have suggested that SARS-CoV-2 might be an independent cause of myocardial damage in some patients through pathophysiological mechanisms that are not yet fully understood (Chen et al., 2020). Although the virus mainly induces lung injury, autopsy studies have confirmed that the heart, kidneys, vessels, liver, brain, and other organs may also be affected (Yao et al., 2020; Puelles et al., 2020; Cizgici et al., 2020; Hua et al., 2020; Kim et al., 2020; Doyen et al., 2020; Farina et al., 2020; Inciardi et al., 2020). Viral infections are the major cause of myocarditis and pericarditis in developed countries and it is also

evident that SARS-CoV-2 has cardiotropic properties. Most of the case reports published so far have investigated cardiac involvement in COVID-19 patients with severe respiratory tract infections (Zeng et al., 2020; Chen et al., 2020; Cizgici et al., 2020; Kim et al., 2020; Puelles et al., 2020; Hua et al., 2020; Doyen et al., 2020; Farina et al., 2020; Inciardi et al., 2020). The case of a patient with acute pericarditis as the dominant manifestation of SARS-CoV-2 infection is presented here.

Case report

A 51-year-old Caucasian male presented to the emergency department during a COVID-19 outbreak with a suspected ST-elevation myocardial infarction. The patient complained of sudden but persistent chest pain, which had developed 1 day before hospital admission. The pain was sharp, worsened with deep breathing or a change in body position, and was alleviated while sitting. The pain lasted for several hours during the night, but then gradually and spontaneously disappeared. He did not have any respiratory symptoms and denied respiratory or any other infection or acute illness in the previous 3 months.

Apart from hypertension in the previous 5 months, the patient's medical history was unremarkable. He was a non-smoker and he denied any substance abuse.

* Corresponding author at: Nikola Blagojevic, University Clinical Center “Dr. Dragisa Misovic-Dedinje”, Heroja Milana Tepica 1, 11000 Belgrade, Serbia
E-mail address: n.blagojevic0205@gmail.com (N.R. Blagojevic).

On admission, the patient was stable, subfebrile (37.1 °C), with a normal blood pressure (125/80 mmHg), regular heart rate (70 bpm), slight tachypnoea (18 per minute), and normal oxygen saturation on ambient air (98%). The remainder of the physical examination was unremarkable. An electrocardiogram (ECG) demonstrated sinus rhythm, minimal widespread ST elevation in leads D1, D2, aVL, aVF, and V2–V6, ST depression in leads D3 and aVR, and PR depression in leads D1, D2, aVF, and V2–V6 (Figure 1). Coronary angiography, which was performed on admission, was normal.

Laboratory tests revealed a white blood cell (WBC) count of $15.0 \times 10^9/l$ (normal range $4.0\text{--}10.0 \times 10^9/l$), with an elevated neutrophil count of $13.04 \times 10^9/l$ (normal range $2.06\text{--}6.49 \times 10^9/l$) and a low lymphocyte count of $0.85 \times 10^9/l$ (normal range $1.19\text{--}3.35 \times 10^9/l$), elevated levels of C-reactive protein (90.7 mg/l; cut off <6.0 mg/l), borderline elevated erythrocyte sedimentation rate (ESR) (14 mm/1 h), and a slightly elevated interleukin (IL)-6 of 8.7 pg/ml (<6.0 pg/ml). Other blood tests, including levels of high-sensitivity troponin I and other markers of myocardial injury, as well as N-terminal pro-brain natriuretic peptide (NT-proBNP), were within the normal ranges during the patient's entire hospitalization. Real-time reverse transcriptase PCR for the detection of nucleic acid from SARS-CoV-2 in a nasopharyngeal swab showed positive results and was followed by serology testing, which also returned positive for both IgM and IgG SARS-CoV-2 antibodies. Laboratory investigations for common cardiotropic viral agents (coxsackievirus, cytomegalovirus, adenovirus, and parvovirus) were negative.

Echocardiography showed a hyperechogenic pericardium posterolaterally with minimal localized pericardial effusion. The cardiac chambers were of normal size with normal left ventricular systolic function (left ventricular ejection fraction of 65%) and without regional wall abnormalities or more than mild valve disease. A chest computed tomography (CT) scan showed a small zone of ground-glass opacity in the right lower lobe, covering less than 5% of the volume of the lobe (according to the severity score index, 1 point out of a maximum of 5 for a given lobe and 25 for the lung as a whole), without any other pulmonary or upper abdomen pathology. According to the COVID-19 Reporting and Data System (CO-RADS) for the assessment of pulmonary involvement in

COVID-19 on a non-enhanced chest CT scan, the finding was classified as CO-RADS 3 (Prokop et al., 2020).

Considering the clinical presentation and the ECG, laboratory, and echocardiography findings, the patient was diagnosed with acute pericarditis caused by SARS-CoV-2 with suspected mild viral pneumonia. The treatment included lopinavir/ritonavir (200/50 mg twice daily), aspirin (100 mg once daily), a beta-blocker (bisoprolol 2.5 mg once daily), and an antibiotic (ceftriaxone 2 g once daily).

The patient was well and afebrile without chest pain or any respiratory symptoms during the hospital stay. Serial echocardiographic studies did not demonstrate any deterioration in left ventricular systolic function or increase in pericardial effusion. The ECG changes (ST and PR segments) gradually resolved and were followed by T wave inversion in lead D3. Laboratory markers of inflammation were normalized and the patient was discharged.

Discussion

The case presented here demonstrated a patient who was diagnosed in an acute phase of pericarditis caused by SARS-CoV-2. Although cardiac involvement has been described previously in patients with COVID-19 and massive pneumonia, to our knowledge this is a rare case describing cardiac involvement in SARS-CoV-2 infection in a patient with mild pneumonia (Farina et al., 2020; Inciardi et al., 2020).

Emerging evidence suggests that SARS-CoV-2 has a tropism for myocardium and pericardium. Myocardial injury, detected by the presence of elevated high-sensitivity troponin I, has been reported to occur in about 12% of patients with COVID-19, and the virus has also been isolated in the pericardial fluid of a patient with COVID-19-associated pericarditis and cardiac tamponade (Farina et al., 2020; Huang et al., 2020). However, previous reports are scarce and in the majority of cases pulmonary involvement in COVID-19 is dominant, accompanied by perimyocardial damage. In these patients, perimyocarditis was mainly diagnosed due to clinical deterioration caused by heart failure (Zeng et al., 2020; Chen et al., 2020; Cizgici et al., 2020; Farina et al., 2020).

It is well established that viral agents can cause perimyocarditis either by directly affecting the heart or through mechanisms

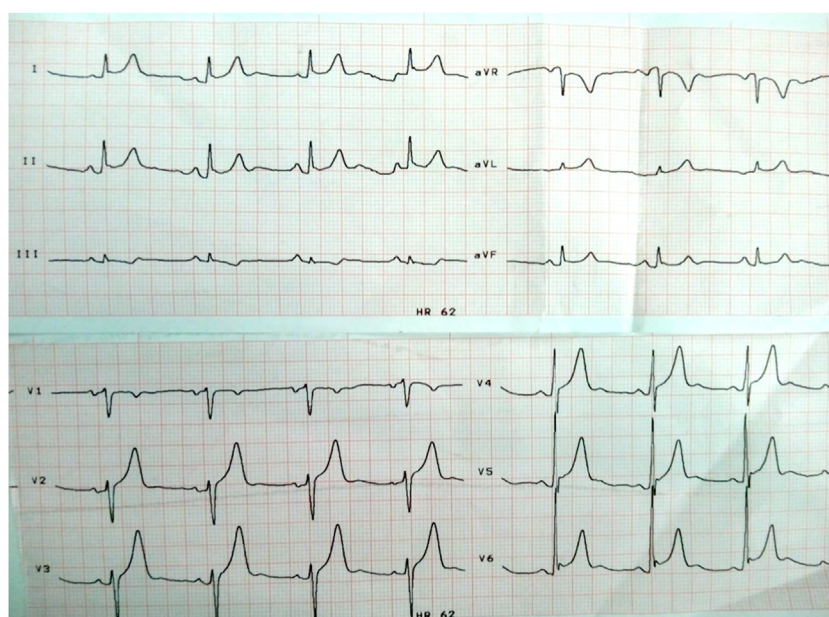


Figure 1. ECG on admission showing minimal widespread ST elevation in leads D1, D2, aVL, aVF, and V2–V6, ST depression in leads D3 and aVR, and PR depression in leads D1, D2, aVF, and V2–V6.

resulting from systemic inflammation during severe infections. The patient in the present case report had elevated levels of the proinflammatory cytokine IL-6, which is produced by immune cells in response to viral agents and appears to be an important mediator in the cytokine storm (Nishimoto and Kishimoto, 2006). Increased concentrations of IL-6 are also found in pericardial fluid in all forms of pericarditis (Ristić et al., 2013). Unlike previously published cases, the SARS-CoV-2 infection in our patient presented with dominantly pericardial involvement. The significance of early treatment with antiviral medication for the relatively benign course of the disease in our patient is to be established.

A limitation of this investigation is the lack of cardiac magnetic resonance imaging and pericardial biopsy that would have excluded myocarditis or confirmed pericarditis, respectively.

In conclusion, pericarditis should be considered in patients with chest pain, ST elevation on ECG, a normal coronary angiogram, and COVID-19. Accordingly, this atypical presentation of SARS-CoV-2 infection should not be forgotten. We emphasize the importance of clinical examination and ECG for decision-making in the setting of the COVID-19 epidemic. Future studies are needed to reveal in more detail the pathophysiological relationship between SARS-CoV-2 infection and the cardiovascular system, as well as the long-term outcomes of patients who have suffered perimyocardial damage due to SARS-CoV-2.

Funding source

This research did not receive any specific grant from funding agencies in the public, commercial, or not-for-profit sectors.

Ethical approval

Approval was obtained from the local ethics committee.

Conflict of interest

The authors declare that they have no known competing financial interests or personal relationships that could have appeared to influence the work reported in this paper.

Acknowledgements

This work was supported by the Ministry of Education and Science of the Republic of Serbia.

Appendix A. Supplementary data

Supplementary material related to this article can be found, in the online version, at doi:<https://doi.org/10.1016/j.ijid.2020.09.1440>.

References

- Chen C, Zhou Y, Wang DW. SARS-CoV-2: a potential novel etiology of fulminant myocarditis. *Herz* 2020;45(3):230–2, doi:<http://dx.doi.org/10.1007/s00059-020-04909-z>.
- Cizgici AY, ZencirkiranAgus H, Yildiz M. COVID-19 myopericarditis: it should be kept in mind in today's conditions [published online ahead of print, 2020 Apr 28]. *Am J Emerg Med* 2020;S0735–6757(20):30310–7, doi:<http://dx.doi.org/10.1016/j.ajem.2020.04.080>.
- Doyen D, Mocerri P, Ducreux D, Dellamonica J. Myocarditis in a patient with COVID-19: a cause of raised troponin and ECG changes. *Lancet* 2020;395(10235):1516.
- Farina A, Uccello G, Spreafico M, Bassanelli G, Savonitto S. SARS-CoV-2 detection in the pericardial fluid of a patient with cardiac tamponade [published online ahead of print, 2020 Apr 23]. *Eur J Intern Med* 2020;S0953–6205(20):30166–7, doi:<http://dx.doi.org/10.1016/j.ejim.2020.04.045>.
- Hua A, O'Gallagher K, Sado D, Byrne J. Life-threatening cardiac tamponade complicating myo-pericarditis in COVID-19. *Eur Heart J* 2020;(March):ehaa253, doi:<http://dx.doi.org/10.1093/eurheartj/ehaa253>.
- Huang C, et al. Clinical features of patients infected with 2019 novel coronavirus in Wuhan, China. *Lancet* 2020;395:497–506.
- Inciardi RM, Lupi L, Zaccone G, et al. Cardiac Involvement in a Patient With Coronavirus Disease 2019 (COVID-19) [published online ahead of print, 2020 Mar 27]. *JAMA Cardiol* 2020;, doi:<http://dx.doi.org/10.1001/jamacardio.2020.1096>.
- Kim IC, Kim JY, Kim HA, Han S. COVID-19-related myocarditis in a 21-year-old female patient. *Eur Heart J* 2020;41(19):1859, doi:<http://dx.doi.org/10.1093/eurheartj/ehaa288>.
- Nishimoto N, Kishimoto T. Interleukin 6: from bench to bedside [published correction appears in *Nat Clin Pract Rheumatol*. 2006 Dec;2(12):691]. *Nat Clin Pract Rheumatol* 2006;2(11):619–26, doi:<http://dx.doi.org/10.1038/ncprheum0338>.
- Prokop M, van Everdingen W, van Rees Vellinga T, et al. CO-RADS – A categorical CT assessment scheme for patients with suspected COVID-19: definition and evaluation [published online ahead of print, 2020 Apr 27]. *Radiology* 2020;201473, doi:<http://dx.doi.org/10.1148/radiol.2020201473>.
- Puelles VG, Lütgehetmann M, Lindenmeyer MT, Sperhake JP, Wong MN, Allweiss L, et al. Multiorgan and renal tropism of SARS-CoV-2. *N Engl J Med* 2020;(March), doi:<http://dx.doi.org/10.1056/NEJMc2011400> [Epub ahead of print].
- Ristić AD, Pankuweit S, Maksimović R, Moosdorf R, Maisch B. Pericardial cytokines in neoplastic, autoreactive, and viral pericarditis. *Heart Fail Rev* 2013;18(3):345–53, doi:<http://dx.doi.org/10.1007/s10741-012-9334-y>.
- Tian-Yuan Xiong, Simon Redwood, Bernard Prendergast, Mao Chen. Coronaviruses and the cardiovascular system: acute and long-term implications. *Eur Heart J* 2020;1:1–3, doi:<http://dx.doi.org/10.1093/eurheartj/ehaa231>.
- Yao XH, Li TY, He ZC, Ping YF, Liu HW, Yu SC, et al. A pathological report of three COVID-19 cases by minimal invasive autopsies. *Zhonghua Bing Li Xue Za Zhi* 2020;49(5):411–7.
- Zeng JH, Liu YX, Yuan J, et al. First case of COVID-19 complicated with fulminant myocarditis: a case report and insights [published online ahead of print, 2020 Apr 10]. *Infection* 2020;1–5, doi:<http://dx.doi.org/10.1007/s15010-020-01424-5>.