

How Trustworthy Are Clinical Examinations and Plain Radiographs for Diagnosis of Scaphoid Fractures?

Mohammad Reza Ghane,¹ Mohammad Saeid Rezaee-Zavareh,^{1,2,*} Mohammad Kazem

Emami-Meibodi,¹ and Vahid Dehghani²

¹Trauma Research Center, Baqiyatallah University of Medical Sciences, Tehran, IR Iran

²Students' Research Committee, Baqiyatallah University of Medical Science, Tehran, IR Iran

*Corresponding author: Mohammad Saeid Rezaee-Zavareh, Trauma Research Center, Baqiyatallah University of Medical Sciences, Tehran, IR Iran. Tel/Fax: +98-2181264354, E-mail: Dr_Rezaee@Live.com

Received 2014 September 26; Revised 2014 December 01; Accepted 2015 February 10.

Abstract

Background: Sometimes patients with a scaphoid fracture, especially in an acute phase of injury, can have normal radiographs and, therefore, initial diagnosis of the scaphoid fracture may be neglected. In this study, we determined the value in of clinical examination and a radiograph in the diagnosis of scaphoid fracture based on the results of a two-week follow-up magnetic resonance imaging (MRI).

Objectives: In this study, sought to assess the value of using both a clinical examination (tenderness of scaphoid tubercle, tenderness of anatomical snuffbox, and compression test) and radiographic imaging in the diagnosis of scaphoid fractures based on the results after a two-week follow-up MRI.

Patients and Methods: From December 2012 to February 2013, we enrolled 48 patients with suspected scaphoid fractures who had been referred to the emergency department of Baqiyatallah hospital, Tehran, Iran. Patients with negative results for clinical and radiographic examinations were excluded from the study. Cast immobilization was done for patients who had at least one positive finding during a physical examination test and who had normal radiographs. Patients who had a normal physical examination, but abnormal radiographs were referred to the orthopedic clinic after cast or split treatment. These patients also had a follow-up MRI two weeks after wrist trauma; the MRI was used to determine the sensitivity, specificity, positive predictive value (PPV), and negative predictive value (NPV) of the clinical and radiographic examinations.

Results: Scaphoid tubercle tenderness had a sensitivity of 95.23% and a specificity of 74.07% in the diagnosis of scaphoid fracture. This test did not show a statistically difference with MRI results ($P = 0.05$). The results of the tenderness of the anatomical snuff box (sensitivity = 85.71%, specificity = 29.62%) was statistically different from the MRI results ($P = 0.000$). The results for the sensitivity (42.85%) and specificity (29.62%) for a compression test were not statistically different from the MRI results ($P = 0.05$). All of the radiographic tests that we applied in our project had 100% specificity for the diagnosis of a scaphoid fracture. However, the results were significantly different from the MRI results ($P = 0.000$).

Conclusions: A clinical examination combined with a plain radiograph should be considered to improve the diagnostic precision for patients presenting with scaphoid fractures in an emergency department. In this way, both overtreatment and undertreatment of patients can be avoided.

Keywords: Scaphoid Bone, Fractures, Physical Examination, Magnetic Resonance Imaging, X-ray Film, Diagnosis

1. Background

The scaphoid, along with seven other bones, comprise the carpus (volarly) (1, 2). Branches of the radial artery feed the scaphoid, although the proximal lobe of the scaphoid does not have a direct blood supply. Therefore, avascular necrosis is a complication that occurs with scaphoid fractures and non-union occur more often in the proximal lobe (3, 4).

Most carpal bone fractures occur in the scaphoid. This

type of fracture is frequently seen in men, and it is rare in children and the elderly (5). The most frequent reason for a scaphoid fracture is a fall on an outstretched hand, which leads to hyper dorsiflexion of the wrist (3). The most common classification systems for scaphoid fractures are the Herbert classification, Prosser classification, Russe classification, and Mayo classification. Russe and Mayo classifications have an anatomical basis, but the Prosser system relates to the explanation of stable and unstable fractures and can, therefore, be used for selecting a treatment op-

tion. Scaphoid fractures can be also categorized according to the displacement, location, and chronicity of fracture (3, 6). Sometimes patients with a scaphoid fracture, especially if they are in an acute phase of injury, can have normal radiographs; in these cases, the initial diagnosis of scaphoid fracture can be overlooked (5, 7). These patients can develop complications such as non-union, avascular necrosis, and osteoarthritis. An exact diagnosis based on the history, physical examination, and radiographic imaging should be done for these patients (8). In other words, taking a good history of the patient, an exact clinical examination, and appropriate radiographs can help diagnose scaphoid fractures. Taking a good history includes any previous history of wrist or scaphoid injuries and understanding the mechanisms that lead to fractures, such as falling or compression, which leads to extreme dorsiflexion. Tenderness of the scaphoid tubercle, and swelling and tenderness of the anatomical snuffbox should be taken into account during the physical examination. Obtaining radiographs with different views (posteroanterior, lateral, and oblique) can also be very helpful (2).

It is better to consider the injury to be a true fracture in patients who have a suggestive clinical examination for fracture (suspected fracture of the scaphoid) with a normal radiograph. In these cases, immobilization with a cast must be done and then patients must be followed up after two weeks of injury both clinically and radiographically. This method can protect patients from further complications, although sometimes it can result in overtreatment (1). Other studies reported that other imaging modalities can be applied for diagnosis of suspected scaphoid fracture including: magnetic resonance imaging (MRI) (9), compact tomography (CT) (9), and bone scintigraphy (10). Among these modalities, MRI is considered to be the most accurate method for diagnosis of scaphoid fracture (9) and some studies suggested that it should be used as the first choice to diagnose cases of suspected scaphoid fracture (8). However, MRI is associated with some false positive results and, rarely, false negative results (6). In addition, MRI involves more time and cost than other methods such as a plain radiograph, and it is not always available.

2. Objectives

In this study, we determined the value of using both a clinical examination (tenderness of scaphoid tubercle, tenderness of anatomical snuffbox, and compression test) and radiographic imaging in the diagnosis of scaphoid fractures based on the results after a two-week follow-up MRI.

3. Patients and Methods

3.1. Patients

From December 2012 to February 2013, we enrolled 48 suspected scaphoid fracture patients who had been referred to the emergency department of Baqiyatallah Hospital, Tehran, Iran.

3.2. Study Design

The patients were first assessed with three clinical examination tests including the tenderness of the scaphoid tubercle in the volar surface of the hand, the tenderness of the anatomical snuff box, and a compression test. The physical examination was done by a well-experienced emergency medicine specialist. Radiographs were then taken in the following views of the wrist: posteroanterior, lateral, ulnar oblique, and radial oblique. All radiographic examinations were done and interpreted by two expert radiologists. Based on the clinical examination and the radiographic findings, the patients were categorized in three groups (Figure 1). The first group was patients with negative results for clinical and radiographic examination; this group was excluded from the study. The second group was patients with at least one positive finding during the physical examination tests and normal radiographs. For these patients, the fracture was immobilized with a cast and then a follow-up MRI was done after two weeks. According to the result of the MRI, if the fracture was confirmed, the patients were referred to the orthopedic clinic of our hospital for continuing treatment. The third group of this study was patients who had a normal physical examination, but had abnormal radiographic results. These patients were referred to the orthopedic clinic after a cast or split treatment. These patients also had a follow-up MRI two weeks after wrist trauma.

3.3. Exclusion Criteria

Patients who showed evidence of other fractures in radiographic examination with or without a scaphoid fracture, or who showed a scaphoid fracture with a displacement of more than 1 mm, and had capitulum and scapholunate angles that were more than 30° and 60°, respectively, as well as patients who had negative results for both the physical and radiographic examination were excluded from our study.

This study was approved by the ethics committee of Baqiyatallah University of Medical Sciences. Written informed consent was obtained from all participants according to the principles of the declaration of Helsinki (11).

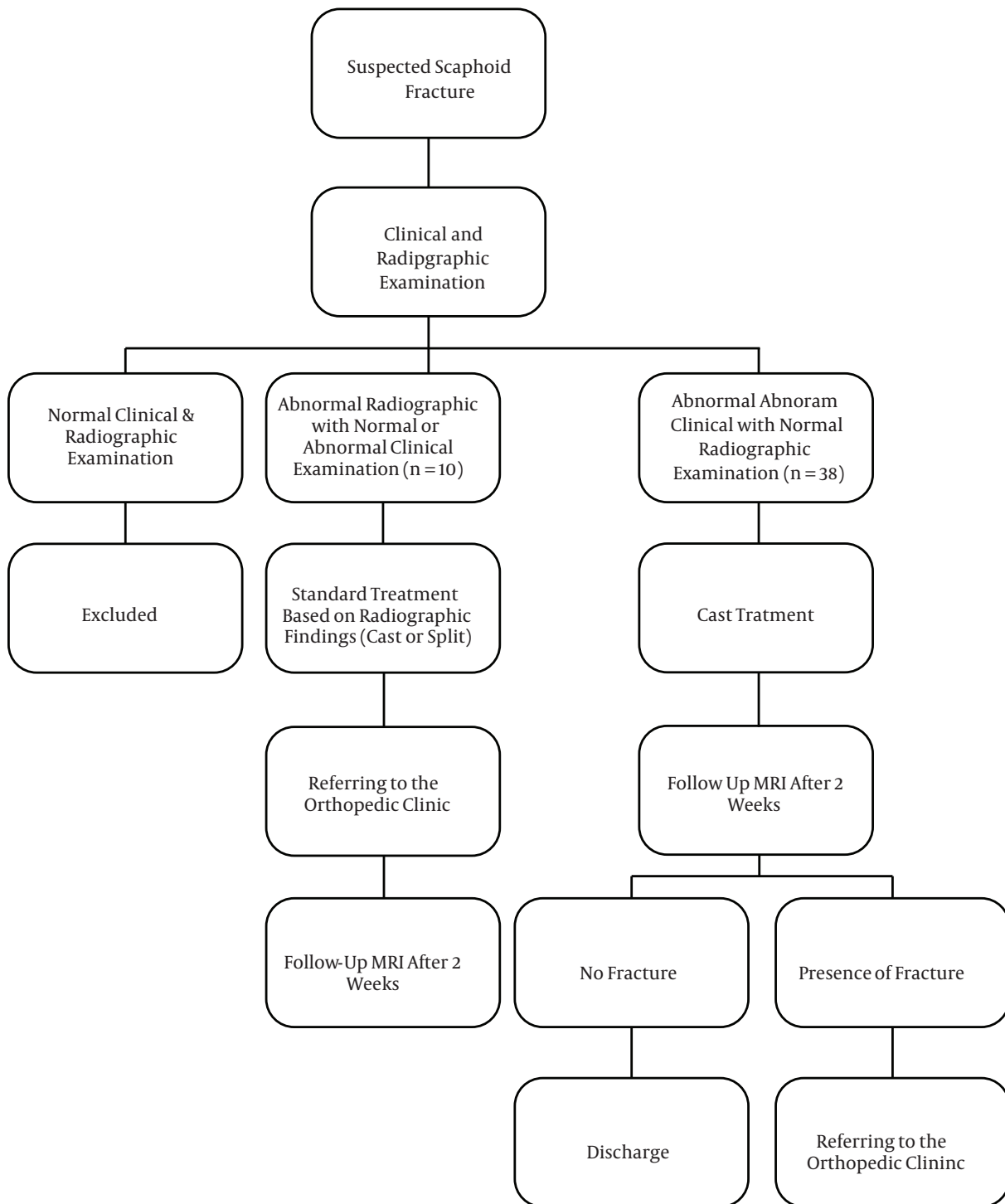


Figure 1. A Flowchart Showing the Classification of Patients in This Study

3.4. Variables

The age, gender, previous history of fracture in the wrist or in the scaphoid bone, chronic disease (diabetes

mellitus, hypertension, coronary artery disease, scleroderma, and gout), and chronic use of any medications

were considered and recorded for all of the patients in this study.

3.5. Statistical Analysis

Ultimately, data analysis was done by SPSS, statistical software package version 16.0. To describe quantitative and qualitative variables, we used frequency (percentage) and mean \pm standard deviation (SD), respectively. Test of association and difference was done using the Pearson correlation, chi-square test, and independent t-tests. A P value less than 0.05 was considered to have statistical significance. To determine the sensitivity, specificity, PPV, and NPV of the clinical and radiographic examinations, a two-week follow-up MRI result was used for standard diagnostic reference.

4. Results

The mean ages of the patients, were 36.64 ± 15.78 years; 46.6% of the patients were male and 35.4% were female. A previous history of wrist and scaphoid fractures were seen in 16.7% and 10.4% of all patients, respectively. There was a history of chronic disease and chronic use of medications in 20.8% and 22.9% of all participants, respectively. Age ($P = 0.197$), gender ($P = 0.119$), previous history of wrist fracture ($P = 0.696$) or scaphoid fracture ($P = 0.369$), chronic use of medications ($P = 0.411$), and chronic disease ($P = 0.244$) had no statistical impact on the scaphoid fractures studied.

Of the 48 patients included in our study, based on the results of a two-week follow-up MRI, 21 patients (43.8%) had a scaphoid fracture, while 27 patients (56.2%) did not have a scaphoid fracture. Falling in 54.2% of patients was the most common cause of a scaphoid fracture, followed by accident (16.7%), violence (12.5%), and other reasons (16.7%).

Table 1 shows the specificity, sensitivity, PPV, and NPV, as well as the number of positive and negative patients based on the diagnostic methods used in this study (tenderness of scaphoid tubercle, anatomical snuff box tenderness, compression test, posteroanterior X-ray, lateral X-ray, ulnar oblique X-ray and radial oblique X-ray). The last column of Table 1 shows the statistical difference between these diagnostic tests and the two-week follow-up MRI. Among these diagnostic methods, the difference between the MRI results and the scaphoid tubercle tenderness ($P = 0.05$) and the compression test ($P = 0.05$) were not statistically significant.

5. Discussion

Although MRI is the first choice for evaluating the presence of a scaphoid fracture, there are benefits to both early

and delayed MRI in the management of scaphoid fracture (12, 13). However, MRI requires more time and cost compared with other diagnostic modalities; MRI can also produce false positive results and false negative results (6, 8). This study highlighted the role for clinical examination and plain radiographs in the diagnosis of scaphoid fractures, especially in the setting of an emergency department in which an exact diagnosis is needed quickly. We also determined how much we can trust these diagnostic tools. One advantage of our study is that we compared our diagnostic tests with MRI results. Based on our results, among the clinical tests, which included tenderness of scaphoid tubercle, anatomical snuff box tenderness, and compression test, scaphoid tubercle tenderness was the most sensitive and specific clinical test in the diagnosis of scaphoid fractures. The results of this test were not statistically different from the MRI results. However, the results of the tenderness of the anatomical snuff box was significantly different from the MRI results. In a study where 246 suspected scaphoid fracture patients were evaluated and the results were compared with a follow-up X-ray, a sensitivity rate of 90% and a specificity rate of 40% was shown for tenderness of anatomical snuff box. For this study, for the scaphoid tubercle tenderness, a sensitivity of 87% and a specificity of 57% was reported (14). Other studies have shown that the tenderness of the scaphoid tubercle alone can be seen in the trapezium and styloid process of the radius (2). The results from the compression test in our study were not statistically different from the MRI results. Esberger's study clinically evaluated 99 patients who were suspected of having a scaphoid fracture. This study showed that the compression test had a sensitivity of 70.5%, a specificity of 21.8%, and a predictive value of 41.9%; thus, the study reported this test to be an unreliable test for the diagnosis of a scaphoid fracture. It should be considered that the results of the compression test were compared with radiographic and bone scan tests (15). All of radiographic tests that we applied in our study had 100% specificity for the diagnosis of scaphoid fractures, although the results were significantly different from the MRI results. Posteroanterior X-ray and ulnar oblique X-ray were the most sensitive radiograph tests in our study. However Low et al. revealed in their study that follow-up radiographs in patients with a suspected scaphoid fracture and normal initial radiographs, had poor sensitivity and poor negative predictive value; they concluded that follow-up radiographs were not a valid diagnostic test (16). Some studies state that using early MRI can lead to reducing the time of cast immobilization in patients with abnormal clinical examination and normal plain radiographs (17). Other studies reported that follow-up radiographs were still used by 94% of clinicians (18).

Table 1. Comparison of Clinical and Radiographic Diagnostic Tests With MRI

Diagnostic Test	Positive Patients	Negative Patients	Sensitivity, %	Specificity, %	PPV, %	NPV, %	Statistical Difference (P Value)
Scaphoid tubercle tenderness	27	21	95.23	74.07	74.07	95.23	0.05
Anatomical snuff box tenderness	37	11	85.71	29.62	48.64	72.72	0.000
Compression test	28	20	42.85	29.62	32.14	40	0.05
Posteroanterior X-ray	10	38	47.61	100	100	71.05	0.000
Lateral X-ray	8	40	38.09	100	100	67.5	0.000
Ulnar oblique X-ray	10	38	45.45	100	100	68.42	0.000
Radial oblique X-ray	8	40	38.09	100	100	67.5	0.000

Abbreviations: NPV, Negative predictive value; PPV, positive predictive value.

5.1. Limitation

To determine an exact sensitivity and specificity value for each test, the selection of appropriate patients was very necessary in our study. We had exact exclusion criteria that was discussed in the method part of this study. This criteria led to a reduced sample size because we could not enroll each patient suspected of having a scaphoid fracture. This low sample size was a limitation in this study.

5.2. Conclusion

In an emergency department when the diagnosis of scaphoid fracture is in doubt, a clinical examination combined with a plain radiograph should be considered to improve diagnostic precision. In this way, the department can avoid overtreatment of the patient, which can include needless immobilization, and undertreatment of the patient, which can lead to complications such as non-union. However, recent studies suggested using MRI to diagnose scaphoid fracture (12, 17, 19). Future studies that use a larger sample size are needed to determine the value of clinical examination and plain radiographs in the diagnosis of scaphoid fracture. Furthermore, these studies must use MRI for the diagnostic reference method. Review articles through meta-analysis can be used for standardizing the method of diagnosing and managing suspected cases of scaphoid fracture.

Acknowledgments

We would like to thank the patients who participated in this study.

Footnotes

Authors' Contribution: Mohammad Reza Ghane and Vahid Dehghani and Mohammad Kazem Emami-Meibodi, and Mohammad Saeid Rezaee-Zavareh contributed to design and data collection of the study. Mohammad Saeid Rezaee-Zavareh provided statistical consulting and performed statistical analysis. Mohammad Saeid Rezaee-Zavareh and Vahid Dehghani drafted the manuscript. All authors contributed to the critical revision and approved the final version of the manuscript.

Financial Disclosure: There are no financial interests related to the material presented in this manuscript.

References

- Phillips TG, Reibach AM, Slomiany WP. Diagnosis and management of scaphoid fractures. *Am Fam Physician*. 2004;**70**(5):879-84. [PubMed: [15368727](#)].
- Schubert HE. Scaphoid fracture. Review of diagnostic tests and treatment. *Can Fam Physician*. 2000;**46**:1825-32. [PubMed: [11013801](#)].
- Tysver T, Jawa A. Fractures in brief: scaphoid fractures. *Clin Orthop Relat Res*. 2010;**468**(9):2553-5. doi: [10.1007/s11999-010-1261-4](#). [PubMed: [20162385](#)].
- Krasin E, Goldwirth M, Gold A, Goodwin DR. Review of the current methods in the diagnosis and treatment of scaphoid fractures. *Postgrad Med J*. 2001;**77**(906):235-7. [PubMed: [11264484](#)].
- Mulligan J, Amblum J. Diagnosis and treatment of scaphoid fracture. *Emerg Nurse*. 2014;**22**(3):18-23. doi: [10.7748/en.22.3.18.e1315](#). [PubMed: [24894291](#)] quiz 25.
- Steinmann SP, Adams JE. Scaphoid fractures and nonunions: diagnosis and treatment. *J Orthop Sci*. 2006;**11**(4):424-31. doi: [10.1007/s00776-006-1025-x](#). [PubMed: [16897211](#)].
- Tiel-van Buul MM, van Beek EJ, Borm JJ, Gubler FM, Broekhuizen AH, van Royen EA. The value of radiographs and bone scintigraphy in suspected scaphoid fracture. A statistical analysis. *J Hand Surg Br*. 1993;**18**(3):403-6. [PubMed: [8345279](#)].
- Yin ZG, Zhang JB, Kan SL, Wang XG. Diagnosing suspected scaphoid fractures: a systematic review and meta-analysis. *Clin Orthop Relat Res*. 2010;**468**(3):723-34. doi: [10.1007/s11999-009-1081-6](#). [PubMed: [19756904](#)].

9. Yin ZG, Zhang JB, Kan SL, Wang XG. Diagnostic accuracy of imaging modalities for suspected scaphoid fractures: meta-analysis combined with latent class analysis. *J Bone Joint Surg Br.* 2012;**94**(8):1077-85. doi: [10.1302/0301-620X.94B8.28998](https://doi.org/10.1302/0301-620X.94B8.28998). [PubMed: [22844049](https://pubmed.ncbi.nlm.nih.gov/22844049/)].
10. Rhemrev SJ, de Zwart AD, Kingma LM, Meylaerts SA, Arndt JW, Schipper IB, et al. Early computed tomography compared with bone scintigraphy in suspected scaphoid fractures. *Clin Nucl Med.* 2010;**35**(12):931-4. doi: [10.1097/RLU.0b013e3181f9de26](https://doi.org/10.1097/RLU.0b013e3181f9de26). [PubMed: [21206223](https://pubmed.ncbi.nlm.nih.gov/21206223/)].
11. Deutsch E. Medical experimentation: international rules and practice. *Law Rev.* 1989;**19**(1):1-10. [PubMed: [11659309](https://pubmed.ncbi.nlm.nih.gov/11659309/)].
12. Burns MJ, Aitken SA, McRae D, Duckworth AD, Gray A. The suspected scaphoid injury: resource implications in the absence of magnetic resonance imaging. *Scott Med J.* 2013;**58**(3):143-8. doi: [10.1177/0036933013496950](https://doi.org/10.1177/0036933013496950). [PubMed: [23960052](https://pubmed.ncbi.nlm.nih.gov/23960052/)].
13. Senevirathna S, Rajeev A, Newby M. The value of delayed MRI scans in the assessment of acute wrist injuries. *Acta Orthop Belg.* 2013;**79**(3):275-9. [PubMed: [23926729](https://pubmed.ncbi.nlm.nih.gov/23926729/)].
14. Freeland P. Scaphoid tubercle tenderness: a better indicator of scaphoid fractures?. *Arch Emerg Med.* 1989;**6**(1):46-50. [PubMed: [2712988](https://pubmed.ncbi.nlm.nih.gov/2712988/)].
15. Esberger DA. What value the scaphoid compression test?. *J Hand Surg Br.* 1994;**19**(6):748-9. [PubMed: [7706879](https://pubmed.ncbi.nlm.nih.gov/7706879/)].
16. Low G, Raby N. Can follow-up radiography for acute scaphoid fracture still be considered a valid investigation?. *Clin Radiol.* 2005;**60**(10):1106-10. doi: [10.1016/j.crad.2005.07.001](https://doi.org/10.1016/j.crad.2005.07.001). [PubMed: [16179171](https://pubmed.ncbi.nlm.nih.gov/16179171/)].
17. Bergh TH, Steen K, Lindau T, Soldal LA, Bernardshaw SV, Lunde L, et al. Costs analysis and comparison of usefulness of acute MRI and 2 weeks of cast immobilization for clinically suspected scaphoid fractures. *Acta Orthop.* 2015;**86**(3):303-9. doi: [10.3109/17453674.2014.986627](https://doi.org/10.3109/17453674.2014.986627). [PubMed: [25409256](https://pubmed.ncbi.nlm.nih.gov/25409256/)].
18. Brookes-Fazakerley SD, Kumar AJ, Oakley J. Survey of the initial management and imaging protocols for occult scaphoid fractures in UK hospitals. *Skeletal Radiol.* 2009;**38**(11):1045-8. doi: [10.1007/s00256-008-0640-3](https://doi.org/10.1007/s00256-008-0640-3). [PubMed: [19194702](https://pubmed.ncbi.nlm.nih.gov/19194702/)].
19. Fallahi F, Oliver R, Mandalia SS, Jonker L. Early MRI diagnostics for suspected scaphoid fractures subsequent to initial plain radiography. *Eur J Orthop Surg Traumatol.* 2014;**24**(7):1161-6. doi: [10.1007/s00590-013-1372-1](https://doi.org/10.1007/s00590-013-1372-1). [PubMed: [24292423](https://pubmed.ncbi.nlm.nih.gov/24292423/)].