

Received: 2014.01.02
Accepted: 2014.03.04
Published: 2014.07.02

Endovascular coil embolization of aneurysm neck for the treatment of ruptured intracranial aneurysm with bleb formation

Authors' Contribution:
Study Design A
Data Collection B
Statistical Analysis C
Data Interpretation D
Manuscript Preparation E
Literature Search F
Funds Collection G

BC 1 **Jun Wan***
AE 1 **Weijin Gu***
EF 2 **Xiaolong Zhang**
CD 2 **Daoying Geng**
AB 2 **Gang Lu**
DE 2 **Lei Huang**
DE 1 **Lei Zhang**
CD 2 **Liang Ge**
EF 1 **Lihua Ji**

1 Department of Radiology, Jing'an District Centre Hospital of Shanghai Huashan Hospital Fudan University Jing'an Branch, Shanghai, China
2 Department of Radiology, Huashan Hospital, Fudan university, Shanghai, China

* Co-first authors – Jun Wan and Weijin Gu

Corresponding Authors:

Source of support:

Xiaolong Zhang, e-mail: zhangxiaolongmed@163.com and Lei Huang, e-mail: hsyysa@163.com

This study was supported by the Health and Family Planning Committee of Shanghai Scientific Research Project (Grant No. 20134088) and the National Nature Science Foundation of China (Grant No. 81371308)

Background: Ruptured intracranial aneurysm (ICA) with bleb formation (RICABF) is a special type of ruptured ICA. However, the exact role and effectiveness of endovascular coil embolization (ECE) in RICABF is unknown. We aimed to investigate the effectiveness and safety of ECE of aneurysm neck for RICABF treatment.


Material/Methods: We retrospectively assessed consecutive patients who were hospitalized in our endovascular intervention center between October 2004 and May 2012. Overall, 86 patients underwent ECE of aneurysm neck for 86 RICABF. Treatments outcomes included secondary rupture/bleeding rate, aneurysm neck embolization rate, residual/recurrent aneurysm, intraoperative incidents, and post-embolization complications, as well as improvements in the Glasgow outcome scale (extended) (GOS-E).

Results: Complete occlusion was achieved in 72 aneurysms (72/86, 83.7%), while 12 aneurysms (12/86, 14.0%) had a residual neck, and 2 aneurysms (2/86, 2.3%) had a residual aneurysm. The postoperative GOS-E was 3 in 3 patients (3.5%), 4 in 10 patients (11.6%), and 5 in 73 patients (84.9%). Follow-up angiography was performed in all patients (mean 9.0 months, interquartile range of 9.0). Recurrence was found in 3 patients (3/86, 3.5%). No aneurysm rupture or bleeding was reported.

Conclusions: Our mid-term follow-up study showed that ECE of aneurysm neck was an effective and safe treatment modality for RICABF. The long-term effectiveness and safety of this interventional radiology technique need to be investigated in prospective and comparative studies.

Keywords: **Intracranial Aneurysm • Ruptured Intracranial Aneurysm With Bleb Formation • False Aneurysm • Endovascular Embolization • Aneurysm Neck Embolization • Interventional Therapy**

Full-text PDF: <http://www.medscimonit.com/abstract/index/idArt/890272>

 3128

 3

 2

 41



Background

Intracranial aneurysms (ICA) are localized, pathological dilation or ballooning of a cerebral artery, with an incidence of 2–5% in the general population [1]. This vascular malformation is very likely to rupture in up to 50% of patients [1], and only a few risk factors for rupture has been identified so far [2,3]. Ruptured ICA results in a number of cerebrovascular complications associated with high morbidity [4–6], leading to a high mortality rate [7–9].

Ruptured ICA with bleb formation (RICABF) is a special type of ruptured ICA in which a hematoma arises from a ruptured ICA and becomes liquefied at the center. The liquefied blood is driven by the constant pressure from the aneurysm, and communicates with the true aneurysm through the vascular rupture opening to form a calabash-like, dumbbell-like, or irregularly-shaped lesions [10]. These false aneurysms are prone to rupture and bleeding due to a weak confinement. Thus, RICABF is associated with a mortality rate of up to 80% due to rebleeding if inappropriately treated [11].

A number of surgical or interventional modalities have been attempted for the treatment of RICABF. Surgical intervention with craniotomy is very challenging in the treatment of RICABF [12] due to the fragile confinement of the lesion [13]. In addition, the feasibility of interventional radiology techniques in the treatment of these false aneurysms is controversial [14,15]. Nevertheless, it has been proposed that endovascular intervention is an effective and minimally invasive treatment modality with less frequent complications [16].

In conventional endovascular coil embolization, the entire aneurysm is completely and compactly filled with embolization agents. However, endovascular coil embolization is associated with some issues, particularly in wide-neck aneurysms, due to high shear stress [17]. Therefore, the primary treatment effect of endovascular intervention should be to decelerate or eliminate the vortex in the aneurysm neck prior to embolization. Song et al. [10] proposed that it was therapeutically essential to completely compact the true aneurysm cavity and to improve the hemodynamics in the aneurysm neck.

There is a lack of studies regarding the mid-term effectiveness and safety of endovascular coil embolization of aneurysm neck for the treatment of RICABF. Therefore, we performed a retrospective, single-arm study in 86 patients to investigate the effectiveness and safety of this interventional radiology approach.

Material and Methods

Subjects

The study protocol was approved by the Institutional Review Board of the Shanghai Municipal Jing'an District Central Hospital/Huashan Hospital Jing'an Branch, affiliated to Fudan University. One hundred and eighty-three patients with 201 ICAs were consecutively hospitalized at our interventional radiology center between October 2004 and May 2012. The angiographic diagnostic criteria of RICABF were: 1) lesion showing as calabash-like, dumbbell-like, or irregular on computed tomography angiography (CTA), magnetic resonance angiography (MRA), or digital subtraction angiography (DSA); and 2) DSA hemodynamic study revealed the coexistence of turbulence and vortex in the RICABF on DSA, the former being located in the proximal part of the aneurysm sac with a relatively higher flow rate, and the latter being located in the distal part of the aneurysm sac with a relatively lower flow rate [18].

From those ICA patients, a cohort of 86 patients with RICABF who underwent endovascular coil embolization of aneurysm neck was identified. Inclusion criteria were: 1) age <80 years; 2) angiography-confirmed RICABF; 3) aneurysm of 5–15 mm in diameter; 4) subarachnoid hemorrhage (SAH) (Figure 1) identified on computed tomography to arise from the RICABF in the case of multiple aneurysms; and 5) Glasgow coma scale (GCS) score >7 points.

In each patient, standard preoperative assessment included angiography, chest radiography, electrocardiography, liver and kidney biochemistry, routine hematology, coagulation function, hepatitis B serology, blood typing, and plasma glucose. Prophylactic antimicrobial agents, antifibrinolytic medication, and sedatives were administered if indicated. SAH patients were evaluated using the Hunt-Hess scale [19].

Antihypertensive drugs and diuretics were given to reduce circulatory and intracranial blood pressure. Intravenous nimodipine (Bayer Healthcare Co. Ltd., Beijing, China) was continuously perfused at a dose of 0.8–1.0 mg/h to prevent cerebral vasospasm. All patients provided an informed written consent prior to surgery.

Endovascular coil embolization of aneurysm neck

All included patients underwent endovascular coil embolization under general anaesthesia with intubation, and target-controlled perfusion of nimodipine (0.8–1.0 mg/h) was maintained throughout the interventional treatment. Out of these 86 patients, 25 patients (28.7%) received systematic heparinization, whereas 61 patients received no heparinization due to the presence of a medium-size narrow-neck aneurysm, a

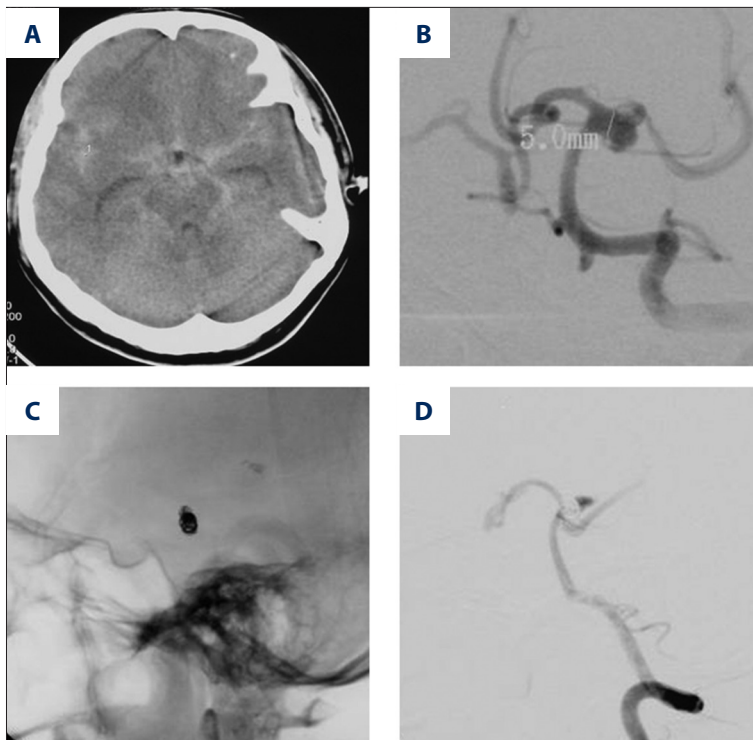


Figure 1. A 41-year-old male complaining of sudden-onset headache exhibited (A) SAH on head CT scan. Cerebral DSA (B) revealed a P1 RICABF involving the left posterior cerebral artery. The proximal true aneurysm cavity and the aneurysm neck (C) were compactly embolized. Immediate angiography (D) showed contrast media stagnation in the bleb of RICABF.

favorable vascular condition, and an expected operative time of less than 1 hour.

The Seldinger technique was used to access the femoral artery, and the aneurysm was accessed using a Prowler 10 (Cordis Neurovascular, Inc., Florida, USA) or an Echelon 10 or 14 (Micro Therapeutics Inc. dba ev3 Neurovascular, CA, USA) microcatheter equipped with a Silverspeed 10 or 14 microguidewire (Micro Therapeutics Inc. dba ev3 Neurovascular, CA, USA).

The specific technique used for aneurysm neck embolization depended upon the width of the aneurysm neck. Narrow-neck aneurysms (body/neck ratio >2 or diameter <4 mm) were coil-embolized in 59 patients, using a 3-dimensional compass/complex/CosMos or a 2-dimensional helical MicroPlex Coiling System (MicroVention, Inc., Tustin, CA), a HydroCoil Embolic System (MicroVention, Inc., 75A Columbia, USA), or a HydroSoft/HyperSoft/SuperSoft/CosMos Embolic System (MicroVention, Inc., 75A Columbia, USA). Only the sac (the true aneurysm cavity) connecting the parent artery, especially the aneurysm neck, was compactly embolized, while the distal sac (the RICABF) was not embolized or was loosely embolized. In the case of a large-orifice opening (>3 cm) between the true aneurysm and the RICABF, the first coil might have been deployed into the RICABF, which required more cautious loose embolization. The delivery of the microcatheter tip and microcoils was more cautious if a high delivery friction was present or if the microcatheter tip projected into the aneurysm. If the RICABF ruptured incidentally upon endovascular coil embolization, the rupture opening was immediately coiled without withdrawing the

microcatheter until the true aneurysm was completely compacted. Upon achieving adequate support for the microcoil, the tip of the microcatheter was withdrawn into the proximal true aneurysm cavity for further compact embolization of the true aneurysm and aneurysm neck (Figure 2).

Wide-neck aneurysms (body/neck ratio <2 or diameter >4 mm), involving the ocular artery ($n=4$), posterior communicating artery ($n=17$), anterior communicating ($n=1$), superior cerebellar artery ($n=1$), middle cerebral artery ($n=1$), and basilar artery ($n=3$), were embolized using microcoils assisted with stenting (Neuroform[®], Boston Scientific Corporation, Natick, MA; Enterprise[™], Cordis Corporation, Bridgewater Township, New Jersey; Solitaire[™] AB, ev3 Neurovascular, Irvine, CA), double-microcatheter, semi-deploying stenting, or endovascular ballooning technique. The stent was delivered into the parent artery but not deployed, and the microcatheter was advanced into the first one-third of the aneurysm with the assistance of the guidewire. The stent was cautiously deployed or semi-deployed, or the endovascular balloon was dilated, to fix the microcatheter between the stent and the artery wall. Using a double-microcatheter technique, a microcatheter was advanced into the aneurysm, and the coil was delivered but not released; a second microcatheter was advanced into the aneurysm, and more microcoils were successively delivered until the aneurysm neck was compacted.

Compact aneurysm embolization was defined as previously reported [20] using the Raymond's criteria [21]. Briefly, at least 7 ml of contrast media (Yangtze River Pharmaceutical Group Co.

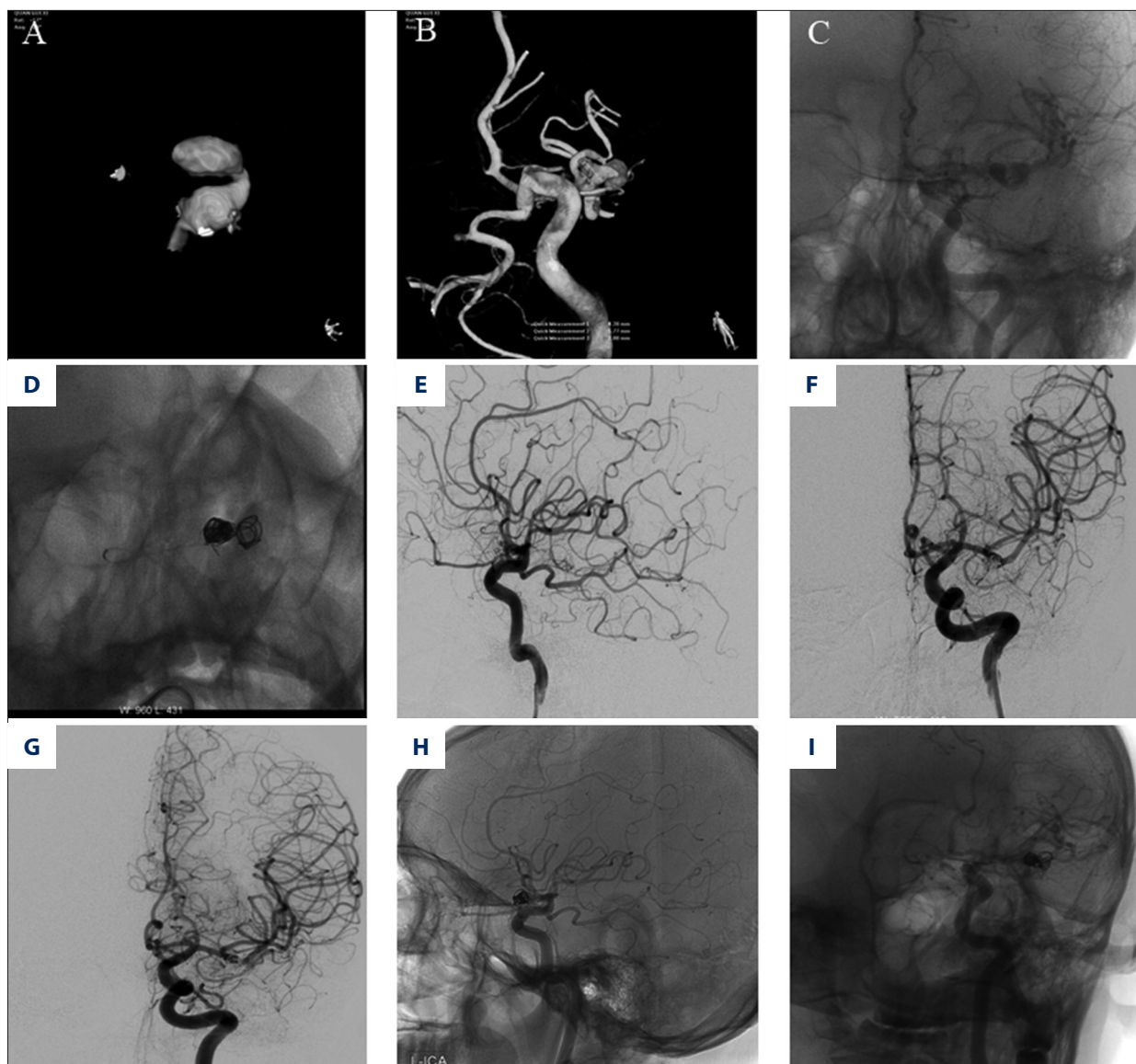


Figure 2. A 41-year-old male complaining of sudden-onset headache showed SAH on head CT scan. (A–C) Cerebral DSA revealed an irregular-shaped RICABF involving the middle cerebral artery. (D–F) The true aneurysm cavity was complete occluded and the distal sac was loosely occluded. The immediate angiography after embolization showed the complete occlusion of the aneurysm. (G–I) Follow-up angiography 19 months after the operation showed no residual or recurrent aneurysm.

Ltd., Taizhou, China), at a concentration of more than 250 mg/L, was injected at a rate of 4 mL/sec. Angiographies were continuously captured for more than 8 sec, at a frame rate of 6 frames per second. Compact aneurysm embolization was successful if the aneurysm was not visualized on at least 2 projections during dynamic angiography.

Postoperative care and follow-up

Intravenous perfusion of nimodipine was continued, and blood pressure was maintained at 110–120/70–80 mmHg. Prophylactic antimicrobial agents, sedatives, and neurotrophic

or cerebroprotective medication were given, as indicated. Aspirin (Bayer HealthCare, Morristown, NJ) or clopidogrel (Sanofi Winthrop Industrie S.A., France) was prescribed for patients undergoing stent-assisted embolization to inhibit platelet aggregation and consequent endovascular thrombosis. Following the intervention, the patients received a loading dose of 150 mg of clopidogrel and 200 mg aspirin on day 1, followed by a dose of 75 mg clopidogrel or 100 mg aspirin per day. All patients were followed-up using the Glasgow outcome scale (extended) (GOS-E) [22] and by cerebral angiography within 12 months after the operation.

A recurrence was defined as any increase in the size of the aneurysm or its neck, or as a new hemorrhagic event of the embolized aneurysm. When a recurrence was found in a patient who was considered protected from rebleeding, or when re-treatment was judged to be inappropriate, the patient did not undergo additional surgery, and another follow-up angiography was done within 12 months.

Measurements and outcomes

In each patient, baseline characteristics were assessed, including demography, symptoms, and angiographic characteristics at presentation. Treatment outcomes included secondary rupture/bleeding rate, rate of aneurysm neck embolization, aneurysm recurrence/residual, intraoperative incidents, and post-embolization complications, as well as GOS-E improvement.

Statistical analysis

This was an observational study, and only descriptive statistics are presented. Continuous variables are presented as means \pm standard deviation (SD) if the data were normally distributed. Categorical data are presented as proportions.

Results

Clinical data at presentation

Table 1 shows the baseline clinical characteristics of the 86 RICABF patients included in the present study. Most of them were women (64/86, 74.4%), and had SAH (66/86, 76.7%). Patients were aged 50.7 \pm 10.6 years. On admission, according to the GCS, only 1 patient (1.2%) had moderate brain damage (GCS of 9–12), while the remaining 85 (98.8%) patients had minor brain damage (GCS \geq 13). Most of them had the classical clinical manifestations of SAH (76.7%), while 12.8% had oculomotor nerve palsy, and 2.3% had frontal or orbital pain. According to the Hunt-Hess scale, 73 patients (84.9%) were grade I, 12 (14.0%) were grade II, and 1 (1.2%) was grade III.

Angiographic characteristics at presentation

Table 2 shows the angiographic characteristics at presentation among the 86 patients with a total of 86 RICABF lesions included in the present study. There were 86 patients with a total of 100 aneurysms and there were 86 RICABF lesions with in the 94 aneurysms accepted for endovascular embolization. The other 6 aneurysms were not treated because of their low risk of hemorrhage due to their small size and regular saccular shape. Most aneurysms (79/86, 91.9%) were located in the anterior cerebral circulation. The 3 most commonly affected arteries were the posterior communicating artery (46/86,

Table 1. Clinical and demographic characteristics of 86 patients with RICABF lesions treated by endovascular coil embolization of aneurysm neck.

	n (%)
Gender	
Male	22 (25.6)
Female	64 (74.4)
Age, year (mean \pm SD)	50.7 \pm 10.6
GCS on admission	
12	1 (1.2)
13	1 (1.2)
14	3 (3.5)
15	81 (94.2)
Clinical manifestation	
SAH	66 (76.7)
Oculomotor nerve palsy	11 (12.8)
Frontal or orbital pain	2 (2.3)
Hunt-Hess scale	
I	73 (84.9)
II	12 (14.0)
III	1 (1.2)

GCS – Glasgow Coma Scale; SAH – subarachnoid hemorrhage.

53.5%), the anterior communicating artery (20/86, 23.3%), and the ophthalmic artery (7/86, 8.1%). Aneurysm neck was wide in 31.4% (27/86) of patients and narrow in 68.6%. Simple embolization was performed in 77.9% (67/86) of patients, stent-assisted in 19.8% (17/86), balloon-assisted in 1.2% (1/86), and dual micro-catheter in 1.2% (1/86).

Embolization outcomes and complications

Table 3 presents the treatment outcomes. Contrast filling in the aneurysm was assessed by the method published by Raymond et al. [21]. Complete occlusion was achieved in 72 aneurysms (72/86, 83.7%), while 12 aneurysms (12/86, 14.0%) had a residual neck, and 2 aneurysms (2/86, 2.3%) had a residual aneurysm. Intraoperative cerebrovascular spasms, manifesting as a 40% reduction in vessel diameter, was observed in 4 patients (4.6%). Intracatheter nimodipine (0.4–1.0 mg) was slowly injected, and the blood pressure was maintained at 110–120/70–80 mmHg. Intraoperative aneurysm bleeding occurred in 2 patients (2.3%); heparin was stopped, and endovascular coil embolization was continued as scheduled.

Post-operative recovery was uneventful in most patients. GOS-E score was 5 in 73 patients (84.9%), 4 in 10 (11.6%), and of 3 in only 3 patients (3.5%). However, 9 patients (10.3%) had cerebral infarction, 5 (5.7%) had cerebrovascular spasms, 4 (4.6%) had aneurysm bleeding, and 1 (1.1%) had a secondary hydrocephalus. All complications were treated using appropriate

Table 2. Angiographic characteristics of 86 patients with RICABF treated by endovascular coil embolization of aneurysm neck.

	n (%)	
Number of aneurysm per patient		
Single	72/86	(83.7)
Multiple	14/86	(16.3)
Number of treated aneurysm per patient		
1	78/86	(90.7)
2	8/86	(9.3)
Location of aneurysm by circulation		
Anterior cerebral circulation	79/86	(91.9)
Posterior cerebral circulation	7/86	(8.1)
Location of aneurysm by artery		
A3	1/86	(1.2)
Arteria cerebral artery	1/86	(1.2)
Arteria internal carotid artery	1/86	(1.2)
Anterior communicating artery	20/86	(23.3)
Basilar artery	4/86	(4.7)
Traffic segment of internal carotid artery	1/86	(1.2)
Left middle cerebral artery	1/86	(1.2)
Middle cerebral artery	2/86	(2.3)
Ophthalmic artery	7/86	(8.1)
Posterior communicating artery	46/86	(53.5)
Superior cerebellar artery	2/86	(2.3)
Shape		
Sac-like	85/86	(98.8)
Irregular sac-like	1/86	(1.2)
Aneurysm neck		
Wide-necked	27/86	(31.4)
Narrow neck	59/86	(68.6)
Treatment		
Simple embolization	67/86	(77.9)
Balloon-assisted	1/86	(1.2)
Dual micro-catheter	1/86	(1.2)
Stent-assisted	17/86	(19.8)

standard treatments, and these patients only exhibited minimal sequelae. Oculomotor palsy observed in 11 patients at admission completely improved in 8 (72.7%) patients by postoperative day 2.

Follow-up result

All patients were postoperatively followed up using cerebral angiography within 12 months (median of 9.0, interquartile range of 9.0 months). Among the 86 patients available for follow-up, 83 patients kept stable compared with the immediate angiography, including 71 complete occlusions (71/72), 11 residue necks (11/12), and 1 residue aneurysms (1/2), while

Table 3. Treatment outcomes in 86 patients with RICABF lesions treated by endovascular coil embolization of aneurysm neck.

	n (%)	
Immediate angiography (n=86)		
Complete occlusion	72	(83.7)
Aneurysm neck residual	12	(14.0)
Aneurysm residual	2	(2.3)
Follow up angiography		
Aneurysm recurrence	3/86	(3.4)
Postoperative GOS-E		
3	3/86	(3.5)
4	10/86	(11.6)
5	73/86	(84.9)
Procedure-related complications		
Cerebral infarction	9	(10.3)
Aneurysm bleeding	4	(4.6)
Cerebrovascular spasms	5	(5.7)
Secondary hydrocephalus	1	(1.1)

GOS-E – Extended Glasgow Outcome Scale.

3 patients had recurrent aneurysms. The first recurrent case was a narrow-neck aneurysm with no residual aneurysm neck after simple coil embolization, but the follow-up angiography revealed the aneurysm neck to be slightly filled with contrast media. The other 2 cases had wide-neck aneurysms. The first underwent stent-assisted embolization with a residual aneurysm and the residual part was slightly increased at follow-up. The last case underwent simple coil embolization and showed a residual neck, and the neck was slightly increased at the follow-up angiography. No revision surgery or embolization was performed these 3 cases with minor recurrence, and the patients were considered protected from rebleeding, but further short-term follow-up angiography was performed. No patient with minimal residual or recurrent aneurysm had a secondary aneurysm rupture during follow-up.

Discussion

Using endovascular coil embolization, aneurysm necks achieved complete occlusion in most patients (72/86, 72.3%) and postoperative GOS-E was high in most patients. All patients were postoperatively followed up using cerebral angiography. Aneurysm recurrence was observed in only 3 (3.5%) patients. No aneurysm rupture or bleeding was reported during follow-up.

Neural impairment observed in patients with RICABF derives mainly from the space-occupying effect of a large aneurysm, compressing nerves in its vicinity, such as the optic and oculomotor nerves. The severity of neural impairment is associated with aneurysm size, growth orientation, and aneurysm blood flow rate. It is known that the embolization of the

aneurysm-bearing artery will shrink the aneurysm by up to 30% within 1 year, and the embolization of the aneurysm itself will significantly prolong the time of aneurysm shrinkage [23]. Moreover, embolization of the true aneurysm will discontinue blood flow into the RICABF and eliminate the “hammer” effect caused by the aneurysm pulsation. Consequently, our results showed that oculomotor palsy observed in 11 RICABF patients at admission completely improved in 8 (72.7%) patients after RICABF neck embolization.

The primary goal when treating RICABF is to prevent ICA rupture and rebleeding. Thus, endovascular embolization allows the elimination of the aneurysm with minimal interruption of blood supply to the brain. However, endovascular embolization presents a relatively high risk of aneurysm recurrence compared with the more invasive surgical closure, due to the fact that vascular endothelium may not be fully anastomosed at the aneurysm neck [24–26].

The primary intraoperative safety concern arising from RICABF coil embolization is a higher risk of incidental rupture and bleeding, which results from iatrogenic injuries in most cases, compared with the risks arising from true ICA embolization. Major risk factors for intraoperative complications include underlying poor vascular strength, misplacement of catheter, guide-wire, and/or microcoils, and excessive aneurysm compactness [2,27,28]. Compact embolization of distal RICABF will increase the luminal tension and cause subsequent rupture and bleeding. However, compact embolization of the aneurysm neck is much safer because the neck is bordered by the relatively stronger true aneurysm wall instead of the fragile fibroconnective tissues confining RICABF. Song et al. [10] reported that endovascular coil embolization without or with loose compaction of RICABF resulted in occasional intraoperative rupture, minimal aneurysm recurrence, and no secondary bleeding within a follow-up period of up to 60 months. In the case of a dumb-bell-shaped (wide-neck) aneurysm, coils are more likely to be mistakenly deployed in the RICABF cavity upon neck embolization, and consequently cause rupture and bleeding [29,30]. Therefore, endovascular coil embolization of RICABF should be limited to the true aneurysm cavity to minimize iatrogenic rupture and bleeding [10,20,31].

The long-term efficacy of coil embolization is known to largely depend upon whether complete embolization has been achieved at the first attempt; aneurysm neck residual and coil compression are the primary risk factors contributing to aneurysm recurrence [32]. Up to 49% of patients are likely to have a recurrent aneurysm during the follow-up period if a residual aneurysm neck is present following embolization [33]. Complete compactness of the aneurysm neck will allow the migration and coverage of proliferating vascular endothelial cells, while blocking blood stream to the pre-existing

aneurysm. Moreover, compact embolization of proximal true aneurysm and RICABF neck can offer an adequate support for coils, and avoid postoperative recurrence associated with coil compression. Studies showed that an aneurysmal SAH recurrence is 15–22 times more likely than the expected rate of a first SAH [34,35]. A study showed aneurysm recurrence in 8% of patients treated with coil embolization [26]. In a large series, 34% had an aneurysm recurrence in the 12 months following embolization [21]. Finally, a large systematic review showed that aneurysm recurrence occurred in 21% of 8161 aneurysms [36]. In contrast, our study showed a low rate of aneurysm recurrence with compact embolization of aneurysm neck alone.

The great majority (>80%) of our patients achieved absolute complete compact embolization of aneurysm neck, and a small percentage (<3%) of our patients achieved residual aneurysm. However, our follow-up results suggest that a residual neck might not contribute to a higher risk of aneurysm recurrence. The completion rate of aneurysm embolization depends upon the body/neck ratio, aneurysm neck size, and the included angle between the aneurysm and the aneurysm-bearing artery [11,21,36–40]. The failure to achieve a complete compact embolization can be attributed to the limitation of the technique; a small residual aneurysm neck may be present due to the dislocation of the coil on deployment, even when using the smallest and the most flexible microcoils available. In a short-term follow-up study, Yu et al. [41] reported that compact embolization of the proximal true aneurysm (neck) without embolizing the distal RICABF was associated with a nearly zero recurrence rate, similar to the recurrence rate following compact embolization of both proximal true aneurysm and distal RICABF. In the present study, wide-neck aneurysms were at a higher risk of residual aneurysm and recurrence. Indeed, 3 wide-neck aneurysms exhibited residual aneurysm following coil embolization, all of which were found to recur on follow-up angiography, but resulted in no secondary rupture or re-bleeding. A larger residual aneurysm neck may also be associated with the radiologist’s learning curve. Therefore, coil embolization of RICABF neck should be performed by experienced interventional neuroradiologists.

We acknowledge that our study was non-randomized and retrospective, and suffered from the limitations that are inherent in this kind of study. Prospective studies should be conducted in larger sample sizes to confirm our findings.

Conclusions

In conclusion, endovascular coil embolization of aneurysm neck is an effective and safe treatment modality for RICABF, and is associated with few intraoperative and postoperative complications. Mid-term follow-up suggests a minimal recurrence

rate and that recurrence is more likely to happen in wide-neck aneurysms. The long-term effectiveness and safety of this interventional technique need to be investigated in prospective, comparative studies.

References:

- Chyatte D, Lewis I: Gelatinase activity and the occurrence of cerebral aneurysms. *Stroke*, 1997, 28: 799–804
- Dusak A, Kamasak K, Goya C et al: Arterial distensibility in patients with ruptured and unruptured intracranial aneurysms: is it a predisposing factor for rupture risk? *Med Sci Monit*, 2013, 19: 703–9
- Cooper CJ, Said S, Nunez A et al: Dural arteriovenous fistula discovered in patient presenting with recent head trauma. *Am J Case Rep*, 2013, 14: 444–48
- Vlak MH, Algra A, Brandenburg R, Rinkel GJ: Prevalence of unruptured intracranial aneurysms, with emphasis on sex, age, comorbidity, country, and time period: a systematic review and meta-analysis. *Lancet Neurol*, 2011; 10: 626–36
- Schievink WI: Intracranial aneurysms. *N Engl J Med*, 1997; 336: 28–40
- Hop JW, Rinkel GJ, Algra A, van Gijn J: Case-fatality rates and functional outcome after subarachnoid hemorrhage: a systematic review. *Stroke*, 1997; 28: 660–64
- Huang J, van Gelder JM: The probability of sudden death from rupture of intracranial aneurysms: a meta-analysis. *Neurosurgery*, 2002; 51: 1101–5; discussion 1105–7
- Stegmayr B, Eriksson M, Asplund K: Declining mortality from subarachnoid hemorrhage: changes in incidence and case fatality from 1985 through 2000. *Stroke*, 2004; 35: 2059–63
- Broderick JP, Brott TG, Duldner JE et al: Initial and recurrent bleeding are the major causes of death following subarachnoid hemorrhage. *Stroke*, 1994; 25: 1342–47
- Song J, Liu S, Wang T et al: The imaging features and endovascular embolization therapy of false aneurysm after the rupture of intracranial aneurysm. *Chin J Neurosurg*, 2006, 22: 741–44
- Bederson JB, Connolly ES Jr, Batjer HH et al: Guidelines for the management of aneurysmal subarachnoid hemorrhage: a statement for healthcare professionals from a special writing group of the Stroke Council, American Heart Association. *Stroke*, 2009; 40: 994–1025
- Lempert TE, Halbach VV, Higashida RT et al: Endovascular treatment of pseudoaneurysms with electrolytically detachable coils. *Am J Neuroradiol*, 1998; 19: 907–11
- Ma L, Yu Z, Yang M et al: Basic and clinical research on false aneurysm forming after the rupture of intracranial aneurysm. *Chin J Neurosurg*, 2004; 20: 118–21
- Fiorella D, Albuquerque FC, Deshmukh VR et al: Endovascular reconstruction with the Neuroform stent as monotherapy for the treatment of uncoilable intradural pseudoaneurysms. *Neurosurgery*, 2006, 59: 291–300; discussion 291–300
- Vanninen RL, Manninen HI, Rinne J: Intracranial iatrogenic carotid pseudoaneurysm: endovascular treatment with a polytetrafluoroethylene-covered stent. *Cardiovasc Intervent Radiol*, 2003; 26: 298–301
- Molyneux AJ, Kerr RS, Yu LM et al: International subarachnoid aneurysm trial (ISAT) of neurosurgical clipping versus endovascular coiling in 2143 patients with ruptured intracranial aneurysms: a randomised comparison of effects on survival, dependency, seizures, rebleeding, subgroups, and aneurysm occlusion. *Lancet*, 2005; 366: 809–17
- Shojima M, Nemoto S, Morita A et al: Role of shear stress in the blister formation of cerebral aneurysms. *Neurosurgery*, 2010, 67: 1268–74; discussion 1274–75
- Wardlaw JM, White PM: The detection and management of unruptured intracranial aneurysms. *Brain*, 2000; 123(Pt 2): 205–21
- Hunt WE, Hess RM: Surgical risk as related to time of intervention in the repair of intracranial aneurysms. *J Neurosurg*, 1968; 28: 14–20
- Wang D, Ling F, Li M et al: [An occlusive evaluation proposal to intra-saccular embolization of intracranial aneurysm]. *Zhonghua Wai Ke Za Zhi*, 2000; 38: 844–47
- Raymond J, Guilbert F, Weill A et al: Long-term angiographic recurrences after selective endovascular treatment of aneurysms with detachable coils. *Stroke*, 2003; 34: 1398–403
- Hudak AM, Caesar RR, Frol AB et al: Functional outcome scales in traumatic brain injury: a comparison of the Glasgow Outcome Scale (Extended) and the Functional Status Examination. *J Neurotrauma*, 2005; 22: 1319–26
- Dovey Z, Misra M, Thornton J et al: Guglielmi detachable coiling for intracranial aneurysms: the story so far. *Arch Neurol*, 2001; 58: 559–64
- Halpin DM, Decramer M, Celli B et al: Exacerbation frequency and course of COPD. *Int J Chron Obstruct Pulmon Dis*, 2012; 7: 653–61
- Molyneux AJ, Kerr RS, Birks J et al: Risk of recurrent subarachnoid haemorrhage, death, or dependence and standardised mortality ratios after clipping or coiling of an intracranial aneurysm in the International Subarachnoid Aneurysm Trial (ISAT): long-term follow-up. *Lancet Neurol*, 2009; 8: 427–33
- CARAT Investigators: Rates of delayed rebleeding from intracranial aneurysms are low after surgical and endovascular treatment. *Stroke*, 2006; 37: 1437–42
- Sato K, Kato M: [Re-bleeding during embolization of ruptured cerebral aneurysms by Guglielmi detachable coil]. *Masui*, 2002; 51: 1238–42
- Sluzewski M, Bosch JA, van Rooij WJ et al: Rupture of intracranial aneurysms during treatment with Guglielmi detachable coils: incidence, outcome, and risk factors. *J Neurosurg*, 2001; 94: 238–40
- Zhang J, Qu Z, Wang Z et al: Combined endovascular stent implantation and endovascular coil placement for the treatment of 16 cases of intracranial wide-necked aneurysms. *Chin J Neurosurg*, 2002; 18: 256–58
- Tanoue S, Kiyosue H, Matsumoto S et al: Ruptured „blisterlike” aneurysm with a pseudoaneurysm formation requiring delayed intervention with endovascular coil embolization. Case report. *J Neurosurg*, 2004; 101: 159–62
- Struffert T, Buhk JH, Buchfelder M et al: Coil migration after endovascular coil occlusion of internal carotid artery pseudoaneurysms within the sphenoid sinus. *Minim Invasive Neurosurg*, 2009; 52: 89–92
- Brettler S: Endovascular coiling for cerebral aneurysms. *AACN Clin Issues*, 2005; 16: 515–25
- Hayakawa M, Murayama Y, Duckwiler GR et al: Natural history of the neck remnant of a cerebral aneurysm treated with the Guglielmi detachable coil system. *J Neurosurg*, 2000; 93: 561–68
- Wermer MJ, Greebe P, Algra A, Rinkel GJ: Incidence of recurrent subarachnoid hemorrhage after clipping for ruptured intracranial aneurysms. *Stroke*, 2005; 36: 2394–99
- Rinkel GJ, Algra A: Long-term outcomes of patients with aneurysmal subarachnoid haemorrhage. *Lancet Neurol*, 2011; 10: 349–56
- Ferns SP, Sprengers ME, van Rooij WJ et al: Coiling of intracranial aneurysms: a systematic review on initial occlusion and reopening and retreatment rates. *Stroke*, 2009; 40: e523–29
- Campi A, Ramzi N, Molyneux AJ et al: Retreatment of ruptured cerebral aneurysms in patients randomized by coiling or clipping in the International Subarachnoid Aneurysm Trial (ISAT). *Stroke*, 2007; 38: 1538–44
- Ferns SP, Sprengers ME, van Rooij WJ et al: Late reopening of adequately coiled intracranial aneurysms: frequency and risk factors in 400 patients with 440 aneurysms. *Stroke*, 2011; 42: 1331–37
- Murayama Y, Nien YL, Duckwiler G et al: Guglielmi detachable coil embolization of cerebral aneurysms: 11 years' experience. *J Neurosurg*, 2003; 98: 959–66
- Choi DS, Kim MC, Lee SK et al: Clinical and angiographic long-term follow-up of completely coiled intracranial aneurysms using endovascular technique. *J Neurosurg*, 2010; 112: 575–81
- Yu J, Wang H, Xu K et al: Endovascular treatment of intracranial aneurysm with ruptured bleb formation. *Chin J Neurosurg*, 2010; 26: 988–91

Conflicts of interest

The authors declare that they have no conflict of interest.