

The Triple Unilimb Z Plasty Technique for Severe Forms of Unilateral Cleft Lip Repair

Percy Rossell-Perry, MD, PhD,
FACS

Background: A wide spectrum of variation of the unilateral cleft lip deformity requires an individualized management. Current classifications for unilateral cleft lip are limited to incomplete or complete, and these descriptions do not address well this deformity. The soft tissue deficiency is not considered, which plays an important role in the surgical correction of the unilateral cleft lip. The author developed an innovative technique for surgical correction of unilateral cleft lip with severe soft tissue deficiency.

Methods: Since 2007, 168 patients with severe unilateral cleft lip have been operated on by the author, using the proposed surgical technique. The author's classification of severity considers a severe unilateral cleft lip as a discrepancy between the non-cleft and cleft vertical height greater than 6 mm. The technique uses 2 Z plasties for the upper lip and 1 Z plasty for vermilion repair.

Results: This method lets the surgeon to achieve an adequate symmetry of the upper lip. A low rate of revision (14.88%) has been observed for 13 years, using the proposed surgical technique, by the author.

Conclusions: An innovative technique to address severe forms of unilateral cleft lip is presented in this article. This method represents a good alternative for cleft lips with increased lateral segment tissue deficiency, providing adequate lip symmetry. (*Plast Reconstr Surg Glob Open* 2020;8:e3213; doi: [10.1097/GOX.0000000000003213](https://doi.org/10.1097/GOX.0000000000003213); Published online 4 November 2020.)

INTRODUCTION

Current classification describes the unilateral cleft lip deformity as complete or incomplete, providing insufficient information for surgical planning. For this reason, a classification of severity has been previously described by the author.¹

This method divides the cleft into 4 components: nose, upper lip, primary, and secondary palate. The upper lip component is estimated by considering the differences between the soft tissues of the cleft and the non-cleft side.

The Millard technique, probably the most widely used method, is limited to help achieving an adequate upper lip symmetry in these severe forms.² Shorter lip and upper

lip asymmetry have been described by different authors using the rotational advancement method.^{3,4} The triple unilimb Z plasty provides an additional length for cleft lip repair and minimizes the size of the triangles. Two minor transpositions are less visible than 1 large transposition.^{5,6} The method uses an additional vermilion Z plasty, as described by Samuel Noordhoff.⁷

In comparison with the Nakajima technique (another method based on two lip rotations), the proposed technique uses tissues from the medial side (area usually resected) for the upper Z plasty.⁸ Presurgical orthopedics is not used by the author for unilateral cleft lip repair.

METHODS

Since 2007, 168 patients with severe unilateral cleft lip have been operated on by the author using the proposed surgical technique. All these cases were classified as severe based on the author's classification, and a severe unilateral cleft lip is defined if the difference between the cleft and the non-cleft side vertical height is greater than 6 mm. The results were assessed by rate of non-desirable outcomes.

From the Faculty of Medicine Post Graduate Studies, School of Medicine, San Martín de Porres University; Edgardo Rebagliatti Hospital, Lima, Peru; and the South American Medical Advisory Council, Smile Train Foundation, USA.

Received for publication July 20, 2020; accepted September 3, 2020. Presented orally at the ACPA's 68th Annual Meeting, San Juan, Puerto Rico, 2011.

Copyright © 2020 The Author. Published by Wolters Kluwer Health, Inc. on behalf of The American Society of Plastic Surgeons. This is an open-access article distributed under the terms of the [Creative Commons Attribution-Non Commercial-No Derivatives License 4.0 \(CCBY-NC-ND\)](https://creativecommons.org/licenses/by-nc-nd/4.0/), where it is permissible to download and share the work provided it is properly cited. The work cannot be changed in any way or used commercially without permission from the journal.

DOI: [10.1097/GOX.0000000000003213](https://doi.org/10.1097/GOX.0000000000003213)

Disclosure: The author has no financial interest to declare in relation to the content of this article.

Related Digital Media are available in the full-text version of the article on www.PRSGlobalOpen.com.

Surgical Technique (Figs. 1, 2).

Markings

- Point 1. Right peak of the Cupid's bow
 - Point 2. Middle point of the Cupid's bow
 - Point 3. Left peak of the Cupid's bow
 - Points 1', 2', and 3'. Similar as points 1, 2, and 3 but located over red line
 - Point 4. Midline point between supralabium and infralabium (Pool's concept)
 - Point 5. Midpoint of the lip columellar crease
 - Points 6 and 7. Lateral junction of the columella border and lip columellar crease
 - Point 8. End's point of the white roll
 - Point 8'. Same as point 8 but located over red line
 - Point 9. Intersection of the subalare crease and medial border of the lateral lip.
- A and B. Alar bases. C and D. Oral commissures.

Upper Transposition

7ab Triangle. The base of this triangle is determined by the difference between the non-cleft lip height¹⁻⁶ and the distance 9-c-e-8 at the cleft side. The height of this triangle is equal to the distance between points 9 and B. The rotational incision is the distance 9-B.

Middle Transposition

cde Triangle. The base of the triangle is measured as 3mm and the height of the triangle is determined by the distance from the point 4 to the point f. Distance from the point 8 to the point e is the same as the distance 3-f. Finally, the rotational incision is the distance f-4.

Lower Transposition

gh8' Triangle. The base of the triangle is determined by the difference between the cleft side's vermillion height, and the height of the triangle is determined by the distance from the point 3' to the point 2'. Distance from the point 8 to the point g is the same as the distance 3-3'. Finally, the rotational incision is the distance 3'-2'.

Final Formula:

$$e-8 = f-3$$

$$d-e = d-c = f-4$$

$$7-a = a-b = 9-B$$

$$9-c + c-e + e-8 + 7-b = 1-6$$

$$8-g + g-8' = 1-1'$$

Surgical Procedure

The medial lip incision starts at point 4 and follows the line between 7 and 3' and completed on the vermillion. A full-thickness incision is made through the cutaneous tissue and a small area of skin, vermillion, and mucosa is excised.

Dissection scissors frees the orbicularis oris muscle from the overlying skin, vermillion, and oral mucosa. After this, an appropriate downward rotation of the Cupid's bow is completed.

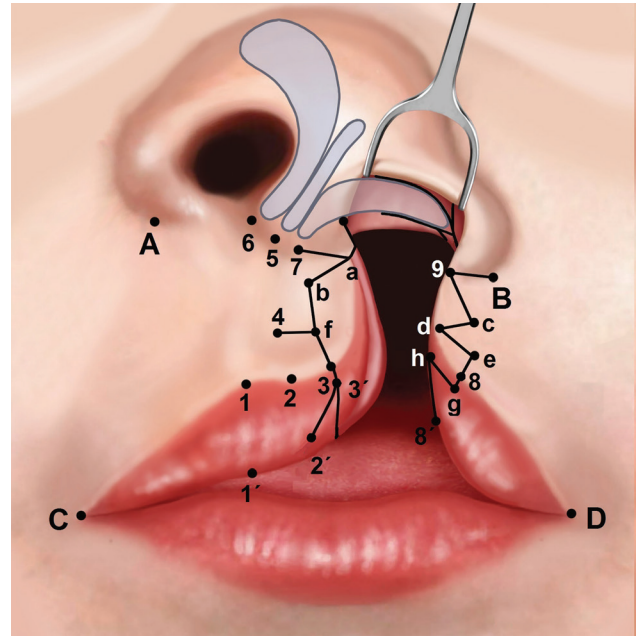


Fig. 1. The triple unilimb Z plasty for severe unilateral cleft lip deformity: preoperative view. A and B, Alar bases. C and D, Oral commissures.

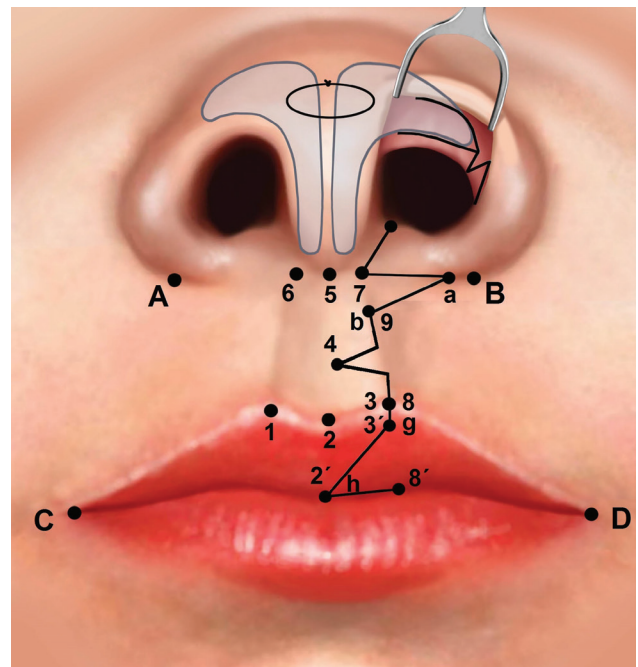


Fig. 2. The triple unilimb Z plasty for severe unilateral cleft lip deformity: postoperative view. A and B, Alar bases. C and D, Oral commissures.

Lateral segment incision starts at point 9 and follows the line to point 8 and finally 8'. This incision continues upward from point 9 following the lower piriform rim as necessary, depending on the width of the cleft. Finally, the advancement flap is released freeing the attachment of the base of the nasal ala from the piriform fossa.

The lateral lip segment incision is completed on the vermilion markings and upper buccal sulcus. These incisions and skin and vermilion resection create the 3 triangular flaps, 2 cutaneous and 1 in the vermilion; and 2 rectangular mucosal flaps are elevated from the cleft margins and used one above the other for oral mucosa repair.

The orbicularis oris muscle and the nasal fascicle of the levator labii superioris alaeque nasi are freed from their abnormal insertion in the alar base area and upper alveolar cleft margin and are turned down. Then the levator alaeque nasi is transposed and sutured to the caudal septum to correct the nostril sill.

Muscle and mucosa repairs are performed using 5-0 absorbable sutures, and dermal interrupted sutures are placed between medial and lateral skin segments. Finally, the skin closure is performed using absorbable (7/0 Vicryl or 6/0 catgut fast absorbing) skin sutures in a simple interrupted form. The nose deformity is repaired primarily using the V-Y-Z technique.

RESULTS

Demographic and other characteristics (number, age, gender, side of cleft, and cleft width) of the 168 patients included in this study are presented as supplemental information (see table, Supplemental Digital Content 1, which lists the operative characteristics of the studied patients with severe unilateral complete cleft lip nose. [n: 168]; <http://links.lww.com/PRSGO/B506>). This method lets the surgeons achieve an adequate symmetry of the upper lip (Figs. 3, 4). Rates of non-desirable outcomes were low, and the most common were long lip and development of a hypertrophic scar. Low rate of lip revision and hypertrophic scar have been observed in the operative group of patients [25/168 (14.88 %) and 17/168 (10.11 %)], respectively.

DISCUSSION

During the first 10 years of my practice as cleft surgeon, the Millard technique⁹ was used, obtaining variable results. An increased rate of hypertrophic scar and lip's asymmetry was observed during this period. Undesirable outcomes using this technique were primarily observed in patients with complete unilateral cleft lip with more tissue deficiency, and the same finding has been observed by Fisher,⁴ Tennison,¹⁰ and Randall.¹¹

A study published by the author compared three techniques for unilateral cleft lip repair (Millard's, Millard's modification, and triple unilimb Z-plasty) and concluded that the rotation advancement method is limited to addressing severe forms of unilateral cleft lip.⁶

An individual management of unilateral cleft lip is required to achieve better surgical outcomes; therefore, the author's protocol for unilateral cleft lip and palate considers a different technique for each type of cleft lip according to the severity of the cleft.

The main advantages of this innovative technique are preservation of lip tissues, improvement of lateral segment deficiency, and use of similar tissues for lip and nose repair. A limitation of the triple unilimb Z plasty technique would be the difficulty for secondary repair due to the multiple scars. For these reasons, the technique must be carefully

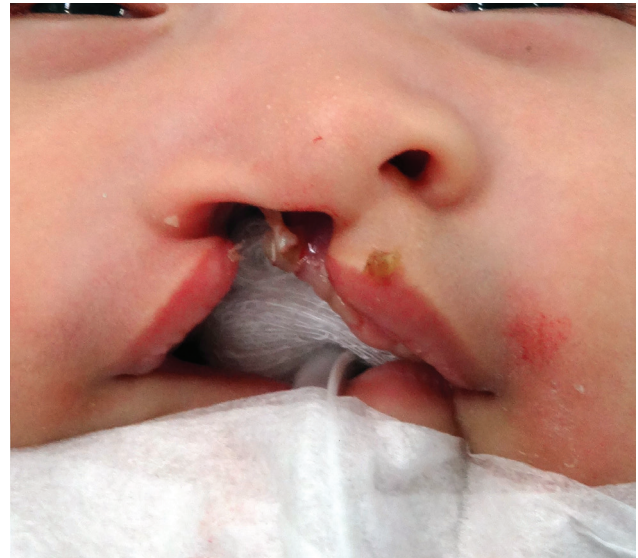

Fig. 3. Preoperative view of a 3-months-old patient with severe unilateral cleft lip deformity (discrepancy between cleft and non-cleft side lip height is 8 mm).

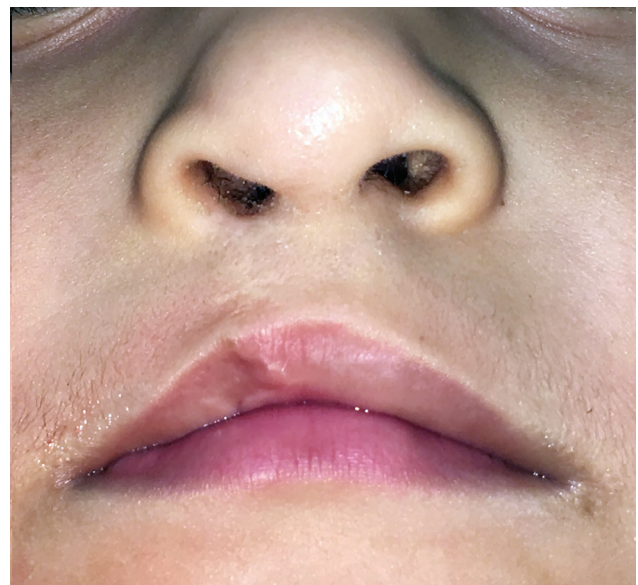

Fig. 4. Postoperative front view of the patient after surgery, illustrating cosmetic improvement of the lip and nose using the proposed method after 5 years.

planned and the relevant areas be measured before performing a repair to prevent non-desirable outcomes.

The rate of lip revision is acceptable considering the degree of severity and compared with the rate of lip revisions published by different authors (15%–21%).^{12,13} Development of hypertrophic scar was low in the operative group of patients in comparison with the reported rate for Spanish patients (10.11 versus 32.2 %).¹³

CONCLUSIONS

The presented technique is a good alternative to address severe forms of unilateral cleft lip. This method represents

an alternative for cleft lips with increased lateral segment tissue deficiency, providing adequate lip symmetry.

Prof. Percy Rossell-Perry, MD, PhD, FACS
 120 Schell St, Apt 1503, Miraflores
 Lima 18, Peru
 E-mail: prossellperry@hotmail.com;
prossellperry@gmail.com

REFERENCES

1. Rossell-Perry P. New diagram for cleft lip and palate description: The clock diagram. *Cleft Palate Craniofac J*. 2009;46:305–313.
2. Sitzman TJ, Giroto JA, Marcus JR. Current surgical practices in cleft care: Unilateral cleft lip repair. *Plast Reconstr Surg*. 2008;121:261e–270e.
3. Chowdri NA, Darzi MA, Ashraf MM. A comparative study of surgical results with rotation-advancement and triangular flap techniques in unilateral cleft lip. *Br J Plast Surg*. 1990;43:551–556.
4. Fisher DM. Unilateral cleft lip repair: An anatomical subunit approximation technique. *Plast Reconstr Surg*. 2005;116:61–71.
5. Rossell-Perry P, Gavino-Gutierrez AM. Upper double-rotation advancement method for unilateral cleft lip repair of severe forms: classification and surgical technique. *J Craniofac Surg*. 2011;22:2036–2042.
6. Rossell-Perry P. A 20 year experience in unilateral cleft lip repair: From Millard to the triple unilimb Z plasty technique. *Ind J Plast Surg*. 2016; 49: 48–57.
7. Noordhoff MS. Reconstruction of vermilion in unilateral and bilateral cleft lips. *Plast Reconstr Surg*. 1984;73:52–61.
8. Nakajima N. Primary repair of an incomplete unilateral cleft lip. *Br J Plast Surg*. 1998; 51: 511–516.
9. Millard DR Jr. A radical rotation in single harelip. *Am J Surg*. 1958;95:318–322.
10. Tennison CW. The repair of the unilateral cleft lip by the stencil method. *Plast Reconstr Surg (1946)*. 1952;9:115–120.
11. Randall P. A triangular flap operation for the primary repair of unilateral clefts of the lip. *Plast Reconstr Surg Transplant Bull*. 1959;23:331–347.
12. Zhang Z, Miyabe M, Morioka D, et al. Incidence of secondary lip correction for children with unilateral cleft lip. *Annals Plast Surg*. 2019; 83: 424–428.
13. Soltani AM, Francis CS, Motamed A, et al. Hypertrophic scarring in cleft lip repair: A comparison of incidence among ethnic groups. *Clin Epidemiol*. 2012;4:187–191.