

Surgical management and outcomes of levamisole-induced vasculitis in a burn center: A case series



Mya Abousy, BA,^a Scott Sylvester, MD,^a David Milek, MD,^b C. Scott Hultman, MD, MBA, FACS,^a and Julie Caffrey, DO, MS^a
Baltimore, Maryland and Rochester, New York

Key words: cocaine; levamisole; levamisole-induced necrosis syndrome; levamisole-induced vasculitis; vasculitis.

INTRODUCTION

Levamisole is an anthelmintic drug initially used to treat parasitic worm infections in addition to various cancers and immunologic disease processes such as rheumatoid arthritis, lichen planus, and Crohn's disease due to its immunomodulatory properties.¹ However, levamisole was withdrawn from the market in 1999 because of reported side effects, including agranulocytosis and skin vasculitis.^{2,3} In the veterinary world, it continues to be used as a deworming medication.² Studies have also suggested that levamisole may lead to central nervous system complications, such as leukoencephalopathy.⁴ As of 2019, approximately 80% of the cocaine consumed in the United States was contaminated with levamisole to potentiate the stimulatory effects of cocaine and increase its bulk.^{2,5} Levamisole-induced vasculitis typically presents as a purpuric rash, which typically arises on the ears, cheeks, face, extremities, buttocks, and thighs.⁶ The rash may exhibit areas of necrosis and can progress to a full-thickness wound. Histology typically demonstrates thrombotic or leukocytoclastic vasculitis and sometimes vascular occlusion.² Though the diagnosis is one of exclusion, the aforementioned cutaneous manifestations, a history of cocaine use, arthralgias, leukopenia, and positive anti-neutrophil cytoplasmic antibody (ANCA) titers should raise suspicion for levamisole-induced vasculitis.⁷

If levamisole-induced vasculitic wounds progress to full-thickness necrosis, surgical intervention may be required.^{5,6} To date, there is no widely-accepted

Abbreviations used:

ANA:	anti-nuclear antibody
BLE:	bilateral lower extremities
MPO:	myeloperoxidase
NPWT:	negative-pressure wound therapy
p-ANCA:	perinuclear anti-neutrophil cytoplasmic antibodies
PR3:	proteinase 3
TBSA:	total body surface area
VAC:	vacuum-assisted closure

standardized treatment algorithm for full-thickness, necrotic wounds due to this disease despite the continuous increase in cases and severer presentations in the recurrences, all the more increasing the necessity to evaluate treatment options to determine the most efficient approach.³ Though there are case series that have resulted in the development of guidelines and/or recommendations for surgical treatment of levamisole-induced vasculitis based on a minimal number of patient cases, such publications are scarce, and further examples are needed in order to provide a comprehensive algorithm.^{8,9} This study presents data on 4 patients with levamisole-induced vasculitis with a view to evaluating their surgical management and contributing to the scarce body of literature that discusses management of this condition when it reaches full-thickness necrosis.

METHODS

This was an Institutional Review Board-exempt retrospective review of 4 patients with

From the Department of Plastic and Reconstructive Surgery, Johns Hopkins School of Medicine, Baltimore^a; and Department of Surgery, University of Rochester School of Medicine.^b

Funding sources: None.

Correspondence to: Julie Caffrey, DO, MS, Johns Hopkins Bayview Medical Center, Department of Plastic and Reconstructive Surgery, 4940 Eastern Avenue, Adult Burn Center, Suite P3-4-11, Baltimore, MD 21224. E-mail: Jcaffrey5@jhmi.edu.

JAAD Case Reports 2021;13:36-42.

2352-5126

© 2021 by the American Academy of Dermatology, Inc. Published by Elsevier, Inc. This is an open access article under the CC BY-NC-ND license (<http://creativecommons.org/licenses/by-nc-nd/4.0/>).

<https://doi.org/10.1016/j.jidcr.2021.04.028>

levamisole-induced vasculitis. Inclusion criteria consisted of patients over the age of 18 treated at our regional burn center for levamisole-induced vasculitis between October 2014 and October 2019. Pregnant or incarcerated patients and patients under the age of 18 were excluded. Patient demographics, medical history, laboratory findings, images, and operative notes were reviewed. Data was analyzed using Microsoft Excel. Two cases were selected for further elaboration.

RESULTS

All patients were Caucasian, and 3 of 4 were women (Table 1). The average age upon admission was 54.8 years.

CASE DESCRIPTIONS

Upon initial hospital presentation, cocaine was detected by urine toxicology analysis for all patients, although levamisole was not in 3 of 4 patients. This is likely due to levamisole's short half-life of 5.6 hours, leaving only 3%-5% of the drug present in the urine within 48 hours of use.² Patient 2 was the only patient who tested positive for levamisole.

The route of ingestion, timing of use, and duration of cocaine use was unknown, except patients 1 and 3, who presented following cocaine inhalation.

Patient 1 presented with painful bullae, epigastric pain, and arthralgias lasting for 3 days after using cocaine via inhalation. Upon physical exam, she was found to have 25 × 15 cm vasculitic patches and hemorrhagic bullae on the anterior surface of her thighs bilaterally and lesions on the lateral aspect of the right shin with dark eschar concerning for necrosis. All lower-extremity lesions drained clear fluid. The upper extremities exhibited smaller lesions on the dorsal surfaces of the hand bilaterally. This was her second incidence of levamisole-induced vasculitis, with the first being 2 years previously, and the present lesions appeared to be a progression of her previous lesions. This patient further demonstrated microscopic hematuria with a normal creatinine level, and renal ultrasound revealed obstructive renal stones. Computed tomography of the abdomen revealed splenic infarction. A skin biopsy showed necrotizing leukocytoclastic vasculitis.

Patient 2 presented with a non-healing right lower-extremity (RLE) wound lasting for 4 months and a rash developing over the past 2 days, which began on his RLE and progressed to his groin. He had been seen at another hospital 4 months previously upon noticing the non-healing RLE wound, and a presumptive diagnosis of levamisole-induced vasculitis was made. His vital signs were stable, and his

physical exam was unremarkable, apart from an 8 x 5-cm necrotic-appearing skin ulcer on the right anterior shin with surrounding areas of purpura. Though the patient denied cocaine use for the past 20 years, urine toxicology analysis was positive for both cocaine and levamisole. Wound cultures performed upon admission grew *Klebsiella oxytoca*, *Citrobacter freundii*, *Pseudomonas aeruginosa*, and *Enterococcus faecalis*. The patient had a history of stage III chronic kidney disease, and urinalysis revealed microscopic hematuria and proteinuria, which prompted a renal biopsy for evaluation of glomerulonephritis. While the patient was not found to have glomerulonephritis, there was evidence of chronic interstitial disease with nonspecific immunoglobulin deposition. The skin biopsy demonstrated leukocytoclastic vasculitis with focal thrombosis and fibrinoid degeneration of the dermal small vessels.

The remaining 2 patients are discussed in further detail below. The lower extremities were the most common location of the vasculitis (all patients) followed by the upper extremities (3 of 4), and anterior trunk (2 of 4). All patients presented with a mixture of partial- and full-thickness lesions. The affected total body surface area (TBSA) measured upon initial hospital admission ranged from 5%-40%.

Laboratory findings

Three of 4 patients presented with a previous diagnosis of hepatitis C, and all patients had leukopenia. Moreover, all patients had increased C-reactive protein levels. Immunologic testing demonstrated anticardiolipin antibody positivity in 4 of 4 patients, anti-myeloperoxidase (MPO) antibody positivity in 2 of 4, anti-proteinase 3 (PR3) antibody positivity in 2 of 4 patients, perinuclear antibody (p-ANCA) positivity in 3 of 4, anti-nuclear antibody (ANA) positivity in 1 of 4, and anti-double-stranded DNA (dsDNA) antibody positivity in 1 of 4 patients (Table 1).

Levamisole-induced vasculitis is thought to be an autoimmune-mediated vasculitis. p-ANCA has been reported to be present in 86%-100% of levamisole-induced vasculitis cases, while c-ANCA is found in nearly 50%.^{2,10} In a report of 30 patients with ANCA positivity associated with cocaine ingestion, all patients were found to MPO positive, while half were PR3 positive.¹⁰ Dual positivity for MPO and PR3 has been thought to be a marker of drug-induced vasculitis, though this is not necessary for a definitive diagnosis.¹¹ The specific antigens giving rise to these ANCA-positive immunologic patterns remain to be identified.² The literature reports that patients with levamisole-induced vasculitis often have additional

Table I. Characteristics of the patients in the case series

Case	Sex	Age	Location of vasculitis	TBSA (%)	Lab findings	Surgical management	No. of surgeries	Days in hospital	Postoperative complications
1	F	51	BLE, BUE	5	Hep C, cardiolipin, MPO, PR3, p-ANCA, ↑CRP	Excision of wounds, allografting, autografting, VAC placement	3	60	None
2	M	59	RLE	5	Hep C, MPO, cardiolipin, ↑CRP	Excision of wounds, allografting, autografting, VAC placement	3	56	Graft failure
3	F	53	Face, ears, BUE, anterior trunk, BLE	40	ANA, dsDNA, p-ANCA, PR3, cardiolipin, ↑CRP	Excision of wounds, allografting, synthetic skin application, autografting, incision and drainage of complex post-op abdominal wall abscess, VAC placement	19	128	CAUTI, graft failure, wound infection, bacteremia, Torsade's, delirium
4	F	56	BUE, BLE, anterior trunk, flank	25	Hep C, p-ANCA, cardiolipin, ↑CRP	Excision of wounds, xenografting, allografting, VAC placement, autografting, CO ₂ fractional laser treatment	13	134	Wound infection

ANA, Anti-nuclear antibody; BLE, bilateral lower extremities; BUE, bilateral upper extremities; CAUTI, catheter-associated urinary tract infection; CRP, C-reactive protein; dsDNA, double-stranded DNA; F, female; HEP C, hepatitis C; M, male; MPO, myeloperoxidase; P-ANCA, perinuclear anti-neutrophil cytoplasmic antibodies; PR3, proteinase 3; RLE, right lower-extremity; TBSA, total body surface area; VAC, vacuum-assisted closure.

immunologic markers, including ANA, anticardiolipin, dsDNA, and lupus anticoagulant, among others¹¹; one study demonstrated ANA positivity in 14 of 17 patients and anticardiolipin positivity in 3 of 9 patients, while another case study of 6 patients revealed 100% anticardiolipin positivity.¹²

Wound care

Patient 1: Soap and water with daily dressing changes.

Patient 2: Silver sulfadiazine was applied twice daily to the wounds.

Patient 3: Initial wound care consisted of mafenide acetate (Sulfamylon) mixed with saline for a total of 10 mL every 6 hours. After a month of hospitalization, her wound care was transitioned to weekly wound vacuum-assisted closure (VAC) changes.

Patient 4: Mafenide acetate (Sulfamylon) mixed with saline for a total of 10 mL every 6 hours and amphotericin.

Surgical management and outcomes

All patients underwent staged excision and debridement of their wounds within 1-4 days of initial hospital presentation followed by allografting. Further debridement and allograft exchange was

performed based on wound evaluation. Autograft of the wound was performed following staged excision, when the wound appeared healthy and suitable. Furthermore, all patients received negative-pressure wound therapy (NPWT) throughout their stay. One patient underwent xenografting prior to autografting and postoperative CO₂ fractional laser treatment for hypertrophic scarring.

The postoperative complications arising in this patient population included graft failure (2 of 4 patients), catheter-associated urinary tract infection (1 of 4), bacteremia (1 of 4; *P aeruginosa* bacteremia), delirium (1 of 4), and Torsades de pointes (1 of 4). Wound infection was present in 2 of the 4 patients. The average length of hospitalization was 94.5 days, involving an average of 9.5 total surgeries per patient, with an inpatient mortality of 0%.

Patient 3 was found to have a catheter-associated urinary tract infection one day following her second surgery, which was an excision of the wounds on her bilateral upper extremities, right flank, bilateral lower extremities (BLE), and abdomen with first allograft placement. Her urine cultures grew more than 100,000 colony-forming units (CFU) of *Escherichia coli* and more than 100,000 CFU of *P aeruginosa*. This catheter-associated urinary tract infection was thought to be exclusively related to

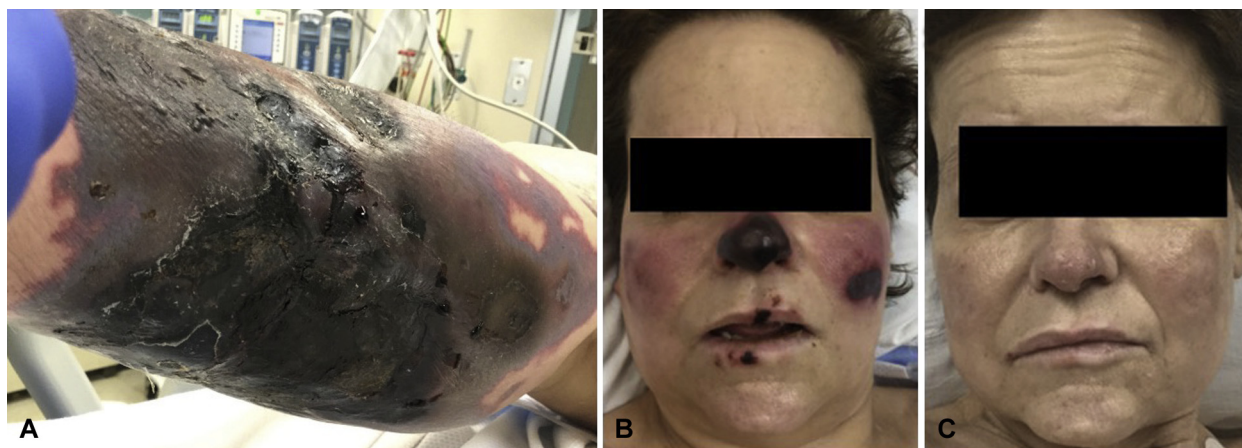

Fig 1. Levamisole-induced vasculitis causing necrotic wounds on the bilateral and upper extremities lower (**A**, right lower-extremity), nasal tip, left cheek, lips (**B**), ears, and anterior aspect of the trunk. The patient's facial wounds healed well after treatment (**C**).

surgery. Patient 3 was also found to have *P aeruginosa* bacteremia from her infected wounds. This bacteremia was detected after her seventh surgery, which consisted of wound bed preparation of her BLE wounds and bilateral wound VAC placement.

Patients 3 and 4 experienced wound infection. The wound infection in patient 3 was detected at multiple stages: upon presentation, the patient's wounds grew multidrug-resistant *P aeruginosa*, methicillin-sensitive *Staphylococcus aureus*, *E coli*, and coagulase-negative staphylococci. After her second surgery (excision of bilateral upper extremities, right flank, BLE, and abdomen with first allograft), she had superinfection of her donor graft sites which grew *E coli*, *P aeruginosa*, *E faecalis*, and coagulase-negative staphylococci. After her 13th surgery (third debridement and wound VAC replacement of bilateral lower-extremity wounds), her cultures grew *E coli*, *Morganella morganii*, *P aeruginosa*, and *Bacteroides fragilis*.

The wound infection in patient 4 was first detected from the intraoperative cultures taken from the eighth surgery (excisional biopsy of left-thigh wounds and third round of excisional preparation of her bilateral thighs). Her left-thigh wounds developed 2 pigmented patches, which were concerning for a fungal infection. Cultures were positive for *Klebsiella*, *P aeruginosa*, methicillin-resistant *S aureus*, and *Candida*.

Representative cases

Case 3. This patient is a 54-year-old woman, who presented to the emergency department with generalized body pain, fever, and a 3-day history of necrotic wounds in multiple body regions in the setting of cocaine inhalation. Upon presentation, all vital signs were stable. Her physical exam was

notable for bleeding nasal lesions and necrotic wounds surrounded by a purpuric vasculitis on the BLE (**Fig 1, A**), face (**Fig 1, B**), ears, bilateral upper extremities, and anterior trunk. Her medical history is significant for iron-deficiency anemia, proteinuria, and leukopenia. The patient reported similar wounds 18 months prior to her presentation, which had been treated with surgical debridement and grafting, making this her second episode of levamisole-induced vasculitis. She did not have any extracutaneous manifestations throughout her hospital stay. Skin biopsy demonstrated non-leukocytoclastic vasculitis with thrombosis of small- and medium-sized vessels. She was subsequently diagnosed with 40% TBSA levamisole-cocaine induced vasculitis. Immunologic testing revealed positive titers for anti-dsDNA antibody, ANA, cardiolipin antibody, PR3 antibody, and p-ANCA, along with elevated C-reactive protein.¹⁰ While anti-MPO antibody positivity is mostly found in p-ANCA-positive cases, it is not a requirement for diagnosis, and anti-PR3 antibody positivity is found in roughly half of patients with p-ANCA positivity.¹⁰ Anticardiolipin, ANA, and anti-dsDNA antibodies are reported to be concurrently found in patients with this condition, though they have not been as thoroughly studied as the ANCA markers.¹⁰

The patient's wound cultures from her lower extremities tested positive for *Klebsiella*, *S aureus*, *P aeruginosa*, and *Enterococcus*. The patient underwent 19 surgical procedures, comprising debridement, excision, allografting, and autografting of her wounds. However, her nasal lesions were allowed to heal by demarcation, separation of eschar, and secondary intention (**Fig 1, C**). This decision was made due to the lesions being on her face, since surgery would have left prominent scars in a

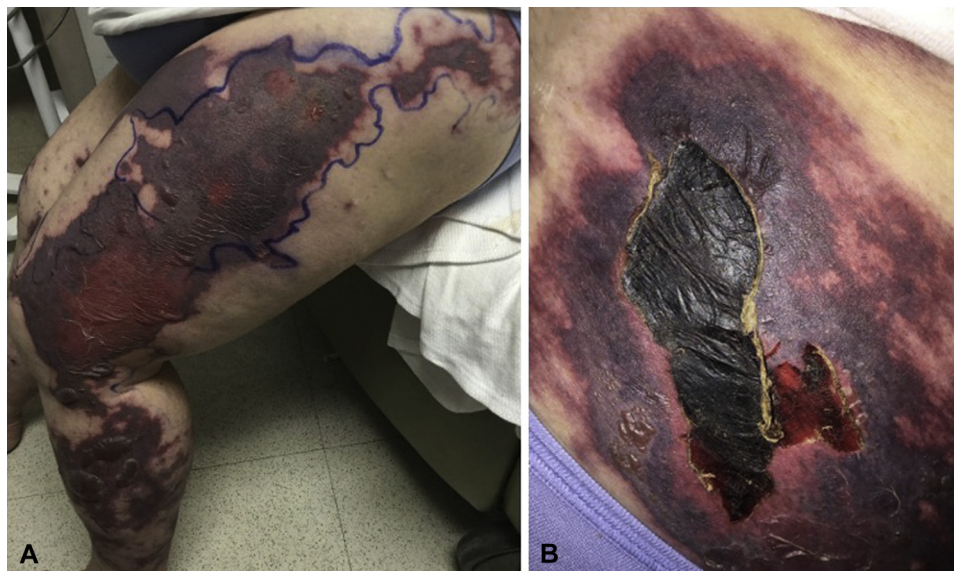


Fig 2. Levamisole-induced vasculitis in a 56 year-old woman who presented with 25% TBSA necrotic wound surrounded by purpuric vasculitis on the bilateral upper and lower extremities (**A**) left lower-extremity, (**B**) right flank.

noticeable area. She had multiple losses of her skin grafts, compounded with wound infections, leading to necrotic and foul-smelling wounds requiring repeat operations. Her hospital stay was further complicated by an abdominal wall abscess, which was encountered during her second procedure and subsequently excised and drained. She required a surgery nearly every week, where wounds were continuously debrided and where NPWT was applied. She was discharged to a nursing facility after 117 days in the hospital, once her wounds had markedly improved.

Approximately 9 months later, this patient presented to the emergency department with a 6-day history of BLE erythema, swelling, pain and purulent discharge, and necrosis on the nose tip and bilateral cheeks. The patient last used cocaine 5 days prior to admission and presented with chills but denied fever. Her lower-extremity wounds were managed with Silvadene, and her facial wounds were managed with bacitracin. Her wounds healed well within 11 days, at which point she was discharged from the hospital.

Case 4. This patient is a 55-year-old woman with a past medical history significant for hepatitis C virus infection and polysubstance use, including cocaine. She initially presented to the emergency department after accidental exposure to sodium lauryl sulfoacetate, while preparing homemade bath products. Upon presentation, her vital signs were stable, though she presented with acute worsening of disseminated purpuric vasculitis and necrotic wounds on the bilateral upper and lower extremities (Fig 2, A), flank

(Fig 2, B), and lower abdomen. According to the patient's husband, it was likely that she had used cocaine 3 days prior to presentation, and urine toxicology analysis was positive for cocaine and benzodiazepines. The route of ingestion and duration of use of cocaine was unknown. Apart from the cutaneous findings, the physical exam was otherwise noncontributory, and she had no extracutaneous manifestations of the disease. She first noticed the vasculitis on her left arm before the sulfoacetate exposure, and it progressively spread throughout her body. The patient also had a history of admission 2 years previously for BLE wounds at another hospital with limited documentation availability, though it is assumed that this was also due to levamisole-induced vasculitis, given her history of cocaine use. Due to her worsening respiratory status and concern for inhalation injury, the patient was intubated and admitted to the Burn Intensive Care Unit. A biopsy demonstrated leukocytoclastic vasculitis with marked erythrocyte extravasation within the papillary and mid-dermis. Her rheumatologic laboratory results were remarkable for p-ANCA positivity and elevated C-reactive protein (14.8 mg/L). She was initially treated with supportive local wound care and systemic steroid therapy and continued her care on an outpatient basis. However, she missed her outpatient appointments with the burn surgery team, and her wounds worsened over time, which ultimately led to re-admission 24 days following her initial admission for cellulitis, full-thickness skin necrosis of 25% TBSA, and secondary infection, for which she required surgical debridement.

During her prolonged hospital stay, she underwent a total of 13 surgical procedures, including serial debridement of necrotic wounds, xenografting, allografting, NPWT placements, and autografting. Her inpatient course was complicated by wound infection requiring further debridement. She was ultimately discharged to her home after 134 days. Over the course of the months after her hospital discharge, the patient developed symptomatic hypertrophic scarring on her left upper and BLE, which was treated with fractional CO₂ laser.

CONCLUSIONS

We have presented 4 cases of severe levamisole-induced vasculitis, which ultimately progressed to full-thickness necrosis. Our study serves to strengthen the evidence that patients with full-thickness necrosis induced by levamisole-induced vasculitis greatly benefit from not only immediate excision and debridement, but also from treatment in a burn center, which has the appropriate resources and training to best adapt to the unique needs of patients with this condition.

Half of the patients in this case series required 13 or more surgeries, leaving many opportunities for wound infection and other surgical complications with each surgery. Burn centers are specifically developed to handle complex wounds that require this many operations, along with all the postoperative complications that may arise. The long hospital stays and sometimes large TBSA involvement of levamisole-induced vasculitis require appropriate surgical treatment and monitoring by comprehensive surgical teams that are well-equipped to manage these types of wounds. Given the complexity and severity of the cases presented in this report, we recommend that patients with levamisole-induced vasculitis be treated in burn centers in case of progression to full-thickness necrosis. Not only do patients with levamisole-induced vasculitis require a team that can manage patients with numerous surgeries, but they also require close following by nutritionists, wound care teams, infectious disease physicians, nephrologists, and even ophthalmologists in cases of eyelid involvement. Burn centers are multidisciplinary institutions that uniquely integrate physicians, pharmacists, nutritionists, physical therapists, nurses, and social workers specifically trained to treat patients with these types of injuries.¹³ Furthermore, a 10-year retrospective review performed in 2010 demonstrated that non-burn wound admissions to burn centers had increased by 244.9%.¹³ This rise in non-burn cases due to severe skin and soft-tissue injuries necessitates that burn

specialists familiarize themselves with severe presentations of vasculitides.

Most cases of levamisole-induced vasculitis will heal with levamisole cessation, though a small subset of cases that cause full-thickness necrosis require urgent surgical intervention.⁸ Our patients recovered from this vasculopathy with a combination of urgent surgical wound debridement followed by autografting, allografting, and xenografting. While current treatment guidelines for levamisole-induced vasculitis consist of cessation of levamisole use,⁶ there are no widely adopted consensus guidelines regarding the optimal timeline for surgical management of full-thickness necrosis caused by levamisole-induced vasculitis. However, Miner et al suggest that early surgical excision (within 10 days of admission) provides optimal patient outcomes and avoids the morbidity observed with delayed excision.⁹ Other case studies recommend delayed excision (1 month after admission) in order to minimize potential graft loss.⁶ In our experience, urgent wound debridement was performed no later than 4 days following admission to remove necrotic tissue and decrease microbial contamination of the wound. Further wound debridement is performed until a healthy appearing wound bed is obtained. Autografting is only performed after the wound bed appears healthy. NPWT is utilized to granulate the wound bed with a view to preparing it for skin grafting. While the rate of partial graft loss in patients with full-thickness necrosis caused by levamisole-induced vasculitis remains higher than what is seen with burns and other wounds, we attribute this to the limited vascular supply related to the underlying disease pathology, which typically targets small- and medium-sized blood vessels. Further case reports of patients with a severe presentation of this condition and their surgical and non-surgical outcomes are required to standardize surgical approaches and optimize patient recovery, as cases of levamisole-induced full-thickness necrosis remain sparse in the current medical literature.

Conflicts of interest

None disclosed.

REFERENCES

1. Marquez J, Aguirre L, Muñoz C, Echeverri A, Restrepo M, Pinto LF. Cocaine-levamisole-induced vasculitis/vasculopathy syndrome. *Curr Rheumatol Rep*. 2017;19(6):36.
2. Abdul-Karim R, Ryan C, Rangel C, Emmett M. Levamisole-induced vasculitis. *Proc (Bayl Univ Med Cent)*. 2013;26(2):163-165.
3. George TC, Freet DJ, Cross JM, Huzar TF. Levamisole-induced vasculitis. *JAAPA*. 2019;32(1):23-27.
4. Xu N, Zhou W, Li S, Zhou G, Zhang N, Liang J. Clinical and MRI characteristics of levamisole-induced

- leukoencephalopathy in 16 Patients. *J Neuroimaging*. 2009;19(4):326-331.
5. Raheemullah A, Melhem M, Andruska N. Cocaine cessation for levamisole-induced vasculitis: treating the underlying disease. *J Clin Rheumatol*. 2020;26(8):e276-e278.
 6. Ching JA, Smith DJ. Levamisole-induced necrosis of skin, soft tissue, and bone: case report and review of literature. *J Burn Care Res*. 2012;33(1):e1-e5.
 7. Alekseyev K, Micaily I, Parikh N. A severe case of levamisole-induced vasculitis requiring extensive surgery and skin grafts. *J Cutan Aesthet Surg*. 2016;9(1):41-43.
 8. McEvenue G, Brichacek M, Logsetty S, Shahrokhi S. Surgical management of levamisole-adulterated cocaine induced soft tissue necrosis: case study and treatment algorithm. *J Burn Care Res*. 2017;38(3):e638-e646.
 9. Miner J, Gruber P, Perry TL. Early excision and grafting, an alternative approach to the surgical management of large body surface area levamisole-adulterated cocaine induced skin necrosis. *Burns*. 2015;41(3):e34-e40.
 10. McGrath MM, Isakova T, Renke HG, Mottola AM, Laliberte KA, Niles JL. Contaminated cocaine and antineutrophil cytoplasmic antibody-associated disease. *Clin J Am Soc Nephrol*. 2011;6(12):2799-2805.
 11. Jin Q, Kant S, Alhariri J, Geetha D. Levamisole adulterated cocaine associated ANCA vasculitis: review of literature and update on pathogenesis. *J Commun Hosp Intern Med Perspect*. 2018;8(6):339-344.
 12. Graf J, Lynch K, Yeh CL, et al. Purpura, cutaneous necrosis, and antineutrophil cytoplasmic antibodies associated with levamisole-adulterated cocaine. *Arthritis Rheum*. 2011;63(12):3998-4001.
 13. Kastenmeier A, Faraklas I, Cochran A, et al. The evolution of resource utilization in regional burn centers. *J Burn Care Res*. 2010;31(1):130-136.