



Case report

Bartholin's gland abscess a rare cause of rectovaginal fistula: A case report and literature review

F.Z. Bensardi, S. KABURA^{*}, ElAttar Layla, A. El Bakouri, M. Bouali, K. El Hattabi, A. Fadil

Service of Emergency of the Visceral Surgery, Ibn Rochd University Hospital Centre, Morocco
 Hassan II University of Casablanca, Medicine and Pharmacy Faculty, Morocco
 Department of Surgery, Ibn Rochd-Casablanca University Hospital Centre, Morocco

ARTICLE INFO

Keywords:

Rectovaginal fistula
 Bartholinitis
 Vaginal advancement flap
 Martius flap

ABSTRACT

Introduction: Rectovaginal fistula (RVF) is an abnormal communication between the vagina and the rectum. RVFs caused by Bartholin's gland infection are very rare. We present the case of recurrent rectovaginal fistula complicating a Bartholin's gland abscess successfully treated with a Martius flap. The aim of this work is to demonstrate the possibility of complication of Bartholin's gland infection by a rectovaginal fistula and the efficacy of Martius flap procedure for recurrent RVF of the low third part of the vagina.

Observation: It is a 30-year-old woman admitted to our department for recurrent RVF due to an abscess of the Bartholin's glands. She was previously treated with a vaginal advancement flap which failed with persistence of the fistula and its symptoms. The patient underwent a RVF repair by Martius flap with complete healing of the fistula.

Discussion: Rectovaginal fistula is a complex pathology with psycho-social, individual, family, religious and ethno-environmental repercussions. Its main aetiologies are obstetric, rectal surgery. Several techniques including the vaginal or anal advancement flap and the Martius flap are used for the treatment of rectovaginal fistulas. For recurrent fistulas, the Martius flap seems to be the most indicated with better results.

Conclusion: Rectovaginal fistula remain a challenge for surgeons and have major psycho-socio-economic repercussions for the patient. The complication of Bartholin's gland infection by rectovaginal fistula is rare. The Martius flap technique is the method of choice for recurrent rectovaginal fistulas of the lower third of the vagina or in association with other pathologies.

1. Introduction

Rectovaginal fistula is an abnormal communication between the vagina and the rectum with epithelialization allowing the passage of stool through the vagina [1] (Byrnes 2017). RVFs due to Bartholin's cyst infection are very rare and few cases have been reported in the literature [2] (Nasser 2014). The management of RVF is complex and represents a great challenge for the surgeon and must be individualized [3] (Lo 2016). We present the case of recurrent rectovaginal fistula secondary to Bartholinitis successfully treated with a Martius flap. The aim of this study is to confirm accordance to the literature the possibility of RVF complicating a Bartholin's gland abscess and the efficacy of Martius flap for treating the recurrent RVF of the lower third of vagina. This manuscript has been reported in line with SCARE's 2020 Criteria [4].

2. Observation

It is a 30-year-old patient with no past medical history, treated for Bartholinitis in July 2019 complicated by a rectovaginal fistula. She was operated for her fistula in December 2019 using vaginal advancement flap with the sutures leakage in postoperative after a week. The patient underwent a cleanliness stomy and was reoperated for her RVF. On the second admission in the service, the physical examination noted a functional stool diversion stoma, with normal monitoring signs and the preoperative biological assessment was unremarkable. The vaginal examination finds fistula of 0.5 mm of the low third part at the left posterolateral side of the vagina wall with sclerotic edge. The digital rectal examination notes internal hemorrhoids stage 2, with good sphincter pressure. The rectosigmoidoscopy was unremarkable. A blood count performed showed; Hg: 13.20/mm³, GB: 3900/mm³, platelets: 333000/μl. the pre-anesthetic assessment was normal.

^{*} Corresponding author at: Service of Emergency of the Visceral Surgery, Ibn Rochd University Hospital Centre, Morocco.

<https://doi.org/10.1016/j.ijscr.2021.106344>

Received 21 July 2021; Received in revised form 17 August 2021; Accepted 21 August 2021

2210-2612/© 2021 Published by Elsevier Ltd on behalf of IJS Publishing Group Ltd. This is an open access article under the CC BY-NC-ND license

(<http://creativecommons.org/licenses/by-nc-nd/4.0/>).

The patient underwent a RVF repair by Martius flap. In supine and lithotomy position, under general anesthesia, with a nasogastric tube, urinary catheter, ATBQ.

A transverse perineal incision followed by dissection of the rectovaginal septum was made (Fig. 1A), a vertical slit of the vaginal wall was made up to the fistula and then its resection (Fig. 1B). An anteroposterior vertical incision was then made at the opposite left major labia, then the bulbocavernosus muscle was dissected from the skin and the deep plane preserving its vascular pedicle from the internal pudendal artery. It was then repositioned on the posterior surface of the vagina after creating a subcutaneous tunnel (Fig. 2A,B,C&D). The fixation of the flap to the rectal mucosa and then the closure of the vaginal slit (Fig. 2E), the incisions of perineal and the labia majora were sutured with 3-0 vicryl stitches without drainage (Fig. 3). The post-operative were simple, the patient was discharged from the hospital at the fifth day with a clean appearance of the wound. The stool reversion was performed after three months and there was no symptoms or complaint for our patient.

3. Discussion

Rectovaginal fistula is a complex pathology with psycho-social, individual, familial, religious and ethno-environmental repercussions [5] (Touhidi). RVF complicates 0.1% of vaginal deliveries [3] (Lo 2016) and accounts for around 5% of anorectal fistulas, while their incidence due to a congenital malformation is less than 1% [6] (Tiwari). The fistulas that develop in the anal canal are anovaginal fistulas [7] (Guillermín). The aetiologies of RVF are very varied and include obstetric and vaginal trauma, cryptoglandular infections, inflammatory bowel disease, rectal or vaginal surgery, radiation, neoplasms and pelvic infections in adults. In children, it is especially congenital malformations that are involved [6] (Tiwari). The diagnosis of a RVF is primarily clinical by the presence of stool through the vagina [8] (Woo et al). Bartholin's glands are located bilaterally at the posterior part of the labia majora and terminate in the vestibule at about 4 a.m. and 8 a.m. at the opening of the vagina. These pea-sized glands are only palpable if the duct becomes cystic or abscessed [9] [Kim]. About 2% of women will develop a Bartholin's gland cyst or abscess in their lifetime secondary to bacterial infections [10,11] (omole 201, Soares). However, the occurrence of FRV due to infection or cyst of the Bartholin glands is exceptional and few cases

have been reported in the literature [2] (Nasser 2014). According to our research, only 4 cases had been described until 2015 and we were unable to identify another case. Our case therefore corroborates the existing data in the literature on FRV secondary to an abscess of the Bartholin's gland. Fistulas secondary to an abscess of the Bartholin glands are localized in the lower third of the vagina and therefore classified as type I according to Rosenshein or simple according to Rotenberger [7] (Guillermín). Kim described a fistula between Bartholin's glands with the rectum without involvement of the vagina [9] (Kim 2015). Our case is a simple fistula of the lower third of the vagina or type I according to Rosenshein although the etiology is not gynecological. The management of FRV presents a major challenge for the surgeons and the success rate is 45 to 70% after primary repair [3] (Lo 2016). Several techniques including the vaginal or anal advancement flap, perineoproctectomy with planar closure, sphincteroplasty and fistulectomy, coloanal anastomosis and Martius or gracilis muscle flap are the main surgical protocols used for the treatment of rectovaginal fistulas. Biological glues can also be applied in some cases. Cell therapy for rectovaginal fistula repair has been studied in various studies and promising results have been reported [12] (Scoglio 2015). The endorectal advancement flap when used as a primary procedure in the treatment of uncomplicated rectovaginal fistula and has been found to be acceptable [13] (Beksac et al). On the other hand, for recurrent fistulas, the Martius flap seems to be the most indicated with results varying from 55% to 93% according to Scoglio's series over a 10-year follow-up period [12] (Scoglio 2015). Colostomy has several indications in the treatment of RVF. Patients with severe symptoms or with other comorbidities including active Crohn's disease, postradic proctitis may benefit it to allow tissue healing and symptom relief. In some cases, a stoma may be the definitive treatment for patients with RVF, especially in patients with incontinence anal sphincters. In recurrent RVF, pelvic dissection, damaged local tissue and in tissue transposition procedures, colostomy is more indicated [14] (Abugalaza 2017). Treatment failures are very high and the techniques must be individualized [15] (Fu et al). For our case study, the patient was initially treated with the vaginal advancement flap which failed with immediate postoperative leakage. We therefore proceeded with a first colostomy followed by the treatment of FRV after one month according to the Martius flap with good results. Despite many surgical techniques used to treat RVF, there is no standardized protocol. The choice of a technique depends on the clinical

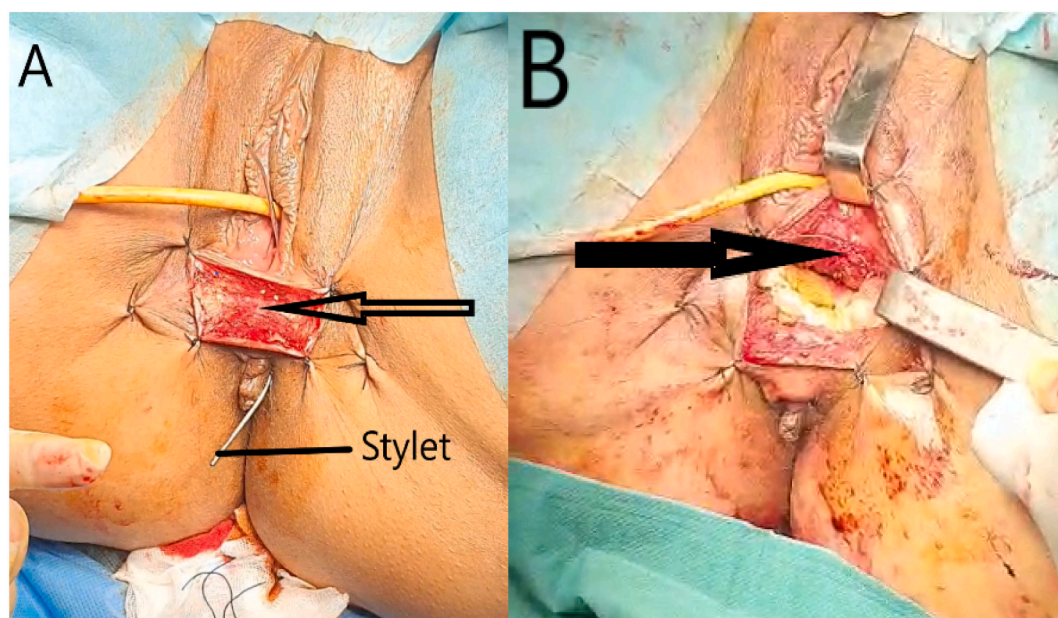


Fig. 1. Arciform perineal incision(A), rectovaginal septum dissection and the suture of the rectal and vagina fistula (B).

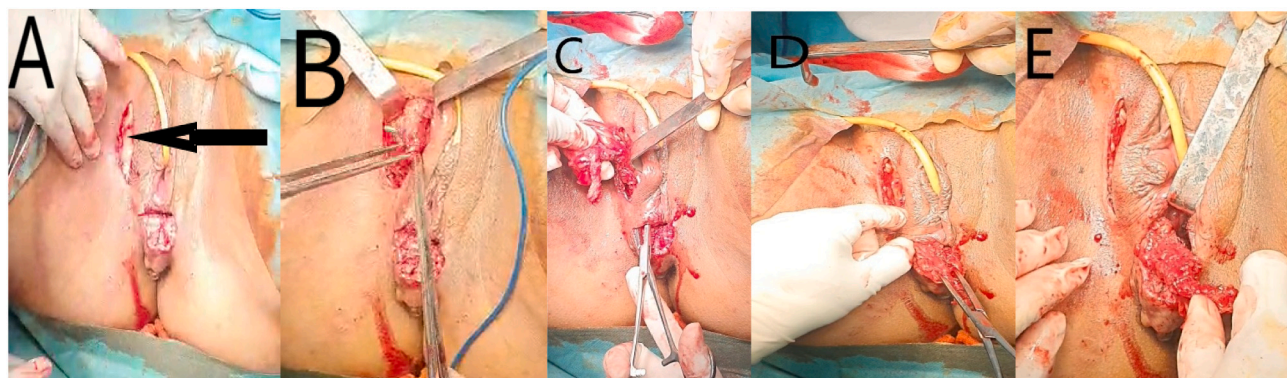


Fig. 2. Labial majora incision(A), bulbocavernosus muscle dissection(B), muscle tunelisation and transposition(C&D), martius flap transposition between the rectovaginal septum; note the Farabeuf retractor exposing the septum dissection(E).

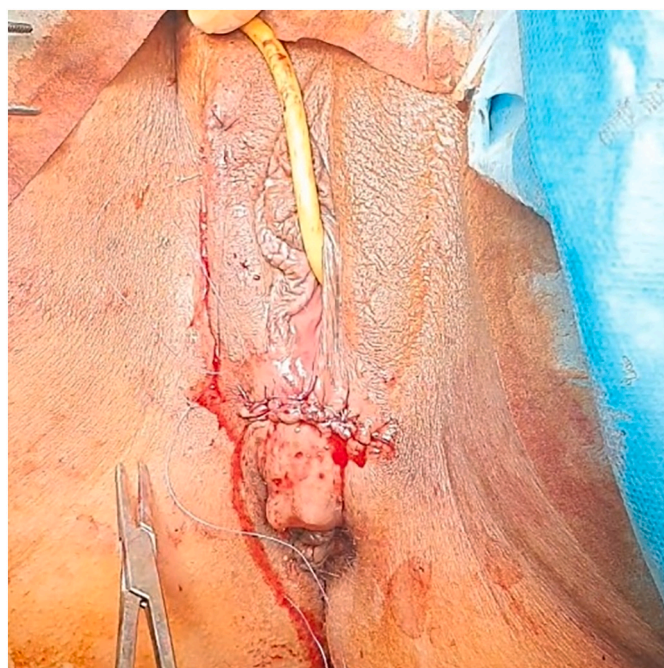

Fig. 3. The final aspect of the patient after perineal and labial majora incisions suture.

presentation and the causes of the fistula. The results obtained vary according to the series from 30 to 90% according to the clinical forms and the surgical technique used. According to Byrnes, the rates of recurrence after the initial surgical repair of the RVF are high and do not differ according to the type of procedure or by subspecialty of the patient. This case shows the possibility of complication of Bartholin's gland abscess resulting in rectovaginal fistula and the efficacy of Martius flap in treatment of recurrent RVF of the lower third part of the vagina.

4. Conclusion

Rectovaginal fistula remains a major challenge for surgeons with major psycho-socio-economic repercussions for the patient and society. RVFs secondary to infection of the Bartholin glands are rare. The Martius flap technique seems to be the best procedure for rectovaginal fistulas of the lower third of the vagina, especially in the event of recurrence or associated pathologies.

Provenance and peer review

Not commissioned, externally peer-reviewed.

Funding

No funding for research.

Ethical approval

The study is exempt from ethical approval in our institution.

Consent

Written informed consent was obtained from the patient for publication of this case report and accompanying images. A copy of the written consent is available for review by the Editor-in-Chief of this journal on request.

Guarantor

KABURA Sylvestre

CRediT authorship contribution statement

Fatima Zahra Bensardi: designed the study, wrote the protocol and the first draft of the manuscript

designed the study, wrote the protocol and the first draft of the manuscript

Sylvestre KABURA: designed the study, wrote the protocol and the first draft of the manuscript

ElAttar Layla: designed the study, wrote the protocol and the first draft of the manuscript

ElBakouri Abdelillah: managed the analyses, and the correction of the manuscript

Mounir Bouali: managed the analyses, and the correction of the manuscript

Khalid ElHattabi: managed the analyses, and the correction of the manuscript

Fadil Abdelaziz: managed the analyses, and the correction of the manuscript

All authors read and approved the final manuscript.

Declaration of competing interest

No conflicts of interest.

References

- [1] J.N. Byrnes, J.J. Schmitt, B.M. Faustich, K.C. Mara, A.L. Weaver, H.K. Chua, Outcomes of rectovaginal fistula repair, *Female Pelvic Med. Reconstr. Surg.* 23 (2) (mars 2017) 124–130.
- [2] H.A. Nasser, V.M. Mendes, F. Zein, B.Y. Tanios, T. Berjaoui, Complicated rectovaginal fistula secondary to Bartholin's cyst infection: Rectovaginal fistula, *J. Obstet. Gynaecol. Res.* 40 (4) (2014) 1141–1144, avr.
- [3] T.-S. Lo, Y.-H. Huang, A.K. Dass, N. Karim, MaC Uy-Patrimonio, Rectovaginal fistula: twenty years of rectovaginal repair: twenty years of RVF management, *J. Obstet. Gynaecol. Res.* 42 (10) (Oct 2016) 1361–1368.
- [4] R.A. Agha, T. Franchi, C. Sohrabi, G. Mathew, A. Kerwan, A. Thoma, et al., The SCARE 2020 guideline: updating consensus surgical CAse REport (SCARE) guidelines, *Int. J. Surg.* 84 (2020) 226–230, déc.
- [5] F. Touhidi Nezhad, R. Jalali, F. Karimi, Women's experiences of rectovaginal fistula: an ethno- religious experience, *BMC Women's Health* 20 (1) (2020) 130, déc.
- [6] C. Tiwari, Congenital rectovaginal fistula with anorectal agenesis: a rare anorectal malformation, *Int. J. Pediatr. Adolesc. Med.* 3 (2017).
- [7] P.H. Guillermin, B. Deval, Fistules recto-vaginales des deux tiers inférieurs du vagin, Disponible sur: in: *Pelvi-périnéologie* [Internet], Springer-Verlag, Paris, 2005, pp. 259–267 http://link.springer.com/10.1007/2-287-27807-9_29.
- [8] I.T. Woo, J.S. Park, G.-S. Choi, S.Y. Park, H.J. Kim, H.J. Lee, Optimal strategies of rectovaginal fistula after rectal cancer surgery, *Ann. Surg. Treat. Res.* 97 (3) (2019) 142.
- [9] Y.S. Kim, H.S. Han, M.W. Seo, W.S. Kim, J.H. Lee, N.K. Park, Recto-Bartholin's duct fistula: a case report, *Gynecol. Obstet. Investig.* 79 (2) (27 janv 2015) 136–138.
- [10] F. Omole, R.C. Kelsey, K. Phillips, K. Cunningham, in: *Bartholin Duct Cyst and Gland Abscess: Office Management* 99(12), 2019, p. 7.
- [11] R. Soares, T. Reis, F. Valido, C. Chaves, Bartholin's gland abscess caused by *Streptococcus pneumoniae* in a sexually active young woman, *BMJ Case Rep.* 12 (4) (2019), e228492 avr.
- [12] D. Scoglio, A. Fichera, Management of Rectovaginal Fistula, Disponible sur: in: T. M. Pawlik, S.K. Maithe, N.B. Merchant (Eds.), *Gastrointestinal Surgery* [Internet], Springer New York, New York, NY, 2015, pp. 387–398 http://link.springer.com/10.1007/978-1-4939-2223-9_37.
- [13] K. Beksac, A. Tanacan, N. Ozgul, M.S. Beksac, Treatment of rectovaginal fistula using sphincteroplasty and fistulectomy, *Obstet. Gynecol. Int.* 2018 (2018) 1–5.
- [14] M. Abu Gazala, S.D. Wexner, Management of rectovaginal fistulas and patient outcome, *Expert Rev. Gastroenterol. Hepatol.* 11 (5) (4 mai 2017) 461–471.
- [15] J. Fu, Z. Liang, Y. Zhu, L. Cui, W. Chen, Surgical repair of rectovaginal fistulas: predictors of fistula closure, *Int. Urogynecol. J.* 30 (10) (Oct 2019) 1659–1665.