

## Unilateral macular drusen in a young female

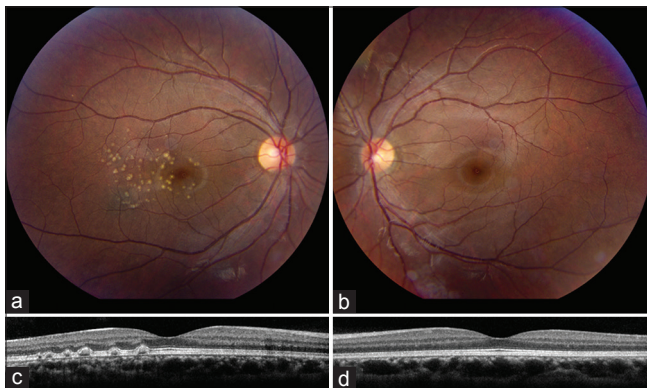
### Case

A 27-year-old female with a history of systemic lupus erythematosus (SLE) was referred for evaluation of unilateral macular drusen. Family history of familial drusen was negative. On examination, visual acuity was 20/25 in the right eye (OD) and 20/20 in the left eye (OS). Funduscopy OD revealed numerous (>80) yellowish temporal perifoveal lesions (A). Funduscopy OS was normal (B).

### What is Your Next Step?

- Start the Age-Related Eye Disease Study (AREDS) vitamins
- Enhanced depth imaging optical coherence tomography (EDI OCT)
- Fluorescein angiography
- Bevacizumab intravitreal injection.

Illustration – [Fig. 1].



### Findings

EDI OCT OD showed drusen-like deposits (DLDs) located between the retinal pigment epithelium and Bruch membrane, with the largest DLD measuring 232  $\mu\text{m}$  in base and 89  $\mu\text{m}$  in elevation (C). Macula OS was intact by EDI OCT (D). Further systemic work-up revealed no evidence of glomerulonephritis.

**Diagnosis:** Drusen like deposits in SLE.

**Correct Answer:** B.

### Discussion

Ocular involvement in SLE can occur in up to 30% of patients.<sup>[1]</sup> Asymptomatic choroidal alteration and DLDs in patients with SLE glomerulonephritis were first described in 2011 by Baglio *et al.* using indocyanine green angiography.<sup>[2]</sup> Later in 2017, Invernizzi *et al.* documented presence of DLDs, with or without glomerulonephritis, however, they found that patients with glomerulonephritis demonstrated more DLDs per eye, larger DLDs, and DLDs involvement of >3 quadrants (all  $P < 0.03$ ).<sup>[3]</sup> We advise patients with SLE to have a thorough dilated funduscopy examination. A screening EDI OCT should be considered in patients with SLE.

### Declaration of patient consent

The authors certify that they have obtained all appropriate patient consent forms. In the form the patient(s) has/have given his/her/their consent for his/her/their images and other clinical information to be reported in the journal. The patients understand that their names and initials will not be published and due efforts will be made to conceal their identity, but anonymity cannot be guaranteed.

### Financial support and sponsorship

Nil.

### Conflicts of interest

There are no conflicts of interest.

### References

- Palejwala NV, Walia HS, Yeh S. Ocular manifestations of systemic lupus erythematosus: A review of the literature. *Autoimmune Dis* 2012;2012:290898.
- Baglio V, Gharbiya M, Balacco-Gabrieli C, Mascaro T, Gangemi C, Di Franco M, *et al.* Choroidopathy in patients with systemic lupus erythematosus with or without nephropathy. *J Nephrol* 2011;24:522-9.
- Invernizzi A, dell'Arti L, Leone G, Galimberti D, Garoli E, Moroni G, *et al.* Drusen-like deposits in young adults diagnosed with systemic lupus erythematosus. *Am J Ophthalmol* 2017;175:68-76.

**Kareem Sioufi<sup>1,2</sup>, Katherine E Talcott<sup>1</sup>, Marc J Spirm<sup>1</sup>**

<sup>1</sup>The Retina Service of Wills Eye Hospital, Mid Atlantic Retina, Philadelphia, Pennsylvania, PA, <sup>2</sup>Storm Eye Institute, Medical University of South Carolina, Charleston, South Carolina, USA

**Correspondence to:** Dr. Kareem Sioufi, Retina Service, Wills Eye Hospital, Thomas Jefferson University, 840 Walnut Street, Philadelphia, 19107-5109 PA, USA. E-mail: kareem.sioufi@gmail.com

Access this article online	
<b>Quick Response Code:</b>	<b>Website:</b> www.ijo.in
	<b>DOI:</b> 10.4103/ijo.IJO_1349_18

This is an open access journal, and articles are distributed under the terms of the Creative Commons Attribution-NonCommercial-ShareAlike 4.0 License, which allows others to remix, tweak, and build upon the work non-commercially, as long as appropriate credit is given and the new creations are licensed under the identical terms.

**For reprints contact:** reprints@medknow.com

**Cite this article as:** Sioufi K, Talcott KE, Spirm MJ. Unilateral macular drusen in a young female. *Indian J Ophthalmol* 2018;66:1531.