

## LETTER TO THE EDITOR

# Leukocytoclastic vasculitis after coronavirus disease 2019 vaccination

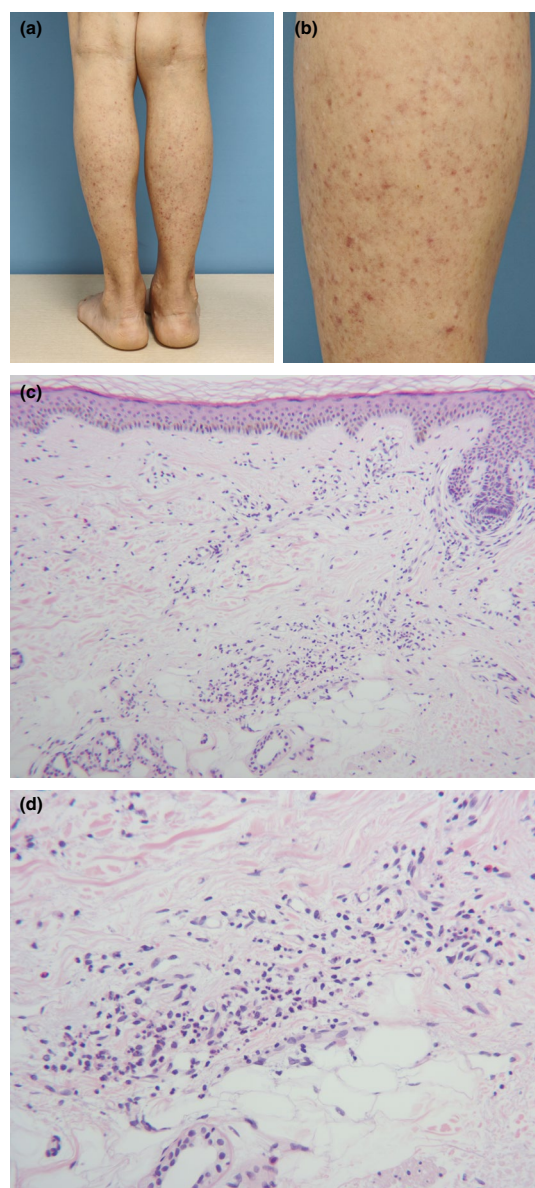
Dear Editor,

The ChAdOx1 nCoV-19 vaccine (AstraZeneca<sup>®</sup>; UK) has been administered against severe acute respiratory syndrome coronavirus 2 (SARS-CoV-2). Injection-site skin reaction has been reported as a common adverse drug reaction; however, there has been only one report of vasculitis so far with the ChAdOx1 nCoV-19 vaccine.<sup>1</sup> Herein, we present a case of new-onset leukocytoclastic vasculitis following ChAdOx1 nCoV-19 vaccination.

A 68-year-old Korean woman presented with asymptomatic erythematous to purpuric non-blanching macules on both lower extremities for 2 days (Figure 1a,b). Concomitant symptoms including fever, arthralgia, abdominal pain, or hematuria were denied. She had received the first vaccination of ChAdOx1 nCoV-19 7 days prior to the onset of lesions. She denied any medical history, including vasculitis or medication. Laboratory finding revealed decreased C3 and C4 levels (68.3 and 2.4 mg/dL, respectively), but all other tests, including complete blood count, renal function test, urinalysis, and antinuclear antibody, were unremarkable. Histopathological examination showed perivascular and interstitial inflammatory infiltration with lymphocytes, neutrophils, eosinophils, and leukocytoclasia, with extravasation of a few erythrocytes (Figure 1c,d). She was treated with oral methylprednisolone (4 mg/day for 1 week, followed by 2 mg/day for 2 weeks), colchicine 1.2 mg/day, and topical methylprednisolone for 3 weeks. The lesions resolved and did not relapse after cessation of treatment. The lesion slightly recurred on the legs with the second vaccination, but resolved spontaneously in a few days.

Polymorphic dermatological manifestations have been reported in coronavirus disease 2019 (COVID-19) patients. Giovanni *et al.*<sup>2</sup> classified COVID-19-associated cutaneous manifestations into six clinical patterns, among which purpuric vasculitic patterns represented 7.1–15.4%. Histopathological findings of vasculitic lesions vary, including leukocytoclastic vasculitis, perivascular neutrophilic and lymphocytic infiltration, fibrin deposition, or endothelial swelling.<sup>2</sup> Meanwhile, correlation with immunoglobulin A vasculitis has been described in case systemic manifestations were accompanied or skin lesions were distributed to extensive area of the body.<sup>3</sup>

The SARS-CoV-2 spike protein, which is a major component of the vaccine, has been suggested to activate alternative complement pathway through binding to mannose-binding lectin.<sup>4</sup> Similar to complement-mediated endotheliopathy in COVID-19 patients, the SARS-CoV-2 spike protein may have induced complement activation or autoimmunity, thereby leading to the inflammation of the cutaneous microvasculature.



**FIGURE 1** (a) Clinical manifestation presented as erythematous to purpuric non-blanching macules on both lower legs. (b) Closer image of the lesion. (c) Histopathological findings of the perivascular and interstitial inflammatory cell infiltration in superficial to mid-dermis (hematoxylin–eosin [HE], original magnification  $\times 100$ ). (d) Higher magnification image showing infiltration of lymphocytes with several neutrophils and eosinophils, accompanying leukocytoclasia, endothelial cell swelling, and sparse extravasation of erythrocyte (HE,  $\times 200$ )

Unlike the case of cutaneous vasculitis after other COVID-19 vaccinations such as BNT162b2 (Pfizer®; USA),<sup>5</sup> the decreased C3 and C4 levels in our patient reveal a clearer association between vascular injury and complement activation. The different characteristics of vaccines, including gene delivery mechanism or adjuvants, might cause variable manifestations of post-vaccination vasculitis. Lower level of viral antigen load in vaccination compared to COVID-19 might have contributed to favorable and self-limiting prognosis of vasculitis, indicating that the triggering factor of the skin lesion resolved in a short period of time.







Vasculitis may not be considered as a contraindication of vaccination, as it appears to occur in very exceptional cases and shows favorable prognosis. Nonetheless, clinicians should monitor cutaneous adverse reactions by vaccines. Further investigations would be necessary to clarify the characteristics of vasculitis following COVID-19 vaccination.

#### ACKNOWLEDGMENTS

None.

#### CONFLICT OF INTEREST

None declared.

Woo Jung Jin   
 Sang Woo Ahn   
 Seung Hee Jang   
 Seong Min Hong   
 Jung Eun Seol   
 Hyojin Kim 

Department of Dermatology, College of Medicine, Busan Paik Hospital, Inje University, Busan, Korea

#### Correspondence

Hyojin Kim, Department of Dermatology, College of Medicine, Busan Paik Hospital, Inje University, 75 Bokji-ro, Busanjin-gu, Busan 47392, Korea.  
 Email: derma09@hanmail.net

#### ORCID

Woo Jung Jin  <https://orcid.org/0000-0003-4499-8901>  
 Sang Woo Ahn  <https://orcid.org/0000-0003-4820-3870>  
 Seung Hee Jang  <https://orcid.org/0000-0002-8343-209X>  
 Seong Min Hong  <https://orcid.org/0000-0002-8273-7350>  
 Jung Eun Seol  <https://orcid.org/0000-0002-3029-9635>  
 Hyojin Kim  <https://orcid.org/0000-0003-0987-4938>

#### REFERENCES

1. Guzmán-Pérez L, Puerta-Peña M, Falkenhain-López D, Montero-Menárguez J, Gutiérrez-Collar C, Rodríguez-Peralto JL, et al. Small-vessel vasculitis following Oxford-AstraZeneca vaccination against SARS-CoV-2. *J Eur Acad Dermatol Venereol*. 2021. <https://doi.org/10.1111/jdv.17547>
2. Genovese G, Moltrasio C, Berti E, Marzano AV. Skin manifestations associated with COVID-19: Current knowledge and future perspectives. *Dermatology*. 2021;237:1–12.
3. Sandhu S, Chand S, Bhatnagar A, Dabas R, Bhat S, Kumar H, et al. Possible association between IgA vasculitis and COVID-19. *Dermatol Ther*. 2021;34:e14551.
4. Yu J, Yuan X, Chen H, Chaturvedi S, Braunstein EM, Brodsky RA. Direct activation of the alternative complement pathway by SARS-CoV-2 spike proteins is blocked by factor D inhibition. *Blood*. 2020;136:2080–9.
5. Erler A, Fiedler J, Koch A, Schütz A, Heldmann F. A case of leukocytoclastic vasculitis after vaccination with a SARS-CoV2-vaccine - a case report. *Arthritis Rheumatol*. 2021. <https://doi.org/10.1002/art.41910>