

Contents lists available at [ScienceDirect](http://www.sciencedirect.com)

## International Journal of Surgery Case Reports

journal homepage: [www.casereports.com](http://www.casereports.com)

# Ectopic spleen: An easily identifiable but commonly undiagnosed entity until manifestation of complications



Konstantinos Blouhos, Konstantinos A. Boulas\*, Ilias Salpigktidis, Nikolaos Baretas, Anestis Hatzigeorgiadis

Department of General Surgery, General Hospital of Drama, Drama, Greece

## ARTICLE INFO

### Article history:

Received 25 March 2014

Accepted 14 May 2014

Available online 28 May 2014

### Keywords:

Wandering spleen

Ectopic spleen

Torsion

Strangulation

Rupture

## ABSTRACT

**INTRODUCTION:** Ectopic spleen is an uncommon clinical entity as splenectomy for treatment of ectopic spleens accounts for less than 0.25% of splenectomies. The most common age of presentation is childhood especially under 1 year of age followed by the third decade of life.

**PRESENTATION OF CASE:** The present report refers to a patient with torsion of a pelvic spleen treated with splenectomy. The patient exhibited a period of vague intermittent lower abdominal pain lasted 65 days followed by a period of constant left lower quadrant pain of increasing severity lasted 6 days. On the first 65 days, vague pain was attributed to progressive torsion of the spleen which resulted in venous congestion. On the last 6 days, exacerbation of pain was attributed to irreducible torsion, infraction of the arterial supply, acute ischemia, strangulation and rupture of the gangrenous spleen. Diagnosis was made by CT which revealed absence of the spleen in its normal position, a homogeneous pelvic mass with no contrast enhancement, free blood in the peritoneal cavity, and confirmed by laparotomy.

**DISCUSSION:** Clinical manifestations of ectopic spleen vary from asymptomatic to abdominal emergency. Symptoms are most commonly attributed to complications related to torsion. Operative management, including splenopexy or splenectomy, is the treatment of choice in uncomplicated and complicated cases because conservative treatment of an asymptomatic ectopic spleen is associated with a complication rate of 65%.

**CONCLUSION:** Although an ectopic spleen can be easily identified on clinical examination, it is commonly misdiagnosed until the manifestation of complications in adulthood.

© 2014 The Authors. Published by Elsevier Ltd. on behalf of Surgical Associates Ltd. This is an open access article under the CC BY-NC-ND license (<http://creativecommons.org/licenses/by-nc-nd/3.0/>).

## 1. Introduction

Wandering spleen, also known as ectopic spleen, is an uncommon clinical entity characterized by hypermobility of the spleen due to laxity or absence of the normal ligaments that attach the spleen to the left upper quadrant. This allows the spleen to essentially drop to the lower abdomen by the force of gravity attached only to its abnormally elongated vascular pedicle. Clinical manifestations vary from asymptomatic to abdominal emergency.<sup>1</sup> Common complications of a wandering spleen include torsion of its pedicle, compression of another organ by the spleen or the pedicle, and susceptibility of the spleen to trauma. Symptoms are most commonly attributed to complications related to irreducible torsion

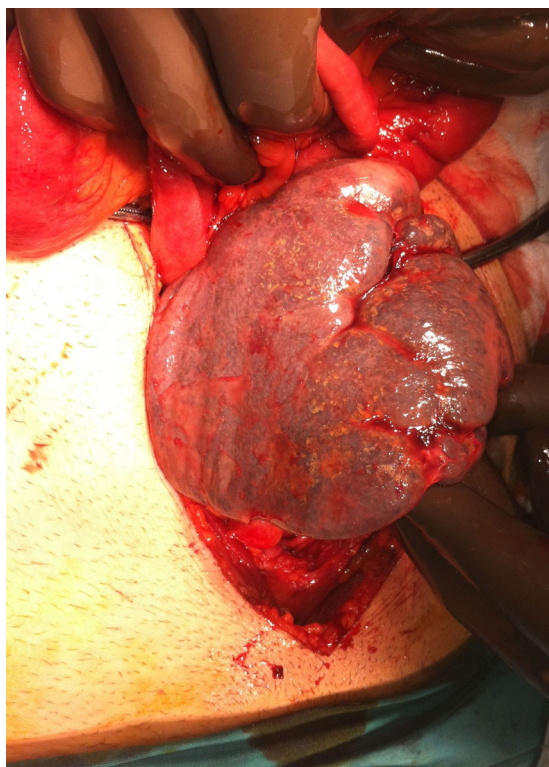
which produces venous congestion, arterial infraction, strangulation and rupture of the spleen. Treatment of choice is splenopexy for an uncomplicated or complicated but viable wandering spleen and splenectomy for a non-viable spleen.<sup>2</sup> Herein, we present a case of a patient with progressive torsion of a pelvic spleen causing recurrent abdominal pain and eventually spleen strangulation and rupture.

## 2. Presentation of case

A 46-year-old male was admitted to the emergency department complaining of constant left lower quadrant abdominal pain of increasing severity for the last 6 days. Direct questioning revealed a history of mild, intermittent lower abdominal pain for the past 65 days. The patient was febrile (38.8°C), had tachycardia (118 beats/min) and blood pressure of 90/50 mmHg. Physical examination revealed abdominal distention, predominantly in the hypogastric region due to a tender mass causing dullness on percussion suprapubically. Pelvic mass or pelvic peritonitis arised from a variety of causes were included in the differential diagnosis. Laboratory findings revealed leukocytosis of 16,400/mm<sup>3</sup>,

\* Corresponding author at: Department of General Surgery, General Hospital of Drama, End of Hippokratous Street, 66100 Drama, Greece. Tel.: +30 6937265675; fax: +30 2513501559.

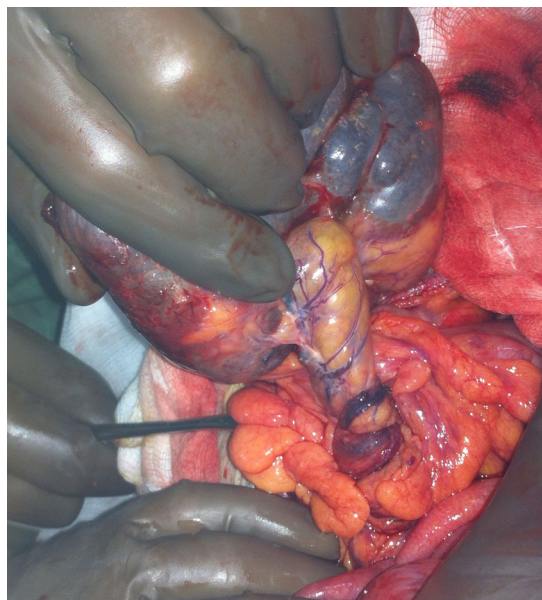
E-mail addresses: [kostasblu@hotmail.com](mailto:kostasblu@hotmail.com) (K. Blouhos), [katerinantwna@hotmail.com](mailto:katerinantwna@hotmail.com) (K.A. Boulas), [alkis.salpigktidis@windowslive.com](mailto:alkis.salpigktidis@windowslive.com) (I. Salpigktidis), [nikos.baretas@yahoo.gr](mailto:nikos.baretas@yahoo.gr) (N. Baretas), [ahatzigeorgiadis@gmail.com](mailto:ahatzigeorgiadis@gmail.com) (A. Hatzigeorgiadis).



**Fig. 1.** A free-floating spleen, attached only to its abnormally elongated vascular pedicle, was discovered among loops of small intestine and sigmoid colon within the pelvis. The spleen was enlarged, congested, strangulated and ruptured at its lower pole.

normal erythrocytes and platelets count. Abdominal X-rays revealed increased pelvic radio-opaqueness, few dilated loops of small intestine, and displacement of the splenic flexure in the normal spleen position. Emergency CT revealed absence of the spleen in its normal position, a homogeneous pelvic mass with no contrast enhancement pushing aside the sigmoid colon, free blood in the peritoneal cavity around the mass, and a normal urinary tract. The absence of the spleen in its normal position and the non-enhancement of the pelvic mass made the diagnosis of an ectopic strangulated spleen undeniable.

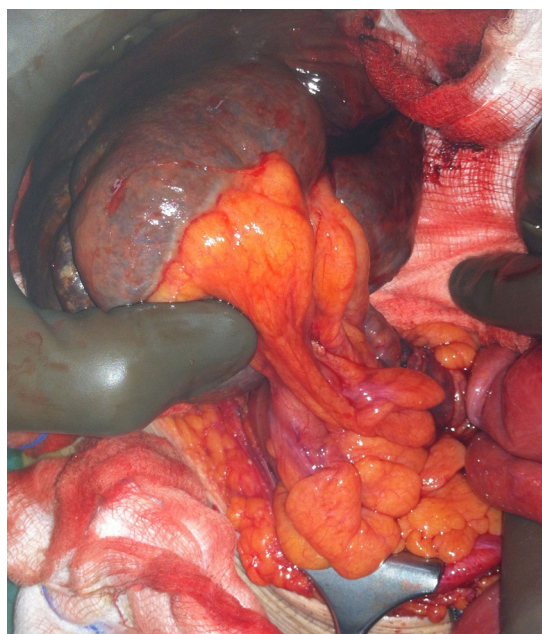
The patient underwent emergency exploratory laparotomy. During surgery, the spleen was enlarged (23 cm × 18 cm × 12 cm), located inside the pelvis, attached to an abnormally elongated torted pedicle (19 cm), and adhered to the greater omentum and intestine (none of splenic ligaments were present) (Fig. 1). The spleen was strangulated due to the 760° clockwise twists of its pedicle (Fig. 2), and ruptured at its lower pole (2 cm in depth, not evolving a trabecular vessel grade II laceration). After adhesiolysis, a counterclockwise derotation was performed (Fig. 3); however, the organ continued to appear non-viable and total splenectomy was performed. Thorough investigation revealed no evidence of accessory spleens in the left upper quadrant, the bowel mesentery, the greater omentum and the pelvis. During exploration, a Meckel's diverticulum was discovered and removed. Histology revealed acute thrombotic changes in arteries and veins of the splenic hilum, with diffuse hemorrhagic and ischemic infarcts of the spleen. The postoperative course was uneventful and the patient was discharged on the fifth postoperative day without any complication. Vaccination against *Pneumococcus*, *Meningococcus* and *Haemophilus influenza* were administered two weeks after surgery.



**Fig. 2.** Strangulation of the spleen occurred due to a 760° clockwise torsion of its vascular pedicle.

### 3. Discussion

Wandering spleen is a rarely diagnosed clinical entity. According to our knowledge less than 500 cases of patients with recurrent abdominal pain or abdominal emergency caused by a wandering spleen have been reported in the literature. Moreover, splenectomy for treatment of a wandering spleen account for less than 0.25% of splenectomies in reported series.<sup>3</sup> Wandering spleen is 7 times more common in females than males after age 10 and 2.5 times more common in males than females under the age of 1 year. The most common age of presentation is childhood especially under 1 year of age followed by the third decade of life, and is more frequently seen in females of reproductive age.<sup>4</sup>



**Fig. 3.** The spleen continued to appear non-viable despite the counterclockwise derotation.

Wandering spleen occurs because of either extreme laxity or absence of the normal ligaments that attach the spleen to its fixed position in the left upper quadrant. Several ligaments maintain the spleen in its normal position. Three of these ligaments are virtually always present (except in the condition of the wandering spleen), and two may be present to variable extents. The three ligaments, that are constantly present, are the splenogastric ligament, the splenorenal ligament and the splenocolic ligament. The two ligaments, that are variably present, are the splenoportal and the splenophrenic ligament. Absence or laxity of the above mentioned ligaments allows the spleen to essentially drop to the lower abdomen in either the right or the left lower quadrant by the force of gravity attached by its elongated vascular pedicle.<sup>5</sup> The etiology of a wandering spleen is multifactorial. It occurs most probably as a result of congenital anomalies in the development of the dorsal mesogastrium and the absence or malformation of the normal splenic suspensory ligaments. Conditions associated with wandering spleen include enlargement or absence of a kidney, splenomegaly and previous pregnancy. Splenomegaly and pregnancy are thought to contribute to the laxity of the supporting structure by direct effect of gravity and estrogen respectively.<sup>6</sup>

Clinical manifestations vary from asymptomatic to abdominal emergency. Symptoms may remain limited or absent for long periods of time, but complications related to torsion, compression of another organ by the spleen or its pedicle and susceptibility of the spleen to trauma are quite common. Symptoms are most commonly attributed to complications related to torsion. Initially, irreducible torsion produces venous congestion as a result of which the spleen becomes edematous and enlarged. Eventually, progressive torsion results in infraction of the arterial supply, acute ischemia, strangulation, necrosis and rupture of the congested and gangrenous spleen.<sup>7</sup> More frequently, patients are admitted due to a non specific chronic pelvic pain related to splenomegaly or pressure on adjacent organs. The most common physical finding is a palpable lower abdominal mass representing the abnormally enlarged torted spleen. Laboratory tests are usually nonspecific, but may occasionally reveal evidence of hypersplenism or functional asplenia. Definitive diagnosis is reached by imaging modalities. Ultrasonography, nuclear scintigraphy, CT and MRI can prove useful in revealing the nature of a pelvic mass of unknown entity and confirm the diagnosis of an ectopic spleen.<sup>8</sup>

Operative management is the treatment of choice in uncomplicated and complicated cases because conservative treatment of an asymptomatic wandering spleen is associated with a complication rate of 65%.<sup>9</sup> The wandering spleen is ideally for laparoscopic splenectomy because it is generally free from attachments and other organs. The treatment for a wandering spleen as an incidental finding at laparotomy or if the torsion can be corrected

and the spleen appears to be viable is splenopexy. Splenopexy has been successful in preventing complications of wandering spleen while preserving the splenic function. Different techniques have been described in the literature by surgeons. They applied open or laparoscopic techniques with or without using a mesh and peritoneal flaps.<sup>10</sup> If the spleen appears gangrenous, then a splenectomy must be performed. As the torsion involves the vascular pedicle, partial splenectomy or splenic implantation of the totally strangulated spleen is usually unattainable. However, partial infraction of a wandering spleen necessitating partial splenectomy and splenopexy or splenectomy and splenic implantation has been reported in the literature.<sup>11</sup>

#### 4. Conclusion

The present report was referred to a patient with progressive torsion of a pelvic spleen causing recurrent abdominal pain and eventually spleen strangulation and rupture. The patient exhibited a period of vague intermittent lower abdominal pain lasted 65 days followed by a period of constant left lower quadrant pain of increasing severity lasted 6 days. On the first 65 days, vague pain was attributed to progressive torsion which resulted in venous congestion and enlargement of the spleen. On the last 6 days, exacerbation of pain was attributed to irreducible torsion, infraction of the arterial supply, acute ischemia, strangulation, necrosis and rupture of the congested and gangrenous spleen. Although the presence of the ectopic spleen could be easily identifiable on serial physical examinations since childhood, it was diagnosed in adulthood due to manifestation of complications.

#### Conflicts of interest

None.

#### Funding

None.

#### Ethical approval

Written informed consent was obtained from the patient for publication of this case report and accompanying images.

#### Author contributions

Konstantinos Boulas, Salpigktidis I and Baretas N equally contributed to the writing of this paper. Konstantinos Blouhos, Anestis Hatzigeorgiadis and Konstantinos Boulas performed the operation.

#### Key learning points

- The presence of an ectopic spleen can be easily identified on serial physical examinations since childhood.
- However it is commonly misdiagnosed until the manifestation of complications in adulthood.

#### References

1. King CR, Mansuria S. Pelvic pain in the presence of wandering spleen. *J Minim Invasive Gynecol* 2013;**20**:549–50.
2. Bhanumathi V, Balkishan B, Masood SV. Torsion of wandering spleen in a woman presenting as emergency. *Indian J Surg* 2013;**75**:59–61.
3. Magowska A. Wandering spleen. A medical enigma, its natural history and rationalization. *World J Surg* 2013;**37**:545–50.
4. Allen KB, Andrews G. Pediatric wandering spleen – the case for splenopexy: review of 35 reported cases in the literature. *J Pediatr Surg* 1989;**24**:432–5.
5. Varga I, Galfiova P, Adamkov M, Danisovic L, Polak S, Kubikova E, et al. Congenital anomalies of the spleen from an embryological point of view. *Med Sci Monit* 2009;**15**:269–76.
6. Buehner M, Baker MS. The wandering spleen. *Surg Gynecol Obstet* 1992;**175**:373–87.



7. Brown CV, Virgilio GR, Vazquez WD. Wandering spleen and its complications in children: a case series and review of the literature. *J Pediatr Surg* 2003;**38**:1676–9.
8. Gayer G, Zissin R, Apter S, Atar E, Portnoy O, Itzhak Y. CT findings in congenital anomalies of the spleen. *Br J Radiol* 2001;**74**:767–72.
9. Dawson JH, Roberts NG. Management of the wandering spleen. *Aust N Z J Surg* 1994;**64**:441–4.
10. Fukuzawa H, Urushihara N, Ogura K, Miyazaki E, Matsuoka T, Fukumoto K, et al. Laparoscopic splenopexy for wandering spleen: extraperitoneal pocket splenopexy. *Pediatr Surg Int* 2006;**22**:931–4.
11. Fonseca AZ, Ribeiro Jr M, Contrucci O. Torsion of a wandering spleen treated with partial splenectomy and splenopexy. *J Emerg Med* 2013;**44**:33–6.

#### Open Access

This article is published Open Access at [scimedirect.com](http://scimedirect.com). It is distributed under the [IJSCR Supplemental terms and conditions](#), which permits unrestricted non commercial use, distribution, and reproduction in any medium, provided the original authors and source are credited.