

Rapid recovery following fulminant meningococemia complicated by myocarditis in a 15-year-old Nepalese girl: a case report

Pratyush Shrestha¹
Nabin K Shrestha²
Smith Giri³

¹Department of Surgery, College of Medical Sciences, Bharatpur, Nepal;

²Department of Internal Medicine, BP Koirala Institute of Health Sciences, Dharan, Nepal; ³Department of Internal Medicine, Tribhuvan University Teaching Hospital, Kathmandu, Nepal

Introduction: Fulminant meningococemia is a relatively rare life-threatening disease caused by *Neisseria meningitidis*. The clinical presentation is varied, but, when associated with myocarditis, it carries a particularly poor prognosis. We report a case of a patient with fulminant meningococemia who subsequently developed severe myocardial dysfunction and successfully recovered within a period of 14 days of hospitalization.

Case presentation: A 15-year-old girl presented with headache, fever, body ache, and diarrhea for 1 day, and ecchymotic rash over her body for 4 hours. Blood cultures confirmed infection with *N. meningitidis*. After 6 days in the hospital, the patient developed anasarca, elevated jugular venous pressure, and shock. The patient was managed with intravenous ceftriaxone and captopril. Over the next 3 days the patient rapidly improved and started walking.

Conclusion: Meningococemia complicated by myocarditis has an extremely poor prognosis with high mortality. Our case suggests that recovery from a severe myocardial dysfunction can occur rapidly within a few days. Prompt recognition and management in this case might have contributed to the patient's rapid recovery from myocarditis.

Keywords: *Neisseria meningitidis*, Nepal, recovery, shock

Introduction

Fulminant meningococemia is a relatively rare life-threatening disease caused by *Neisseria meningitidis*,¹ and is perhaps the most rapidly lethal form of septic shock in humans. It differs from most other forms of septic shock by the prominence of hemorrhagic skin lesions (petechiae, purpura, etc).²

N. meningitidis is a gram-negative diplococcus that causes a wide variety of diseases in the human body. Meningitis, associated with fever, headache, and nuchal rigidity, is the most common pathologic presentation of meningococcal disease, and has a mortality rate of 5%–10%.³ Fulminant meningococemia, as the name suggests, is the most severe form of infection by *N. meningitidis*.³

Meningococcal infection can present in epidemic or endemic form. Multiple factors have been identified that increase the transmissibility of *N. meningitidis*, including active or passive inhalation of tobacco smoke, upper viral respiratory tract infection, drought seasons, and overcrowding.⁴

Fulminant meningococemia is associated with high mortality, with most deaths occurring in the first 24 hours.⁵ The clinical presentation is varied, but, when associated with myocarditis, carries a poor prognosis.⁶ We report a case of fulminant meningococemia complicated by myocarditis, with rapid recovery.

Correspondence: Smith Giri
Department of Internal Medicine,
Tribhuvan University Teaching Hospital,
Maharajgunj, PO Box 1524,
Kathmandu, Nepal
Tel +977 01 4107738
Fax +977 01 4418186
Email smithgiri963@gmail.com

Case presentation

A 15-year-old Nepalese girl presented to the emergency department of BP Koirala Institute of Health Sciences (BPKIHS), Dharan, Nepal, with complaints of headache, fever, body ache and diarrhea for 1 day, and rash that had been evolving on her face and limbs for 4 hours. She had been taken first to a local practitioner in her local village health center in a state of shock (blood pressure 80/40 mmHg), and been administered 200 mg hydrocortisone and 2 g ceftriaxone intravenously, as well as a bolus dose of 1 L normal saline, before being referred to BPKIHS.

On presentation, she had a temperature of 99.8°F, heart rate of 112/minute, and blood pressure of 100/70 mm of Hg. Meningeal signs were absent. There were numerous ecchymotic lesions over her face, chest, back, abdomen, arms, and legs, as shown in Figure 1. There were no other findings of significance.

Investigations revealed a platelet count of 82,000/ μ L and an international normalized ratio (INR) of 2.6. Blood cultures were positive for *N. meningitidis*. Lumbar puncture performed within a few hours of presentation yielded a mild lymphocytic pleocytosis with normal cerebrospinal fluid (CSF) protein and glucose levels. CSF culture did not reveal any organisms.

Considering local sensitivity patterns, the patient was treated with 2 g intravenous (IV) ceftriaxone every 12 hours. Over the next few days, she developed shortness of breath and worsening edema. Fever persisted and the patient remained bedridden with severe malaise. On the sixth day of hospitalization, she was noted to have anasarca, an elevated jugular venous pulse, shock with blood pressure of 80/40 mmHg,

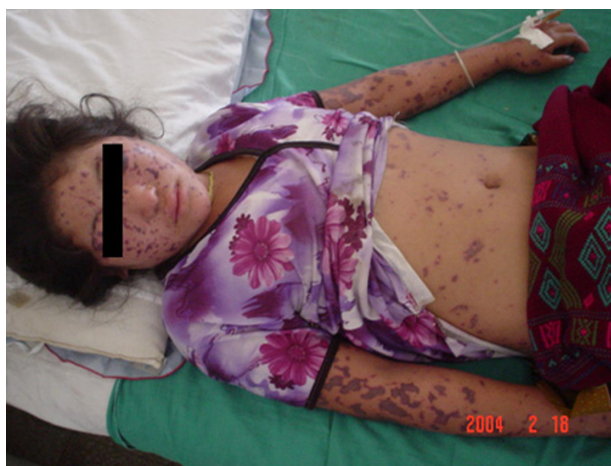

Figure 1 Purpuric rash of meningococemia at presentation. Reprinted with permission from The Cleveland Clinic Foundation. Shrestha NK. Infectious disease emergencies. In: Carey WD, editor. *Current Clinical Medicine*, 2nd ed. Philadelphia, PA: Saunders Elsevier; 2010:706.¹⁷ Copyright © 2010 The Cleveland Clinic Foundation.

and a third heart sound (S_3) gallop on cardiac auscultation. The patient did not complain of any chest pain. A chest radiograph revealed an enlarged cardiac silhouette, as shown in Figure 2, and electrocardiogram (ECG) showed T wave flattening in lead aVF and T wave inversions in leads III, V_1 , V_2 and V_3 . Total creatinine kinase (CK) and CK-MB were elevated (302 and 15 U/L, respectively). Troponin levels were slightly elevated at 0.6 U/L (normal < 0.1 U/L). An echocardiography revealed global myocardial hypokinesia with an ejection fraction of 40% (normal 55%–70%).

A diagnosis of myocarditis complicating acute meningococemia was made. The patient was started on captopril 6.25 mg thrice daily and the dose was gradually increased to 25 mg thrice daily over the next 3 days, with close monitoring of blood pressure. The patient was also given intermittent doses of furosemide (20 mg IV) and maintenance fluids. Over the next 3 days, the patient defervesced, started walking, and gradually returned to her premorbid state. She received ceftriaxone for a total of 7 days. Follow-up echocardiography revealed an ejection fraction of 60% with good mobility of the myocardium. She was discharged after a 14-day hospitalization with complete clinical recovery except for the rash, which was fading away at the time of discharge. The patient was advised to attend follow-up after 2 weeks, but did not show up.

Discussion

Meningococemia is a relatively rare disease caused by *N. meningitidis*. Although the exact incidence of the disease in Nepal is unknown, the annual incidence in the United States and Europe has been suggested to be 0.35 cases per 100,000 and 1 case per 100,000, respectively.⁷ The presence

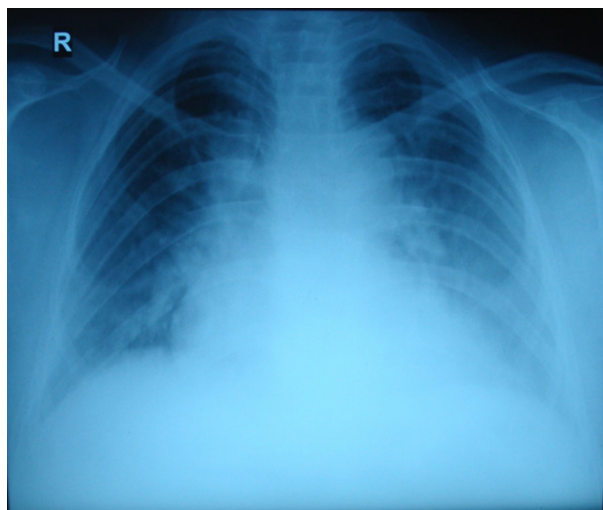


Figure 2 Chest X-ray, posteroanterior view showing obvious cardiomegaly.

of a capsule is a major virulence factor, and six capsular groups have been described as causing the majority of invasive disease (A, B, C, W-135, X, and Y). Among these, groups A, C, and W-135 are known to be common in Asia and Africa.⁸ In epidemic settings in third-world countries, case fatality rates as high as 70% have been recorded.⁹

Transmission of meningococci occurs through direct contact with respiratory droplets. The mucosa of the upper respiratory tract of human beings is the major reservoir and, in most instances, the disease is acquired through close contact with asymptomatic carriers.⁸ Clinical manifestations of *N. meningitidis* infection are varied. Initial symptoms may mimic a viral disease; however, within a few days, more localized features develop in cases that develop meningitis, such as headache, nausea, stiff neck, and vomiting.⁸ The most characteristic clinical feature of fulminant meningococemia is the development of petechial or ecchymotic rashes. However, meningococemia can lead to complications such as massive adrenal hemorrhage, disseminated intravascular coagulation, arthritis, heart problems such as pericarditis and myocarditis, neurological problems such as deafness and peripheral neuropathy, and peripheral gangrene.¹⁰

Our patient presented with fever, shock, and ecchymotic rash. The differential diagnoses considered at the time are shown in Table 1. However, the rashes were somewhat typical of meningococemia (Figure 1). Considering the condition's fatality potential, we chose to start her on empiric antibiotics in addition to hemodynamic resuscitation. The suggested treatment strategies for myocarditis are outlined in Table 2. The patient had evidence of bacteremia with little evidence of meningitis; such a presentation indicates widespread dissemination before there is time for meningitis to develop. Such patients are known to have a worse prognosis than patients presenting with meningitis alone.¹⁰

The course of illness in our patient was complicated by myocarditis. This complication is not recognized very frequently, but has been described before.^{6,11-14} An autopsy study in children revealed the presence of myocarditis in 42% of 31 children who had died of meningococcal infection, though the

Table 1 Differential diagnosis at presentation

SN	Differential diagnosis
1	Meningococemia
2	Immune thrombocytopenic purpura
3	Hemolytic uremic syndrome
4	Rickettsia
5	Acute leukemias with neutropenic fever
6	Toxic shock syndrome

Abbreviation: SN, serial number.

Table 2 Treatment strategies for the management of meningococcal myocarditis

SN	Treatment strategies	Therapeutic agents
1	Treatment of offending agent	Antibiotics
2	Symptomatic management	
	a. Afterload reduction	ACE inhibitors, milrinone
	b. Preload reduction	Diuretics
	c. Reduction of heart rate	Beta blockers
	d. Increased cardiac contractility	Inotropic agents (dopamine, dobutamine, milrinone)

Abbreviations: SN, serial number; ACE, angiotensin converting enzyme.

extent of inflammation was mild in the majority,¹⁵ which suggests that myocarditis may be more common than is recognized clinically. Endomyocardial biopsy remains the gold standard for the diagnosis of myocarditis; lymphocytic infiltrates with myocardial necrosis are deemed to be characteristic.¹⁶ We did not have the ability to perform right-heart catheterization or endomyocardial biopsy in our patient to make a definitive diagnosis of myocarditis. Also, there is a possibility that the elevated CPK and troponin were a result of myositis secondary to meningococemia. However, enlargement of the cardiac silhouette on a chest radiograph, ECG signs, and echocardiographic findings of global hyperkinesia with a lowered ejection fraction suggest that the heart failure that developed was due to myocarditis rather than cytokine effect or fluid overload.

Owing to the rarity of the condition, guidelines are lacking as to the appropriate management of meningococcal myocarditis. Considering the fact that a vast majority of cases of myocarditis are infectious in origin, one might argue that a similar management strategy could be helpful. Current guidelines favor symptomatic management of myocarditis with the use of diuretics, ACE inhibitors, and beta blockers along with treatment of the offending agent where applicable.¹⁶ We chose to start the patient on captopril and furosemide for symptomatic management with careful monitoring of the blood pressure. There are no data to confirm if there is a benefit to using captopril in patients with myocarditis from meningococemia. However, we opted to treat our patient cautiously with captopril as she had a clinical picture of worsening myocarditis with shock and could not afford treatment in the intensive care unit. Captopril is a potent vasodilator and helps left-ventricular failure by reducing the afterload on the heart muscle. Her recovery might have been beneficially influenced by the captopril.

The unusual thing about our patient was her rapid and successful recovery within a span of a few days. Previous evidence has shown that resolution of clinical myocarditis is often prolonged and incomplete.¹⁴ However, this report reaffirms the possibility of rapid resolution of severe meningococcal myocarditis, which has been seen before.⁶ Pathologic evidence of myocarditis is more common than

appreciated clinically in patients with meningococemia. Prompt recognition and management in our patient may have contributed to her rapid recovery from myocarditis.

Conclusion

Clinical myocarditis is an infrequently recognized complication of acute meningococemia, and can lead to severe heart failure. Recovery from myocarditis may be delayed and take several months. Our case suggests that rapid resolution of clinical myocarditis is possible with early diagnosis and treatment.

Disclosure

No sources of funding were used to assist in preparation of this case report, and the authors report no conflicts of interest in this work.

References

- Hahn SM, Sundi MA. Fever and rash. In: Stein JH, editor. *Internal Medicine*. Boston, MA: Little, Brown and Company; 1990:93–110.
- Stephens DS, Munford RS, Wetzler LH. Meningococcal Infections. In: Kasper DL, Fauci AS, Longo DL, Braunwald E, Hauser SL, Jameson JL, editors. *Harrison's Principles of Internal Medicine*. New York, NY: McGraw-Hill Companies; 2005:931–935.
- Herf C, Nichols J, Fruh S, Holloway B, Anderson CU. Meningococcal disease: recognition, treatment, and prevention. *Nurse Pract*. 1998;23(8):33–36.
- Almeida-González L, Franco-Paredes C, Pérez LF, Santos-Preciado JI. Meningococcal disease caused by *Neisseria meningitidis*: epidemiological, clinical, and preventive perspectives. *Salud Publica Mex*. 2004;46(5):438–450. Spanish.
- Gradaus F, Klein RM, von Giesen HJ, et al. Clinical course and complications of meningococcal septicemia. *Med Klin (Munich)*. 1999;94(11):633–637. German.
- Razminia M, Salem Y, Elbzour M, Teves D, Deshmukh H, Khosla S. Importance of early diagnosis and therapy of acute meningococcal myocarditis: a case report with review of literature. *Am J Ther*. 2005;12(3):269–271.
- Stephens DS, Greenwood B, Brandtzaeg P. Epidemic meningitis, meningococcaemia, and *Neisseria meningitidis*. *Lancet*. 2007;369:2196–2210.
- Taldir G, Parize P, Arvis P, Faisy C. Acute right-sided heart failure caused by *Neisseria meningitidis*. *J Clin Microbiol*. 2013;51(1):363–365.
- Oberti J, Hoi NT, Caravano R, Tan CM, Roux J. An epidemic of meningococcal infection in Vietnam (southern provinces). *Bull World Health Organ*. 1981;59(4):585–590. French.
- Salzman MB, Rubin LG. Meningococemia. *Infect Dis Clin North Am*. 1996;10(4):709–725.
- Sipila R, Kiiilavuori K. Meningococcus septicemia accompanied by perimyocarditis. *Duodecim*. 1997;113(17):1702. Finnish.
- Sandler MA, Pincus PS, Weltman MD, et al. Meningococcaemia complicated by myocarditis. A report of 2 cases. *S Afr Med J*. 1989;75(8):391–393.
- DaCosta DF, Neville E, Raman GV. Association of myocarditis and acute renal failure complicating meningococcal septicaemia. *J Infect*. 1991;22(3):259–261.
- Albanesi Filho FM, Rocha RM, Barros RA. Meningococemia complicated by myocarditis. *Arq Bras Cardiol*. 1998;70(2):115–118. Portuguese.
- Garcia NS, Castelo JS, Ramos V, Rezende GS, Pereira FE. Frequency of myocarditis in cases of fatal meningococcal infection in children: observations on 31 cases studied at autopsy. *Rev Soc Bras Med Trop*. 1999;32(5):517–522.
- Kindermann I, Barth C, Mahfoud F, et al. Update on myocarditis. *J Am Coll Cardiol*. 2012;59(9):779–792.
- Shrestha NK. Infectious disease emergencies. In: Carey WD, editor. *Current Clinical Medicine*, 2nd ed. Philadelphia, PA: Saunders Elsevier; 2010:706.

International Medical Case Reports Journal

Publish your work in this journal

The International Medical Case Reports Journal is an international, peer-reviewed open-access journal publishing original case reports from all medical specialties. Previously unpublished medical posters are also accepted relating to any area of clinical or preclinical science. Submissions should not normally exceed 2,000 words or

Submit your manuscript here: <http://www.dovepress.com/international-medical-case-reports-journal-journal>

4 published pages including figures, diagrams and references. The manuscript management system is completely online and includes a very quick and fair peer-review system, which is all easy to use. Visit <http://www.dovepress.com/testimonials.php> to read real quotes from published authors.

Dovepress