

Post-transplant small cell carcinoma arising in the native kidney of renal transplant recipient

Wenhao Tang, Lulin Ma, Xiaofei Hou, Longtao Yan, Amit Mani Upadhyay

Department of Urology, Peking University, Third Hospital, Beijing, 100083, P.R. China

ABSTRACT

Small cell carcinoma (SCC) originating from kidney is extremely rare. To date, there has been no reported case of primary SCC of renal transplant recipients' (RTRs) own kidney. Here, we report the first case of primary SCC of RTRs' own kidney. Resection of bilateral native kidneys, possessing whole length of ureters and small cuffs of bladder along with a neoplasm located in her right kidney, was performed on a 68-year-old female patient, five years after renal transplantation. The immuno-histochemical result confirmed mixed SCC of the right kidney (SCC combined with little transitional cell carcinoma). Postoperatively, platinum-based adjuvant chemotherapy (Cisplatin combined with Gemcitabine) was given, and the patient is still alive with well-functioning transplanted kidney.

Key words: Kidney, renal transplant, small cell carcinoma

DOI: 10.4103/0970-1591.52941

INTRODUCTION

Small cell carcinoma (SCC) frequently originates from lung, which constitutes approximately 10-20% of pulmonary malignant neoplasm. Extrapulmonary SCC (EPSCC) is very rare, constituting only about 5% of the total SCC, which is generally known to be more fatal than pulmonary SCC. Among EPSCC, the primary renal SCC is extremely rare. The first case of primary renal SCC was described by Capella C in 1984, and to our knowledge, there are only 34 such cases reported in the English literatures.^[1] So far, there has been no cases on renal transplant recipients (RTRs) own kidney primary SCC reported. So we believe that this is the first case report on renal primary SCC of RTR.

CASE REPORT

A 68-year-old Chinese lady was presented with right renal mass after routine ultrasound examination of the abdomen. She had no obvious complaint and no history of (h/o) hematuria, loin pain, and fever. The patient had h/o cadaver renal transplant five years ago. The postoperative period was uneventful. She received Tacrolimus (FK506), Mycophenolate mofetil

(MMF), and Prednisone as immunosuppressive agent. On physical examination, patient's general condition was fair, she was nonanemic, nonicteric, and no sign of peripheral lymphadenopathy was noted. Abdomen was soft with no palpable mass and hepato-splenomegaly. Ultrasonography (USG) of the abdomen revealed a mass of size 4 × 3 cm in the right kidney and several other smaller masses behind the inferior vena cava (IVC), the biggest one measuring 3.3 × 2.0 cm in size. Computer tomography (CT) of the abdomen showed right renal mass (CT value 42 HU) on slight enhancement and (CT value 55 HU) on contrast enhancement, and right hydronephrosis, multiple enlarged abdominal lymph nodes, left shrunken kidney, and normal allograft in the pelvis [Figure 1]. MRI of the abdomen further showed a right renal mass of size 4.3 × 4.6 × 6 cm with high T1- and moderate T2-weighted image.

After thorough preoperative preparation, resection of bilateral native kidneys with whole length of ureters and small cuffs of bladder was done. Dissection of the abdominal lymph nodes was also carried out simultaneously. The tumor was 4 × 3 cm in size, located in the middle and lower pole of the right kidney. The resected neoplasm had pseudocapsule, and the dissected section was dark red in color. Multiple enlarged lymph nodes were also seen in the para-aortic region and behind the IVC; the largest one measuring about 3 × 2 cm in size. The postoperative period was uneventful and the patient got discharged on the 15th day.

Histopathological report showed mixed SCC of the right kidney [Figure 2] (SCC combined with little transitional

For correspondence: Dr. Wenhao Tang, Department of Urology, Peking University, Third Hospital, 49# Hua Yuan North Road, Haidian District, Beijing-100 083, China.
E-mail: tangwenhao9696@hotmail.com

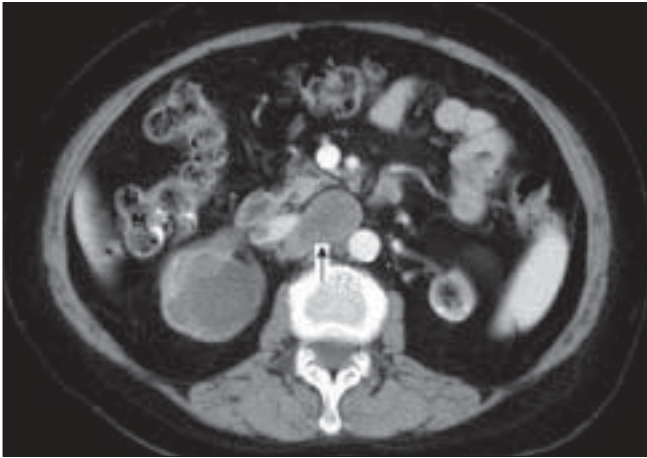


Figure 1: Contrast-enhanced CT scans: Right renal mass (CT value 42 HU) with slight enhancement (CT value 55 HU) on contrast enhancement, right hydronephrosis; multiple enlarged abdominal lymph nodes (with arrow head); and left shrunken kidney

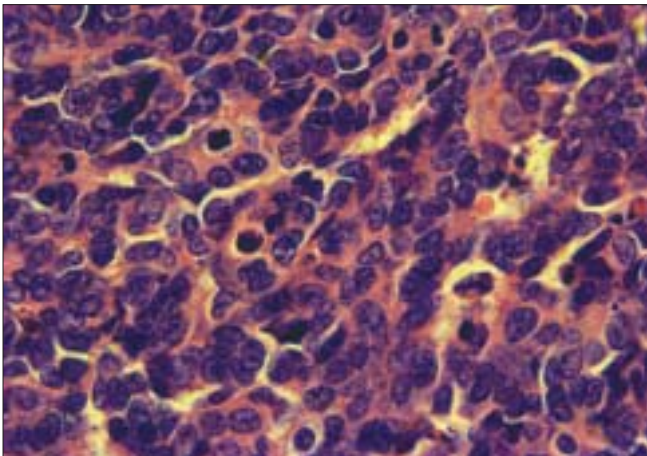


Figure 2: Microscopic picture (original magnification, x40)

cell carcinoma). The retroperitoneal lymph nodes (3/6) also showed tumor metastasis with same pathology as that of the right kidney. Immunohistochemistry results were as follows: Chromogranin (CgA)(+), Vimentin(+), CD56(+), CD99(+), CK(little cell +), EMA, CD10, CK7, CK20, Synaptophysin (Syn), and BCL-2. Generally, CgA and Syn with both positive or just one test positive can be considered as SCC.

Platinum-based adjuvant chemotherapy (Cisplatin combined with Gemcitabine) was given postoperatively. During follow-up (till 1 year after the surgery), the patient was found to be in good health with well-functioning transplanted kidney containing serum creatinine in the range of 90 to 100 $\mu\text{mol/l}$.

DISCUSSION

Due to its extreme rarity, it is very difficult to devise a guideline for renal SCC treatment, and till date, the therapeutic strategy for treating renal SCC is still a challenge for urologists.

The EPSCC resembles primary pulmonary SCC in many respects, such as histological characters, aggressive nature, high propensity for distant dissemination, etc. Thus, many authors refer to pulmonary SCC to create its therapeutic strategy.^[2,3] In the above-mentioned literature, the best therapeutic regimen is described as surgery combined with adjuvant chemotherapy. Maihail *et al.*, reviewed 22 patients of SCC that originated from kidney or renal pelvis, and who had received surgery combined with systemic adjuvant chemotherapy; the median survival of platinum-containing regimen group was 20 months while it was only 8 months in group not receiving platinum. Hence the author indicates that the primary therapeutic modality for renal SCC is surgery combined with systemic chemotherapy. The platinum-based chemotherapy has been found responsible for tumor regression as well as patients' prolonged survival.^[3] Timothy R. Asmis *et al.*, analysed 12 cases of urinary bladder SCC and 10 cases of prostate SCC. They found out that the prognosis of bladder SCC was better than prostate SCC, with median survival of 19.8 months vs 9.5 months.^[2]

The increased incidence of malignancy in patients on immunosuppression following organ transplantation is well documented. Some authors point out that the accrual risk of *de novo* malignancy following renal transplantation is approximately 100 times greater than the general population.^[4] Thus, we believe that the etiology of the recipient's own kidney SCC may relate to immunosuppressive modality. This indicates that the surveillance for malignancy after transplantation should be strengthened in order to find it out in the earliest stage. In our case, we decided to resect the contra-lateral kidney, whole length of ureter, and small cuff of bladder as well, to prevent the recurrence of disease in contra-lateral kidney or renal pelvis. After histopathological confirmation of the renal SCC, the platinum-based adjuvant chemotherapy was applied and the patient responded well to this therapy. However, there are also reports of prostate SCC after renal transplantation, which had more fulminant progression than SCC of other organs. This be due to the influence of immunosuppressant drugs.^[5]

CONCLUSION

We believe that this is the first case of primary SCC of RTRs' own kidney. Multimodal therapy including surgery and adjuvant chemotherapy was beneficiary in this particular patient.

REFERENCES

1. Miyake M, Fujimoto K, Tanaka M, Matsushita C, Tanaka N, Hirao Y. A case of small cell carcinoma of the kidney. *Hinyokika Kyo* 2007;53:235-40.
2. Asmis TR, Reaume MN, Dahrouge S, Malone S. Genitourinary small cell carcinoma: A retrospective review of treatment and survival patterns at The Ottawa Hospital Regional Cancer Center. *BJU Int* 1997;4:711-5.

3. Mihalil NS, Elson P, Bukowski RM. Therapy and outcome of small cell carcinoma of the kidney: Report of two cases and a systematic review of the literature. *Cancer* 2003;97:1436-41.
4. Beltran BE, Morales D, Medina M. *Journal of Clinical Oncology*, 2007 ASCO Annual Meeting Proceedings Part 1. 2007, 25(18S), (June 20 Supplement): 21155.
5. Rannikko A, Krogerus L, Nyberg M, Salmela K, Ruutu M. Rapid

progression of small cell carcinoma in a renal transplant Recipient. *Int J Urol* 2006;13:817-9.

How to cite this article: Tang W, Ma L, Hou X, Yan L, Upadhyay MA. Post-transplant small cell carcinoma arising in the native kidney of renal transplant recipient. *Indian J Urol* 2009;25:264-6.

Source of Support: Nil, **Conflict of Interest:** None declared.