



ELSEVIER

Contents lists available at ScienceDirect

## Toxicology Reports

journal homepage: [www.elsevier.com/locate/toxrep](http://www.elsevier.com/locate/toxrep)

# Histomorphometric study of testis in deltamethrin treated albino rats

Anil Kumar<sup>a,\*</sup>, Mahindra Nagar<sup>b</sup><sup>a</sup> Department of Human Structure and Neurobiology, Oman Medical College Affiliated with West Virginia University (USA), Sohar, Sultanate of Oman<sup>b</sup> Department of Anatomy, University College of Medical Sciences & Guru Teg Bahadur Hospital, Delhi 110095, India

## ARTICLE INFO

## Article history:

Received 5 March 2014

Received in revised form 6 July 2014

Accepted 6 July 2014

Available online 15 July 2014

## Keywords:

Deltamethrin

Pyrethroid

Testis

Seminiferous tubules

Spermatogenic cell

Supporting cell

Histopathological changes

## ABSTRACT

Deltamethrin, a type II synthetic pyrethroid, has led to a widespread concern over the potential adverse effects on human health. Adult Wistar albino rats, weighing 150–200 g, were divided into two groups of ten animals each. The group II rats were injected with deltamethrin (1 mg/kg body weight) intraperitoneally, for five days/week for a month. The group I were controls. Animals were sacrificed within 24 h of the last injection by perfusion under anesthesia. Paraffin sections (8  $\mu$ m) were cut, and stained with hematoxylin and eosin. Histomorphometry was done. There was a decrease in the body weight but increase in the weight of the testis of rat. The mean vertical, antero-posterior and transverse diameter of the testis is reduced. The basement membrane enclosing the seminiferous tubules appeared thickened at sites. The number of seminiferous tubules per unit area is statistically significantly reduced. There was a generalized significant decrease in the diameter and the epithelium thickness (height) of the seminiferous tubules, associated collapse and distortion at sites of the tubules predominantly in the central region. The data obtained in the present work suggest that gonadal (testis) changes could seriously affect the reproductive potential of the rat.

© 2014 The Authors. Published by Elsevier Ireland Ltd. This is an open access article under the CC BY-NC-ND license (<http://creativecommons.org/licenses/by-nc-nd/3.0/>).

## 1. Introduction

In the past five years, deltamethrin, a type II synthetic broad spectrum pyrethroid, occupies a leading position in many countries for commercial agriculture, garden and home pest control, forestry, aircraft disinfectant, livestock application and public health programs and hence residues in foods are high leading to a widespread concern over the potential adverse effects on human health. Recently, toxicity in form of excessive salivation, impaired limb function, ataxia, loss of righting reflex, lethality, paraesthesias,

choreoathetosis, tremors, rarely paralysis and convulsions has been reported on mice, rat, rabbit and guinea pig via dermal, oral and inhalational routes [1–3]. Reproductive effects in rats include decrease weight of testis, seminal vesicle, prostate gland, and decrease in sperm cell concentration, sperm motility, plasma testosterone levels and pregnancy rates [4]. Occupational hazards seen in human are transient cutaneous and mucous membrane irritation, itching, dizziness, abnormal facial sensations, anaphylaxis, bronchospasm, eosinophilia, fever, hypersensitivity, pneumonia, sweating, and sudden edema of the face, eyelids, lips, mucous membrane and tachycardia [5]. International literature describes a significant increase in the incidence of male infertility in humans in the past decade possibly due to environmental contaminants like pesticides [7] which act as endocrine disruptors and since they are being

\* Corresponding author. Tel.: +968 95393982.

E-mail addresses: [virgo.8977@gmail.com](mailto:virgo.8977@gmail.com) (A. Kumar), [nagarmahindara@hotmail.com](mailto:nagarmahindara@hotmail.com) (M. Nagar).

widely used ever since the international technological shift in industrial and agricultural development which involves the handling and exposure to various substances although harmful to humans, further research is warranted. The available information indicates that deltamethrin may pose serious hazards to non-target organs like testis resulting in infertility; the present experimental study was undertaken in a mammal, albino rat.

## 2. Materials and methods

### 2.1. Experimental design

Inbred adult Wistar albino rats (150–200 g) were divided into two groups. Animals were group housed (12 h light/dark cycle) with ad libitum access to food and water. The group II rats were injected with deltamethrin without dilution (1 mg/kg body weight) intraperitoneally, for five days/week for a month. The group I were controls. Animals were sacrificed within 24 h of the last injection by perfusion under anesthesia. Paraffin sections (8  $\mu\text{m}$ ) were cut, and stained with hematoxylin and eosin. Observations were done on every fifth section of on a Zeiss light microscope and Image Pro-Express Analysis System in both the groups.

### 2.2. Measurements

#### 2.2.1. Body weight of the animals

The body weights were recorded before the onset of the experiment and prior to the sacrifice of the animals. The data was tabulated and statistically analyzed.

#### 2.2.2. Size and weight of the testis

The size of the testis was measured in a vertically between the upper and lower poles. The antero-posterior and transverse diameter was recorded in the middle of the testis with the help of vernier calipers in both the groups. Each testis was blotted and weighed in a electronic scale. The data was tabulated and statistically analyzed.

#### 2.2.3. Histomorphological study

Observations were done on every fifth section of the testis stained with hematoxylin and eosin on a Zeiss light microscope and Image Pro-Express Analysis System in both the groups.

The various characteristics of the testis with regard to the state of tunica albuginea, seminiferous tubules, various cells in the seminiferous epithelium and interstitial tissue were studied with hematoxylin and eosin staining in both the groups, experimental and control.

#### 2.2.4. Histomorphometric study

For all linear measurements, Abercrombie's [8] method was used, in which ocular micrometer was calibrated with stage micrometer.

**2.2.4.1. Calibration of ocular micrometer for linear measurements.** Calibration of ocular micrometer was done with the help of stage micrometer, separately for low power and high power objective of a light microscope, keeping the

particular eyepiece and particular objective, the readings were constant.

**2.2.4.1.1. Measurement of seminiferous tubules.** The size of the seminiferous tubules was measured in the peripheral and central regions, from four different fields of every section of the testis. Two diameters at right angles to each other, passing through the center of the tubule were measured. One was considered the long diameter and the other called the short diameter. Hundred tubular profiles that were round or nearly round were chosen randomly and measured in each animal [9]. These readings, obtained from experimental and control animals were tabulated and statistically analyzed.

**2.2.4.1.2. Measurement of the epithelium thickness (height) in the seminiferous tubules.** The height of the epithelium was measured in hundred seminiferous tubules that were round or nearly round, at four sites, at right angles and opposite each other in the peripheral and central regions of the testis in each animal. The readings from all the animals in both the groups were tabulated and statistically analyzed.

#### 2.2.4.2. Tubular count.

**2.2.4.2.1. Measurement of unit area.** An ocular micrometer with an engraved square grid was used to measure an area. The length of one side of the square grid was calibrated with the stage micrometer, to find out the length of one side of the grid. Then the area of the grid was then calculated.

**2.2.4.2.2. Tubule count in a unit area.** Counting of seminiferous tubules was done in sections stained with hematoxylin and eosin by placing an ocular micrometer with an engraved square grid of an area of 57,600  $\mu\text{m}^2$ , in the peripheral and central region. Tubules falling on the right and lower border of the square were included, whereas those falling on the upper and left border were excluded for the count. The four corners and two central fields in each section were chosen randomly and measured in each animal. The readings from all the animals in both the groups were tabulated and statistically analyzed.

### 2.2.5. Statistical analysis

Quantitative observations in all the rats were done in both the groups and the data was tabulated and statistically analyzed by independent sample "t" test. But body weight in the experimental and control rats after was tabulated and statistically analyzed by Tukey's test. Statistical analysis was performed using SPSS 11.5 software.  $P < 0.001$  was considered as a significant level.

## 3. Results

### 3.1. Control group

Animals included in the study survived well throughout the period of 30 days. There was no appreciable change in appetite and behavior of the animals. The mean body weight of the animals was  $178.50 \pm 7.47$  g before the onset of the experiment and  $182.50 \pm 8.57$  g prior to the sacrifice of the rats (Table 1). There was an increase in the animal

**Table 1**  
Comparison of body weight (gm) in control and experimental rats.

	Group	Mean ( $\mu\text{m}$ )	SD	p-value (one way ANOVA)	Significance (Tukey's test at 5% level)
Before the experiment	Control	178.5	7.47	>0.001	The groups were not statistically significant
	Experimental	181.5	6.25		
Prior to sacrifice	Control	182.0	8.57	<0.001	Experimental group was statistically significantly different control groups
	Experimental	166.0	8.09		

weight before the onset of the experiment and prior to the sacrifice but it was not statistically significant (Table 1).

### 3.1.1. Gross observation

In the adult rat the testes were light brown in color and were located in the scrotal sac, situated ventrolateral to the anus with its curved surface directed caudally. The testicles of adult rats were large relative to the body size and usually abundance of fat was seen surrounding them. The mean vertical, transverse and anteroposterior diameters of the left testis were  $1.89 \pm 0.029$  cm,  $0.91 \pm 0.043$  and  $0.88 \pm 0.039$  cm whereas diameters of the right testis were  $1.88 \pm 0.030$ ,  $0.91 \pm 0.032$  and  $0.87 \pm 0.033$  cm respectively (Table 2). The average weight of the left testis was  $900 \pm 46.33$  g and of the right testis it was  $907 \pm 38.40$  g. Mean weight of the testis in controls was calculated as  $903.61 \pm 45.32$  (Table 4).

### 3.1.2. Histomorphological and histomorphometric observations in control group

The seminiferous tubules were counted in a unit area with the help of an ocular micrometer with an engraved square grid and by a pro image-express analyzer. The mean count of seminiferous tubule per unit area was found to be  $8.61 \pm 0.43$  (Table 5). The mean long and short diameter of the peripheral seminiferous tubules measured was  $219.87 \pm 4.44$  and  $146.76 \pm 8.42$   $\mu\text{m}$  respectively (Table 6). The mean long and short diameter of the central seminiferous tubules was found to be  $319.75 \pm 11.74$  and  $216.97 \pm 8.92$   $\mu\text{m}$  respectively (Table 7). The mean height of the epithelium of the seminiferous tubule in the peripheral and central region was measured to be  $11.40 \pm 0.93$  and  $19.82 \pm 1.48$   $\mu\text{m}$  respectively (Table 8).

The interstitial tissue consisted of loose connective tissue with interspersed flattened fibroblasts, macrophages, lymphatics, nerves, mast cells and interstitial cells of leydig.

## 3.2. Observations in experimental group after deltamethrin treatment

### 3.2.1. Experimental group

During the course of the experiment, it was observed that the rats became more hyperactive immediately after receiving the first dose of deltamethrin. The increase in the activity was accompanied by sneezing, shivering, groaning, excessive salivation which lasted for half hour. On subsequent days, the animals appeared sluggish, there was a loss of appetite associated with loose feces and occasional vomiting was observed. Before administration of the next dose of the drug the rats became very aggressive and showed resistance during injecting the drug.

The mean body weight of the animals at the beginning of the experiment was  $181.50 \pm 6.25$  g while just prior to the sacrifice the weight was  $166.00 \pm 8.09$  g (Table 1). The decrease in the body weight in the experimental rats after administration of deltamethrin was found to be statistically significant ( $p < 0.001$ ) by Tukey's test when compared with the control animals (Table 1).

### 3.2.2. Gross observations

The testis was smooth and encapsulated. There were patchy areas of fatty tissue adherence on the surface and at sites hemorrhages were observed. Grossly, there was a nodular enlargement on the lower pole of the testis. No abnormal lobulation of the testis was seen (Fig. 1).

The testis appeared smaller in size as compare to the testis of control animals. When measured with vernier calipers, the mean vertical, antero-posterior and transverse diameters of the right testis were  $1.87 \pm 0.028$ ,  $0.87 \pm 0.033$  and  $0.90 \pm 0.030$  cm respectively whereas it was  $1.88 \pm 0.034$ ,  $0.87 \pm 0.028$  and  $0.91 \pm 0.044$  cm in the left testis (Table 3). The average weight of the right and left testis was  $1049.00 \pm 46.47$  and  $1053 \pm 44.42$  respectively. Mean weight of the testis in the treated rats was calculated as  $1051.00 \pm 42.41$ . The average weight of the testis in the treated rats showed a significant increase in the weight (Table 4).

Under the tunica albuginea, a number of cut sections of the seminiferous tubules were observed which appeared to be smaller and mostly irregular. The basement membrane stained pink with hematoxylin and eosin. It appeared to be slightly thickened at sites (Fig. 2).

The mean tubular population in unit area appeared to be reduced. It was found to be  $4.62 \pm 0.36$  in a unit area of  $57,600 \mu\text{m}^2$  where as it was  $8.61 \pm 0.43$  in the control animals (Table 5). On statistical analysis, the tubular population was significantly reduced in the experimental rats as compared to the control animals (Table 5).

The mean long and short diameters of the peripheral seminiferous tubules were  $219.19 \pm 4.22$   $\mu\text{m}$  and  $132.92 \pm 2.84$   $\mu\text{m}$  respectively (Table 6). Statistical analysis showed there was no statistical significant difference in the diameters of the peripheral seminiferous tubules as compared to the peripheral seminiferous tubules in the control animals (Table 6). The mean long and short diameters of the central seminiferous tubules were  $273.23 \pm 7.52$   $\mu\text{m}$  and  $132.92 \pm 2.84$   $\mu\text{m}$  respectively (Table 7). Statistical analysis showed there was a significant decrease in the diameters of the central seminiferous tubules as compared to the central seminiferous tubules in the control animals (Table 7).

The average height of the epithelium in peripheral and central seminiferous tubules was measured and found to

**Table 2**  
Diameters (cm) of the testis in control rats.

Serial no.	Left side			Right side		
	Vertical	Antero-posterior	Transverse	Vertical	Antero-posterior	Transverse
1	1.88	0.84	0.85	1.87	0.84	0.90
2	1.90	0.86	0.88	1.86	0.84	0.88
3	1.86	0.88	0.92	1.92	0.92	0.92
4	1.92	0.90	0.94	1.95	0.90	0.94
5	1.94	0.92	0.96	1.86	0.84	0.92
6	1.86	0.88	0.98	1.88	0.91	0.94
7	1.88	0.84	0.88	1.86	0.86	0.96
8	1.86	0.96	0.86	1.87	0.88	0.88
9	1.88	0.90	0.88	1.88	0.83	0.86
10	1.88	0.84	0.92	1.86	0.84	0.89
Mean	1.89	0.88	0.91	1.88	0.87	0.91
SD	0.026	0.039	0.043	0.030	0.033	0.032

**Table 3**  
Diameters (cm) of the testis in experimental rats.

Serial no.	Left side			Right side		
	Vertical	Antero-posterior	Serial no.	Vertical	Antero-posterior	Serial no.
1	1.88	0.87	0.98	1.86	0.91	0.96
2	1.92	0.92	0.88	1.84	0.84	0.88
3	1.84	0.91	0.86	1.86	0.85	0.86
4	1.92	0.89	0.88	1.87	0.85	0.88
5	1.94	0.84	0.85	1.85	0.92	0.90
6	1.86	0.84	0.88	1.86	0.84	0.88
7	1.85	0.86	0.92	1.92	0.89	0.92
8	1.86	0.84	0.94	1.90	0.86	0.94
9	1.87	0.86	0.96	1.86	0.84	0.92
10	1.86	0.88	0.88	1.92	0.87	0.90
Mean	1.88	0.87	0.91	1.87	0.87	0.90
SD	0.034	0.028	0.044	0.028	0.029	0.030

**Table 4**  
Comparison of weight (g) of testis in control and experimental rats.

Group	Mean ( $\mu\text{m}$ )	SD	<i>p</i> -value (one way ANOVA)	Significance (Tukey's test at 5% level)
Control	903.61	45.32	<0.001	Both groups were significantly different from each other
Experimental	1051.00	42.41		

**Table 5**  
Comparison of mean count per unit area ( $57,600 \mu^2$ ) of seminiferous tubules in control and experimental rats.

Region	Group	Mean ( $\mu$ )	S.D	<i>p</i> -value (one way ANOVA)	Significance (Tukey's test at 5% level)
Mean count per unit area	Control	8.61	0.43	<0.001	Both groups were significantly different from each other
	Experimental	4.62	0.36		

**Table 6**  
Comparison of mean diameters ( $\mu\text{m}$ ) of peripheral seminiferous tubules in control and experimental rats.

Parameters	Group	Mean ( $\mu\text{m}$ )	SD	<i>p</i> -value (one way ANOVA)	Significance (Tukey's test at 5% level)
Long diameter	Control	219.87	4.22	<0.001	Both groups were significantly different from each other
	Experimental	219.19	4.22		
Short diameter	Control	146.76	8.42	<0.001	Both groups were significantly different from each other
	Experimental	132.92	2.84		

**Table 7**  
Comparison of mean diameters ( $\mu\text{m}$ ) of central seminiferous tubules in control and experimental rats.

Parameters	Group	Mean ( $\mu\text{m}$ )	S.D	<i>p</i> -value (one way ANOVA)	Significance (Tukey's test at 5% level)
Long diameter	Control	319.75	11.74	<0.001	Both groups were significantly different from each other
	Experimental	273.23	7.52		
Short diameter	Control	216.97	8.92	<0.001	Both groups were significantly different from each other
	Experimental	169.55	6.47		

**Table 8**Comparison of mean thickness ( $\mu\text{m}$ ) of the epithelium of the central and peripheral seminiferous tubules in control and experimental rats.

Region	Group	Mean ( $\mu\text{m}$ )	SD	<i>p</i> -value (one way ANOVA)	Significance (Tukey's test at 5% level)
Central	Control	19.82	1.48	<0.001	Both groups were significantly different from each other
	Experimental	18.32	1.53		
Peripheral	Control	11.40	0.93	<0.001	Both groups were significantly different from each other
	Experimental	10.10	2.23		

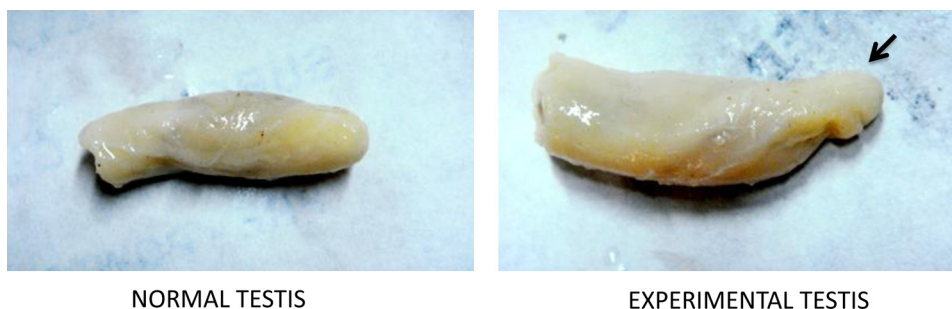
be  $10.10 \pm 2.23$  and  $18.32 \pm 1.53 \mu\text{m}$  respectively (Table 8). It was found to be statistically significantly reduced when compared to the height of the epithelium in the control rats in both, the peripheral and central seminiferous tubules (Table 8).

#### 4. Discussion

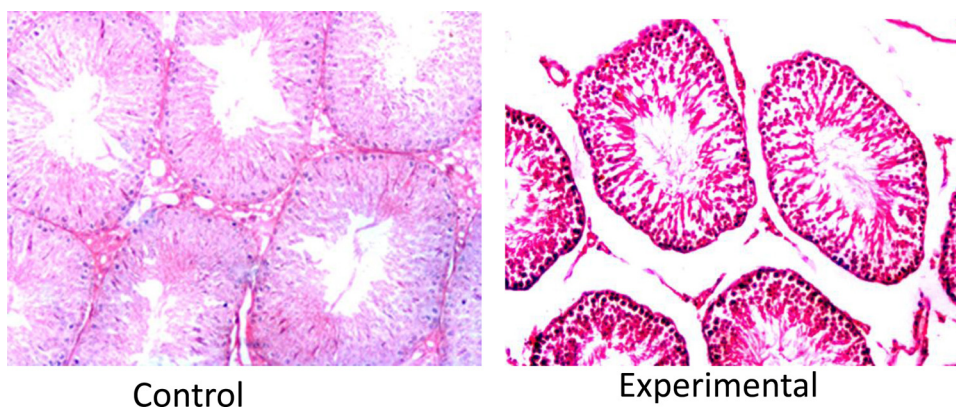
During the course of the experiment, it was observed that the rats became hyperactive immediately after receiving the first dose of deltamethrin. The increase in activity was accompanied by sneezing, shivering, groaning, and excessive salivation which lasted for half an hour. On subsequent days, the animals appeared sluggish; there was a loss of appetite associated with loose feces and occasional vomiting. Prior to the administration of the next dose of the drug the rats became very aggressive and showed resistance during injecting the drug. Deltamethrin is known to be neuropoisonous acting on the axons in the peripheral and central system by interacting sodium channels [10].

Manna et al. [11] explained it to be a result of significantly low gamma amino butyric acid concentrations in the brain tissue. Chen et al. [12] has suggested mitochondria-mediated apoptosis of the nerve cells in the rat brain to be the cause of these toxic effects.

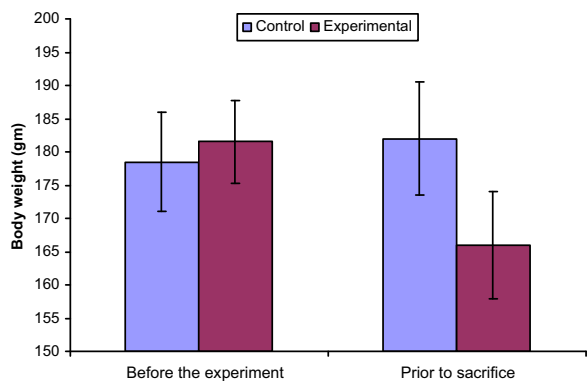
At the onset of the experiment the mean body weight was  $178.50 \pm 7.47$  g, while just prior to their sacrifice, it was  $182.50 \pm 8.57$  g in the control rats. The slight increase in the body weight in these animals was not statistically significant. In the experimental rats the mean body weight at the beginning of the experiment was  $181.50 \pm 6.25$  g and prior to their sacrifice it was  $166.00 \pm 8.09$  g. There was a statistically significant decrease in the body weight ( $p < 0.001$ ) (Graph 1) in deltamethrin treated rats which may have resulted due to the hyperactivity, excessive salivation, loss of appetite, diarrhea and the occasional vomiting observed in these animals. This decrease in body weight in experimental rats is in accordance with the findings of Kavlock et al. [13] who reported a 20% reduction in the body weight in female rats. Madsen et al. [14] and Elbetieha et al. [6] also reported a similar reduction in body weight in male Fisher



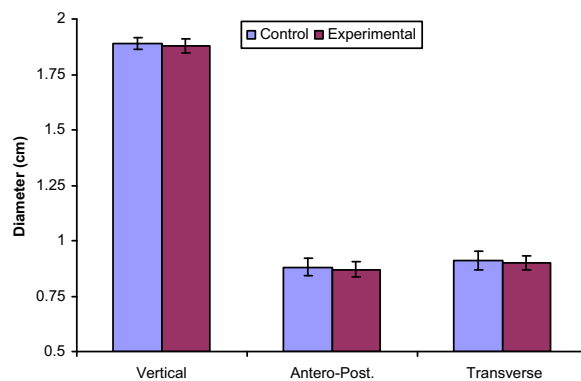
**Fig. 1.** Photograph of the experimental rat testis showing growth (arrow marked) of the lower part of the testis.



**Fig. 2.** Photomicrograph of the transverse section of the normal rat testis and experimental rat testis showing altered and distorted seminiferous tubules with irregular shape, basement membrane thickening. Hematoxylin and eosin stain (200 $\times$ ).



**Graph 1.** Comparison of body weight (gm) in control and experimental rats.

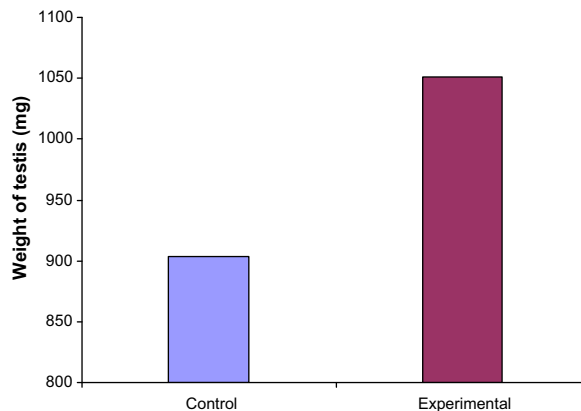


**Graph 2.** Comparison of the mean diameter (cm) of the testis in control and experimental rats.

and Sprague-Dawley rats respectively after oral administration of deltamethrin. Similar findings were seen when deltamethrin was administered dissolved in propylene glycol intraperitoneally in Wistar albino rat by Patro et al. [15]. However our findings are in contrast with the observations of Sayim et al. [16] and Varshneya et al. [17] who did not observe a significant change in the body weight of the animals after administration of a type II pyrethroid, cypermethrin. The difference in observation of the body weight might have resulted due to the different routes and doses of administration used in our studies. However, Andrade et al. [18] observed no significant alteration in body weight of rats after oral administration of deltamethrin. This could be due to the difference in the route of administration and/or a variable dose used as compared to the present study.

In the control animals, the mean vertical, antero-posterior and transverse diameters were  $1.88 \pm 0.030$  cm,  $0.87 \pm 0.033$  cm,  $0.91 \pm 0.032$  cm respectively in the middle of the testis. The vertical diameter of the testis in the present study is favorably comparable with Hebel and Stromberg [19] who recorded a vertical length of 2.00 cm in the albino Wistar rat. The transverse diameter of the testis as cited by him was 1.40 cm was greater than either of the antero-posterior and transverse diameters measurement in the present study. The difference in opinion may have resulted due to the different methods of fixatives used for the organ. According to Howroyd et al. [20] there are many factors that affect fixation and different fixatives are better at preserving tissue for different endpoints of analysis in rat testes.

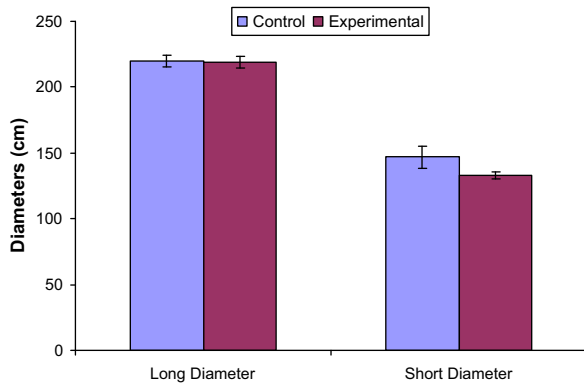
In the experimental group, the mean vertical length of the testis was  $1.87 \pm 0.028$  cm where as in control rats, it was  $1.88 \pm 0.030$  cm. On statistical analysis it was evident that the apparent decrease in the length of the testis when compared to the control is not statistically significant. The mean antero-posterior diameter of the testis in the control animals was  $0.87 \pm 0.033$  cm and in the experimental animals it was  $0.87 \pm 0.033$  cm. These values are statistically insignificant when compared to the diameters in the control animals. The mean transverse diameter was  $0.91 \pm 0.032$  cm and  $0.90 \pm 0.030$  cm in the control and experimental animals respectively. The reduced transverse diameter in the deltamethrin treated rats was not statistically significant as suggested by the independent sample "t"



**Graph 3.** Comparison of weight (mg) of testis in control and experimental rats.

test. These findings suggest that the deltamethrin did not affect the gross size of the testis in the albino rats (Graph 2). Since no data was available with respect to the measurements of the testis after administration of this pesticide, it could not be compared.

The mean weight of the testis on the left side was  $900 \pm 46.33$  and  $1053.00 \pm 44.42$  mg and on the right side was  $907.22 \pm 38.40$  and  $1049.00 \pm 46.47$  mg in the control and experimental groups respectively. This increase in the mean weight of the testis was statistically significant (Graph 3). Madsen et al. [14] also observed significant increase in the testis and brain weight in Fisher rats after administration of oral deltamethrin in soyabean oil by gavage for 28 consecutive days. It was suggested that the increase in the weight was a result of excessive fluid retention in the interstitial tissue. In our study too this could be a one of causes for the increase in testicular weight and probably if the duration of the experiment was prolonged, ultimately a loss of testicular weight may have resulted due the associated tubular degeneration. Hassan et al. [21] and Abd El-Aziz et al. [4] exhibited a significantly lower weight of the testicles in rat after administration of oral deltamethrin in doses as low as one milligram per kilogram per day (the lowest level tested) for 65 days. This significant reduction in testicular weight was attributed to the significantly reduced plasma testosterone levels which



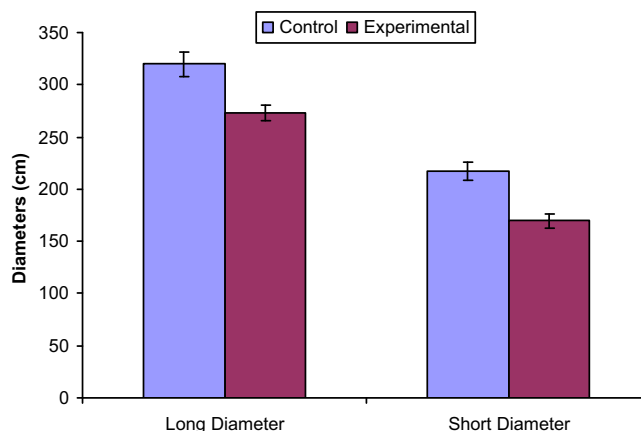
**Graph 4.** Comparison of mean diameters ( $\mu\text{m}$ ) of peripheral seminiferous tubules in control and experimental rats.

occurred as early as 14 days after the onset of the treatment. However, Abd El-Khalek et al. [22] and Elbetieha et al. [6] observed a reduced male reproductive organ weight with other type II pyrethroids like cypermethrin and fenvalerate, in a dose-dependent manner in Sprague-Dawley rats. Rai et al. [24] observed reduction in the testicular weight after immobilization stress in albino rats which was attributed to the severe suppression of spermatogenesis and degeneration of testicular tissue.

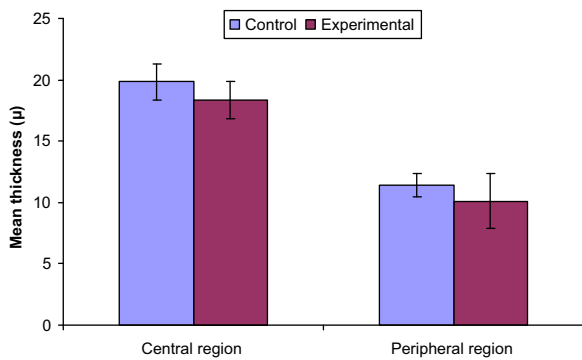
In the control animals, deep to the tunica albuginea, were a number of cut sections of normal seminiferous tubules with intervening interstitial tissue. The mean long diameter of the seminiferous tubule in the controls varied from  $319.75 \pm 11.74$  and  $219.87 \pm 4.22 \mu\text{m}$  in central and peripheral tubules. The mean short diameter of seminiferous tubules is  $216.97 \pm 8.92$  and  $169.55 \pm 6.47 \mu\text{m}$  in the central and peripheral regions respectively. Kalla and Bansal [23] observed that the diameter of the seminiferous tubules ranged between 269 and  $289 \mu\text{m}$  in mature Sprague-Dawley rats. The mean diameters of the tubules in his study are lower than that in the present study probably due to the different strain of rats used in the respective studies. It may also be partially due to the concentration of the myoid cells in the lamina propria.

In the experimental rats, deep to the tunica albuginea, there were a number of smaller and mostly irregular cut sections of the seminiferous tubules. The basement membrane enclosing the seminiferous tubules appeared to be slightly thickened at sites and surrounded externally by a thin layer of lamina propria containing myoepithelial cells. Similar observations were also reported by El-Gohary et al. [25] after administration of deltamethrin in adult male albino rats in a dose of  $1 \text{ mg/kg}$  intraperitoneally for 21 consecutive days. The mean long and short diameters of the seminiferous tubules were  $219.19 \pm 4.22$  and  $132.92 \pm 2.84 \mu\text{m}$  and  $273.23 \pm 7.52$  and  $169.55 \pm 6.47 \mu\text{m}$  in the peripheral and central region of the testis respectively. This generalized statistically significant decrease in the diameter of the tubules (Graph 4 and 5) with an associated collapse and distortion at sites of the tubules predominantly in the central region may have resulted due to the thickening of the tunica albuginea and a decrease in the vascularity in the central area of the testis. Elbetieha et al. [6] found no changes in the diameter of tubules in Sprague-Dawley rats after administration of a type II pyrethroid. Whereas Andrade et al. [18] administered deltamethrin in a dose of four milligrams per kilogram by an oral gavage and observed adverse effects on the diameter of seminiferous tubules. Smaller seminiferous tubule diameters after introduction of deltamethrin in Sprague-Dawley rats by Kilian et al. [26] were attributed to an endocrinal disturbance leading to the atrophy of the male reproductive health.

The average height of the epithelium in peripheral and central seminiferous tubules was measured and found to be  $10.10 \pm 2.23$  and  $18.32 \pm 1.53 \mu\text{m}$  respectively in the experimental rats as compared to the controls which were measured to be  $11.40 \pm 0.93$  and  $19.82 \pm 1.48 \mu\text{m}$  in the peripheral and central region respectively. Epithelial height was found to be statistically significantly reduced in the experimental rats when compared to the height of the epithelium in the control rats in both, the peripheral and central seminiferous tubules (Graph 6). It is suggested that due to the detachment of these cells from the basal lamina resulting in a vascular insufficiency causes sloughing of these cells into the lumen leading to the decrease in



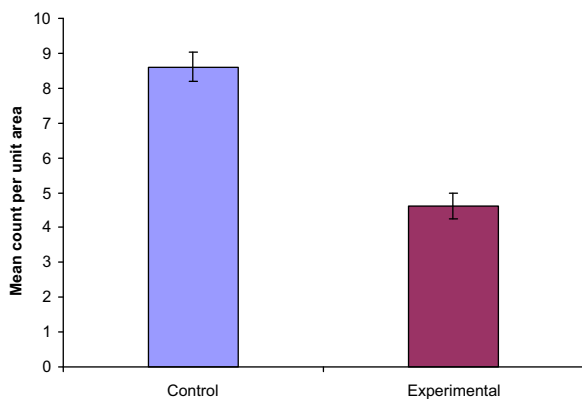
**Graph 5.** Comparison of mean diameters ( $\mu\text{m}$ ) of central seminiferous tubules in control and experimental rats.



**Graph 6.** Comparison of mean thickness ( $\mu\text{m}$ ) of the epithelium of the central and peripheral seminiferous tubules in control and experimental rats.

the height of the tubular epithelium in the deltamethrin treated rats resulting in a proportional spermatogenic hypoplasia with marked thinning of the spermatogenic cell rows. Testicular atrophy and degenerative changes of the seminiferous tubules have been reported in experimental animals with various insecticides [29,30]. Our histopathological results are in agreement with the observations of Hess and Nakai [28] who found that the administration of pyrethroids induced sloughing of germ cells and abnormal development of the head of elongating spermatids and assigned these changes to the intracellular redistribution of water and ions. Wu et al. [31] administered deltamethrin in corn oil, intraperitoneally to male Sprague-Dawley rats and found large number of cells showed pyknosis and disruption of eosinophilic cytoplasm, indicating cellular degeneration. Kilian et al. [26] after administration of deltamethrin in Sprague-Dawley rats observed a reduction of the epithelium thickness in testes along with apical sloughing and vacuolization which he suggested to be due to a disrupted endocrinal activity.

The comparison between the numbers of tubules per unit area revealed that the tubules per unit area had reduced in the experimental rats (Graph 7). This could be due to the increased edema in the interstitial space between the tubules along with the reduced tubular



**Graph 7.** Mean count of the seminiferous tubules per unit area ( $57,600 \mu\text{m}^2$ ) in control and experimental rats.

diameter as a result of atrophy of the tubules, massive spermatogenic necrosis, more so in the central regions of the testes. Tewari et al. [27] also observed a similar decrease in the number of tubules in the central region of the testis after deltamethrin and suggested that this may be due to the peculiar blood supply of the testis and/or because of the fibrosed tunica albuginea. Observations of our study are in conformity with those of the Elbetieha et al. [6] who observed an increase in the amount of connective tissue between seminiferous tubules, a decrease in the perimeter and the number of seminiferous tubules per unit area in male Sprague-Dawley rats after administration of a similar type II pyrethroid, cypermethrin. Similar observations have been reported by Clos et al. [32], Tamura et al. [33], Turner et al. [34], Hernandez et al. [35]. According to Manna et al. [11] repeated doses of deltamethrin in rats caused an edematous fluid accumulation between the tubules and focally at sites within some of the tubules. However in contrast, Ameen [36] reported that there was no fluid accumulation between the tubules in rats with type II pyrethroids. The difference in opinion may have resulted due to the higher dose and longer duration of the drug administration.

In control rats the interstitial tissue filled the intertubular space and consisted of loose meshwork of connective tissue with the fibroblasts, Leydig cells along with arterioles, venules and capillaries. Similar observations have been recorded by Richard et al. [37], Fawcett et al. [38]. In the experimental animal the intertubular space appeared to have increased. Deltamethrin probably caused damage to the components of the loose areolar tissue in the interstitial space along with the few of the Leydig cells resulting in an increase in the interstitial fluid which has emerged as edema. This was called testes tissue cell damage by Soleimanirad [39].

There is a significant increase in the incidence of male infertility in humans in the past decade possibly due to environmental contaminants like pesticides which act as endocrine disruptors [7]. Ever since the international technological shift in industrial and agricultural development from the 20th century they are being widely used involving handling and exposure although these are harmful to human. Despite the diversity of habits and cultures around the world, various authors have reaffirmed the possible significant drop in sperm quality and consequently an increase in male infertility rates, apparently this constitutes an international phenomenon [40–44]. The actual causes of increased infertility remain controversial but research suggests that pyrethroids to which men are exposed constantly in developing countries like India may be one of the major reasons that can affect male fertility.

Despite the relative lack of studies on this issue, the relevance of such risk calls for further studies as well as measures to prevent human exposure to the various environmental harmful substances which may be affecting the male reproductive system. The present study is one such attempt with deltamethrin in a mammal, the albino rat and it is suggested that the distinct histomorphological changes noted after chronic administration of deltamethrin are characteristic of toxic effects on the testis like tubular atrophy resulting in the absence or scarce formation of normal sperms and subsequent infertility.



## 5. Conclusion

There was a statistically significant increase in the body weight of the animals. The gross diameters of the testis did not reveal any statistically significant difference. The weight of the testis had probably increased due to the interstitial edema as observed histologically. There was a generalized significant decrease in the diameter of the tubules with an associated collapse and distortion at sites of the tubules predominantly in the central region which may have resulted due to the thickening of the tunica albuginea and a decrease in the vascularity in the central area of the testis. Epithelial height was found to be statistically significantly reduced in the experimental rats when compared to the height of the epithelium in the control rats in both, the peripheral and central seminiferous tubules. It is suggested that the detachment of these cells from the basal lamina resulted in a vascular insufficiency which caused sloughing of these cells into the lumen leading to the decrease in the height of the tubular epithelium in the deltamethrin treated rats resulting in a proportional spermatogenic hypoplasia with marked thinning of the spermatogenic cell rows. The distinct histopathological changes noted after administration of deltamethrin are characteristic of toxic effects on the testis.

## Transparency document

The [Transparency document](#) associated with this article can be found in the online version.

## Acknowledgements

I would like to express my profound gratitude to Dr. Mahindra Nagar, Dr. Kamlesh Khatri and Dr. Veena Bhardi who enlightened my period of work and invaluable guidance and continuous inspiration. Also like to thanks Mr. Laxman Singh for their assistance and technical support.

## References

- [1] J.M. Clark, Effects and mechanism of action of pyrethrin and pyrethroid insecticides, in: L.W. Chang, R.S. Dyer (Eds.), *Handbook of Neurotoxicology*, Marcel Dekker, New York, 1990, pp. 511–546.
- [2] D.N. Bateman, Management of pyrethroid exposure, *J. Toxicol. – Clin. Toxicol.* 38 (2) (2000) 107–109.
- [3] D.M. Soderlund, J.M. Clark, L.P. Sheets, Mechanisms of pyrethroid neurotoxicity: implications for cumulative risk assessment, *J. Toxicol.* 17 (1) (2002) 30–59.
- [4] M.I. Abd El-Aziz, A.M. Sahlab, M. Abd El-Khalik, Influence of diazinon and deltamethrin on reproductive organs and fertility of male rats, *Dtsch. Tierarztl. Wochenschr.* 6 (1994) 230–232.
- [5] M. O'Malley, Clinical evaluation of pesticide exposure and poisonings, *Lancet* 349 (1997) 1161–1166.
- [6] A. Elbetieha, S.I. Da'as, W. Khamas, H. Darmani, Evaluation of the toxic potentials of cypermethrin pesticide on some reproductive and fertility parameters in the male rats, *Arch. Environ. Contam. Toxicol.* 41 (2001) 522–528.
- [7] E.K.R. Queiroz, W. de Weissmann, Occupational exposures and effects on the male reproductive system, *Cad Saude Publica* 22 (2006) 485–493.
- [8] Abercrombie, *Anat. Rec.* 94 (1946) 239–247 (by the Wistar Institute of Anatomy and Biology, Philadelphia, PA. Annotations by Robert W. Williams (1998)).
- [9] L.R. Franca, M.O. Suescun, J.R. Miranda, A. Giovambattista, M. Perello, E. Spinedi, et al., Testis structure and function in a nanogenetic hyperadipose rat model at prepubertal and adult ages, *Endocrinology* 147 (2006) 1556–1563.
- [10] J.R. Corbett, K. Wright, A.C. Ballie, *The Biochemical Mode of Action of Pesticides*, Academic Press, London, 1984, pp. 382.
- [11] S. Manna, D. Bhattacharyya, T.K. Mandal, S. Dey, Neuropharmacological effects of deltamethrin in rats, *Vet. Sci.* 7 (2) (2006) 133–136.
- [12] D. Chen, X. Huang, L. Liu, N. Shi, Deltamethrin induces mitochondrial membrane permeability and altered expression of cytochrome C in rat brain, *J. Appl. Toxicol.* 27 (2007) 368–372.
- [13] R.J. Kavlock, G.P. Daston, C. DeRosa, P. Fenner-Crisp, L.E. Gray, S. Kaattari, et al., Research needs for the risk assessment of health and environmental effects of endocrine disruptors: a report of the US EPA-sponsored workshop, *Environ. Health Perspect.* 104 (1996) 715–740.
- [14] C. Madsen, M.H. Claesson, C. Ropke, Immunotoxicity of the pyrethroid insecticides deltamethrin and  $\alpha$ -cypermethrin, *Toxicology* 107 (1996) 219–227.
- [15] N. Patro, S.K. Mishra, M. Chattopadhyay, I.K. Patro, Neurotoxicological effects of deltamethrin on the postnatal development of cerebellum of rat, *J. Biosci.* 22 (1997) 117–130.
- [16] F. Sayim, N.U. Karabay-Yavasoglu, Y. Uyanikgil, H. Aktug, A. Yavasoglu, M. Turgut, Neurotoxic effects of cypermethrin in Wistar rats: a haematological, biochemical and histopathological study, *J. Health Sci.* 51 (2005) 300–307.
- [17] C. Varshneya, T. Singh, L.D. Sharma, H.S. Bahga, S.K. Garg, Immunotoxic responses of cypermethrin, a synthetic pyrethroid insecticide in rats, *Indian J. Physiol. Pharmacol.* 36 (1992) 123–126.
- [18] A.J.M. Andrade, S. Araújo, G.M. Santana, M. Ohi, P.R. Dalsenter, Reproductive effects of deltamethrin on male offspring of rats exposed during pregnancy and lactation, *Regul. Toxicol. Pharmacol.* 36 (3) (2002) 310–317.
- [19] R. Hebel, M.W. Stromberg, *Anatomy of the Laboratory Rat*, Williams & Wilkins Co., Baltimore, 1976.
- [20] P. Howroyd, R. Hoyle-Thacker, O. Lyght, D. Williams, E. Kleymenova, Morphology of the fetal rat testis preserved in different fixatives, *Toxicol. Pathol.* 2 (2005) 300–304.
- [21] A.A. Hassan, M.M. Hassouna, T. Taketo, C. Gagnon, M.M. Elhilali, The effect of diabetes on sexual behaviour and reproductive tract function in male rats, *J. Urol.* 49 (1993) 148–154.
- [22] M.M. Abd El-Khalek, N.A. Rahmy, H.H. Haleem, Effect of the pyrethroid insecticide cypermethrin on fertility in male rats, *Vet. Med. J. (Giza)* 47 (3) (1999) 295–305.
- [23] N.R. Kalla, M.P. Bansal, Effect of carbon tetrachloride on gonadal physiology in male rats, *Acta Anat.* 91 (1975) 380–385.
- [24] J. Rai, S.N. Pandey, R.K. Srivastava, Effect of immobilization stress on spermatogenesis of albino rat, *J. Anat. Soc. India* 52 (1) (2003) 55–57.
- [25] M. El-Gohary, W.M. Awara, S. Nassar, S. Hawas, Deltamethrin-induced testicular apoptosis in rats: the protective effect of nitric oxide synthase inhibitor, *Toxicology* 132 (1999) 1–8.
- [26] E. Kilian, R. Delpont, M.S. Bornman, D.T.C. Jageer, Simultaneous exposure to low concentration of dichlorodiphenyltrichloroethane, deltamethrin, non-phenol and phytoestrogen has negative effects on the reproductive parameters in male Sprague-Dawley rats, *J. Embryol. Androl.* 39 (2007) 128–135.
- [27] S.P. Tewari, Effect of vincristine on testis of rats, *Abst. Anat. Soc. Ind. Histochem.* V (1981).
- [28] R.A. Hess, M. Nakai, Histopathology of male reproductive system induced by the fungicide benomyl, *Histopathology* 15 (2002) 207–224.
- [29] J.C. Chapman, St.J. Warne, M. Patra, R.W.R. Patra, Considerations when applying the revised toxicant guidelines, *Aust. J. Ecotoxicol.* 7 (2001) 157–174.
- [30] D.N. Ezeasor, Light and electron microscopical observation on the Leydig cells of the scrotal and abdominal testis of naturally unilateral cryptorchidism in west American dwarf goats, *J. Anat.* 141 (1990) 27–40.
- [31] A. Wu, Y. Liu, Apoptotic cell death in rat brain following deltamethrin treatment, *Neurosci. Lett.* 279 (2) (2000) 85–88.
- [32] M. Clos, M. Ramoneda, G. Gracia, Modification of testicular cytochrome P-450 after fenitrothion administration, *J. Gen. Pharmacol.* 25 (1994) 499–503.
- [33] K. Tamura, M. Nei, S. Kumar, Prospects for inferring very large phylogenies by using the neighbor-joining method, *Proc. Natl. Acad. Sci.* 101 (2004) 11030–11035.
- [34] K.J. Turner, Effects of in utero exposure to the organophosphate insecticide fenitrothion on androgen dependent reproductive development, *Toxicol. Sci.* 68 (2002) 174–183.

- [35] A. Hernandez, M. Gomez, V. Perez, J. Gracialario, A. PLA, Influence of exposure to pesticides on serum components and enzyme activities of cytotoxicity among intensive agriculture farmers, *J. Environ. Res.* 102 (2006) 70–76.
- [36] M.O. Al-Jahdali, A.S. Bin Bisher, Testicular histopathological alterations in rats treated with sumithion, *J. Biol. Sci.* 7 (3) (2007) 520.
- [37] J.J. Richard, G.A. Junk, M.J. Avery, N.L. Nehring, J.S. Fritz, H.J. Svec, Analysis of various Iowa waters for selected pesticides: atrazine, DDE and dieldrin, *Pestic. Monit. J.* 9 (1975) 117.
- [38] R.S. Fawcett, B.R. Christensen, D.P. Tierney, The impact of conservation tillage on pesticide runoff into surface water: a review and analysis, *J. Soil Water Conserv.* 49 (1994) 126–135.
- [39] J. Soleimanirad, Experimentation, effects of EMF on spermatogenesis is process in rat medicine magazine, *Univ. Med. Sci.* 31 (1996) 55.
- [40] H.S. Swan, E.P. Elkin, L. Fenster, Have sperm densities declined? A reanalysis of global trend data, *Environ. Health Perspect.* 105 (1997) 1228–1232.
- [41] A.L. Golden, J.M. Moline, N. Bar-Chama, Male reproduction and environmental and occupational exposures: a review of epidemiologic methods, *Salud Pública Méx.* 41 (1999) 93–105.
- [42] N.E. Skakkebaek, E. Raipert-De Meyts, K.M. Main, Testicular dysgenesis syndrome: an increasingly common developmental disorder with environmental aspects, *Hum. Reprod.* 16 (2001) 972–978.
- [43] L. Multigner, A. Oliva, Secular variations in sperm quality: fact or science fiction? *Cad. Saúde Pública* 18 (2002) 403–412.
- [44] F.F. Pasqualotto, C.V. Locambo, K.S. Athayde, S. Arap, Measuring male infertility: epidemiological aspects, *Rev. Hosp. Clín. Fac. Med. Univ. São Paulo* 58 (2003) 173–178.