

In vivo confocal microscopy of iris in recessive cornea plana with anterior synechiae

Enrico Bruni^{1,2}, Emilio Pedrotti¹, Paolo Plinio Di Sarro¹,
Mattia Passilongo¹, Giorgio Marchini¹

Access this article online	
Quick Response Code:	Website: www.ijo.in
	DOI: 10.4103/ijo.IJO_346_18

¹Eye Clinic, Department of Neurosciences, Biomedicine and Movement Sciences, University of Verona, Ple Ludovico Antonio Scuro 10, ²Sacro Cuore Don Calabria Hospital, Negrar, Verona, Italy

Correspondence to: Dr. Enrico Bruni, Sacro Cuore Don Calabria Hospital, Via Don A. Sempredoni, 5, 37024 Negrar (Verona), Italy. E-mail: enrico.bru@libero.it

Manuscript received: 26.03.18; Revision accepted: 19.05.18

Key words: Anterior synechiae, confocal microscopy, cornea plana, iris

We present a case of iris synechiae visualization with utilization of laser scanning vivo confocal microscopy (LSCM) in the recessive cornea plana. Autosomal recessive cornea plana (ARCP) is characterized by a flattened corneal surface associated with hyperopia and various anterior segment anomalies such as: corneal opacity, microcornea, anterior segment synechiae and a shallow anterior chamber.^[1] The diagnosis is based on clinical and keratometric findings.^[2]

Case

We examined confocal microscopy in a patient with cornea plana, anterior synechiae and shallow anterior chamber [Fig. 1]. Confocal microscopy was performed with HRT III Rostock Cornea Module (Heidelberg engineering, Germany). As previously reported by

This is an open access journal, and articles are distributed under the terms of the Creative Commons Attribution-NonCommercial-ShareAlike 4.0 License, which allows others to remix, tweak, and build upon the work non-commercially, as long as appropriate credit is given and the new creations are licensed under the identical terms.

For reprints contact: reprints@medknow.com

Cite this article as: Bruni E, Pedrotti E, Di Sarro PP, Passilongo M, Marchini G. *In vivo* confocal microscopy of iris in recessive cornea plana with anterior synechiae. Indian J Ophthalmol 2018;66:1311-3.

Vesaluoma, the Bowmann layer was absent^[3] and keratocytes appeared fewer than in normal individuals. During the exam we discovered a fibrous-like trabecular structure with: ramifications, interdigitations and scattered round processes below the corneal endothelium [Figs. 2-5] that represent the iris tissue and the anterior iridocorneal synechiae

Discussion

Some researchers have tried to study the iris with a modified non-contact laser scanning *in vivo* confocal microscopy (LSCM)^[4] by changing the camera lens and increasing the working distance; however, the quality of images was subpair. Li *et al.* have reported iris ultrastructure in patients with anterior synechiae^[5] as revealed by LSCM. They found five patterns of iris ultrastructure: trunk-like, branch/bush-like, fruit-like, epithelioid-like, and deep, going from anterior to posterior. Our confocal microscopy images show four patterns of iris ultrastructure: in Figs. 2 and 3, a web-like (trabecular) structure right below the corneal endothelium might represent the fibrous scar tissue of the anterior border layer of the iris synechiae [Figs. 2 and 3]. This pattern is similar to the tree-branch structure found by Li *et al.*, but our images show much thinner, much highly reflective branches, and wider empty spaces. Scattered round processes are visible and might represent pigment agglomerates. We were able to detect a deeper trunk [Fig. 4] and branch/bush-like [Fig. 5] structures as reported by Li *et al.*

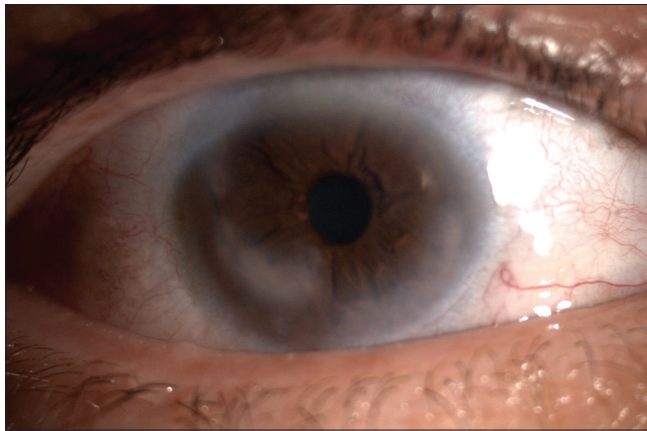


Figure 1: Slit-lamp photograph of cornea plana with anterior synechiae. Note the underlying iris tissues were dragged toward the corneal scars (adherent leukoma)

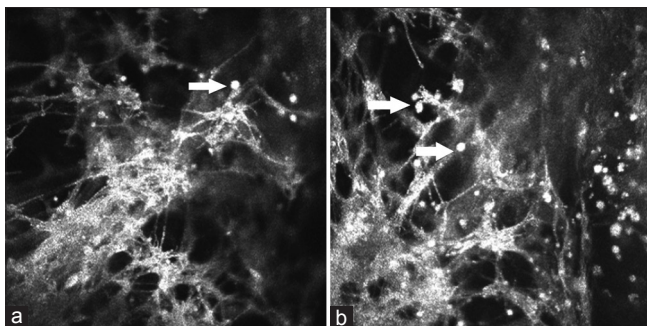


Figure 3: (a and b) Trabecular structures found below the corneal endothelium with numerous pigment clumps (white arrows)

Conclusion

In conclusion, we found a new trabecular structure right below the corneal endothelium [Figs. 2 and 3] that has never been seen in literature. This structure may represent the true synechiae between the anterior border layer iris and the corneal endothelium. While the images displayed by Li *et al.* show normal iris ultrastructure, our images display the stretched and fibrous iris tissue adherent to the corneal endothelium. We

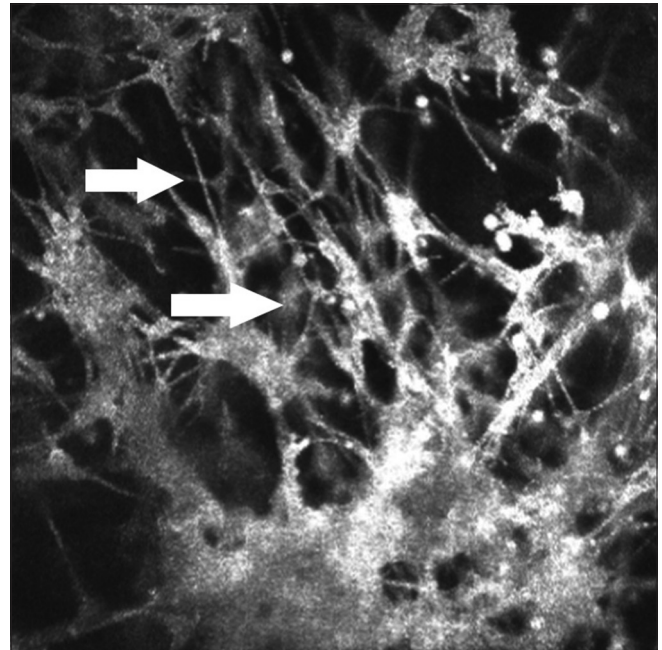


Figure 2: An example of fibrous web-like (trabecular) structure with thin branches (white arrows) in human iris with anterior synechiae by *in vivo* LSCM

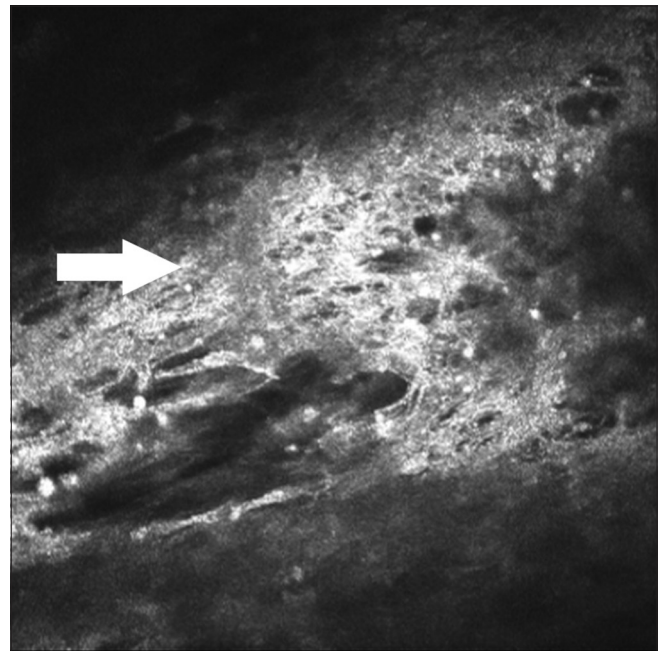


Figure 4: Trunk-like iris structure with scattered pigment clumps. Note the support structure with thick arrangement (arrow)

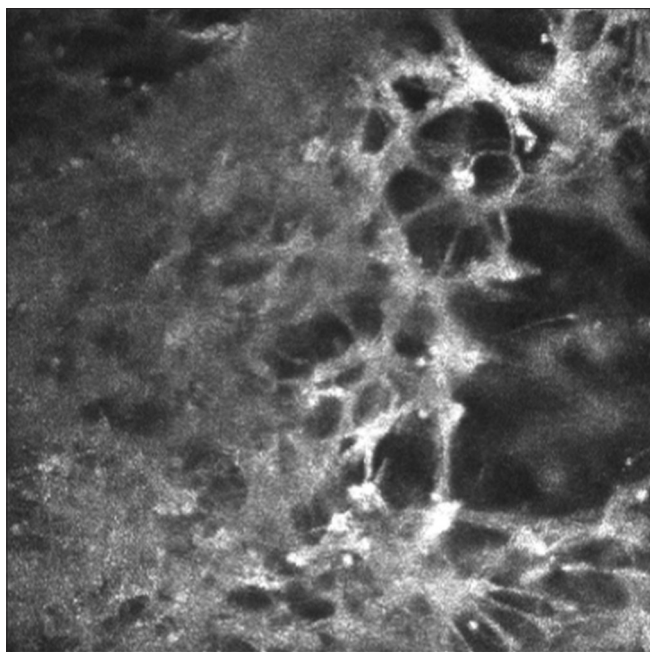


Figure 5: Bush-like iris structure

were able to observe trunk-like and branch/bush-like structures at a deeper level into the iris as previously reported by Li *et al.* While deep structures are difficult to analyze due to limited penetration of laser light, LSCM is an excellent diagnostic tool

in autosomal recessive cornea plana and offers the possibility of visualizing iris ultrastructure when anterior synechiae are present.

Financial support and sponsorship

Nil.

Conflicts of interest

There are no conflicts of interest.

References

1. Ebenezer ND, Patel CB, Hariprasad SM, Chen LL, Patel RJ, Hardcastle RJ, *et al.*, Clinical and molecular characterization of a family with autosomal recessive cornea plana. *Arch Ophthalmol* 2005;123:1248-53.
2. Rantala E, Majander A. Anterior segment optical coherence tomography in autosomal recessive cornea plana. *Acta Ophthalmol Scand* 2015;93:232-3.
3. Vesaluoma MH, Sankila EM, Gallar J, Muller RJ, Petroll WM, Mollanen JA, *et al.* Autosomal recessive cornea plana: *In vivo* corneal morphology and corneal sensitivity. *Invest Ophthalmol Vis Sci* 2000;41:2120-6.
4. Sbeity Z, Palmiero PM, Tello C, Liebmann JM, Ritch R. Non-contact *in vivo* confocal scanning laser microscopy in exfoliation syndrome, exfoliation syndrome suspect and normal eyes. *Acta Ophthalmol Scand* 2011; 89:241-7.
5. Li M, Cheng H, Guo P, Zhang C, Tang S, Wang S. Iris ultrastructure in patients with synechiae as revealed by *in vivo* laser scanning confocal microscopy: *In vivo* iris ultrastructure in patients with Synechiae by Laser Scanning Confocal Microscopy. *BMC Ophthalmol* 2016;15(Suppl 1):46.